

## Teaching Point (Section Editor: W. Herrington)

# Hemodialysis-associated endovascular device infection

Edward A. Ross<sup>1</sup>, Jennifer L. Paugh-Miller<sup>1</sup> and Robert W. Nappo<sup>2</sup>

<sup>1</sup>Division of Nephrology, Hypertension and Renal Transplantation, University of Florida, Gainesville, FL, USA and <sup>2</sup>Shands Hospital, University of Florida, Gainesville, FL, USA

Correspondence and offprint requests to: Edward A. Ross; E-mail: rossea@medicine.ufl.edu

**Keywords:** bacteremia; endocarditis; stent

### Introduction

Bacteremia is a major concern in hemodialysis patients being evaluated for fever, and identifying a source of ongoing infection is often challenging. In the absence of an obvious catheter-related nidus, clinicians typically consider a wide range of entities including endocarditis, osteomyelitis, joint infections and epidural abscesses. Despite advanced CT, magnetic or radionuclide imaging techniques, however, the site of continuing or relapsing infection can remain occult. We believe that endovascular stents are an under-appreciated potential location for such infections. The use of these devices has become increasingly common and is of particular concern when deployed for access-associated venous stenoses in dialysis patients. With the widespread use of endovascular devices, and especially in circumstances when care is rendered at multiple facilities, the patients and their medical providers may be unaware that those devices are present. There is much human and animal model literature describing the use of arterial and venous stents made from bare metal or combined with polymeric materials [1]. Although they are subject to infection upon implantation, it appears that the risk decreases with the endothelialization that historically was thought to occur over approximately 4 weeks. The speed and ultimate coverage area of cell growth is, however, controversial [2]. There is evidence that stents can become infected more than a month post-insertion, perhaps when associated with incomplete endothelial growth, thrombi or local trauma (e.g. needle cannulation) [3].

We present here a patient with persistent bacteremia due to an infected vena cava stent, complicated by the presence of a vegetation. This case highlights the importance of detecting these devices when evaluating febrile hemodialysis patients and the challenges in determining the optimal surgical or medical plan of care.

### Case

A 53-year-old female on chronic hemodialysis was transferred to our medical center (University of Florida Shands

Hospital, Gainesville, FL, USA) for recurrent methicillin-resistant *Staphylococcus aureus* (MRSA) bacteremia and vegetations on a superior vena caval (SVC) stent. This report follows our University's Institutional Review Board guidelines.

Twenty-one months prior to this admission (PTA) she had care elsewhere for appendicitis complicated by perforation, retroperitoneal abscess and MRSA wound infection. With underlying diabetic nephropathy she then sustained acute kidney injury and rapidly became dialysis dependent. Both internal jugular veins were utilized for hemodialysis access. Ten months PTA she underwent placement of a left upper extremity arteriovenous graft. Eight months prior to transfer, she developed SVC syndrome with venous thromboses that involved the bilateral internal jugular veins. An SVC stent was placed immediately proximal to the right atrium. Within weeks of the procedure she experienced multiple episodes of MRSA bacteremia, failing repeated courses of intravenous daptomycin. Six months PTA transesophageal echocardiography demonstrated vegetations in the SVC stent. Despite intravenous vancomycin therapy and then oral doxycycline, at 3 months PTA her dialysis access graft became infected, was removed and later replaced with one of bovine material. With ongoing antibiotics a repeat echocardiogram showed improvements in the vegetations. Later, antibiotics were stopped and within a week facial edema recurred. Imaging confirmed recurrent SVC syndrome, for which the stent was extended and venoplasty performed. This was soon followed by fevers, chills, documented MRSA bacteremia and re-institution of vancomycin. Echocardiography showed persistence of the SVC stent vegetations. A radionuclide-labeled white blood cell scan demonstrated uptake there. She was then transferred to our medical center for consideration of surgical excision of the SVC stents with possible axillary-atrial venous bypass.

On admission she was well-nourished, and (remarkably) healthy-appearing. The physical examination was quite benign, with her being afebrile (36.0°C), blood pressure 167/83 mmHg, heart rate 65 bpm, 92.3 kg, no edema, lungs clear, heart without murmurs, abdomen without organomegaly, extremities with functioning left forearm dialysis access graft, and skin only showing multiple

healed incisions. Laboratory data included a normal white blood cell count of  $6.5 \times 10^9/L$ , hemoglobin 110 g/L, platelets  $327 \times 10^9/L$  and chemistry values consistent with adequate dialysis. She arrived on vancomycin and multiple blood cultures remained negative. Transthoracic echocardiography demonstrated the stent extending from the SVC into the main body of the right atrium. There was an  $\sim 0.7$  cm vegetation with limited mobility on the stent's luminal surface (Figure 1), and a smaller more mobile mass at its edge. The images were consistent with her history of an infected vegetation and focal areas of possible thrombi. The cardiothoracic surgery consultant opined that excision of the stent would be of very high risk and hopefully could be avoided if a more effective antibiotic regimen could be devised. The infectious disease consultants preferred stent removal followed by at least 6 weeks of antibiotics, but with that not being readily feasible they devised a new medical regimen. Rifampin and gentamicin were added to the vancomycin, for a total of 8 weeks of therapy and followed by serial surveillance cultures. The intravenous vancomycin and gentamicin doses were guided by blood levels, and the rifampin was administered at 600 mg per day orally. Warfarin dosing was appropriately increased so as to maintain systemic anticoagulation during concurrent use of rifampin. The patient was discharged on this triple antibiotic regimen for 8 weeks, and 12 months after its completion remains clinically well without recurrent infection.

## Discussion

In the five decades since their initial design, endovascular stents have undergone much development and study for their use in arterial and venous disease. Indications and results vary depending on multiple factors that include the type of vessel, location, size, elasticity and presence of atherosclerosis or thrombi. Safety concerns traditionally have focused on the complications of recurrent stenosis, thrombosis and device migration. Stents have had increasing utilization in hemodialysis patients and are typically deployed at post-anastomotic peripheral access or central vein sites [1, 4]; however, the initial animal studies instead focused on various aspects of arterial stents, mostly in swine models and with a paucity of long-term

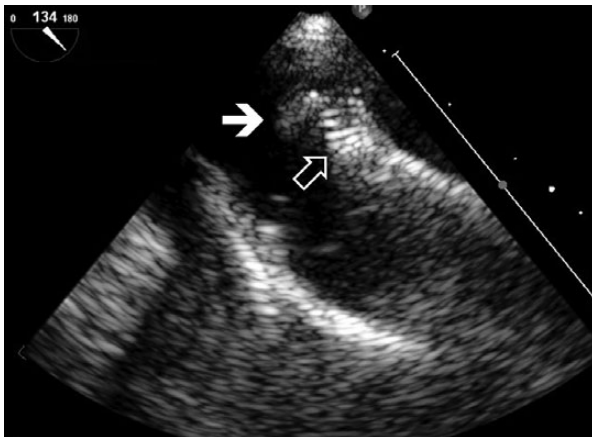


Fig. 1. Echocardiogram image demonstrating the sessile mass (solid arrow) at the endovascular stent (open arrow at white parallel striations).

results. It is thought that much of the protection against restenoses or infection is derived from endothelialization over the stent's surface. Depending on factors such as the characteristics of the woven filaments (e.g. diameter, nodal distance), composition (bare metal or polymer-coated) and luminal surface area, it has been traditionally thought that endothelial covering of the device may take 4 weeks or longer to develop. It is apparent, though, that risk can extend beyond an arbitrary post-procedure interval and it is possible that some stent surfaces may never have a uniform cellular layer. This was highlighted by McLennan *et al.*'s [2] canine model in which polytetrafluoroethylene-covered metal stents were placed across the venous anastomosis of arteriovenous grafts, and were subsequently studied by intravascular ultrasound and histology. At 1 month, 59% of the luminal stent surfaces were covered by a mural thrombus layer. In a limited sampling of 33 sections only one demonstrated endothelialization, and the cells covered a mere 20% of that surface.

Consistent with there being risk from incompletely endothelialized stent surfaces, Thibodeaux *et al.* [5] demonstrated that when *S. aureus* bacteremia was experimentally induced 3 weeks following arterial bare metal stent insertion in a swine model, 60% of the devices became infected. At 4 weeks [3], 50% could still be seeded with bacteria. Gross images revealed that patches of the metallic mesh surface remained uncovered [5]. Similar to these animal model findings, there have been human cases of infected arterial stents [6], including those at coronary [7] and iliac [8] sites.

It has thus been suggested that the first month after stent placement is of the most concern for complications [9, 10]. Slow, incomplete or patchy cell coverage would prolong the risk of thrombus formation or be a site for microbial seeding. Conversely, thrombus formation, such as that on bare steel mesh stents, might delay endothelialization and thus extend the risk of bacterial seeding. This highlights the need for appropriate anticoagulation [10]. In a given individual it may be impossible to discern whether thrombus formation was primary or secondary to infection.

Long-term human experience with the complications from venous stents is scant, especially for dialysis applications. Guest *et al.* [10] described a patient similar to ours, although it occurred at a subclavian vein stent and there was no direct visualization of a vegetation. They stressed the difficulties of surgical excision and their case was cured with antibiotics. Naddour *et al.*'s [11] case involved stenting at the innominate and subclavian veins. In both publications infection with *S. aureus* occurred early (3 weeks) in the post-implantation interval. There is additional risk when dialysis needles are cannulated directly into stents and cause physical damage to the mesh. Asif *et al.* [12] reported that the resultant broken wires can erode beyond the vessel and through the skin, leading to bleeding or infection. Nevertheless, to put these case reports in perspective, a larger study of percutaneously-placed polytetrafluoroethylene-covered metal stent grafts for post-anastomotic hemodialysis access venous stenoses had excellent success for up to 6 months. Haskal *et al.* [1] reported that there were infectious complications in 6 of 95 patients with the stents, compared with 2 of 90 who just underwent angioplasty, which was not statistically different.

Although surgical removal of infected stents would be ideal, the potential difficulty and complications from surgical removal ought not be underestimated. This is of

particular concern for central large vein stents. Excision can be exceptionally difficult due to infection, inflammation and fibrosis of surrounding tissue, the need for venous bypass and the risk of recurrent infection. Bates and Almehti [13] described a mycotic aneurysm at a subclavian artery stent site and the patient's death due to multiple infectious complications following surgical excision. A minimally invasive approach, however, may be possible for removing central catheters tethered to central veins or intra-cardiac structures. This promising technology was described by Carrillo et al. [14] wherein a laser sheath was used in three patients to detach catheters that were adhered to central veins and the right atrium. The external sheath was also successfully utilized to aspirate thrombus. This new methodology has not yet been widely adopted nor used for infected clots. In regard to medical management, since Verghese et al.'s 1985 report [15] it has been recognized that central venous thrombophlebitis can potentially be treated with antibiotics; however, those patients did not have foreign bodies present. In the presence of stent hemodialysis-associated endovascular device infection (HEDI), anecdotal reports of successful conservative care using prolonged courses of antibiotics are encouraging. Guest et al. [10] used 9 weeks of antibiotics, Naddour et al. [11] administered them for 6 weeks and both reported success for *S. aureus*. Nevertheless, long-term suppressive antibiotic therapy has also been recommended in some cases [16].

Investigators have suggested that during the post-deployment interval of greatest risk there needs to be more rigorous use of antibiotic prophylaxis for procedures associated with bacteremia [8–10]; however, as noted above, the duration of exposed non-epithelialized stent material is ill-defined, unpredictable and varies between devices and patients. Robust prophylaxis guidelines for stents have yet to be crafted for these circumstances, and is a topic worthy of future investigation.

In light of the limited literature and lack of rigorous randomized control trials for HEDI, we believe it prudent to adopt an approach wherein dialysis patients are given prophylactic antibiotics for bacteremia-associated procedures (e.g. dental, colonoscopies) for the first month post-stent placement, and longer if there is re-intervention (e.g. stent extension or intra-stent thrombolysis). Based on this case and other reported patients, we believe clinicians need to be exceptionally vigilant for endovascular device infections during the early post-placement timeframe and be aware that the risk subsequently declines but likely never to zero.

For febrile or bacteremic hemodialysis patients who have incomplete medical records or may have had care at other facilities, there needs to be a low threshold for appropriate imaging to detect metallic stents or stent grafts. Depending on the location of the infected stent the clinical presentation can be highly variable, ranging from isolated fever (e.g. fever of unknown origin) to focal abscesses, sepsis, septic emboli or unusual manifestations such as immune complex vasculitis. The features of cardiovascular device infections were reviewed by Baddour et al. [16] who likened the findings to those of infectious endocarditis or endarteritis. Although they described *Staphylococci* as being the most common organisms, we stress the need for appropriate blood culture technique so as to be able to identify unusual, fastidious or fungal organisms [17, 18]. With central line infections being a growing focus of concern and quality improvement in hospitals [19], it is relevant that catheters would be at risk to seed or be seeded by occultly infected stents. Inappropriately

labeling silent HEDI as a case of just catheter-associated bacteremia would lead to inappropriate care. We suggest ultrasound imaging as an initial step for detecting endovascular lesions, as it is a relatively inexpensive noninvasive modality. The sensitivity of radionuclide (e.g. gallium citrate or labeled white blood cells) scans to detect stent infections has not been established, but this scintigraphy has anecdotally been very helpful. Fiorani et al. [20] highlighted the potential difficulty in making a diagnosis of endograft (aortoiliac) infections, with patients often presenting with non-specific signs. CT and leukocyte-labeled scintigraphy was recommended and the authors stressed the need for the development of better diagnostic modalities.

In summary, based on our experience and that from other cases, we believe that surgical excision of infected stents with a subsequent long course of antibiotics is the preferred treatment approach. While typically feasible for sites in the extremities, there may be very high risk to removing devices in large central veins such as the superior vena cava. The surgery can be extremely complex due to inflammation and fibrosis of nearby tissues, the need for venous bypass and fear of it too becoming infected. The risks and benefits of surgical versus medical treatment under these circumstances are best evaluated on a case by case basis. Fortunately, there are individuals such as our patient who had successful treatment of *S. aureus* with conservative care using multiple antibiotics for a prolonged period of time.

## Teaching Points

This case of HEDI illustrates four clinical lessons:

1. The need to identify the presence of these foreign objects in individuals with incomplete or scattered medical records;
2. The ability to image this complication by radionuclide scanning or by ultrasonic detection of the endovascular lesions;
3. The difficulty in curing these infections even with prolonged courses of multiple antibiotics;
4. The appreciation that surgical excision is usually the best option but could be technically challenging and of very high risk.

*Conflict of interest statement.* None of the authors have any conflicts of interest.

## References

1. Haskal ZJ, Trerotola S, Dolmatch B et al. Stent graft versus balloon angioplasty for failing dialysis-access grafts. *N Engl J Med* 2010; 362: 494–503
2. McLennan G, Trerotola SO, Forney M et al. Short-term patency and safety of an expanded polytetrafluoroethylene encapsulated endoluminal device at the venous anastomosis of a canine arteriovenous graft model. *J Vasc Interv Radiol* 2001; 12: 227–234
3. Hearn AT, James KV, Lohr JM et al. Endovascular stent infection with delayed bacterial challenge. *Am J Surg* 1997; 174: 157–159
4. Quinn SF, Schuman ES, Hall L et al. Venous stenoses in patients who undergo hemodialysis: treatment with self-expandable endovascular stents. *Radiology* 1992; 183: 499–504
5. Thibodeaux LC, James KV, Lohr JM et al. Infection of endovascular stents in a swine model. *Am J Surg* 1996; 172: 151–154

6. Therasse E, Soulez G, Cartier P *et al.* Infection with fatal outcome after endovascular metallic stent placement. *Radiology* 1994; 192: 363–365
7. Bouchart F, Dubar A, Bessou JP *et al.* Pseudomonas aeruginosa coronary stent infection. *Ann Thorac Surg* 1997; 64: 1810–1813
8. Bunt TJ, Gill HK, Smith DC *et al.* Infection of a chronically implanted iliac artery stent. *Ann Vasc Surg* 1997; 11: 529–532
9. Paget DS, Bukhari RH, Zayyat EJ *et al.* Infectibility of endovascular stents following antibiotic prophylaxis or after arterial wall incorporation. *Am J Surg* 1999; 178: 219–224
10. Guest SS, Kirsch CM, Baxter R *et al.* Infection of a subclavian venous stent in a hemodialysis patient. *Am J Kidney Dis* 1995; 26: 377–380
11. Naddour F, Yount RD, Quintal RE. Successful conservative treatment of an infected central venous stent. *Catheter Cardiovasc Interv* 2000; 51: 196–198
12. Asif A, Gadalean F, Eid N *et al.* Stent graft infection and protrusion through the skin: clinical considerations and potential medico-legal ramifications. *Semin Dial* 2010; 23: 540–542
13. Bates MC, Almeihmi A. Fatal subclavian stent infection remote from implantation. *Catheter Cardiovasc Interv* 2005; 65: 535–539
14. Carrillo RG, Garisto JD, Salman L *et al.* A novel technique for tethered dialysis catheter removal using the laser sheath. *Semin Dial* 2009; 22: 688–691
15. Verghese A, Widrich WC, Arbeit RD. Central venous septic thrombophlebitis—the role of medical therapy. *Medicine (Baltimore)* 1985; 64: 394–400
16. Baddour LM, Bettmann MA, Bolger AF *et al.* Nonvalvular cardiovascular device-related infections. *Circulation* 2003; 108: 2015–2031
17. Manian FA. Vascular and cardiac infections in end-stage renal disease. *Am J Med Sci* 2003; 325: 243–250
18. Harlock JA, Qadura M, Lee G *et al.* Infected aortic stent graft with Propionibacterium acnes. *Vasc Endovascular Surg* 2013; 47: 394–396
19. Hernandez-Boussard T, McDonald KM, Morton JM *et al.* Determinants of adverse events in vascular surgery. *J Am Coll Surg* 2012; 214: 788–797
20. Fiorani P, Speziale F, Calisti A *et al.* Endovascular graft infection: preliminary results of an international enquiry. *J Endovasc Ther* 2003; 10: 919–927

Received for publication: 3.12.13; Accepted in revised form: 16.12.13