



Contents lists available at ScienceDirect

International Journal of Surgery Case Reports

journal homepage: www.casereports.com

Complete laceration of motor branches of facial nerve and its successful repair: A case report from Afghanistan

Sayed Hamid Mousavi^{a,b,1}, Sharifeh Haghjoo^{c,1}, Azin Tahvildari^{d,1}, Shohra Qaderi^{a,*,1}

^a Medical Research Center, Kateb University, Kabul, Afghanistan

^b Afghanistan National Charity Organization for Special Diseases (ANCOSD), Kabul, Afghanistan

^c Department of Medical Informatics, Faculty of Medicine, Kabul University of Medical Sciences, Kabul, Afghanistan

^d Student Research Committee, School of Medicine, Shahid Beheshti University of Medical Sciences, Tehran, Iran

ARTICLE INFO

Article history:

Received 27 February 2021

Received in revised form 22 March 2021

Accepted 22 March 2021

Available online 26 March 2021

Keywords:

Afghanistan

Low resources country

Full recovery

Nerve laceration

Facial paralysis

ABSTRACT

INTRODUCTION: Facial nerve (the seventh cranial nerve) injury causes functional, aesthetic, and psychological difficulties. The second most common cause of facial nerve palsy is trauma.

PRESENTATION OF CASES: A previously healthy 21-year-old worker, was brought to emergency room after car accident, with complete paralysis of all muscles of the left side of his face. He was transferred to operating room. After anatomical determining the nerve, end-to-end manner was done. After nine month of follow up an excellent repair was seen.

DISCUSSION: Traumatic facial nerve injury is usually accompanied by temporal bone fracture (up to 70 percent) but in some cases facial nerve is damaged without any fractures, and damage of facial nerve branches can happen due to laceration. Management of an injured facial nerve depends on its etiology. There are three main options for facial nerve repair; direct end-to-end coaptation, coaptation with an interposition graft and nerve transfer. Surgery exploration is indicated in patients with complete and immediate facial nerve paralysis and denervation more than 90 % electrophysiological findings.

CONCLUSION: Traumatic facial nerve paralysis management is challenging considering operation in low resources countries. In this case early repair of facial nerve is beneficial and has a good to excellent prognosis in immediate complete damage of facial nerve even without accessibility to electroneurography or electromyography to estimate the severity of injury.

© 2021 Published by Elsevier Ltd on behalf of IJS Publishing Group Ltd. This is an open access article under the CC BY-NC-ND license (<http://creativecommons.org/licenses/by-nc-nd/4.0/>).

1. Introduction

Facial nerve, the seventh cranial nerve has origin from the lower pons and curves in the cerebellopontine angle (CPA) to enter the internal auditory meatus along the vestibular cochlear nerve [1]. The most common cause is idiopathic paralysis or bell's palsy, and other common etiologies are various traumas [2]. The best choice of treatment for a transected and known site of injury is tension free directed end-to-end coaptation [3]. Prognosis of facial nerve surgical repair is associated with a lot of factors. The location of the nerve injury shown to be a crucial factor, and early surgical repair was associated with a better prognosis in which a 21 months post operation demonstrated a significant improvement [4,5]. Based on the Surgical CAse REport, 2020 (SCARE) guidelines [6], here we present a cases of a young Afghan man with complete laceration

of motor branches of facial nerve, grades VI of House-Brackmann System (HB) with a successful surgical repair in a hospital of Kabul, Afghanistan [7].

2. Case presentation

A previous healthy 21-year-old male worker who were brought to the emergency department of a hospital in Kabul, with a deep laceration in the left temporal area about 2.5 cm in the front of the ears to the area under the lower lip of approximately 72 h after a car accident. Family history, drug history and social history were unremarkable. On examination wound depth was considerable and spread to the underling bones. The paralysis and immobility in all the muscles of the left half was apparent. Disability in eyebrows raising, or closing eyelid was seen, complete paralysis of the muscles around the month and chin was obvious (Fig. 1). After control of bleeding and compression bandage, he was transferred to ENT ward for further interventions. Facial bones x-ray showed no bone injury and fractures, Magnetic Resonance Imaging (MRI) was not available in the center. Blood investigation revealed a total leucocyte count of 7000/mcl (Normal 4000/mcl to 11,000/mcl), Hemoglobin (HB)

* Corresponding author.

E-mail addresses: Dr.Mousavi@kateb.edu.af (S.H. Mousavi), Haghjoo@kums.edu.af (S. Haghjoo), Azintahvildari@sbmu.ac.ir (A. Tahvildari), Shohra.qaderi@yahoo.com (S. Qaderi).

¹ Equal Authorship.

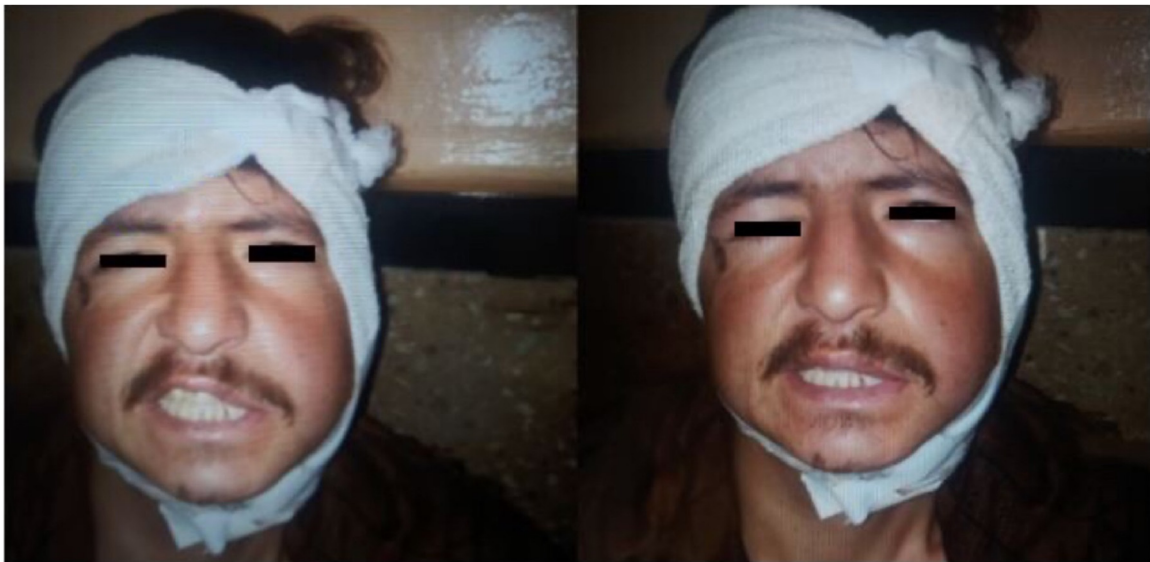

Fig. 1. Disability in left eyelid raising and inability in smiling.

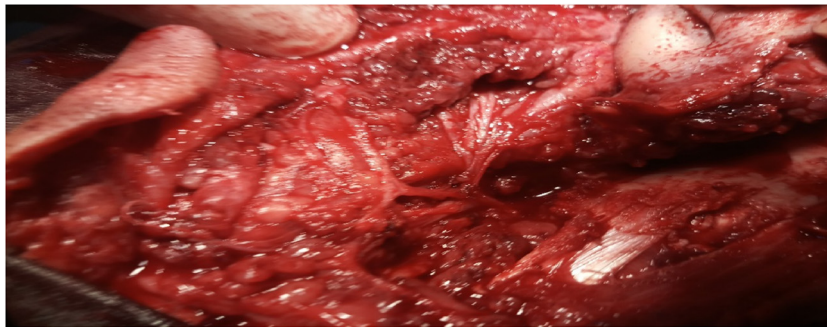

Fig. 2. The nerve branches are shown during the operation.




Fig. 3. The photo shows improvement in muscles function.

Table 1
Scale of facial muscle function after repair.

Grade	Results	Definition of Recovery
I	Super	Excellent with minimal mass movement
II	Excellent	Mass movement; can close eyes, smile
III	Good	Tone and symmetry without ability to smile and close eyes simultaneously
IV	Fair	Incomplete eyelid closure or very weak mouth movement
V	Poor	Symmetry only, tone intact, no movement
VI	Failure	Flaccid, tone lost

12 g/dL (Normal 13 g/dL to 18 g/dL), Platelet 203×10^3 (Normal 140×10^3 to 400×10^3), Partial Thromboplastin Time (PTT) 32 (Normal 23 s to 35 s), International Normalized Ratio (INR) 1 (Normal 0.8–1.1), Erythrocyte Sedimentation Rate (ESR) 10 mm/ 1 h (Normal Up to 14 mm/ hour), and C-Reactive Protein (CRP) 5 (Normal < 10 mg/L). The patient was taken to the operating room. The longitudinal incision was performed under general anesthesia. During operation all motor branches of the facial nerve were cut including, frontotemporal, zygomatic-buccal, and mandibular. However, the trunk of facial nerve was intact (Fig. 2). Anatomical determining of proximal and distal parts of nerves were done. End-to-end manner under magnification microscope with 9/0 nylon was applied. The surgery was carried out for about 6 h under supervision of attending ENT surgeon. The patient was discharged 48 h after surgery with advice of doing facial muscles physiotherapy, he returned for the follow-up at the ninth months after surgery with an improvement in the performance of muscles except for the frontal and forehead muscles. According to the clinical findings (good to excellent), strip grade 2 (Table 1), was seen (Fig. 3). The patient could not afford to pay for doing EMG-NCV.

3. Discussion

Facial nerve, the seventh cranial nerve has origin from lower pons and curves in the cerebellopontine angle (CPA) to enter the internal auditory meatus along the vestibular cochlear nerve [1]. Facial nerve injury causes functional, aesthetic, and psychological difficulties, occurring as a result of mechanical, chemical, or ischemic damages in which caused by trauma, or iatrogenic damages [8]. The most common cause is idiopathic paralysis or bell's palsy, and trauma is the second most common cause of facial nerve palsy [9]. Traumatic facial nerve injury is usually accompanied by temporal bone fracture (up to 70 percent) but in some cases facial nerve is damaged without any fractures, and damage of facial nerve branches can happen due to laceration [10].

Approach to acute facial nerve paralysis and its management can be challenging; when to operate and when consider conservative management [11]. The management of the injured facial nerve depends on its etiology of injury and there are three main options for facial nerve repair; direct end-to-end coaptation, coaptation with an interposition graft, and nerve transfer [12]. According to Darrouzet et al. study, surgery exploration is indicated in patients with complete and immediate facial nerve paralysis and electrophysiological findings denervation more than 90 % [11] This patient indicated for surgery due to complete and immediate paralysis. Electrophysiological testing was unavailable in the hospital.

Function recovery of facial nerve depends on the severity of injury and timing of onset [13], and patients who have paresis and later develop complete paralysis have a better prognosis [14]. Although this patient had a complete immediate paralysis, 9 months after surgery, muscle performance improved and strip grade 2 (good to excellent) was seen.

In Conclusion; Traumatic facial nerve paralysis management is challenging considering operation in low resources countries. In this case we demonstrated that early repair of facial nerve is beneficial and has a good to excellent prognosis in immediate complete damage of facial nerve even without accessibility to electroneurography or electromyography to estimate the severity of injury.

Declaration of Competing Interest

The authors report no declarations of interest.

Sources of funding

None.

Ethical approval

This is a case report paper.

Consent

Informed consent was obtained from the both of the patients, for publication of this case report and accompanying images. A copy of the written consent is available for review by the Editor-in-Chief of this journal on request.

Author contribution

SH and SQ conceptualized the study, SHM and SQ acquisition of data, and drafting the manuscript, AT and SH revising for critical intellectual concept and approved of the version to be submit.

Registration of research studies

Not applicable.

Guarantor

Corresponding author is Dr. Shohra Qaderi accept full responsibility for the work and/or the conduct of the study, had access to the data, and controlled the decision to publish.

Provenance and peer review

Not commissioned, externally peer-reviewed.

References

- [1] A. Patel, A. Makaryus, StatPearls [Internet], 29, StatPearls Publishing, Treasure Island (FL), 2020, Apr.
- [2] M.H. Hohman, T.A. Hadlock, Etiology, diagnosis, and management of facial palsy: 2000 patients at a facial nerve center, *Laryngoscope* 124 (7) (2014) E283–E293.
- [3] A.N. Rabie, et al., Dynamic rehabilitation of facial nerve injury: a review of the literature, *J. Reconstr. Microsurg.* 29 (05) (2013) 283–296.
- [4] Ö.A. Özmen, et al., Outcomes of facial nerve grafting in 155 cases: predictive value of history and preoperative function, *Otol. Neurotol.* 32 (8) (2011) 1341–1346.
- [5] L. Li, et al., Efficacy of surgical repair for the functional restoration of injured facial nerve, *BMC Surg.* 21 (1) (2021) 1–10.
- [6] R.A. Agha, et al., The SCARE 2020 guideline: updating consensus Surgical CAse REport (SCARE) guidelines, *Int. J. Surg.* 84 (2020) 226–230.
- [7] M. Sánchez-Ocando, et al., Facial nerve repair: the impact of technical variations on the final outcome, *Eur. Arch. Oto-Rhino-Laryngol.* 276 (12) (2019) 3301–3308.
- [8] S.J. Mathes, V.R. Hentz, *Mathes Plastic Surgery, 1*, Saunders Elsevier, Philadelphia, 2006, p. 235.
- [9] W. House, Facial nerve grading system, *Otolaryngol. Head. Neck Surg.* 93 (1985) 184–193.

- [10] V. Darrouzet, et al., Management of facial paralysis resulting from temporal bone fractures: our experience in 115 cases, *Otolaryngol. Head. Neck Surg.* 125 (1) (2001) 77–84.
- [11] M. Montava, et al., Temporal bone fractures: sequelae and their impact on quality of life, *Am. J. Otolaryngol.* 36 (3) (2015) 364–370.
- [12] A. Gardetto, et al., Direct coaptation of extensive facial nerve defects after removal of the superficial part of the parotid gland: an anatomic study, *Head Neck: J. Sci. Spec. Head Neck* 24 (12) (2002) 1047–1053.
- [13] T.-A.N. Melvin, C.J. Limb, Overview of facial paralysis: current concepts, *Facial Plast. Surg.* 24 (02) (2008) 155–163.
- [14] R.K. Mistry, A.A. Al-Sayed, *Facial Nerve Trauma*, StatPearls [Internet], 2020.

Open Access

This article is published Open Access at [sciencedirect.com](https://www.sciencedirect.com). It is distributed under the [IJSCR Supplemental terms and conditions](#), which permits unrestricted non commercial use, distribution, and reproduction in any medium, provided the original authors and source are credited.