

# Intra-channel stent release technique for fluoroless endoscopic ultrasound-guided lumen-apposing metal stent placement: changing the paradigm



## Authors

Andrea Anderloni<sup>1</sup>, Fabia Attili<sup>2</sup>, Silvia Carrara<sup>1</sup>,  
Domenico Galasso<sup>2,\*</sup>, Milena Di Leo<sup>1</sup>, Guido Costamagna<sup>2</sup>,  
Alessandro Repici<sup>1,3</sup>, Rastislav Kunda<sup>4</sup>, Alberto Larghi<sup>2</sup>

## Institutions

- 1 Department of Gastroenterology, Digestive Endoscopy Unit, Humanitas Research Hospital, Rozzano, Italy
  - 2 Digestive Endoscopy Unit, Catholic University, Rome, Italy
  - 3 Humanitas University, Rozzano, Italy
  - 4 Department of Surgical Gastroenterology, Aarhus University Hospital, Aarhus, Denmark
- \* Current affiliation: Division of Gastroenterology, Department of Internal Medicine, Riviera-Chablais, Monthey, Switzerland

submitted 31.8.2016

accepted after revision 2.11.2016

## Bibliography

DOI <http://dx.doi.org/10.1055/s-0042-122009> |  
Endoscopy International Open 2017; 05: E25–E29  
© Georg Thieme Verlag KG Stuttgart · New York  
ISSN 2364-3722

## Corresponding author

Andrea Anderloni, MD PhD, Digestive Endoscopy Unit, Division of Gastroenterology, Humanitas Research Hospital, Rozzano, MI, Italy  
Fax: +39-02-82247308  
[andrea.anderloni@humanitas.it](mailto:andrea.anderloni@humanitas.it)

## ABSTRACT

**Background** Recently, a novel lumen-apposing fully covered self-expanding metal stent (LA-FCSEMS) mounted on an electrocautery-enhanced delivery system has been developed to perform endoscopic ultrasound (EUS)-guided transluminal drainage. From early experience, however, release of the proximal flange of the stent has mostly been done using endoscopic view guidance to ensure proper positioning.

**Aim** We describe a new technique that we have named the Intra-Channel Stent Release Technique (ICSRT) to perform stent placement under complete EUS control, without the use of either fluoroscopic or endoscopic views.

**Material and methods** Data on all consecutive patients who underwent EUS-guided drainage using the new ICSRT between June 2014 and April 2016 were retrospectively retrieved from two institution databases. All EUS procedures were performed by experienced endoscopists with the patient under conscious or deep sedation. The total procedure and stent deployment time, and adverse events related to stent positioning with the ICSRT were evaluated.

**Results** One hundred consecutive patients (51 women; mean age  $\pm$  SD,  $66 \pm 15.2$  years, range 34–95) underwent EUS-guided transluminal drainage with the Hot AXIOS™ device using the new ICSRT. The procedure was technically successful in all but one patient (1%). The mean total procedural time was 21.9 minutes (range 7–50), while the mean time for stent placement was 3.2 minutes (range 1–15). No major adverse events occurred.

**Discussion** The ICSRT has been used to deploy the newly developed lumen-apposing FCSEMS under complete EUS guidance without fluoroscopic and/or endoscopic assistance. The technique appears to be safe and highly effective and should be learned by all interventional endosonographers in order to be able to perform drainage in all clinical scenarios.

## Introduction

Traditionally, fully covered self-expandable metal stents (FCSEMSs) are placed under fluoroscopic and endoscopic guidance [1]. Similarly, FCSEMSs used in endoscopic ultrasound (EUS)-guided drainage of pancreatic fluid collections and drainage of the gallbladder and bile duct [1–5], are also deployed under fluoroscopic and endoscopic views.

Recently, a novel lumen-apposing FCSEMS (LA-FCSEMSs) mounted on an electrocautery-enhanced delivery system (Hot AXIOS™, Boston Scientific Corp., Marlborough, MA, United States) has been developed and reported to be safe and effective for performing EUS-guided transluminal drainage [6–10]. The stent is clearly visible on EUS view, thus potentially allowing the use of fluoroscopy to be limited during its deployment. In

early experiences, however, release of the proximal flange of the stent has mostly been performed using endoscopic view guidance to ensure proper positioning [7, 8, 10].

We describe a technique that we have named the Intra-Channel Stent Release Technique (ICSRT), which allows us to perform stent placement under complete EUS control, without the use of either fluoroscopic or endoscopic views.

## Material and methods

### Study population

Data from all consecutive patients who underwent EUS-guided drainage of pancreatic fluid collections, gallbladder, and common bile duct (CBD) using the novel LA-FCSEMS in two tertiary referral University Hospitals (Humanitas Research Hospital,

Rozzano, Italy and Catholic University, Rome, Italy) between June 2014 and April 2016, were retrospectively retrieved from each single institution database. Patients unsuitable for LA-FCSEMS positioning were not included. Exclusion criteria for Hot AXIOS™ stent placement were: distance of the target lesion >1 cm from the intestinal wall, presence of contracted gallbladder in the case of gallbladder drainage, and CBD diameter <12 mm in the case of biliary drainage.

Starting in June 2014, all the stents were deployed using the newly developed technique (ICSRT, described below) in both institutions. The protocol to carry out retrospective revision of the cases was approved by each local institutional ethics committee. All patients gave their informed consent before the use of the Hot AXIOS™ device.

### The Hot AXIOS™ delivery system

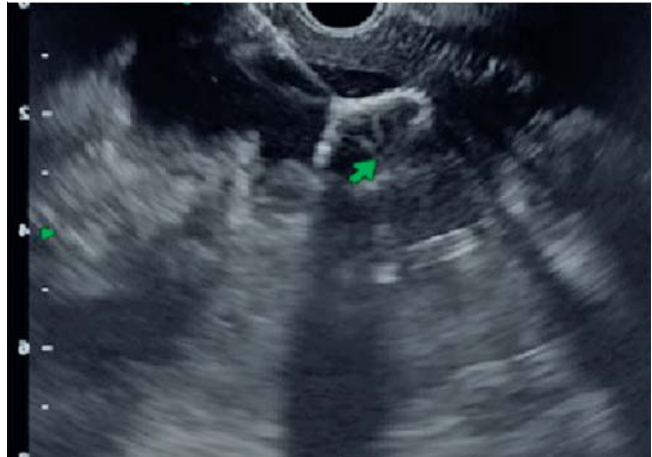The device used in this study (Hot AXIOS™ stent and delivery system, Boston Scientific Inc.) is a through-the-scope LA-FCSEMS mounted on a delivery system with an electrocautery wire at the distal tip. The stent is delivered through a 9- or a 10.8-French catheter (► **Table 1**), which is Luer-locked to the inlet port of the echoendoscope's working channel to allow full control of stent deployment by the endoscopist, without the need for assistance.

### Procedure

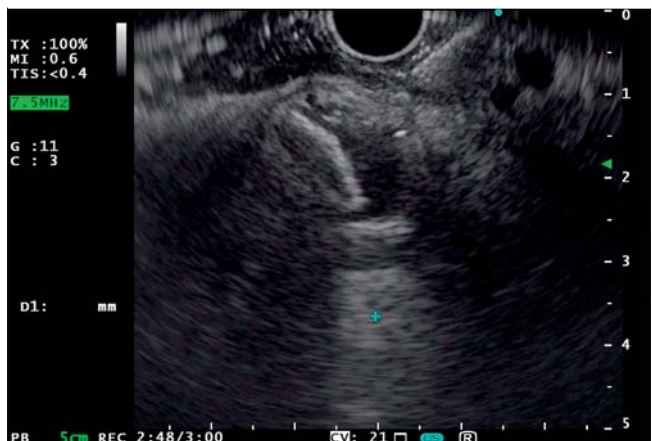All EUS procedures were performed by experienced endoscopists with the patient under conscious or deep sedation, using a conventional therapeutic linear echoendoscope (GF-UC140T, GF-UC180T, Olympus Medical Systems Europe, Hamburg, Germany). Once the target structure (i.e. pancreatic fluid collection, gallbladder, bile duct) was identified, Doppler examination was performed to exclude the presence of interposing vessels. The Hot AXIOS™ catheter was then inserted in the working channel of the echoendoscope and the Luer lock secured to the inlet port of the working channel. After unlocking, the tip of the delivery system was advanced outside the working channel by moving the catheter control hub downwards until contact with the gut wall was demonstrated by EUS. The delivery system was connected to the electrosurgical generator (settings: pure cut mode, 100 Watts, ICC 200, ERBE [AUTOCUT mode, effect 5; ERBE Electrosurgery, Tübingen, Germany]) and penetration of the target structure accomplished by applying pure cut current, while further advancing the catheter control hub downwards. After the catheter was fully inside the target structure, the distal flange of the stent was deployed under EUS by moving the deployment hub upwards. When fully opened, the distal flange becomes visible inside the target structure and appears completely flat like a disc or "Frisbee" (► **Fig. 1** and ► **Fig. 2**). The maneuver for the deployment of the proximal flange started by pulling the distal flange back, toward the gut wall by moving the catheter control hub upwards until the shape of the flange changed from flat to oval. When this change in the shape of the distal flange occurs, the proximal flange can be deployed safely. The deployment was then accomplished by moving the deployment hub fully upwards and this occurred inside the working channel without the

► **Table 1** Characteristics of the different commercially available Hot Axios™ stents and delivery systems.

Stent type	Flange, mm	Lumen, mm	Saddle, mm	Catheter, Fr
06–08	14	6	8	9
08–08	17	8	8	9
10–10	21	10	10	10.8
15–10	24	15	10	10.8

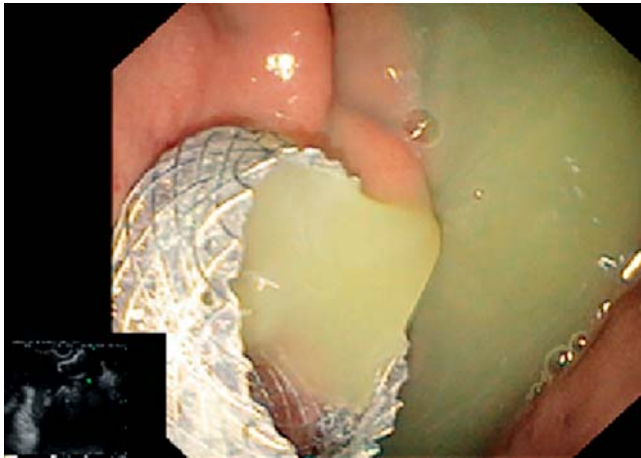


► **Fig. 1** Endoscopic ultrasound image of an intracavity flange of fully covered lumen-apposing self-expandable metal stent deployed into pancreatic pseudocyst.



► **Fig. 2** Endoscopic ultrasound image of intra-common bile duct (CBD) flange of fully covered lumen-apposing self-expandable metal stent.

assistance of endoscopic view. The scope was then gently withdrawn while the catheter control hub was slowly pushed downwards, to allow for the exit of the proximal flange (► **Fig. 3**) from the working channel to complete the release of the stent (► **Video 1**).

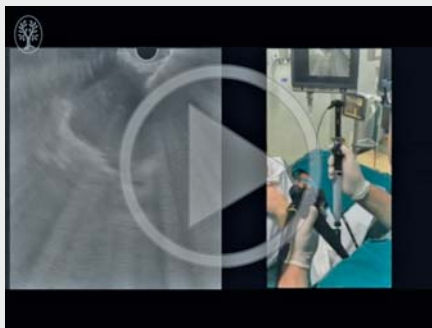


► **Fig. 3** Endoscopic view of an intraluminal flange of fully covered lumen-apposing self-expandable metal stent deployed into pancreatic pseudocyst draining purulent fluid.

### Study parameters

Total procedure and stent deployment time, and any adverse events related to stent positioning with the ICSRT were evaluated. The total procedure time was defined as the time from insertion to exit of the echoendoscope from the mouth of the patient. The stent deployment time was defined as the time from insertion of the Hot AXIOS™ into the working channel of the echoendoscope to the endoscopic confirmation of correct proximal flange deployment into the gastrointestinal lumen.

#### ▶ VIDEO 1



► Video 1: Sequential steps for the new Intra-Channel Stent Release Technique (ICSRT) to deploy the Hot AXIOS™ stent. In early experiences, release of the proximal flange of the stent was mostly performed using endoscopic view guidance to ensure proper positioning. The video shows how the proximal flange of the AXIOS stent is deployed directly inside the working channel of the echoendoscope allowing stent placement to be performed under complete EUS control, without the use of either fluoroscopic or endoscopic views.

## Results

During the study period, 100 consecutive patients (51 women; mean age  $\pm$  SD,  $66 \pm 15.2$  years, range 34–95) underwent EUS-guided transluminal drainage with the Hot AXIOS™ device using the intra-channel stent release technique.

In total, 36 patients underwent drainage of a pancreatic pseudocyst and an additional 22 patients underwent drainage of a walled-off pancreatic necrosis (► **Table 2**); 16 patients deemed to be high surgical risk underwent drainage of the gallbladder due to acute cholecystitis (► **Table 3**); 26 patients with malignant distal biliary obstruction underwent biliary drainage after an unfeasible or failed endoscopic retrograde cholangiopancreatography (ERCP) (► **Table 4**). A 6 mm internal diameter and 8 mm long stent was used in eight patients, an 8 mm  $\times$  8 mm stent in 20 patients, a 10 mm  $\times$  10 mm stent in 33 patients, and a 15 mm  $\times$  10 mm stent in 39 patients. Sixty-four procedures were performed from the stomach (64%), while the remaining 36 were carried out from the duodenum (36%).

The procedure was technically successful in all but one patient (1%). Failure occurred in a patient with acute cholecystitis due to inability to release the proximal flange.

The mean total procedural time was 21.9 minutes (range 7–50 minutes), while the mean time for stent placement was 3.2 minutes (range 1–15 minutes).

In patients with successful stent placement, no major adverse events occurred. Only one self-limited intraprocedural bleeding was observed at the end of stent placement in a case of gallbladder drainage.

## Discussion

We present the clinical results of a novel technique to deploy a recently developed lumen-apposing FCSEMS, which is mounted on an electrocautery-enhanced delivery system. The technique utilizes an intra-channel stent release maneuver, using complete EUS guidance without endoscopic or fluoroscopic imaging. The high technical success rate observed in our large cohort with only one failure demonstrates that this method is safe and highly effective.

Interventional EUS is an expanding field [4,8,11–15] that until now has been performed using accessories borrowed from the ERCP armamentarium. The role of EUS has thus been limited to accessing the target, while the rest of the procedure has been completed utilizing endoscopic and fluoroscopic imaging while continuing to use the echoendoscope. Our study demonstrates that using endosonographic control alone to place and position the LA-FCSEMS can eliminate the need for endoscopic and fluoroscopic imaging. This represents a major breakthrough in interventional EUS with great potential for future applications.

When first developed, deployment of the proximal flange of the Axios stent was recommended to be performed under endoscopic view after visualization of a black marker on an external sheet of the delivering catheter, which is all white [2]. The technique we described for stent deployment under complete EUS guidance without the aid of endoscopic view or

► **Table 2** Characteristics of patients who underwent EUS-guided pancreatic collection drainage with a lumen-apposing metal stent (n = 58).

Sex, n (%)	
Male	32 (55.2%)
Female	26 (44.8%)
Age, mean (SD), years	54.5 (13.7)
Etiology of pancreatic collection, n (%)	
Alcohol pancreatitis	6 (10.3%)
Gallstone pancreatitis	32 (55.2%)
Idiopathic pancreatitis	16 (27.6%)
Postsurgical	3 (5.2%)
Other	1 (1.7%)
Diameter of pancreatic collection, mean (SD), mm	73.5 (58.4)
Type of pancreatic collection, n (%)	
Pseudocyst	36 (62.1%)
WOPN	22 (37.9%)
Successful stent deployment, n (%)	Yes, 58 (100%)
Access route, n (%)	
Transgastric	51 (87.9%)
Transduodenal	7 (12.1%)
Stent diameter, n (%)	
6 mm	1 (1.7%)
8 mm	4 (6.9%)
10 mm	18 (31.1%)
15 mm	35 (60.3%)
WOPN, walled-off pancreatic necrosis.	

fluoroscopy, requires the proximal flange to be released inside the working channel of the scope as explained in the Methods section and illustrated in ► **Video 1**. With the distal flange pulled to the inner wall of the target structure, there will also be a clear view on EUS imaging of the distal flange hugging the wall next to the access site. After releasing the stent completely from the delivery system, it is important to manage the expulsion of the flange from the scope. This is accomplished by gently withdrawing the scope while simultaneously moving the stent catheter downward to push the stent out of the scope.

The advantages of this technique are intuitive. First of all, it allows the operator to maintain the same stable and secure position during the entire deployment, thus decreasing the chance of failure.

Second, the electrocautery-enhanced delivery system allows the stent catheter to be advanced into the desired position in a manner similar to a fine-needle aspiration (FNA) puncture, but with obvious differences. The surface area of the electrode is very small, only 3% of a 10 Fr cystotome, making current densi-

► **Table 3** Characteristics of patients who underwent EUS-guided gall bladder drainage with a lumen-apposing metal stent (n = 16).

Sex, n (%)	Male 5 (31.3%)
Age, mean (SD), years	77.8 (13.2)
Successful stent deployment, n (%)	Yes, 15 (93.8%)
Access route, n (%)	Transgastric 12 (75.0%)
Stent diameter, n (%)	
10 mm	12 (75.0%)
15 mm	4 (25.0%)

► **Table 4** Characteristics of patients who underwent EUS-guided biliary drainage with a lumen-apposing metal stent (n = 26).

Sex, n (%)	Male 12 (83.3%)
Age, mean (SD), years	67.0 (13.1)
Successful stent deployment, n (%)	Yes, 26 (100%)
Access route, n (%)	
Transgastric	1 (3.8%)
Transduodenal	25 (96.2%)
Stent diameter, n (%)	
6 mm	7 (26.9%)
8 mm	16 (61.6%)
10 mm	3 (11.5%)

ty quite high and providing precise, controlled access to the target.

The technique is very reliable as demonstrated by our data. Nevertheless, we do believe that endoscopic and/or fluoroscopic evaluation could be extremely useful in some cases and that is why we suggest (if possible) performing this procedure in a radiological room in order to be ready to switch on the X-ray machine if needed.

In the only failure case that occurred during gallbladder drainage in a patient with acute cholecystitis using a 10 mm long, 10 mm wide stent, post-procedure analysis revealed a malfunction in the scope elevator mechanism that did not allow the stent to fully move to the “open” position.

Being able to deploy under endoscopic, fluoroscopic or EUS guidance should be complementary and may be useful in troubleshooting cases.

According to our results, the intra-channel stent release technique could be proposed as the primary method for deployment of lumen-apposing FCSEMSs, replacing the standard techniques (such as endoscopic or fluoroscopic guidance for distal flange deployment), particularly when an unstable scope position is required. Nevertheless, it is worth noting that the extent of this statement is limited by the observational character of the present study, where the lack of a randomized design does not allow us to generalize the conclusions, but only provides a strong suggestion.

In conclusion, the intra-channel stent release technique, presented and fully explained in this study, has been used to deploy the newly developed lumen-apposing FCSEMS under complete EUS guidance without fluoroscopic and/or endoscopic assistance. The technique appears to be safe and highly effective and should be learned by all interventional endosonographers in order to be able to perform drainage in all clinical scenarios.

## Competing interests

---

None

## References

---

- [1] Varadarajulu S, Banerjee S, Barth B et al. Enteral stents. *Gastrointest Endosc* 2011; 74: 455–464
- [2] Itoi T, Binmoeller KF, Shah J et al. Clinical evaluation of a novel lumen-apposing metal stent for endosonography-guided pancreatic pseudocyst and gallbladder drainage (with videos). *Gastrointest Endosc* 2012; 75: 870–876
- [3] Vazquez-Sequeiros E, Baron TH, Pérez-Miranda M. Spanish Group for FCSEMS in Pancreas Collections. et al. Evaluation of the short- and long-term effectiveness and safety of fully covered self-expandable metal stents for drainage of pancreatic fluid collections: results of a Spanish nationwide registry. *Gastrointest Endosc* 2016; 84: 450–457. e2
- [4] Kunda R, Pérez-Miranda M, Will U et al. EUS-guided choledochoduodenostomy for malignant distal biliary obstruction using a lumen-apposing fully covered metal stent after failed ERCP. *Surg Endosc* 2016; 30: 5002–5008
- [5] Walter D, Teoh AY, Itoi T et al. EUS-guided gall bladder drainage with a lumen-apposing metal stent: a prospective long-term evaluation. *Gut* 2016; 65: 6–8
- [6] Teoh AY, Binmoeller KF, Lau JY. Single-step EUS-guided puncture and delivery of a lumen-apposing stent for gallbladder drainage using a novel cautery-tipped stent delivery system. *Gastrointest Endosc* 2014; 80: 1171
- [7] Rinninella E, Kunda R, Dollhopf M et al. EUS-guided drainage of pancreatic fluid collections using a novel lumen-apposing metal stent on an electrocautery-enhanced delivery system: a large retrospective study (with video). *Gastrointest Endosc* 2015; 82: 1039–1046
- [8] Siddiqui AA, Adler DG, Nieto J et al. EUS-guided drainage of peripancreatic fluid collections and necrosis by using a novel lumen-apposing stent: a large retrospective, multicenter U.S. experience (with videos). *Gastrointest Endosc* 2015; 83: 699–707
- [9] Tharian B, Varadarajulu S, Hawes R. Drainage of obstructed gallbladder with use of lumen-apposing metal stent. *Gastrointest Endosc* 2016; 83: 460–461
- [10] Fabbri C, Luigiano C, Marsico M et al. A rare adverse event resulting from the use of a lumen-apposing metal stent for drainage of a pancreatic fluid collection: “the buried stent”. *Gastrointest Endosc* 2015; 82: 585–587
- [11] Walter D, Will U, Sanchez-Yague A et al. A novel lumen-apposing metal stent for endoscopic ultrasound-guided drainage of pancreatic fluid collections: a prospective cohort study. *Endoscopy* 2015; 47: 63–67
- [12] Chandran S, Efthymiou M, Kaffes A et al. Management of pancreatic collections with a novel endoscopically placed fully covered self-expandable metal stent: a national experience (with videos). *Gastrointest Endosc* 2015; 81: 127–135
- [13] Anderloni A, Buda A, Vieceli F et al. Endoscopic ultrasound-guided transmural stenting for gallbladder drainage in high-risk patients with acute cholecystitis: a systematic review and pooled analysis. *Surg Endosc* 2016; 30: [2016 Apr 8 Epub ahead of print] DOI 10.1007/s00464-016-4894-x
- [14] Khashab MA, Kumbhari V, Grimm IS et al. EUS-guided gastroenterostomy: the first U.S. clinical experience (with video). *Gastrointest Endosc* 2015; 82: 932–938
- [15] Tyberg A, Perez-Miranda M, Sanchez-Ocaña R et al. Endoscopic ultrasound-guided gastrojejunostomy with a lumen-apposing metal stent: a multicenter, international experience. *Endosc Int Open* 2016; 4: E276–E281