

Received: 2016.07.05
Accepted: 2016.09.14
Published: 2016.12.22

Simultaneous Periprosthetic Fractures of the Femur and the Acetabulum After Bipolar Hip Arthroplasty

Authors' Contribution:
Study Design A
Data Collection B
Statistical Analysis C
Data Interpretation D
Manuscript Preparation E
Literature Search F
Funds Collection G

AE 1 **Dionysios-Alexandros Verettas**
B 2 **Pelagia-Paraskevi Chloropoulou**
D 1 **Georgios Drosos**
F 2 **Theodosia Vogiatzaki**
CD 1 **Konstantinos Tilkeridis**
F 1 **Konstantinos Kazakos**

1 Department of Orthopedic Surgery, Democritus University of Thrace, Alexandroupolis, Greece
2 Department of Anesthesiology, Democritus University of Thrace, Alexandroupolis, Greece

Corresponding Author: Dionysios-Alexandros Verettas, e-mail: dveretta@med.duth.gr
Conflict of interest: None declared

Patient: Female, 68
Final Diagnosis: Periprosthetic fractures of the acetabulum and femur after bipolar hip arthroplasty
Symptoms: Inability to walk
Medication: —
Clinical Procedure: Revision cup and internal fixation femur
Specialty: Orthopedics and Traumatology





Objective: Rare co-existence of disease or pathology
Background: Although periprosthetic fractures of the femur are a recognized complication of total hip arthroplasty, periprosthetic fractures of the acetabulum are rare. Simultaneous periprosthetic fractures of both the acetabulum and the femur have not been reported, to our knowledge.

Case Report: We report a simultaneous fracture of the acetabulum and the femur in a 68-year-old female patient who had previously sustained a subcapital fracture of the femur, treated with a bipolar uncemented prosthesis. We discuss the possible mechanism of this combination of fractures.

Conclusions: Simultaneous periprosthetic fractures of the femur and the acetabulum can occur if, in the presence of osteoporotic bone, the metallic femoral head has migrated medially in the acetabulum while the femoral stem is not loose.

MeSH Keywords: Acetabulum • Femur • Internal Fixators • Periprosthetic Fractures

Full-text PDF: <http://www.amjcaserep.com/abstract/index/idArt/900435>

 1587  —  2  10



Background

Since the number of patients requiring total hip arthroplasty (THA) has increased steadily in both younger patients and the more active elderly population, periprosthetic fractures of the femur following THA have a frequency of 0.07% to 18% [1]. There has been also a marked increase in hemiarthroplasty (HA) as treatment for femoral neck fractures, and the frequency of periprosthetic fractures after hip HA ranges between 1.5% and 15% [2,3]. Depending on the type of the periprosthetic fracture, the treatment varies from internal fixation to revision THA or a combination of these two methods [4]. The most commonly used classification is that of Duncan and Masri [5]. On the other hand, periprosthetic fractures of the acetabulum are rare and most often are seen intraoperatively [6]. One of the commonest causes is the presence of osteoporosis that can lead to excessive wear of the bony acetabulum by the metal head and occasionally the combination of softening of the bone in cases of loosening of the implants. Such fractures have been reported after excessive use of bisphosphonate medication or pelvic injuries [7,8] and have been classified in 2 types [9]. Simultaneous periprosthetic fractures of both the acetabulum and femur have not been reported to our knowledge. In this study, we report on a patient who suffered periprosthetic

fractures of both the acetabulum and the femur around a bipolar uncemented hip arthroplasty, a combination of fractures that has not, to our knowledge, been previously reported.

Case Report

A 68-year-old woman presented to the emergency department of our institution with pain and inability to walk on her left leg after having fallen in her garden. The patient had fallen 2.5 years previously and had sustained a subcapital fracture of the left femoral neck. This was treated by a bipolar uncemented hip arthroplasty (Zimmer, Warsaw, Indiana, USA) in a nearby hospital with an uneventful post-operative period, returning to her previous heavy agricultural activities within three months after her fracture. However, she mentioned that she was developing shortening of the operated leg, gradually over the last year, with mild discomfort in the hip region. Despite the fact that her original fracture was due to osteoporosis, the patient was not given any osteoporosis treatment. She was taking no other medication. Before her fall, she had not sustained any loss of consciousness. She mentioned that her fall occurred while trying to get out of her flower bed, possibly because of limping from the shortening of the operated leg.

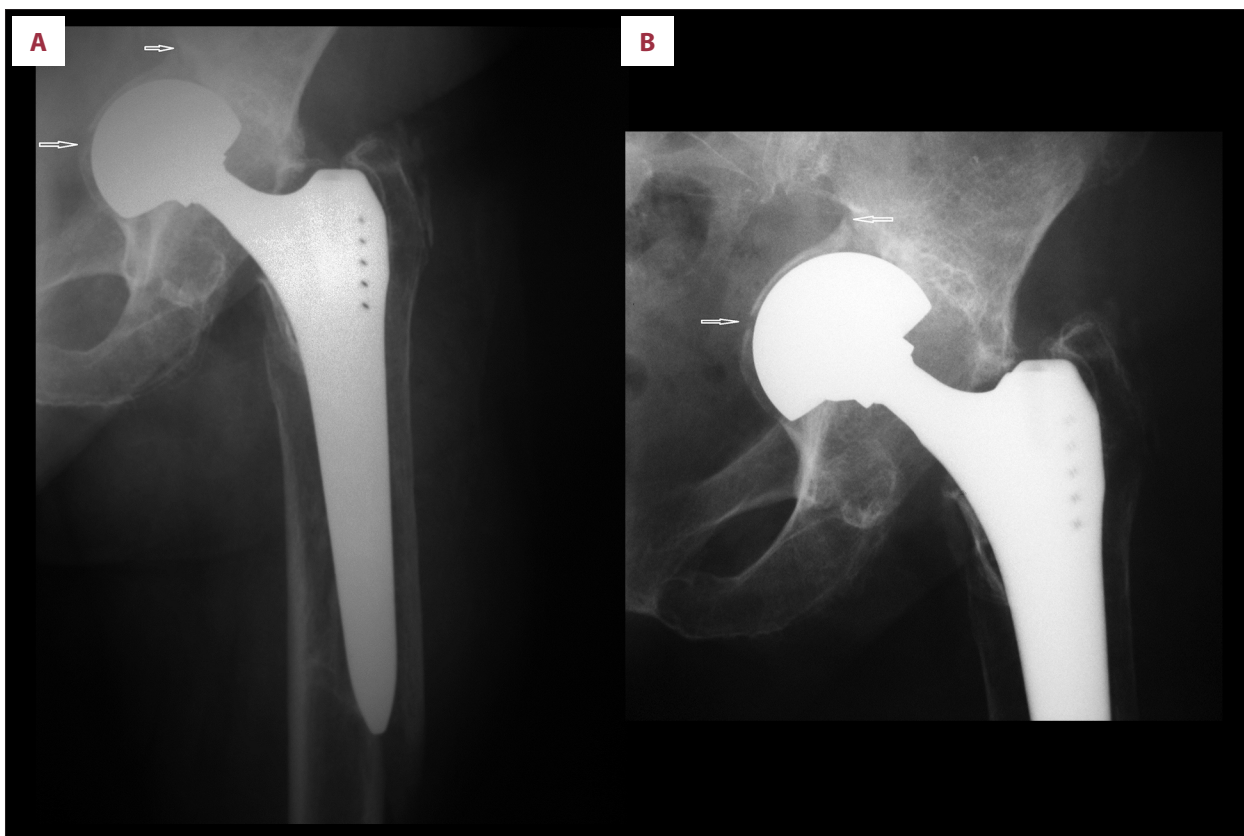


Figure 1. (A) X-Ray showing the presence of a segmental fracture of the acetabulum and the spiral periprosthetic fracture of the upper femur. (B) X-Ray showing in detail the segmental fracture of the acetabulum (arrows).

On clinical examination we found that the left leg was shorter by 2.5 cm, and it was impossible to move it due to severe pain in the groin. The leg was held in mild flexion but there was no rotational deformity. There were no other injuries. X-rays showed a severe amount of wear of the acetabular floor, with protrusion of the metal head of the prosthesis and a segmental fracture of the center of the floor of the acetabulum and the junction of the floor of the acetabulum with the anterior column. In addition, there was a spiral periprosthetic fracture of the femur, arising from the level of the distal third of the femoral stem and extending to 2 cm distal to the tip of the stem. The femoral implant appeared to be stable with no radiographic signs of loosening (Vancouver Type I) (Figure 1A, 1B). All routine preoperative tests were normal. Unfortunately, the patient had not previously attended our outpatient department so there was no information prior to her presentation with the shortening of her leg regarding the range of movement of her hip before her recent fall. However, from the x-rays it could be deduced that the protrusion was not the result of her recent fall but that it was a gradual development, producing, at the same time, the shortening of the leg.

She was operated on the following day. Through a posterolateral approach the joint was exposed after dislocating the bipolar head, with traction and gentle manipulation of the mobile bipolar head, taking care not to damage the acetabular walls because of the protrusion. We elected to use the posterolateral approach because it provides an excellent view of the acetabulum, and at the same time it can be easily and safely extended distally along the femur to address the periprosthetic femoral fracture. The bipolar head was removed with no difficulty. The femoral implant was checked for stability by manual attempts of rotation and telescopic movements. When its stability was verified, the fracture of the femur was addressed. It was reduced and stabilized with a special titanium grip plate and 5 titanium cerclage bands (Plus Endoprothetic, Switzerland). A bone graft was placed around the femur at the level of the fracture. Following graft placement, the fracture of the acetabulum was addressed. During fracture inspection, it was found that there was severe wear and thinning of the acetabulum with a transverse fracture line in the middle of the floor of the acetabulum, while a second fracture was noticed at the proximal part of the floor and the anterior column. After removing the remaining cartilage and carefully roughening the acetabular floor and the perimeter with reamers, the floor of the acetabulum was packed with dried bone chips mixed with bone marrow aspirated percutaneously from the posterior iliac spine. The bone graft was impacted and an uncemented metal cup was gently press-fitted over it, paying particular attention so that the size of the cup was such that it could be positioned at the correct level so that a complete bony coverage was obtained. Finally, the metal cup was additionally stabilized with two screws. The joint was reduced with trials taking particular

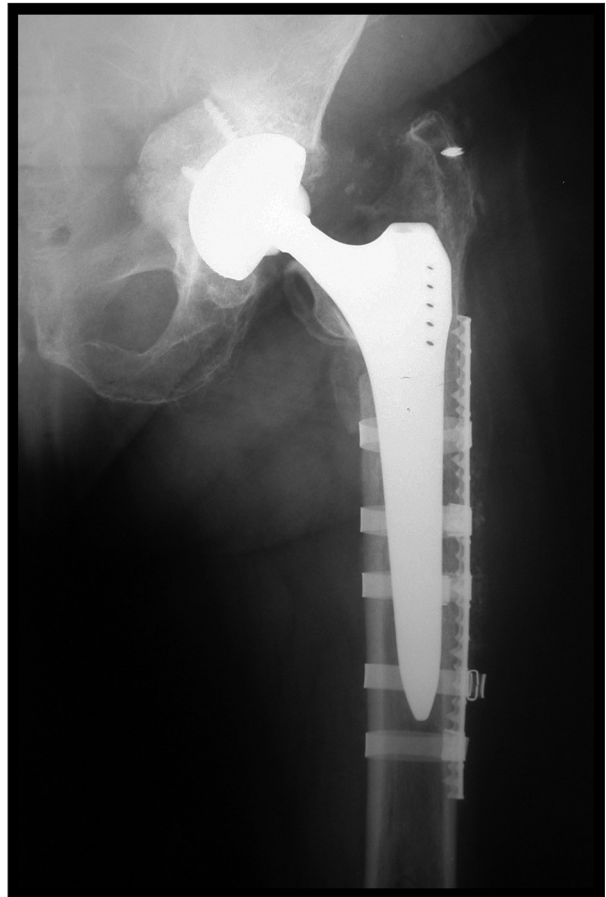

Figure 2. One year postoperative x-ray showing union of the fractures of the acetabulum after revision of the bipolar femoral head and bone grafts, and the method of stabilization of the femoral fracture with elastic plate and titanium bands.

care that the correct length and offset were reconstituted. The stability of the reduction was checked and when satisfactory, the final polyethylene liner has impacted, a new ceramic femoral head was fitted, and the arthroplasty was reduced. The postoperative period was uneventful. The patient remained partially weight bearing for eight weeks and gradually increased her weight bearing to full at 12 weeks postoperatively. She was followed every three months for one year. In her final review, she had no pain and she was walking satisfactorily without any leg length inequality. The final x-ray showed satisfactory incorporation of the graft of the acetabular fracture and union of the fracture of the femur at five years after her surgery (Figure 2).

Discussion

There are many risk factors for the development of periprosthetic fractures of the femur, including the underlying femoral

bone stock and quality, age, previous surgery, excessive stiffness at the hip joint, type and stability of the implant, and the presence of stress risers. Furthermore, periprosthetic acetabular fractures may occur as a result of trauma, chronic migration of a socket or secondary to osteolysis around the socket, and after long-term treatment with bisphosphonates [10].

In our case study, we can only speculate that the cause of the simultaneous femoral and acetabular fracture was due to the severe protrusion. Due to the severe medial migration and protrusion of the bipolar femoral head, the forces of the fall could have been directly applied at the weakened floor of the acetabulum producing a fracture in two sites. The one site was at the point of transition of the strong bone of the anterior column with the thin acetabular floor, while the second site was the thinnest point of the acetabular floor. Because of the inability of the protruding bipolar head to provide adequate joint movement, the rotating moment of the leg during the fall could be transferred through the stable femoral stem onto the osteoporotic femoral bone and thus produce a spiral fracture around the lower third of the femoral stem. Therefore, we believe that these types of fractures can only take place in the situation of a migration and protrusion of the metallic femoral head medially into the thin acetabulum.

Treatment of periprosthetic fractures can be difficult because of the coexisting morbidities and the presence of osteoporosis. In our case, because of the osteoporotic bone of the femur, we selected an “elastic plate” and titanium bands instrumentation

for the stabilization of the femoral fracture in addition to the application of bone grafts locally. Modern treatment of protrusion of the femoral head implies the use of bone graft and cage or tantalum augments. However, our case was not a simple protrusion of the metallic femoral head into the pelvis but a protrusion that had resulted into a segmental fracture of the floor of the acetabulum and its junction with the anterior column. Because of this combination of protrusion and segmental fracture of the acetabulum, we decided to use a more “biologic” method to address the fractures of the acetabulum by filling and impacting the acetabular floor with bone grafts and using an ordinary press-fit metal cup until the cup was near its normal position at the correct level of the acetabulum. The alternatives would be utilizing an anti-protrusion cage and cement. Tantalum augments are not appropriate in these situations.

Conclusions

We believe that, despite its rarity, this combination of periprosthetic fractures of the femur and the acetabulum could be seen only after severe migration and protrusion of a bipolar or monopolar hip prosthesis, since only these types of hip implants can produce considerable wear of the floor of the acetabulum and protrusion when used in healthy, active elderly patients with subcapital fractures of the femur. Care should be taken for early treatment of the migration of the metal head in order to avoid the possibility of the described type of periprosthetic fractures.

References:

1. Sidler-Maier CC, Waddell JP: Incidence and predisposing factors of periprosthetic proximal femoral fractures: A literature review. *Int Orthop*, 2015; 39(9): 1673–82
2. Parker MI, Pryor G, Gurusamy K: Cemented versus uncemented hemiarthroplasty for intracapsular hip fractures: A randomized controlled trial in 400 patients. *J Bone Joint Surg*, 2010; 92-B: 116–22
3. Taylor F, Wright M, Zhu M: Hemiarthroplasty of the Hip with and without Cement: A randomized Clinical Trial. *J Bone Joint Surg*, 2012; 94-A: 577–83
4. Tsiridis E, Haddad FS, Gie GA: The management of periprosthetic femoral fractures around hip replacements. *Injury*, 2003; 34: 95–105
5. Duncan CP, Masri BA: Fractures of the femur after hip replacement. *Instr Course Lect*, 1995; 44: 293–304
6. Haidukewych GJ, Jacofsky DJ, Hansen AD et al: Intraoperative fractures of the acetabulum during primary total hip arthroplasty. *J Bone Joint Surg*, 2006; 88-A: 1952–56
7. Tantavistut S, Tanavalee A, Thanakit V et al: Spontaneous acetabular periprosthetic fracture in a patient continuously having zoledronic acid. *Injury*, 2002; 33(8): 717–22
8. Cha E, Ertl JP, Mullis BH: A case report: Periprosthetic acetabulum fracture with combined pelvic ring injury. *J Orthop Trauma*, 2012; 26(5): e43–45
9. Peterson CA, II, Lewallen DG: Periprosthetic fracture of the acetabulum after total hip arthroplasty. *J Bone Joint Surg*, 1996; 78(8): 1206–13
10. Cook RE, Jenkins PJ, Walmsley PJ et al: Risk factors for periprosthetic fractures of the hip: A survivorship analysis. *Clin Orthop Relat Res*, 2008; 466: 1652–56