

# A Case of Isolated Unilateral Right Renal Vein Thrombosis Associated with Bilateral Pulmonary Embolism Treated with Rivaroxaban a Direct-Acting Oral Anticoagulant

Authors' Contribution:  
Study Design A  
Data Collection B  
Statistical Analysis C  
Data Interpretation D  
Manuscript Preparation E  
Literature Search F  
Funds Collection G

ABCDEF 1,2 **Anthony Matta**  
ABEG 2,3 **Khaled Elenizi**  
ABEG 2 **Rasha AlHarthi**  
ABEG 1,4 **Nicolas Moussallem**  
BE 2 **Noureddine Elhajjaji**  
ABE 2 **Thibault Lhermusier**  
ABE 2 **Didier Carrié**

1 Faculty of Medicine, Holy Spirit University of Kaslik, Kaslik, Lebanon  
2 Department of Cardiology, Rangueil Hospital, Toulouse, France  
3 Department of Internal Medicine College of Medicine, Prince Sattam Bin Abdulaziz University, Alkharj, Saudi Arabia  
4 Department of Cardiovascular, Notre Dame des Secours University Hospital, Jbeil, Lebanon

**Corresponding Author:** Anthony Matta, e-mail: [dr.anthonymatta@hotmail.com](mailto:dr.anthonymatta@hotmail.com)  
**Conflict of interest:** None declared

**Patient:** Female, 44  
**Final Diagnosis:** Renal vein thrombosis  
**Symptoms:** Dyspnea  
**Medication:** —  
**Clinical Procedure:** —  
**Specialty:** Cardiology





**Objective:** Rare disease  
**Background:** Renal vein thrombosis is uncommon and can be associated with nephrotic syndrome. It is associated with high patient morbidity, and it may lead to thromboembolic event.

**Case Report:** A 44-year-old woman presented with shortness of breath, chest pain and tightness, due to bilateral pulmonary embolism originating from right renal vein thrombosis. The diagnosis was made by transthoracic echocardiography and enhanced computed tomography (CT) scan of chest, abdomen, and pelvis. No underlying diseases were found. She was treated with heparin infusion therapy and rivaroxaban with good clinical outcome.

**Conclusions:** A rare case is presented of isolated unilateral right renal vein thrombosis diagnosed following bilateral pulmonary embolism in a previously healthy 44-year-old woman, which was successfully treated with the DOAC, rivaroxaban.

**MeSH Keywords:** Pulmonary Embolism • Renal Veins • Thromboembolism

**Full-text PDF:** <https://www.amjcaserep.com/abstract/index/idArt/916638>

 808  —  2  9



## Background

Renal vein thrombosis is a rare clinical condition, with an etiology that varies according to patient age. In the elderly, renal vein thrombosis occurs in patients following trauma, infection, or malignancy. In young adults and children, renal vein thrombosis can be associated with nephrotic syndrome, especially membranous glomerulonephritis [1,2]. Usually, most cases of renal vein thrombosis are bilateral, but in unilateral cases of renal vein thrombosis, the left renal vein is more frequently involved than the right renal vein [1,2].

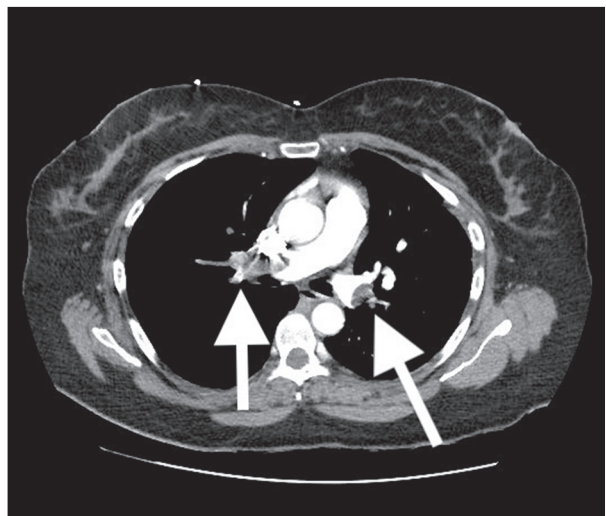
This report is of a case of unilateral renal vein thrombosis affecting the right renal vein complicated by bilateral pulmonary embolism in a previously healthy adult woman without comorbidities.

## Case Report

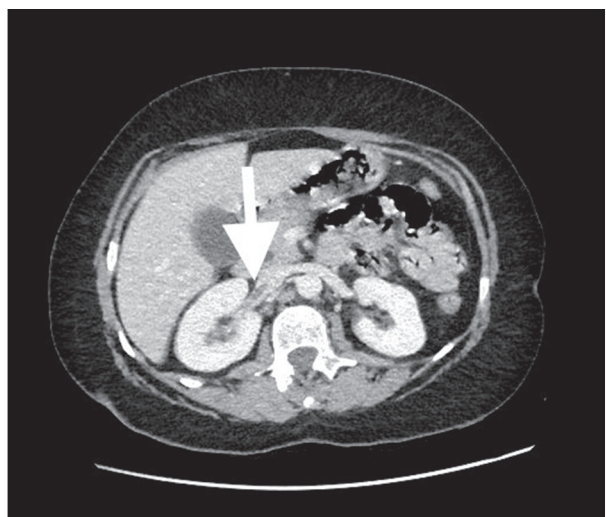
A 44-year-old woman who was previously healthy presented to the emergency room with dyspnea of recent onset associated with compressive chest pain. Her past surgical history included two births by cesarean section. In the emergency room, her blood pressure was 170/110 mmHg, her temperature was 37°C, her heart rate was 110 bpm, and her oxygen saturation was 85% while breathing ambient air.

Physical examination was unremarkable for cardiopulmonary findings, and she had a regular pulse, and normal bilateral air entry on chest auscultation. Laboratory studies showed a white blood cell (WBC) count of  $15 \times 10^9/L$ , hemoglobin of 13.3 g/dl, a creatinine of 0.78 mg/dl, C-reactive protein (CRP) of 2, a troponin of 7 ng/l, and a positive D-dimer test. The electrocardiogram (ECG) showed T-wave inversion in the anteroseptal ECG leads and sinus tachycardia. Chest X-ray showed no acute cardiopulmonary abnormalities. Transthoracic echocardiography performed in the emergency room showed a dilated right ventricle with pulmonary arterial hypertension of 45 mmHg, a normal left ventricular ejection fraction of 65%, with no wall motion abnormalities. Pulmonary computed tomography (CT) angiography showed bilateral proximal pulmonary embolism with an abnormal renal cortex (Figure 1).

Investigations of an underlying cause of bilateral pulmonary embolism in a previously healthy woman included tests for acquired or inherited coagulopathy, and mammography and bilateral lower extremity duplex ultrasonography, which were all normal. However, enhanced CT of the abdomen and pelvis showed a thrombus in the right renal vein extending into the lumen of the inferior vena cava (Figure 2).



**Figure 1.** Pulmonary computed tomography (CT) angiography shows bilateral pulmonary embolism.



**Figure 2.** Contrast-enhanced computed tomography (CT) of the abdomen and pelvis shows thrombus in the right renal vein with extension into the lumen of inferior vena cava.

The patient was diagnosed with renal vein thrombosis with bilateral pulmonary embolism. She was treated successfully by oxygen support and intravenous heparin infusion followed by treatment for one year with rivaroxaban, a direct-acting oral anti-coagulant (DOAC). At three-month follow-up after discharge from hospital, her oxygen saturation was 97% in room air, and she was performing her normal daily activities without limitations.

## Discussion

The management of renal vein thrombosis has progressed from invasive strategies such as nephrectomy or thrombectomy

to medical treatment. The treatment of renal vein thrombosis depends on the underlying etiology. The majority of cases of renal vein thrombosis reported in the literature were associated with nephrotic syndrome. Atorvastatin, angiotensin-converting enzyme (ACE) inhibitors or angiotensin II receptor blockers in cases of nephrotic syndrome complicated with renal vein thrombosis may slow the progression of kidney injury and reduce proteinuria [3,4]. Also, steroids, cyclosporine, and immunosuppressive therapies have benefits in the treatment of membranous glomerulonephritis, and surgery is used only for cases of renal vein thrombosis associated with early-stage renal cell carcinoma [3,4].

There are clinical guidelines for thrombolysis in renal vein thrombosis, but there are guidelines for the management of pulmonary thromboembolism and pulmonary hypertension. For cases of renal vein thrombosis with recurrent thromboembolic events despite medical therapy, an inferior vena cava filter placed below or above the renal veins may be considered [3].

Some studies recommend the use of warfarin for prevention of thromboembolism in patients with renal vein thrombosis [7]. A recent study established the efficacy of using the direct-acting oral anticoagulant (DOAC), apixaban, as a prophylactic treatment for thromboembolic events in cases of nephrotic syndrome [5]. Previous studies have shown that anticoagulation either by warfarin or novel oral anticoagulants (NOACs) should be initiated when renal vein thrombosis is complicated

with pulmonary embolism or other thromboembolic events. Minimum duration of treatment for one year is recommended or until resolution of nephrotic syndrome [3–9].

In this case report, the unusual characteristics of renal vein thrombosis were found, and the case was unilateral, affecting the right renal vein, complicated by bilateral pulmonary embolism. This patient did not have nephrotic syndrome. Given the lack of clinical management guidelines, and taking into consideration previously published studies, rivaroxaban was used as it was previously described in patients with nephrotic syndrome and coagulopathies [8,9]. In this case, heparin infusion followed by treatment with rivaroxaban for one year was chosen, with a good outcome at three-month after discharge from hospital.

## Conclusions

In this case, unilateral right renal vein thrombosis in a previously healthy 44-year-old woman was diagnosed after bilateral pulmonary embolism and managed by intravenous heparin infusion and direct oral anticoagulation (DOAC) with rivaroxaban with good clinical outcome.

## Conflict of interest

None.

## References:

1. Asghar M, Ahmed K, Shah SS et al: Renal vein thrombosis. *Eur J Vasc Endovasc Surg*, 2007; 34: 217–23
2. Kerlin BA, Ayoob R, Smoyer WR: Epidemiology and pathophysiology of nephrotic syndrome associated thromboembolic disease. *Clin J Am Soc Nephrol*, 2012; 7: 513–20
3. Singhal R, Brimble KS: Thromboembolic complications in the nephrotic syndrome: Pathophysiology and clinical management. *Thromb Res*, 2006; 118: 397–407
4. Laskowski I: Renal vein thrombosis. *Medscape* 2018. <https://emedicine.medscape.com/article/460752-overview>
5. Sexton D, De Freitas D, Little MA et al: Direct-acting oral anticoagulants as prophylaxis against thromboembolism in the nephrotic syndrome. *Kidney Int Rep*, 2018; 3(4): 784–93
6. Han THC, Thet Z: Warfarin vs. new oral anticoagulant in primary adult nephrotic syndrome associated venous thromboembolism. *Nephrology*, 2017; 22: 64
7. Kamran HEF, Khalil Q, Bates J, Morse M: Venous and arterial thromboses in nephrotic syndrome: Where only warfarin has walked. *J Gen Int Med*, 2016; 31
8. Zhang L, Zhang H, Zhang J et al: Rivaroxaban for the treatment of venous thromboembolism in patients with nephrotic syndrome and low AT-III: A pilot study. *Exp Ther Med*, 2018; 15: 739–44
9. Dupree LH, Reddy P: Use of rivaroxaban in a patient with history of nephrotic syndrome and hypercoagulability. *Ann Pharmacother*, 2014; 48: 1655–58