


MRI demyelination pattern and clinical course in a child with cerebral X-linked adrenoleukodystrophy (X-ALD)

Acta Radiologica Open
4(4) 1–3
© The Foundation Acta Radiologica
2015
Reprints and permissions:
sagepub.co.uk/journalsPermissions.nav
DOI: 10.1177/2047981615573655
arr.sagepub.com


Johannes Nowak¹, Ulrike Löbel², Matthias Wölfl³,
Paul-Gerhardt Schlegel³ and Monika Warmuth-Metz¹

Abstract

The clinical spectrum in boys with X-linked adrenoleukodystrophy (X-ALD) ranges from isolated adrenocortical insufficiency and slowly progressive myelopathy to devastating cerebral demyelination. In the individual case, the disease course still remains unpredictable. Research findings suggest an important role of brain magnetic resonance imaging (MRI) lesion patterns as prognostic markers for X-ALD. Hence, familiarity with imaging features of childhood X-ALD in combination with clinical manifestation is required in order to stratify affected patients for therapy. We report on MRI findings and clinical course of cerebral X-ALD in a young boy with a rare subtype of white matter demyelination.

Keywords

X-linked adrenoleukodystrophy (X-ALD), magnetic resonance imaging (MRI), Loes score, demyelination, hematopoietic stem cell transplantation

Revised: 7th October 2014; Accepted: 28 January 2015

Introduction

X-linked adrenoleukodystrophy (X-ALD) is a progressive genetic disorder caused by a mutation in the *ABCD1* gene, encoding for a peroxisomal membrane protein that is a member of the ATP-binding cassette superfamily. Defective peroxisomal β -oxidation in affected patients subsequently leads to accumulation of very long chain fatty acids (VLCFA) in all tissues, primarily in the adrenal cortex, nervous system, and testes (1). It is estimated that one in 21,000 boys/men and one in 14,000 girls/women (as heterozygous carriers) are affected (2). There is no evidence that the frequency varies with geographic regions or ethnic background. X-ALD can be reliably diagnosed by abnormally high VLCFA levels in plasma, and by genetic testing (3). Phenotypes include: (i) the rapidly progressive childhood, adolescent, and adult cerebral forms; (ii) slowly progressive paraparesis (axonopathy) in adults (= adrenomyeloneuropathy); and (iii) Addison's disease without neurologic manifestation (2). However, a series of intermediate subgroups can be found within these major clinical categories, with

variable degree and location of cerebral involvement. Furthermore, the various phenotypes do not correlate with the nature of the gene mutation or the severity of the biochemical abnormality. In order to predict the clinical outcome and to evaluate and select therapeutic interventions, the role of brain magnetic resonance imaging (MRI) lesion patterns as prognostic markers has been recently explored (1). We describe and discuss the clinical and neuroimaging presentation of a young child with X-ALD.

¹Departments of Radiology and Neuroradiology, University Hospital of Würzburg, Würzburg, Germany

²Department of Neuroradiology, University Medical Center Hamburg-Eppendorf, Hamburg, Germany

³Department of Pediatrics, University Hospital of Würzburg, Würzburg, Germany

Corresponding author:

Johannes Nowak, Departments of Radiology and Neuroradiology, University Hospital of Würzburg, 97080 Würzburg, Germany.
Email: Nowak_j1@ukw.de



Case report

A 6-year-old boy presented with hyperactive behavior, cognitive decline, and adrenal insufficiency over the last 6 months. Genetically confirmed X-ALD runs in the mother's family, with three affected uncles (two with adrenal insufficiency, one with severe cerebral disease). Plasma levels of VLCFA were elevated at presentation (C26:0/C22:0 = 0.74; norm, 0.1–0.55). Genetic testing confirmed a mutation of the *ABCD1* gene. MRI of the brain showed symmetrical signal alterations of the frontal white matter (WM) with involvement of the genu of corpus callosum, internal capsules, brainstem, and long fiber tracts, indicating severe demyelination (Loes score = 7, Fig. 1) (1). The rapid progression and dismal prognosis in our patient warranted rapid hematopoietic stem cell transplantation as the only possibly curative treatment option. As no HLA-matched donor was readily available, the parents opted for haploidentical stem cell transplantation from the unaffected father. The course of transplantation was complicated with prolonged aplasia. In addition, the boy experienced severe neurological deterioration with an inability to speak and walk. After 28 days in aplasia, primary non-engraftment had to be stated. While preparing other family members for emergency stem cell donations, the patient unfortunately died of bacterial sepsis.

Discussion

Cranial MRI in our case shows a rare variant of X-ALD with anterior predominance (10–15%), whereas most of the patients with the childhood cerebral phenotype have a posterior-predominant pattern

(80%) of WM demyelination. Five distinct patterns with cerebral involvement have been identified, depending on patient age, initial MRI Severity Scale Score (Loes score), and anatomic location of the lesion. It has been shown that cases with anterior or posterior predominance of demyelination at a young age are associated with rapid disease progression, when contrast enhancement was also present (1). The MRI Score progression also strongly correlates with survival (4). In our patient with anterior predominance, the process is typically initiated in the frontal regions with concomitant involvement of the rostrum and genu of corpus callosum (2). In active disease, three zones of demyelination can be found on MR images: a necrotic “burned out” core, an intermediate zone of active demyelination and inflammation with possible contrast enhancement (Fig. 1b), and a peripheral zone that shows demyelination without inflammation (5,6). The corticospinal tracts, fornix, commissural fibers, and the visual and auditory pathways can also become involved. The Loes score of 7 in our patient is indicative of severe cerebral involvement of X-ALD in an active state of the disease, as reflected by gadolinium enhancement. Beside conventional MRI, evolving techniques such as proton magnetic resonance spectroscopy (MRS), diffusion tensor imaging (DTI), and magnetization transfer MRI are under investigation in X-ALD and may provide valuable additional information (7,8).

Therapeutic options in X-ALD currently include supportive care and symptomatic treatment as well as hormone replacement therapy (HRT) (to address the adrenocortical insufficiency). However, HRT benefits endocrine status, but does not seem to alter neurologic

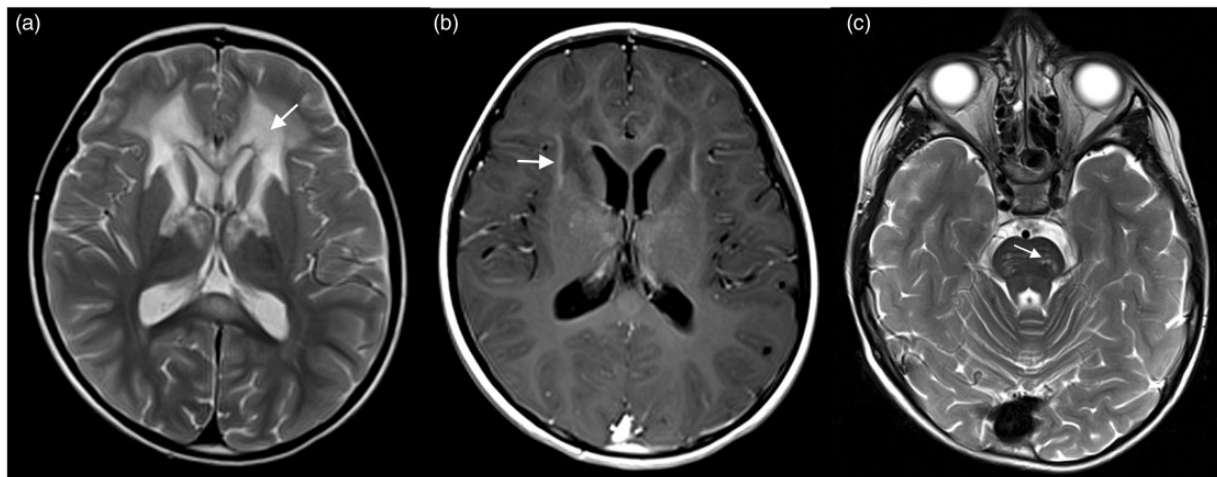


Fig. 1. T2-weighted (a, c) and T1-weighted (b) MR images showing the “cerebral inflammatory phenotype” of X-ALD with severe, symmetric demyelination of the frontal WM (a, arrow). Diverging signal intensities in (a) and contrast enhancement in (b, arrow) indicate different activity of demyelination. Symmetric involvement of the long fiber tracts is common in X-ALD (c, arrow). 1.5 T Siemens Aera (Siemens Medical Systems, Erlangen, Germany).

status and outcome significantly (9). Dietary therapy with Lorenzo's oil (LO) has been demonstrated to somewhat alter the lipid acid profile, but can only be considered as palliation. LO is a 4:1 mixture of glyceryl trioleate and glyceryl trierucate and has been shown to lower or normalize levels of VLCFAs in the plasma after oral administration in combination with moderate reduction of fat in the diet (9). Hematopoietic stem cell transplantation (HSCT) remains the only curative treatment option. The mechanisms underlying the benefit of HSCT have not yet been elucidated. Similar to dietary therapy with LO, outcome after HSCT seems to be favorable in patients in whom therapy was initiated at early stages of the disease, with no or minor symptoms due to cerebral WM demyelination (9,10). However, since not every genetically affected patient develops neurological symptoms, HSCT is only indicated for those showing early signs of neurological involvement (including radiological findings only). Our patient already had significant symptoms when presenting for HSCT, but given the lack of other effective treatment options, HSCT was still considered as a treatment option (9). Hence, affected boys without neurological symptoms should be monitored closely for radiological signs of cerebral X-ALD. New therapeutic approaches (phenylbutyrate, lovastatin, anti-oxidants, gene replacement therapy) are still under investigation (2,9).

In conclusion, clinical manifestations and cerebral involvement of patients with X-ALD range widely. Neuroimaging studies suggest that MRI patterns of demyelination in cerebral X-ALD correlate with disease progression and outcome. This is important in order to select for therapeutic interventions such as HRT and HSCT, which seem to be more effective at early stages of the disease, before cerebral demyelination becomes evident.

Conflict of interest

None declared.

References

1. Loes DJ, Fatemi A, Melhem ER, et al. Analysis of MRI patterns aids prediction of progression in X-linked adrenoleukodystrophy. *Neurology* 2003;61:369–374.
2. Moser HW, Mahmood A, Raymond GV. X-linked adrenoleukodystrophy. *Nat Clin Pract Neurol* 2007;3:140–151.
3. Moser AB, Kreiter N, Bezman L, et al. Plasma very long chain fatty acids in 3,000 peroxisome disease patients and 29,000 controls. *Ann Neurol* 1999;45:100–110.
4. Moser HW, Loes DJ, Melhem ER, et al. X-Linked adrenoleukodystrophy: overview and prognosis as a function of age and brain magnetic resonance imaging abnormality. A study involving 372 patients. *Neuropediatrics* 2000;31:227–239.
5. Kim JH, Kim HJ. Childhood X-linked adrenoleukodystrophy: clinical-pathologic overview and MR imaging manifestations at initial evaluation and follow-up. *Radiographics* 2005;25:619–631.
6. Osborn AG. *Osborn's brain: imaging, pathology, and anatomy*. 1st ed. Salt Lake City, UT: Amirsys, 2013, p.866.
7. Eichler FS, Itoh R, Barker PB, et al. Proton MR spectroscopic and diffusion tensor brain MR imaging in X-linked adrenoleukodystrophy: initial experience. *Radiology* 2002;225:245–252.
8. Fatemi A, Smith SA, Dubey P, et al. Magnetization transfer MRI demonstrates spinal cord abnormalities in adrenomyeloneuropathy. *Neurology* 2005;64:1739–1745.
9. Engelen M, Kemp S, de Visser M, et al. X-linked adrenoleukodystrophy (X-ALD): clinical presentation and guidelines for diagnosis, follow-up and management. *Orphanet J Rare Dis* 2012;7:51.
10. Loes DJ, Hite S, Moser H, et al. Adrenoleukodystrophy: a scoring method for brain MR observations. *Am J Neuroradiol* 1994;15:1761–1766.