



# The Curious Case of Pseudo-Wellens' Syndrome and Myocardial Bridging

Journal of Investigative Medicine High  
Impact Case Reports  
Volume 10: 1–4  
© 2022 American Federation for  
Medical Research  
DOI: 10.1177/23247096211073255  
journals.sagepub.com/home/hic  


David Milne, MBBS<sup>1</sup>, Divya Ramadhin, MBBS<sup>2</sup>,  
Rajeev Seecheran, MBBS, MHA<sup>3</sup>, Valmiki Seecheran, MBBS, MSc<sup>4</sup>,  
Ronald Henry, MBBS, FACC, FESC, FSCAI<sup>2</sup>, and  
Naveen Anand Seecheran, MBBS (MD), MSc, FACP, FRCP(E), FACC, FESC, FSCAI<sup>5</sup> 

## Abstract

Wellens' syndrome is an electrocardiographic harbinger of a critical left anterior descending (LAD) coronary artery stenosis in acute coronary syndromes (ACS), whereas pseudo-Wellens' syndrome typically has angiographically normal coronary arteries. Myocardial bridging (MB) occurs when an epicardial coronary artery segment takes a tunneled intramuscular course. We describe a rare case of MB-induced pseudo-Wellens' syndrome in a young patient presenting with unstable angina (USA).

## Keywords

Pseudo-Wellens' syndrome, Wellens' syndrome, myocardial bridging, myocardial bridge

## Introduction

Wellens' syndrome is an electrocardiographic pattern reflective of a precarious left anterior descending (LAD) stenosis in patients with acute coronary syndromes (ACS). It was initially described in the early 80s in a cohort of patients with unstable angina (USA).<sup>1</sup> There are 2 subtypes that often evolve to symmetrical, deep T-wave inversions in the precordial leads.<sup>2</sup> A clinical entity in which a Wellens' electrocardiographic pattern is apparent with angiographically normal coronary arteries has been defined as pseudo-Wellens' syndrome.<sup>3</sup>

Myocardial bridging (MB) occurs when a coronary artery segment takes a tunneled intramuscular course and is tunneled under an overlying muscular bridge.<sup>4</sup> This results in systolic myocardial compression of the tunneled section, often affecting the LAD, however, remaining clinically silent.<sup>5</sup>

To the authors' knowledge, there is a paucity of literature describing this phenomenon.<sup>6–8</sup> We report a rare case of MB-induced pseudo-Wellens' syndrome in a young patient presenting with USA.

## Case Report

A 32-year-old Caucasian male surgical resident with a medical history of gastroesophageal reflux disease presented to the emergency room with typical angina during an exhaustive on-call session. He had no pertinent social, travel, or

family history and was previously prescribed proton pump inhibitor therapy. His vital signs indicated systolic blood pressures of 142 mm Hg, a heart rate of 112 beats/min, a respiratory rate of 18 breaths/min, and oxygen saturation of 98% on ambient air. His physical examination was normal.

Severe acute respiratory syndrome coronavirus 2 (SARS-CoV-2) IgM and IgG antibody serologies were negative upon arrival at the emergency department. A 12-lead electrocardiogram (ECG) revealed sinus rhythm with anterior T-wave inversions in V<sub>2</sub> to V<sub>3</sub> (Figure 1A). A portable chest radiograph indicated no acute cardiopulmonary disease. Diagnostic investigations included a d-dimer 141 ng/dL (normal ≤ 500 ng/mL), NT-pro-brain natriuretic peptide 185 pg/mL (normal ≤ 300 pg/mL), CK-MB 12 U/L

<sup>1</sup>North West Regional Health Authority, Mt. Hope, Trinidad and Tobago

<sup>2</sup>Advanced Cardiovascular Institute, Port of Spain, Trinidad and Tobago

<sup>3</sup>University of Kansas Medical Center, Wichita, USA

<sup>4</sup>North Central Regional Health Authority, Mt. Hope, Trinidad and Tobago

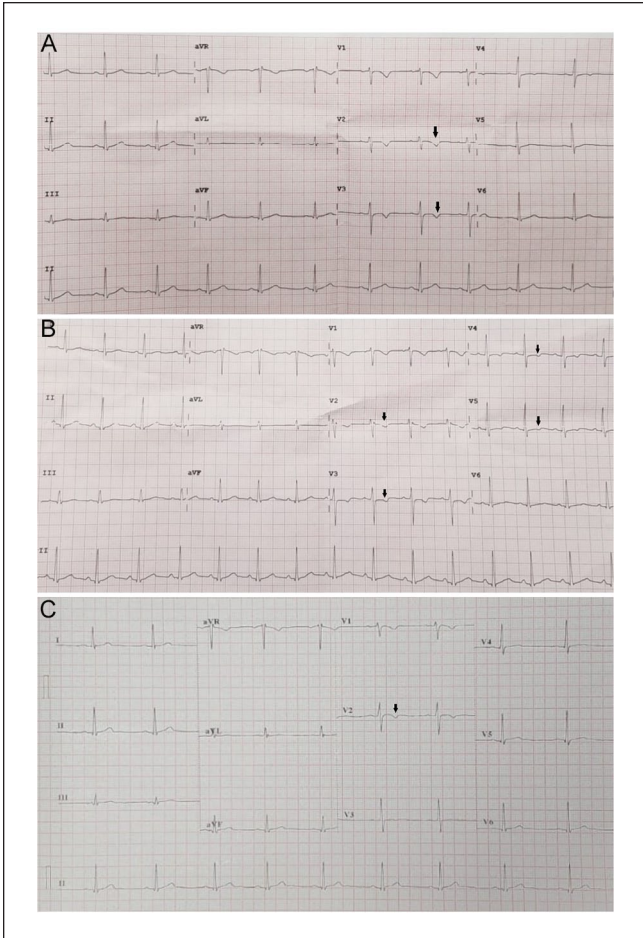
<sup>5</sup>The University of the West Indies, St. Augustine, Trinidad and Tobago

Received November 30, 2021. Revised December 15, 2021. Accepted December 21, 2021.

## Corresponding Author:

Naveen Anand Seecheran, MBBS (MD), MSc, FACP, FRCP(E), FACC, FESC, FSCAI, Faculty of Medical Sciences, Department of Clinical Medical Sciences, The University of the West Indies, 2nd Floor, Building #67, Eric Williams Medical Sciences Complex, Mt. Hope, Trinidad and Tobago.  
Emails: nseecheran@gmail.com; naveen.seecheran@sta.uwi.edu





**Figure 1.** The patient's serial electrocardiograms (ECGs): (A) the patient's admission ECG, revealing the Wellens' type A pattern in  $V_2$ - $V_3$  (black arrows), (B) the patient's ECG prior to coronary angiography revealed the diffuse, dynamic T-wave inversions in  $V_2$ - $V_5$  (black arrows), and (C) the patient's discharge ECG revealed near-normalization with an isolated T-wave inversion in  $V_2$ , which coincided with subsided symptoms (black arrow).

(normal < 20 U/L), and troponin I 0.03 ng/mL (normal < 0.15 ng/mL). A bedside echocardiogram (2D-TTE) demonstrated a preserved left ventricular function without any overt regional wall motion abnormality, including apical ballooning. The patient was subsequently admitted to the cardiac care unit and initiated on comprehensive, guideline-directed, medical therapy for the tentative diagnosis of an ACS as stress-related cardiomyopathy (SRC) was excluded. His cardiovascular regimen included aspirin, ticagrelor, heparin, high-intensity atorvastatin, ramipril, carvedilol, and amlodipine.

The patient's angina intensified, and there were dynamic T-wave inversions in  $V_2$  to  $V_5$  (Figure 1B). He subsequently underwent distal transradial coronary angiography (dTRA) the ensuing day, which revealed mild to moderate systolic compression of a proximal LAD segment (10 mm) consistent

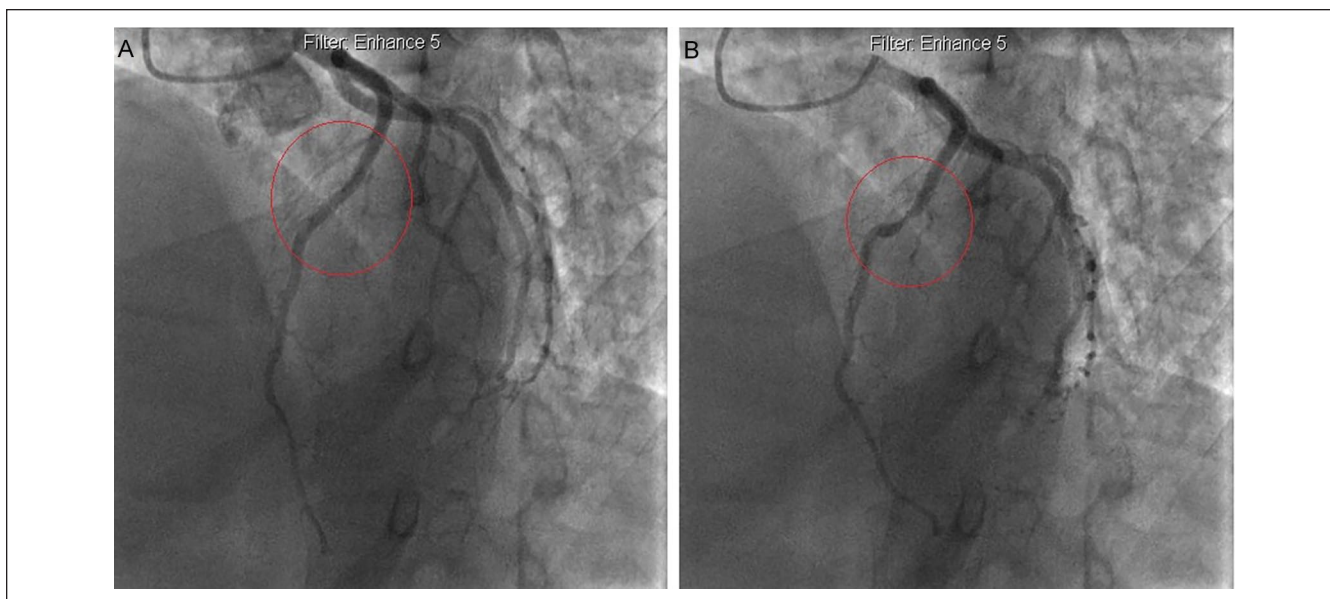
with MB (Figures 2 and 3). The patient received extensive counseling with respect to his diagnosis and opted for noninvasive medical management. His symptoms eventually subsided during his 48-h hospitalization with near-normalization of his ECG, and he was discharged with the aforementioned antianginal and neurohormonal therapies (Figure 1C). On scheduled follow-up monthly appointments, he remained asymptomatic during his work schedule.

## Discussion

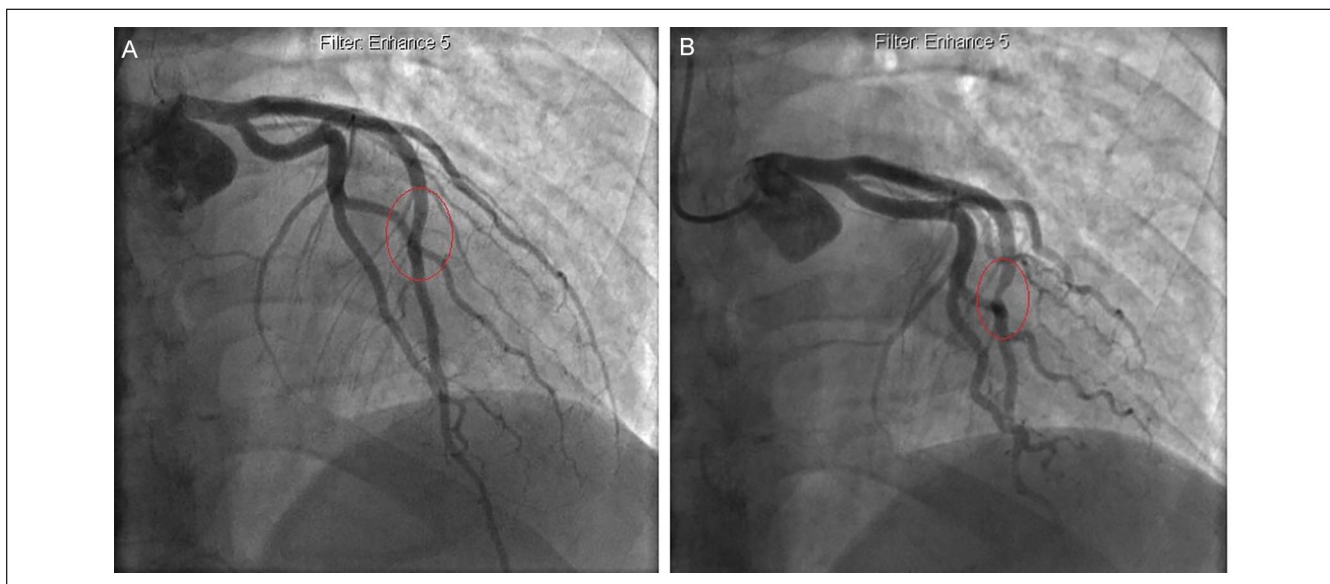
Many factors may precipitate Wellens' syndrome, including coronary artery disease, coronary vasospasm, hypoxia, and increased myocardial demand.<sup>9</sup> It is classified as type A or type B; the former is characterized by biphasic T-wave in leads  $V_2$  and  $V_3$ , and the latter by deep T-wave inversion in the same leads.<sup>1,10</sup> Our patient likely exhibited type A, and other differential diagnoses for precordial T-wave inversions such as cerebrovascular events, hypertrophic cardiomyopathy (HCM), and pulmonary embolism were definitively ruled out.<sup>9</sup> As aforementioned, pseudo-Wellens' syndrome displays a similar electrocardiographic pattern, albeit without the critical LAD lesion.<sup>3</sup> Although Wellens' syndrome alluded to an imminent total or near-total occlusion of the LAD with sequelae of an extensive anterior myocardial infarction, a similar clinical trajectory has not yet been demonstrated for pseudo-Wellens' syndrome.<sup>11</sup>

The prevalence of MB is variable, based on the diagnostic modality employed. Invasive coronary angiography detects approximately 0.5% to 16% (excluding provocative testing), whereas cardiac computed tomography angiography prevalence approaches 25%.<sup>12,13</sup> Similar to the distinction between Wellens' syndrome and pseudo-Wellens' syndrome, with the major caveat being the latter displaying angiographically normal coronary arteries with impaired functional physiology, disparities in MB prevalence underscores the importance of delineating anatomical as opposed to functional testing. In specific high-risk subgroups, such as patients with HCM, the reported prevalence is circa 40%.<sup>14</sup> Advanced diagnostic tests include intravascular ultrasound (IVUS) and provocative fractional flow reserve (FFR), including adenosine, dobutamine, and nitroglycerin.<sup>15,16</sup>

Myocardial bridging is associated with atherosclerosis proximal to the extrinsically compressed segment due to stress-induced endothelial injury. This is also coupled with decreased diastolic filling time, vessel diameter, and coronary flow reserve exacerbated during tachycardia or stressful events.<sup>17</sup> Presentations include the entire cardiovascular spectrum, including ACS, SRC, lethal arrhythmias, including sudden cardiac death, although most are clinically benign.<sup>5</sup> Patients may develop left ventricular hypertrophy (LVH), diastolic, endothelial, and microvascular dysfunction.<sup>5</sup> Despite a paucity of data demonstrating the clinical efficacy of pharmacotherapy, this strategy is often considered first-line. Calcium channel blockers



**Figure 2.** Straight cranial projection coronary angiography: (A) the angiographically normal left anterior descending artery segment (red circle) and (B) mild to moderate bridging of the left anterior descending artery segment during systole (red circle).



**Figure 3.** Right anterior oblique (RAO) coronary angiography: (A) the angiographically normal left anterior descending artery segment (red circle) and (B) mild to moderate bridging of the left anterior descending artery segment during systole (red circle).

attenuate vasospasm, whereas beta-blockers hemodynamically improve parameters such as heart rate and diastolic filling time. Nitrates are contraindicated as they paradoxically accentuate the extrinsic compression typified by “milking” of the epicardial artery and a “step down-step up” phenomenon.<sup>15</sup> Percutaneous coronary intervention (PCI) for refractory symptoms has been attempted; however, often challenging with disappointing results and complications, such as high target lesion revascularization, stent

fracture, thrombosis, and even coronary perforation.<sup>15</sup> Surgical interventions include coronary artery bypass grafting (CABG) and surgical myotomy, where the former is preferred in longer and deeper MB and the latter for less-complex cases.<sup>15,18</sup>

Our patient differed from the previously reported cases in that he was substantially younger (~20 years) than the other patients (early to late 50s) and did not have traditional cardiovascular risk factors, such as diabetes mellitus,



hypertension, dyslipidemia, tobacco use, and obesity. It is interesting to note that two of the case reports ascribed the principal diagnosis as MB-induced Wellens' syndrome, whereas the remaining case report labeled it as MB-induced pseudo-Wellens' syndrome. In our opinion, pseudo-Wellens' reflects a more accurate terminology as the myocardial bridge, despite being a congenital coronary anomaly, is not a conventional atheromatous lesion and may be hemodynamically transient in specific settings. Our patient's symptoms ameliorated with a moderate-dose single-pill combination of perindopril, amlodipine, and atorvastatin in addition to controlled-release carvedilol to attenuate polypharmacy and pill burden. His degree of MB did not warrant surgical intervention, as is usually reserved for refractory symptomatology and major adverse cardiovascular events.

## Conclusion

We describe a patient with MB-induced pseudo-Wellens' syndrome. The clinician should be aware of MB as a potential cause of pseudo-Wellens' syndrome and a differential diagnosis of T-wave inversions in a young subpopulation presenting with an ACS.

## Authors' Contributorship

All authors contributed equally to writing the manuscript, and all authors read and approved the final manuscript.

## Data Sharing Statement

All available data can be obtained by contacting the corresponding author.

## Declaration of Conflicting Interests

The author(s) declared no potential conflicts of interest with respect to the research, authorship, and/or publication of this article.

## Funding

The author(s) received no financial support for the research, authorship, and/or publication of this article.

## Compliance With Ethics Guidelines and Standards

All procedures performed in studies involving human participants were in accordance with the ethical standards of the institutional and national research committee and with the 1964 Helsinki Declaration and its later amendments or comparable ethical standards.

## Informed Consent

The patient has provided both verbal and written informed consent to have the details and images of his case published, and institutional approval was not required for publication.

## ORCID iD

Naveen Anand Seecheran  <https://orcid.org/0000-0002-7779-0181>

## References

1. de Zwaan C, Bär FW, Wellens HJ. Characteristic electrocardiographic pattern indicating a critical stenosis high in left anterior descending coronary artery in patients admitted because of impending myocardial infarction. *Am Heart J.* 1982;103(4 pt 2):730-736.
2. Tandy TK, Bottomy DP, Lewis JG. Wellens' syndrome. *Ann Emerg Med.* 1999;33:347-351.
3. Ola O, Tak T. Pseudo-Wellens syndrome in a patient with hypertension and left ventricular hypertrophy. *Am J Case Rep.* 2019;20:1231-1234. doi:10.12659/ajcr.916623.
4. Angelini P, Velasco JA, Flamm S. Coronary anomalies: incidence, pathophysiology, and clinical relevance. *Circulation.* 2002;105:2449-2454.
5. Corban MT, Hung OY, Eshtehardi P, et al. Myocardial bridging: contemporary understanding of pathophysiology with implications for diagnostic and therapeutic strategies. *J Am Coll Cardiol.* 2014;63:2346-2355.
6. Avram A, Chioncel V, Guberna S, et al. Myocardial bridging—an unusual cause of Wellens syndrome: a case report. *Medicine.* 2020;99:e22491.
7. Ambesh P, Sharma D, Kapoor A, et al. Unusual sign from an unusual cause: Wellens' syndrome due to myocardial bridging. *Case Rep Cardiol.* 2018;2018. doi:10.1155/2018/3105653
8. Kaplanis I, Michas G, Arapi S, et al. Myocardial bridge as a cause of pseudo-Wellens' syndrome. *Hellenic J Cardiol.* 2017;58:453-455.
9. Miner B, Grigg WS, Hart EH. *Wellens Syndrome.* Statpearls. Treasure Island, FL: Statpearls Publishing; 2021.
10. Rhinehardt J, Brady WJ, Perron AD, Mattu A. Electrocardiographic manifestations of Wellens' syndrome. *Am J Emerg Med.* 2002;20(7):638-643.
11. de Zwaan C, Bär FW, Janssen JH, et al. Angiographic and clinical characteristics of patients with unstable angina showing an ECG pattern indicating critical narrowing of the proximal LAD coronary artery. *Am Heart J.* 1989;117(3):657-665. doi:10.1016/0002-8703(89)90742-4.
12. Möhlenkamp S, Hort W, Ge J, et al. Update on myocardial bridging. *Circulation.* 2002;106:2616-2622.
13. Konen E, Goitein O, Sternik L, et al. The prevalence and anatomical patterns of intramuscular coronary arteries. *J Am Coll Cardiol.* 2007;587-593. doi:10.1016/j.jacc.2006.09.039.
14. Basso C, Thiene G, Mackey-Bojack S, Frigo AC, Corrado D, Maron BJ. Myocardial bridging, a frequent component of the hypertrophic cardiomyopathy phenotype, lacks systematic association with sudden cardiac death. *Eur Heart J.* 2009;30(13):1627-1634.
15. Lee MS, Chen C-H. Myocardial bridging: an up-to-date review. *J Invasive Cardiol.* 2015;27(11):521-528.
16. Hakeem A, Cilingiroglu M, Leeser MA. Hemodynamic and intravascular ultrasound assessment of myocardial bridging: fractional flow reserve paradox with dobutamine versus adenosine. *Catheter Cardiovasc Interv.* 2010;75:229-236.
17. Klues HG, Schwarz ER, vom Dahl J, et al. Disturbed intracoronary hemodynamics in myocardial bridging: early normalization by intracoronary stent placement. *Circulation.* 1997;96:2905-2913.
18. Sternheim D, Power DA, Samtani R, et al. Myocardial bridging: diagnosis, functional assessment, and management: JACC state-of-the-art review. *J Am Coll Cardiol.* 2021;78:2196-2212.