

Interventional Challenges in Non-Tubal Ectopic Pregnancy

Sahana Naik; M.S., Sunil Kumar; M.D., Asha Rani; M.S., Shruti Patil; MBBS,
Udayashree Voorkara; DGO, DNB., Vidya S Kamath; M.D.

Department of Obstetrics and Gynecology, SDM College of Medical Sciences and Hospital, Shri Dharmasthala Manjunatheshwara University, Dharwad, Karnataka, India

Received August 2021; Revised and accepted December 2021

Abstract

Objective: Non-tubal ectopic pregnancies (EPs) are rare and potentially life threatening. The number is rising due to various risk factors and there are no uniform guidelines in the management of EPs. This study was done to assess risk factors and challenges in the management of EPs.

Materials and methods: This is a retrospective observational descriptive study that was done at SDM College of Medical Sciences & Hospital, Shri Dharmasthala Manjunatheshwara University Dharwad, Karnataka India. Data was collected from the medical records section of all the patients of non-tubal ectopic pregnancies managed in our hospital from January 2020 to June 2021. The collected data were analyzed for demographic characteristics, risk factors and management.

Results: The incidence of ectopic pregnancies in our institute was 6-7 per 1000 pregnancies, of which 20% of the ectopic pregnancies were non-tubal. The incidence was higher than the other studies, which could be due to our center being a tertiary care referral center. Cesarean scar ectopic pregnancies were the most common accounting for 60% of cases. The management varied from conservative to minimally invasive surgery to hysterectomy with bilateral internal iliac artery ligation, depending upon the clinical presentation, duration of gestation, presence of fetal cardiac activity and hemodynamic stability. The other non-tubal ectopic pregnancies were cervical, ovarian, corneal and heterotopic. Cervical pregnancy beyond 12 weeks of gestation was rare which was managed by conserving the uterus.

Conclusion: Non-tubal ectopic pregnancies are rare. Early diagnosis requires a high index of suspicion if missed can lead to an array of complications leading to loss of fertility, morbidity, and mortality. The key step to avert the complications is early diagnosis and individualized treatment.

Keywords: Pregnancy; Ectopic Pregnancy; Tubal Pregnancy; Medical Intervention; Surgical Intervention

Introduction

Ectopic pregnancy is defined as the implantation of the fertilized embryo outside the uterine cavity. The incidence of ectopic pregnancy is 2-3% (1, 2). Tubal

ectopic pregnancies are the most common. The incidence of non-tubal ectopic pregnancies varies from 5-8.3% (3). Ectopic pregnancy is one of the leading causes of maternal morbidity and mortality (3%) in the first trimester of pregnancy (4). Some of the risk factors for ectopic pregnancies include pelvic inflammatory disease, history of ectopic pregnancies,

Correspondence:

Dr. Udayashree Voorkara

Email: drudayashree@yahoo.com



Copyright © 2022 Tehran University of Medical Sciences. Published by Tehran University of Medical Sciences.

This work is licensed under a Creative Commons Attribution-NonCommercial 4.0 International license (<https://creativecommons.org/licenses/by-nc/4.0/>).

Noncommercial uses of the work are permitted, provided the original work is properly cited.

intrauterine devices, tubal and uterine surgeries, tubectomy, use of assisted reproductive techniques, etc. Non-tubal ectopic (NTE) pregnancy may not be associated with tubal pathology (3).

NTE tends to present at later weeks of gestation in comparison with the tubal ectopic pregnancy, hence one should have a high index of suspicion while examining a case of amenorrhea, pain abdomen and vaginal bleeding (5, 6). The sites of NTE pregnancies are corneal or interstitial, ovarian, abdominal, cervical and cesarean scar pregnancy. The incidence of ectopic pregnancy and NTE pregnancy have been steadily increasing, this has been attributed to the increase in the use of assisted reproductive techniques and rising primary cesarean rates (7). Diagnosis of NTE involves numerous parameters. One should suspect NTE in the presence of ectopic triad of symptoms and raise a red flag on failure to visualize an intrauterine gestational sac. There is limited data on the guidelines for the management of NTE pregnancies. Hence, this study was done to assess the risk factors, clinical difficulties in diagnosing and challenges met in the management of the patients.

Materials and methods

This is a retrospective observational descriptive study done at SDM College of Medical Sciences & Hospital, Shri Dharmasthala Manjunatheshwara University Dharwad, Karnataka India from January 2020 to June 2021 for a period of 18 months. Data were collected from the medical records section after obtaining permission from the hospital authority. During this period, there were 51 cases of ectopic pregnancies, of which 10 cases were non-tubal ectopic pregnancies. The details of the non-tubal

pregnancies were collected from the case records. The patient's demographic details, clinical history, and physical examination were noted.

Details of the investigations used to aid the diagnosis like urine pregnancy test, serum beta human chorionic gonadotropin (HCG), transvaginal ultrasound, and magnetic resonance imaging were collected and analyzed. The details of the surgical procedures performed (laparoscopy/laparotomy) were collected. If the patients underwent conservative management, the follow up details till the resolution of the ectopic were noted down. The data were interpreted using descriptive analytics.

Results

The total number of deliveries in the hospital from January 2020 to June 2021 was 7378. There were 51 ectopic pregnancies during this period, this amounts to an incidence of 6-7 ectopic pregnancies per 1000 deliveries. Out of 51 ectopic pregnancies 10 cases were non-tubal ectopic pregnancies i.e. 20%. Cesarean scar pregnancy (CSP) accounted for more than half (60%) of the NTE pregnancy. This probably could be due to increase in the number of primary cesareans being performed (8). We had six cases of CSP and one case each, of ovarian ectopic, cervical ectopic, heterotrophic and corneal pregnancy (Figure 1).

There were six cases of cesarean scar ectopic pregnancies (Table 1). All the patients had more than 2 previous caesarean sections indicating increased chances of scar ectopic with higher parity and higher order of cesarean (10). Two of the cases were referred in view of failed medical method of termination of pregnancy (MTP).

Table 1: The clinical presentation of the cases with scar ectopic cases

Clinical presentation	Case 1	Case 2	Case 3	Case 4	Case 5	Case 6
Age	35yrs	33yrs	32yrs	28yrs	29yrs	24yrs
Obstetric score	G4P2L2A1	G5P3L1D2A1	G4P3L3	G3P2L2A1	G3P2L2	G3P2L2
No of previous cesarean section	2	3	3	2	2	2
Weeks at presentation	14 ⁺⁴	9 ⁺⁴	6	11 ⁺¹	6 ⁺²	7 ⁺⁴
CSP grading*	Grade IV	Grade III	Grade I	Grade III	Grade I	Grade II
Abdominal; pain	-	+	-	+	+	-
Vaginal Bleeding	-	+	+	-	+	-
Failed MTP**	+	-	+	-	-	-
Treatment	Hysterotomy with bilateral internal artery ligation	Laparotomy with CSP excision and repair	Conservative	Laparoscopic CSP excision and repair with sterilization	Ultrasound guided potassium chloride injection	Laparoscopic guided suction evacuation with sterilization

Abbreviations: *CSP- cesarean scar pregnancy, Grading of CSP according to Shin-Yu Lin et.al. (9)

**MTP-Medical termination of pregnancy

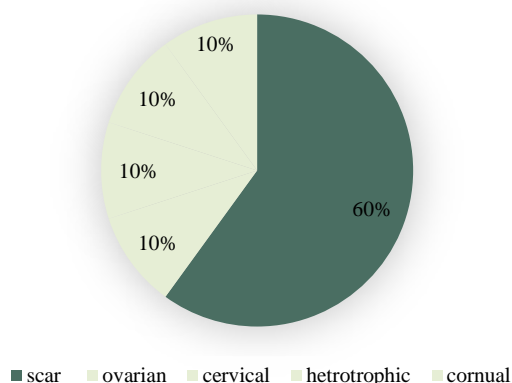


Figure 1: Distribution of non-tubal ectopic pregnancy

The patients were managed according to the clinical condition at presentation. All the patients with cesarean scar ectopic were diagnosed by transvaginal ultrasound with the criteria of (i) an empty uterus; (ii) an empty cervical canal; (iii) on a sagittal view of the uterus, demonstration of a discontinuity in the anterior uterine wall when running through the amniotic sac (iv) the gestational sac is located in the anterior part of the isthmic portion of the uterus with a diminished myometrium layer between the bladder and the sac (11,12). Hemodynamically unstable patients and patients with hemoperitoneum underwent surgical management.

Case no.1: A 35 years G4P2L2A1 woman was referred to our center at 14⁺ weeks of gestation (grade IV CSP) with a history of failed medical method of termination of pregnancy. The failure to diagnose caesarean scar pregnancy could be due to lack of suspicion or operator inexperience. As the pregnancy was advanced and viable, surgery being the only option, patient was electively managed by hysterotomy with bilateral internal iliac artery ligation (figure 2).

Case no.2: A 33 years G5P3L1D2A1 woman at 9⁺ weeks of gestation with previous three cesareans, with grade III CSP presented with bleeding per vaginum with severe anemia, underwent laparotomy with cesarean scar excision and repair. Anemia was corrected with packed red blood cell transfusion.

Case no.3: A 32 years G4P3L3 with previous three lower segment cesareans had taken MTP pill at around 7 weeks and then referred in the view of failure to expel and hematoma at the scar site (grade I CSP). Patient was hemodynamically stable but had a huge hematoma of 6 Cm *6 Cm at the scar site with thinned out myometrium - bladder interface. As there was no

viable pregnancy expectant management was done.

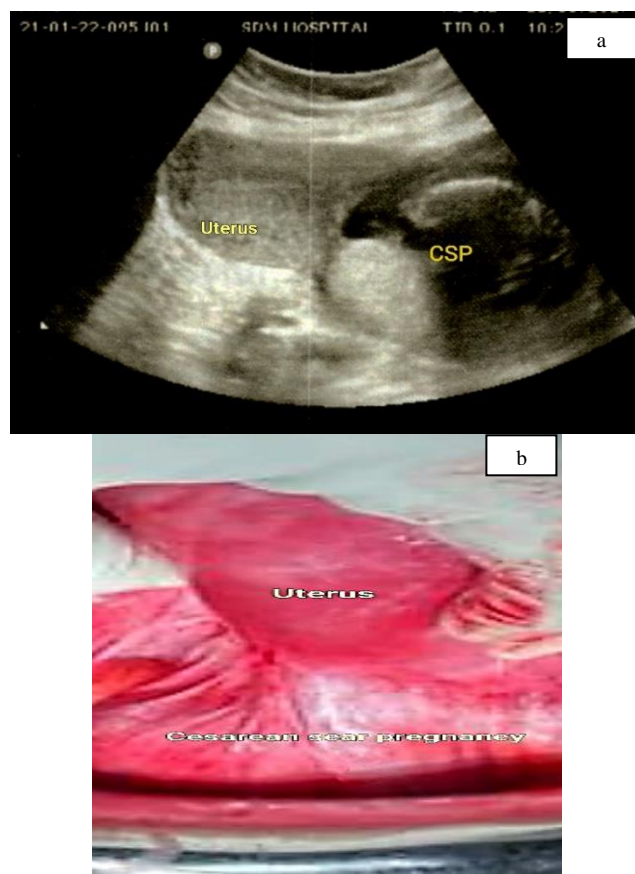
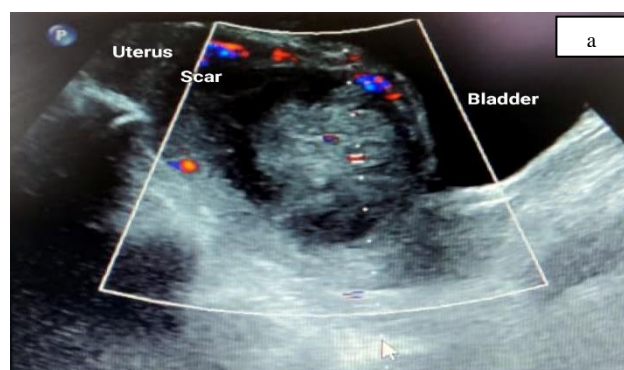

Figure 2: Cesarean scar pregnancy at 14 weeks, a) transvaginal ultrasound picture of cesarean scar pregnancy (CSP) at 14+4 weeks, b) Intra-operative findings of case 1 normal sized uterus with ballooned out scar site

Serial beta Hcg showed decreasing trend and hence followed up with weekly serum beta hCG till it tested negative. Ultrasound was repeated after 6 weeks and it was found that hematoma had regressed to less than 75 % (figure 3).



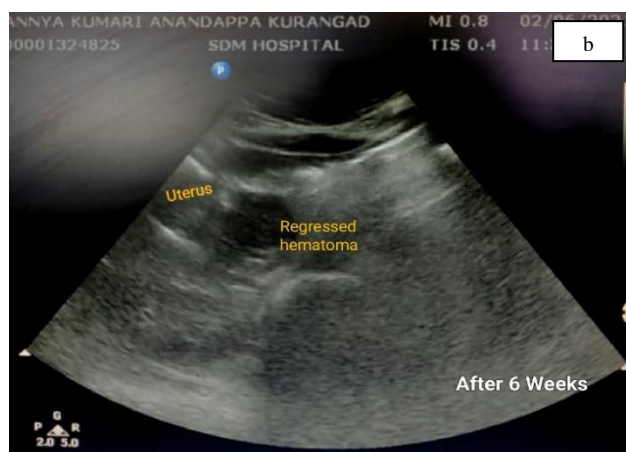


Figure 3: Cesarean scar pregnancy at 6 weeks with previous 3 Cesareans; a) At the presentation, hematoma of 6 cm x 6 cm at scar site with thinned out myometrium -bladder interface, b) Regressed hematoma after 6 weeks of expectant management

Case no.4: A 28 years G3P2L2A1 woman at 11⁺¹ weeks of gestation (Grade III CSP) presented to the hospital with pain abdomen and bleeding, with previous three cesareans and severe anemia. Pre-operative blood transfusion followed by laparoscopic CSP excision and rent repair along with tubal sterilization was done.

Case no.5: A 29 years G3P2L2 woman at 6+2 weeks' gestation (Grade I CSP) with previous 2 cesareans and a viable pregnancy, underwent ultrasound guided intra-amniotic potassium chloride injection and serially followed up with serum beta hCG till negative.

Case 6: A 24 years G3P2L2 woman at 7⁺⁴ weeks of gestation (Grade II CSP) with previous 2 cesareans underwent laparoscopic guided suction evacuation with tubal sterilization.

Non-cesarean scar site non-tubal pregnancies were

diagnosed by transvaginal ultrasound. Average weeks of gestation at presentation was 6 weeks and all the patients came with clinical triad for ectopic i.e. amenorrhea, pain abdomen and bleeding per vagina (11). All the patients were managed surgically as they were hemodynamically unstable or at advanced gestational age at presentation (table 2).

Cervical ectopic pregnancy is rare and occurs in 1 in 9000 deliveries (13,14). Case of cervical ectopic pregnancy presented at 12 weeks' gestation with viable fetus and was asymptomatic. She was an elderly 36 years' pregnant woman with type 2 diabetes mellitus. She had past history of miscarriage that was managed medically (figure 4).

Cervical pregnancy was detected at 12 weeks during her nuchal translucency scan and hence was referred to our center. Clinical examination, ultrasound and MRI showed, a soft, enlarged cervix equal to or larger than the fundus, products of conception entirely confined within and firmly attached to the endocervix, a closed internal cervical os and a partially opened external cervical os (15).

She missed her early antenatal visits due to nationwide lockdown imposed because of the COVID-19 pandemic, hence the delay in diagnosing. The key to avert complications in cervical pregnancy is early diagnosis and treatment. To avoid possible hysterectomy due to uncontrolled hemorrhage, patient was taken up for elective surgery with adequate blood and blood products. We did bilateral internal iliac artery ligation followed by suction evacuation with intracervical balloon tamponade of the cervix. Patient had intraoperative blood loss of 1.5 liters, in spite of internal iliac artery ligations and received blood and blood products. She needed repeat suction evacuation after 2 weeks for collected blood clots in the endocervical canal (figure 5).

Table 2: The clinical presentation of non-tubal ectopic pregnancies other than cesarean scar ectopic pregnancy

Clinical presentation	Ovarian	Cervical	Heterotopic	Corneal
Age	24 years	36 years	31 years	34 years
Mode of conception	Natural	Natural	Natural	IVF
Obstetric score	Primigravida	G2A1	G3P1L1E1	Primigravida
Weeks at presentation	5 weeks	12 weeks	7 weeks	5 weeks
Abdominal pain	+	-	+	+
Vaginal bleeding	+	-	+	+
Hemoperitoneum	+	-	+	+
Treatment	Laparotomy with Ovarian wedge resection	Laparotomy, bilateral internal artery ligation with suction evacuation	Laparoscopic salpingectomy with suction evacuation	Laparoscopic corneal repair

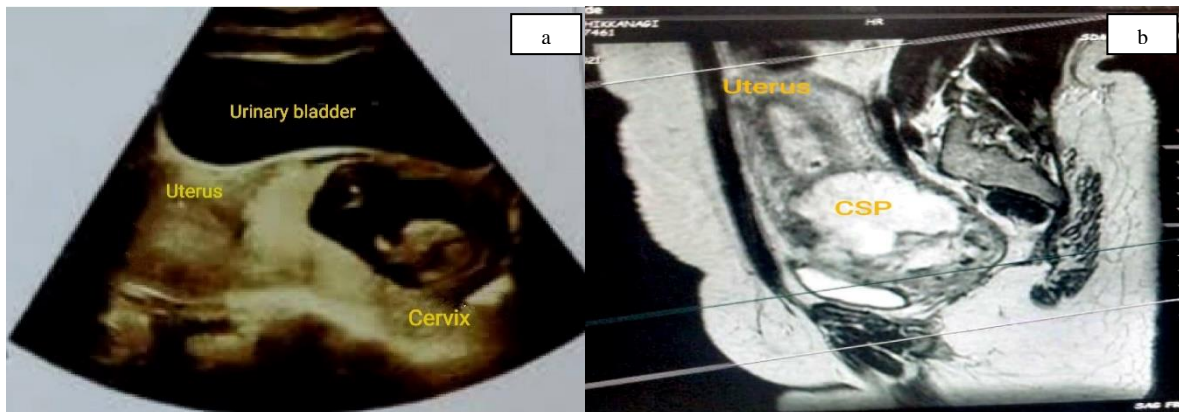


Figure 4: Ultrasound and MRI image of cervical pregnancy; a) Ultrasound image of cervical pregnancy, b) MRI image of cervical pregnancy

Ovarian ectopic: The case met Spiegelberg's criteria for diagnosis (16). A 24 years G3P1L1E1 woman at 5 weeks of gestation was admitted with acute abdomen and hemoperitoneum. She was operated with a pre-operative diagnosis of ruptured tubal ectopic. Ovarian wedge resection was done. The intraoperative findings and later histopathology confirmed it to be an ovarian ectopic. It is difficult to

diagnose ovarian ectopic preoperatively as it can mimic ruptured tubal ectopic /ruptured corpus luteal cyst with hemoperitoneum. **Cornual pregnancy:** A 34 years Primigravida woman at 5 weeks of gestation, conceived after IVF (In vitro fertilization), presented with pain abdomen and hemoperitoneum, with cornual rupture. She underwent laparoscopic cornual excision and repair.

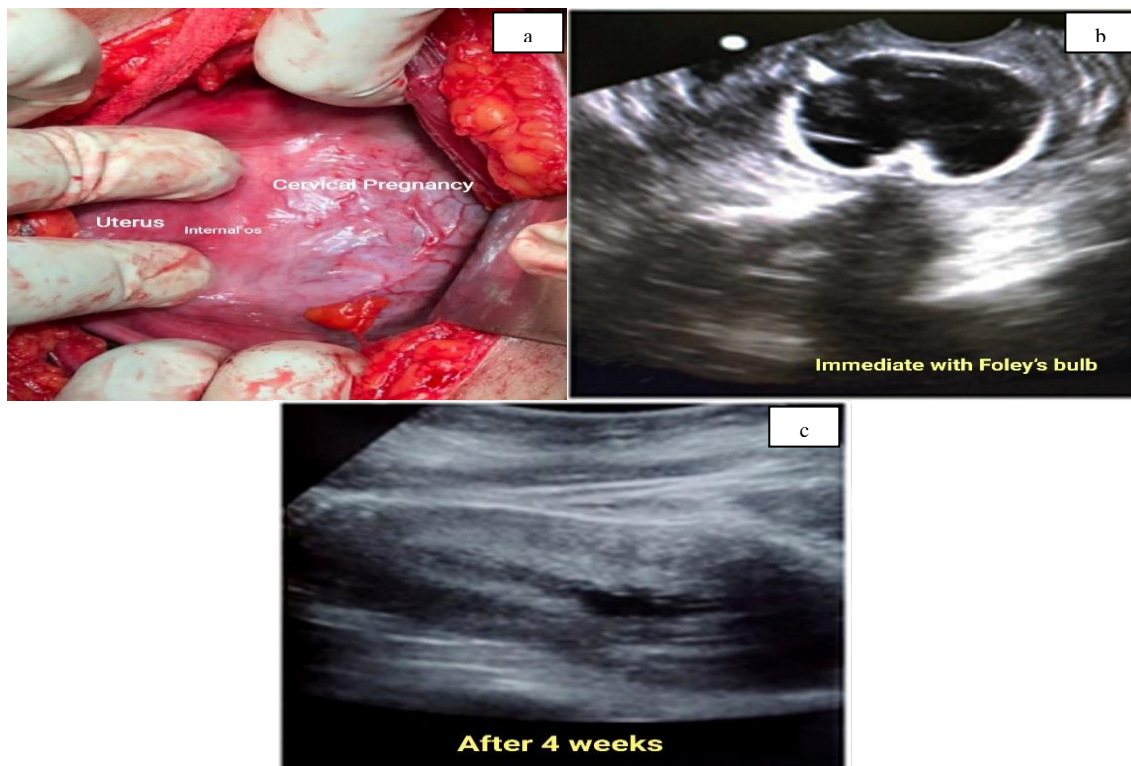


Figure 5: Intraoperative and transvaginal sonography image of cervical pregnancy; a) Intraoperative image of cervical pregnancy, b) Transvaginal sonography done in immediate post - op with intra cervical Foley's bulb tamponade, c) Transvaginal sonography after 4 weeks showing normal cervix

Heterotopic pregnancy: A 31 years G3P1L1E1 woman at 7 weeks presented with hemoperitoneum and an intrauterine gestational sac. She had a history of ectopic pregnancy. She underwent laparoscopic salpingectomy with suction evacuation of intrauterine pregnancy.

Discussion

Ectopic pregnancies account for 2-3% of pregnancies (1,2). Ectopic pregnancies are one of the commonest causes of emergency admissions in the first trimester requiring surgery. The ruptured ectopic pregnancies are still responsible for 2.7%-3.7% of all pregnancy related deaths (4). NTE pregnancies are potentially life threatening and surgically challenging, depending on the site of implantation and usually manifest with hemoperitoneum. There are no clear guidelines as to how to manage NTE pregnancies. Treatment is individualized depending on the clinical presentation, duration of gestation, cardiac activity, and serum beta hCG (17). At our center we had 51 ectopic pregnancies of which 10 cases were non-tubal i.e. 20% which is more than other studies probably due to our hospital being a tertiary referral hospital (1,3,16). NTE accounts for 5-8.5% of all the ectopic pregnancies according to Serin et al., which was lower than our study (20%) (16). Risk factors for ectopic pregnancies include pelvic inflammatory disease, history of intrauterine device insertions, dilation and curettage, history of infertility, tubectomy or in vitro fertilization (17). In our study only one patient had in vitro fertilization, the rest had spontaneous conception. There was no history of prior dilatation and curettage in any of our patient. Most of our patients had spontaneous conception, didn't have prior history of pelvic inflammatory disease. One patient underwent assisted reproductive procedure and the same patient had history of prior ectopic pregnancy. Scar ectopic was the most common of the NTE pregnancy in our study contributing 60% of the cases. The incidence of scar ectopic is on the rise due to the increasing number of primary cesareans being performed (18). The incidence of the scar ectopic is stated to be 6.1% for all the ectopic pregnancies in women who had at least one cesarean delivery, but in our study, all the patients had at least 2 or more lower segment cesarean section amounting to 12% of all the ectopic pregnancies (14-16).

This explains the higher incidence of scar ectopic in our study, could be due to the higher order of prior

cesarean sections or could be due to our center being a tertiary referral Centre (3). The average duration of gestation at presentation was 5-6weeks, this could be due to increased use of transvaginal ultrasound leading to early diagnosis (7,16). Our study was similar to Serin et al. where the patients presented at 6 weeks (16). Due to early detections most of the patients were clinically stable at presentation and were managed medically. Most of the patients had higher order of parity similar to Gull et al., where increase in the order of parity had increased risk for scar pregnancy (19). There is a newer grading of cesarean scar pregnancy (CSP) by Shin-Yu Lin et.al that could help in managing the patients (9). Grade I CSP when the GS was embedded in less than one-half thickness of the myometrium. Grade II CSP denoted that CSP occupied more than one-half depth of the implanted myometrium. In grade III CSP, the GS bulged out of the overlying myometrium and serosa. Grade IV CSP indicated that the GS became an amorphous tumor with rich vascularity at the site of previous cesarean scar. It was found that higher the grading that is beyond 9 weeks with thinned out myometrium, higher the chances of operative interferences (laparoscopy/ laparotomy), hysterectomy and associated morbidity. This was similar to our study where the patients more than 9 weeks of CSP had thinned out myometrium, failed to respond medically requiring surgical procedures. Patients with severe hemorrhage were given blood and blood products, but none underwent hysterectomy.

Cervical pregnancy is rare and accounts for less than 1% of the ectopic pregnancy. Risk factor for cervical pregnancy includes history of endocervical instrumentation, in vitro fertilization, intrauterine devices, none of which was present in our case (20, 21). There are many case reports of cervical pregnancy but all in the early gestation which can be managed medically. But cervical pregnancy going beyond 12 weeks' chances of undergoing emergency laparotomy due to rupture uterus or hysterectomy due to torrential hemorrhage is higher.

Our patient was asymptomatic at presentation but at high risk for complications, as the gestational age was advanced with a viable pregnancy and placenta invading up to the cervical serosa. The delay in the diagnosis could be due to being asymptomatic and missing early antenatal visits due to the nationwide lockdown because of COVID-19 pandemic. Most of the reported cases of cervical pregnancy beyond 12

weeks have resulted in hysterectomy (22). In order to control hemorrhage prophylactic bilateral internal iliac artery ligation was done followed by suction evacuation with intracervical balloon tamponade and hence uterus could be conserved (8, 17, 22). Many case reports describing surgical intervention have used prophylactic uterine artery embolization (UAE) or internal iliac artery ligation followed by suction evacuation similar to our study (3,19,21). Uterine artery embolization is not feasible in all cases either due to non-availability or if there is desire for future fertility. As our patient was nulliparous UAE was not done but prophylactic bilateral internal iliac artery ligation helped in averting major hemorrhage.

The incidence of ovarian ectopic pregnancy after natural conception ranges from 1 in 2000 to 1 in 60 000 deliveries and accounts for 3% of all ectopic pregnancies (21, 22). Ovarian ectopic is usually mimicking as ruptured tubal ectopic or corpus luteal cyst rupture. Ovarian ectopic pregnancies are difficult to diagnose even intraoperatively, as they can be confused with hemorrhagic corpus luteal cyst or rupture tubal ectopic pregnancy (23). In our study too, pre-operative diagnosis of ruptured ectopic was made but intraoperatively diagnosed as ovarian pregnancy and wedge resection was done. It was confirmed later with histopathological report. In our study ovarian tissue conservation was done by wedge resection similar to Alalade et al. study (5).

Heterotopic pregnancy and cornual pregnancy are rare and intriguing pregnancies. The incidence is rising with the advent of assisted reproductive techniques (24). Early diagnosis with prompt treatment remains the mainstay, though many patients end up in emergency department with ruptured ectopic. Treatment modality varies from medical to surgical management depending on clinical condition (25). In our study, heterotopic pregnancy was a natural conception which is rare i.e, 1 in 30,000 pregnancies for spontaneous conception, but she had risk factors with a history of an ectopic pregnancy (26). Patient presented with vaginal bleeding with hemoperitoneum and underwent laparoscopic salpingectomy with suction evacuation.

Cornual pregnancies are rare ectopic pregnancies accounting for 2-4% of the ectopic pregnancies (26). Patient was conceived by IVF procedure, which is a risk factor. In our study, patient presented with cornual rupture with hemoperitoneum. We performed laparoscopic cornual resection and repair which is a fertility preserving procedure (27).

Conclusion

Non-tubal ectopic pregnancies are rare but life threatening conditions that require early diagnosis for conserving fertility and reducing morbidity and mortality. There are no uniform guidelines in the management of the patient. Treatment of the patient depends on the clinical presentation to the hospital; it can vary from conservative approach, to minimally invasive, to surgery with hysterectomy leading to loss of fertility. Hence, the fundamental step in reducing the morbidity in non-tubal ectopic pregnancy is the early diagnosis that could allow medical management and avert major complications.

Conflict of Interests

Authors have no conflict of interests.

Acknowledgments

We thank Dr. Umesh R Dixit, professor, Department of Community Medicine, SDM College of Medical Sciences & Hospital, Shri Dharmasthala Manjunatheshwara University, Dharwad for helping with the statistical analysis.

References

1. Committee on Practice Bulletins-Gynecology. ACOG Practice Bulletin No. 191: Tubal Ectopic Pregnancy. *Obstet Gynecol* 2018; 131: e65-e77.
2. Dheepthikaa SK, Murugan RA. Retrospective study to assess incidence of ectopic pregnancies in Saveetha Medical College and Hospital. *International Journal of Reproduction, Contraception, Obstetrics and Gynecology* 2020; 9: 4632-5.
3. Stabile G, Zinicola G, Romano F, Buonomo F, Mangino FP, Ricci G. Management of non-tubal ectopic pregnancies: a single center experience. *Diagnostics (Basel)* 2020; 10: 652.
4. Shah P, Shah S, Kutty RV, Modi D. Changing epidemiology of maternal mortality in rural India: time to reset strategies for MDG-5. *Trop Med Int Health* 2014; 19: 568-75.
5. Alalade A, Mayers K, Abdulrahman G, Oliver R, Odejinmi F. A twelve-year analysis of non-tubal ectopic pregnancies: Do the clinical manifestations and risk factor for these rare pregnancies differ from those of tubal pregnancies. *Gynecological Surgery* 2016; 13: 103-9.
6. Dolinko AV, Vrees RA, Frishman GN. Non-tubal ectopic pregnancies: Overview and treatment via local injection. *J Minim Invasive Gynecol* 2018; 25: 287-96.

7. Alkatout I, Honemeyer U, Strauss A, Tinelli A, Malvasi A, Jonat W, et al. Clinical diagnosis and treatment of ectopic pregnancy. *Obstet Gynecol Surv* 2013; 68: 571–81.
8. Maymon R, Halperin R, Mendlovic S, Schneider D, Herman A. Ectopic pregnancies in a Caesarean scar: review of the medical approach to an iatrogenic complication. *Hum Reprod Update* 2004; 10: 515-23.
9. Lin SY, Hsieh CJ, Tu YA, Li YP, Lee CN, Hsu WW, et al. New ultrasound grading system for cesarean scar pregnancy and its implications for management strategies: An observational cohort study. *PLoS One* 2018; 13: e0202020.
10. Shah JS, Nasab S, Papanna R, Chen HY, Promecene P, Berens P, Johnson A, Bhalwal A. Management and reproductive counseling in cervical, caesarean scar and interstitial ectopic pregnancies over 11 years: identifying the need for a modern management algorithm. *Hum Reprod Open* 2019; 2019: hoz028.
11. Vial Y, Petignat P, Hohlfeld P. Pregnancy in a cesarean scar. *Ultrasound Obstet Gynecol* 2000; 16: 592-3.
12. Andola S, Kumar RR, Desai RM, Krutika SA. Study of risk factors and treatment modalities of ectopic pregnancy. *J Family Med Prim Care* 2021; 10: 724-9.
13. Maymon R, Halperin R, Mendlovic S, Schneider D, Vaknin Z, Herman A, et al. "Ectopic pregnancies caesarean section scars: the 8-year experience of one medical centre," *Human Reproduction* 2004; 19: 278-84.
14. Samal S, Ghose S, Pallavee P, Porkkodi P. Successful management of live cervical ectopic pregnancy: A case report. *J Clin Diagn Res* 2015; 9: QD03-4.
15. Paalman RJ, McElin TW. Cervical pregnancy: Review of the literature and presentation of cases. *Am J Obstet Gynecol* 1959; 77: 1261–70.
16. Serin AN, Birge O. Non-tubal ectopic pregnancy: Incidence and Diagnosis. London 2019.
17. Nedopekina E, Escura S, Cobo T, Hansson SR, Martinez JM, Figueras F, et al. Conservative treatment in non-tubal ectopic pregnancy and predictors of treatment failure. *Eur J Obstet Gynecol Reprod Biol* 2021; 257: 6-10.
18. Stabile G, Zinicola G, Romano F, Buonomo F, Mangino FP, Ricci G. Management of Non-Tubal Ectopic Pregnancies: A Single Center Experience. *Diagnostics (Basel)* 2020; 10: 652.
19. Ash A, Smith A, Maxwell D. Caesarean scar pregnancy. *BJOG* 2007; 114: 253–63.
20. Michener C, Dickinson JE. Caesarean scar ectopic pregnancy: a single centre case series. *Aust N Z J Obstet Gynaecol* 2009; 49:451-5.
21. Youssef HM, Emamb M, Zayed A. Conservative management of 14 weeks cervical ectopic pregnancy: Case report. *Middle East Fertil Soc J* 2016; 21: 281-4.
22. Scutiero G, Di Gioia P, Spada A, Greco P. Primary ovarian pregnancy and its management. *JSLs* 2012; 16:492-4.
23. Odejimi F, Rizzuto MI, MacRae R, Olowu O, Hussain M. Diagnosis and laparoscopic management of 12 consecutive cases of ovarian pregnancy and review of literature. *J Minim Invasive Gynecol* 2009; 16:354–9.
24. Ghasemi Tehrani H, Hamoush Z, Ghasemi M, Hashemi L. Ovarian ectopic pregnancy: A rare case. *Iran J Reprod Med* 2014; 12: 281-4.
25. Tawab A, ElHariri MA, Abdel Ghaffari Elhariri M., Alaa AA. Heterotopic pregnancy: a case report. *Egypt J Radiol Nucl Med* 2020; 51: 214.
26. Finlinson AR, Bollig KJ, Schust DJ. Differentiating pregnancies near the uterotubal junction (angular, cornual, and interstitial): a review and recommendations. *Fertil Res Pract* 2020; 8.
27. Brincat M, Bryant-Smith A, Holland TK. The diagnosis and management of interstitial ectopic pregnancies: a review. *Gynecological Surgery* 2019; 16: 2.

Citation: Naik S, Kumar S, Rani A, Patil S, Voorkara U, Kamath VS. **Interventional Challenges in Non-Tubal Ectopic Pregnancy.** *J Family Reprod Health* 2022; 16(1): 78-85.