

Root and Canal Morphology of Mandibular Second Molars in a Yemeni Population: A Cone-beam Computed Tomography

 Elham M. SENAN,  Hatem A. ALHADAINY,  Ahmed A. MADFA

ABSTRACT

Objective: This study aimed to identify and characterize root and canal morphology and the prevalence of C-shaped canals of mandibular second molars (MSMs) in a Yemeni population using cone-beam computed tomography (CBCT).

Methods: Three-dimensional digital images of 500 MSMs with mature roots were taken from 250 Yemeni individuals and analyzed for the following features: number of roots, shape and type of roots, type of canal configuration in each root, prevalence of C-shaped canal, and primary variations in the morphology of root and canal systems. Chi square and Fisher's exact tests were employed for statistical analysis.

Results: 89.6% of MSMs had two separate roots, 9% had two fused roots, 0.6% had three separate roots and 0.8% had one root. Mesial root was mostly ribbon-shaped (60.5%) and distal root was mostly kidney-shaped (50.7%). Type II and Type I canal configurations were the most frequent in mesial (56.9%) and distal (91.3%) roots, respectively. C-shaped canals were found in 9%. Six variants were found with variant 3 being the most common (71%).

Conclusion: Yemeni MSMs are mainly two-rooted. The prevalence of three- and one-rooted MSMs was relatively low. Various canals configurations were found in MSMs among this sample of Yemeni population. The clinicians should consider C-shaped roots and canals when treating Yemeni MSMs and should be aware of their morphological variations to ensure successful root canal treatment. Although bilateral similarity of many anatomical features of MSMs was found, individual evaluation of each MSM is necessary while performing endodontic treatment on both sides.

Keywords: Cone-beam computed tomography, C-shaped canal, mandibular second molar, morphology, root canal, Yemen

Please cite this article as: Senan EM, Alhadainy HA, Madfa AA. Root and Canal Morphology of Mandibular Second Molars in a Yemeni Population: A Cone-beam Computed Tomography. *Eur Endod J* 2021; 6: 72-81

From the Department of Restorative and Prosthodontic (E.M.S. ✉ elhamdent06@yahoo.com, e.senan@ust.edu, A.A.M.), College of Dentistry, University of Science and Technology, Sana'a, Yemen; Department of Endodontics (H.A.A.), Faculty of Dentistry, Tanta University, Tanta, Egypt; Department of Endodontics (H.A.A.), College of Dentistry, University of North Carolina, Chapel Hill, USA; Department of Conservative Dentistry (A.A.M.), Faculty of Dentistry, Thamar University, Dhamar, Yemen; Department of Restorative Dental Sciences (A.A.M.), College of Dentistry, Hail University, Hail, Saudi Arabia

Received 31 October 2019,
Accepted 25 June 2020

Published online: 27 January 2021
DOI 10.14744/ej.2020.94695

This work is licensed under a Creative Commons Attribution-NonCommercial 4.0 International License.



HIGHLIGHTS

- Yemeni MSMs had mainly separated two roots (89.6%), followed by fused two roots (9%), one root (0.8%) and separated three roots (0.6%).
- The most frequent canal type of two-rooted MSMs was Vertucci's type II (56.9%) in mesial root and type I (91.3%) in distal root.
- C-shaped roots and canals were found in 9% of the sample with equal unilateral and bilateral occurrence.
- C-shaped canals showed mainly C1 (an uninterrupted C-shape) at the orifice root level (68.9%), while C3c (three-separate canals shape) was the dominant shape at the coronal (55.6%), middle (66.7%), and apical (46.7%) root levels.

INTRODUCTION

Sufficient knowledge of the internal anatomy of teeth is a crucial prerequisite for proper root canal treatment. Long term success of endodontic treatment depends mainly on appropriate cleaning and shaping of the different anatomical details within pulp system including all canals along the root length and their divisions and fusions (1).

A number of studies reported that root and canal morphology of the mandibular second molars (MSMs) showed various and complex anatomical features (2-8) which can complicate the stages of end-

odontic treatment, from canals identification to obturation (4). One of the anatomical variations of MSMs is the number of their roots; although two roots are most commonly noticed, single root MSMs were found in 22-25% in Asian populations (3, 6) and in 9-14% in Caucasians (9). A third

root located distolingually (radix entomolaris, RE), or mesio-buccally (radix paramolaris, RP) was reported in 1.2% of a Thai population (6), 3.5% of Brazilians (2) and 3.45% of Turkish (10).

The C-shaped canal configuration is most frequently found in MSMs despite its presence in a number of posterior teeth such as the mandibular first premolar (11), maxillary first and second molars (12). Failure of the fusion of the epithelial root sheath on root surface either buccally or lingually is believed to be the main cause of C-shaped roots and canals occurrence (13). The prevalence of C-shaped canal was found to be 4.1% in a Turkish population (10), 6-44.5% in Eastern Asian populations (3, 4, 6, 8, 14), 10% in an African (5) and European population (9), 3.5-10% in southern American populations (2, 9), and 10.6% in an Arab population (15).

Few studies have evaluated root and canal morphology of MSMs in the Middle Eastern populations, particularly the occurrence of C-shaped canals (5, 15-18). Furthermore, there is no published study on the prevalence of C-shaped canals in MSMs in Yemen. Therefore, this study aimed to identify the characteristics of root and canal morphology of MSMs and to report the prevalence and anatomic features of C-shaped canals in these teeth in a Yemeni population using the three-dimensional digital imaging of Cone-beam computed tomography (CBCT).

MATERIALS AND METHODS

The protocol of this study was approved by the Medical Ethics Committee of the University of Science and Technology (UST), Sana'a, Yemen. Each participant provided verbal and written consents to be included in the study.

Inclusion criteria

The study sample included 250 Yemeni individuals (125 males and 125 females) attending dental clinics of the UST university at Sana'a city, Yemen, during the years of 2016 to 2018.

The included teeth were fully-erupted bilateral permanent MSMs with mature, sound or with initial decay without cavitation, no previous root canal treatment, no posts and/or crown restorations and no root resorption, calcification, or fractures.

CBCT imaging

The individuals (ranging in age from 18 to 40 years) were referred to a digital radiology center where CBCT images of 500 MSMs were performed (two images for each individual: one for the right side and one for the left side) using the Pax-Flex3D imaging system (VATECH Global, Korea) following the manufacturer's recommended protocol of: 50-90 kVp, 2-10 mA, 50×50 mm field of view (FOV), 15-24 seconds exposure time, and 120 μm voxel size for each tooth from each individual on both sides.

Two endodontists evaluated all CBCT scans after calibration to the anatomical criteria and variants used in this study. Disagreement in images interpretation was discussed between the two endodontists until a decision is made. Ez3D Plus image software (VATECH Global, Korea) was used to analyze the CBCT scans of each tooth in the three sections (axial, coronal, and sagittal) on a 14-inch Lenovo laptop screen (Lenovo

YOGA 3 Pro-1370, Lenovo PC HK Limited, HK, China) with a resolution of 1920 by 1080 pixels in a dimmed light room. Contrast and brightness of CBCT images were adjusted when required to obtain the best possible image for proper reading and analysis.

Observed morphological features

The following morphological features were recorded: Number of roots, type of roots (fused or separated), shape of root in cross section (round, oval, long oval, ribbon-shaped, kidney-shaped, bowling pin and hourglass) (19), type of canals within each root based on Vertucci's (1) classification and primary variations in root and canal systems morphology based on Zhang et al. (3).

C-shaped canals were evaluated in root cross sections coronally, middle and apically as follows: coronal level: 2 mm apical to the canal orifice level; middle: root length was divided by two; and apically: 2 mm coronal to the root apex. Afterwards, these canals were classified according to Fan et al. (20) classifications as follows:

- C1: a continuous C-shaped root canal with no separation
- C2: a comma-shaped root canal, resulting in a non-continuous C-shaped root canal (mesio-buccal-distal canal and a mesio-lingual canal)
- C3c: three separate root canals
- C3d: two separate root canals
- C4: only one root canal (round or oval in cross-section)
- C5: no canal lumen is seen, being visible only near the apex

Three anatomical features should be present for a MSM to be categorized as having a C-shaped canal system: fused roots, a longitudinal groove lingually, buccally or on both surfaces of their roots, and at least one cross-section of the C-shaped canal to be C1, C2 or C3 class configuration.

Statistical analysis

Bilateral and unilateral occurrences of similar anatomical features were recorded and their relations to gender and tooth location were determined. Statistical software (SPSS for Windows version 21.0, SPSS Inc., Chicago, IL, USA) was used to analyze the recorded data using Chi square and Fisher's exact tests. Statistical significance was set at $P \leq 0.05$.

RESULTS

Number of roots

Most MSMs had two roots (98.6%, $n=493$) with only 0.8% ($n=4$) had one root and 0.6% ($n=3$) had three roots with supernumerary RE root (Fig. 1). Molars with three canal orifices were the most common (77%, $n=385$), followed by two canal orifices (21%, $n=105$) whereas one canal orifice was found only in 1.4% ($n=7$). All three-rooted molars have four canal orifices (0.6%, $n=3$). A bilateral occurrence of similar number of canals orifices on both sides was recorded in 80.8% ($n=202$ individual).

No significant difference was found between females and males regarding frequency distribution of the total number of root canal orifices ($P>0.05$). One- and three-rooted molars (RE) occurred more in males. Regarding tooth side position, molars with two roots occur almost equally on both sides. All three-rooted molars (RE) occurred on the left side while one-rooted molars occurred more on the right side. Similar number of roots in right and left MSMs appeared in 98% ($n=245$ individual).

Type of roots

Molars with separated two roots predominated (89.6%, $n=448$), fused two roots were 9% ($n=45$) and separated three roots were 0.6% ($n=3$) (Fig. 1). Table 1 showed correlations between types of roots (separated or fused) with gender and tooth location. Bilateral existence of same type of roots was found in 94% ($n=235$). No significant difference of roots type was found between genders.

Shape of roots in cross section

Within the separated two-rooted molars, mesial root was mainly ribbon-shaped in cross section (60.5%, $n=271$), followed by kidney-shaped (19%), long oval (12.7%), and bowling pin (7.8%). Distal root was mainly kidney-shaped (50.7%, $n=227$), followed by oval (34.4%), long oval (14.5%), and round (0.4%) (Fig. 2). All molars with fused two roots showed a C-shaped root cross section. In three-rooted molars (RE), mesial root was

ribbon-shaped, distal root was either kidney-shaped or oval, and distolingual (DL) root was either oval or round. The four one-rooted molars showed an irregular shape in their root's cross section.

Root canal configuration types

Three of the four one-rooted MSMs showed Vertucci type I canal and the fourth one showed type III canal. Within the separated two-rooted MSMs ($n=448$), mesial root showed type II as the most frequent canal type in both genders accounting for 56.9% ($n=255$), followed by type IV (18.8%, $n=84$). In distal root, type I was the most prevalent type (91.3%, $n=409$). Additional canal types of Vertucci (Sert and Bayirli (21) additional type and Kartal and Yanikoglu (22) canal type) were found in mesial root but not in distal root (Table 2). The three-rooted molars ($n=3$) exhibited type II canal in mesial root and type I in both distal and RE roots (Fig. 3).

Fused roots and C-shaped canals

Of the 45 MSMs (9%) with fused two roots, four teeth (8.9%) had one shallow groove along the buccal root surface, fourteen teeth (31.1%) had one deep groove along the lingual root surface, and the remaining twenty seven teeth (60%) had both (Fig. 2). MSMs with fused two roots showed a C-shaped canal which was found more in females (60%) than males (40%). C-shaped canals occurred in a close frequency in both sides (48.9% on the right and 51.1% on the left).

TABLE 1. Correlations between type of roots in MSMs with gender and tooth side position

	Gender*			Tooth position†		
	Male	Female	Total	Right	Left	Total
One-rooted n (%)	3 (0.6)	1 (0.2)	4 (0.8)	3 (0.6)	1 (0.2)	4 (0.8)
Two-rooted						
Separated n (%)	227 (45.4)	221 (44.2)	448 (89.6)	225 (45)	223 (44.6)	448 (89.6)
Fused n (%)	18 (3.6)	27 (5.4)	45 (9)	22 (4.4)	23 (4.6)	45 (9)
Three-rooted n (%)	2 (0.4)	1 (0.2)	3 (0.6)	0(0)	3 (0.6)	3 (0.6)
Total n (%)	250 (50)	250 (50)	500 (100)	250 (50)	250 (50)	500 (100)

*P value=0.509 (>0.05), †P value=0.135 (>0.05)

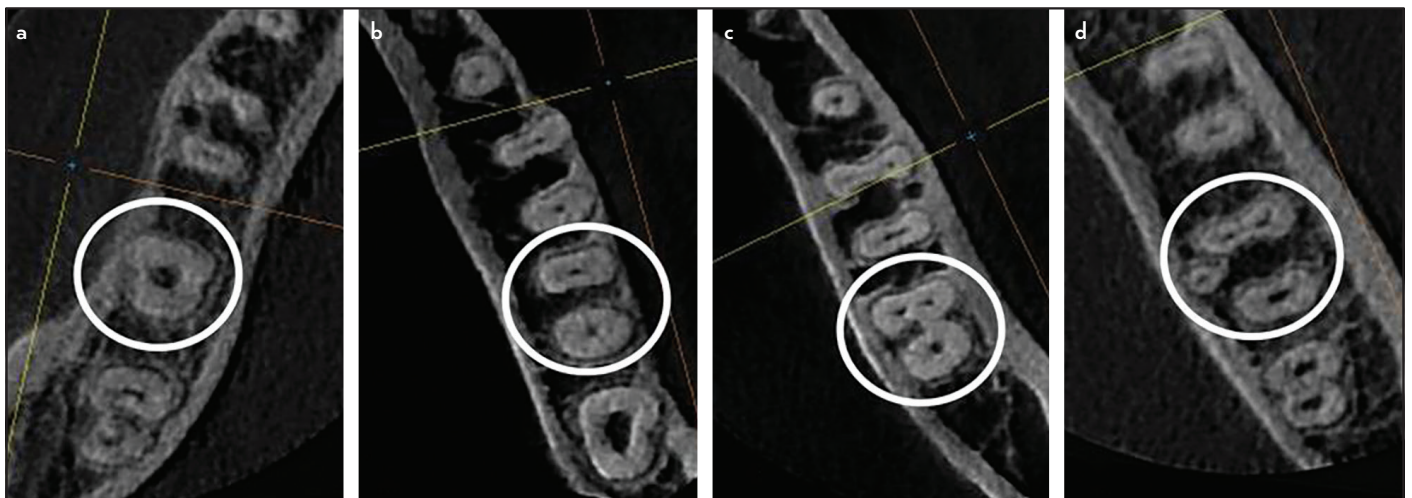


Figure 1. Different variations of MSMs roots numbers and types (white circles): (a) One root, (b) Two separated roots, (c) Two fused roots, and (d) Three separated roots

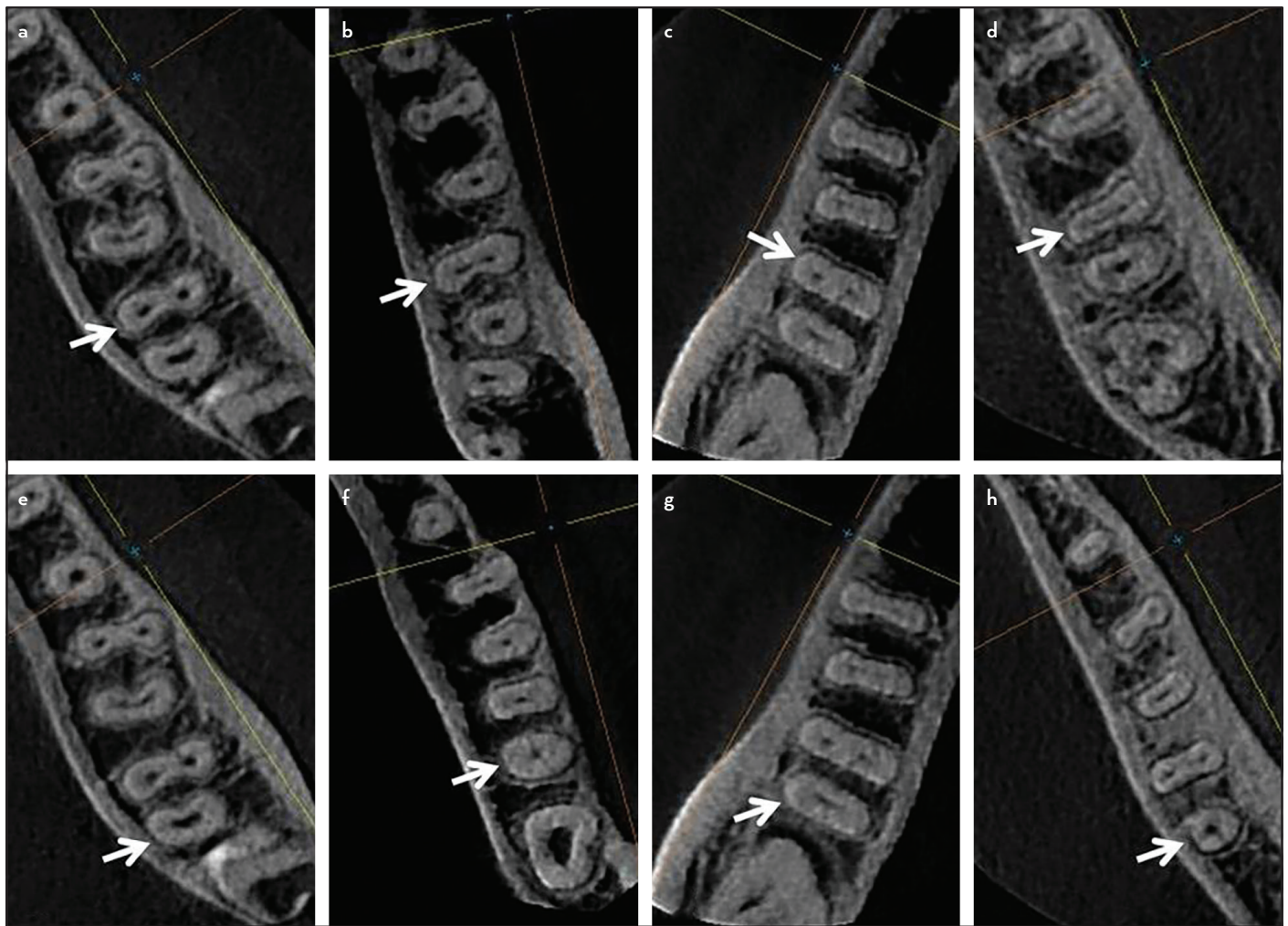


Figure 2. Main root cross-section shapes of MSMs roots (white arrows). Mesial roots: (a) Ribbon-shaped, (b) Kidney-shaped, (c) Long oval and (d) Bowling Pin. Distal roots: (e) Kidney-shaped, (f) Oval, (g) Long oval and (h) Round

TABLE 2. Variations of root canal types of mesial and distal roots of molars with separated two roots

Root	Vertucci's canal types								Vertucci's additional types		Other types*	Total	
	I	II	III	IV	V	VI	VII	VIII	2-3-1‡	2-3-2†	2-3-2-1		
Mesial													
n	18	255	70	84	5	5	0	0	1	4	6	448	
%	4	56.9	15.6	18.8	1.1	1.1	0	0	0.2	0.9	1.3	100	
Distal													
n	409	0	35	0	4	0	0	0	0	0	0	448	
%	91.3	0	7.8	0	0.9	0	0	0	0	0	0	100	

*Kartal and Yanikoglu additional type, †Sert and Bayirli additional types, ‡Not included in Vertucci's classification or within the additional types

The details of cross-sectional shapes of C-shaped canals at different root levels are shown in Table 3 and Figures 3-4. The majority of canals (68.9%) demonstrated an uninterrupted C-shape (C1) at the orifice root level, while three-separate canals shape (C3c) was the dominant shape at the coronal (55.6%), middle (66.7%), and apical (46.7%) levels. Semicolon shape (C2) was found more at coronal level (35.6%) than any other root levels. Two-separate canals shape (C3d) and single oval or round canal shape (C4) were found more frequent at apical level and in close percentages (26.7% and 24.4%

respectively). C5 (no canal lumen) was not detected in this study.

C-shaped canal configuration remains unchanged from orifice to apical level in two teeth only (4.4%). Teeth showed unchanged configuration from coronal to apical level in 37.8% of (17 teeth: C3c in 16 teeth and C3d in one tooth) while the C-shaped canal changed along the root length in the remaining 28 teeth (62.2%). From orifice to coronal level, class changed in 27 teeth, remains unchanged in eight teeth. From

TABLE 3. Cross-sectional canal shapes of C-shaped canals at different levels

Root level		C-shape cross section					Total
		C1	C2	C3c	C3d	C4	
Orifice	n	31	11	3	0	0	45
	% from C-shaped group	68.9	24.4	6.7	0	0	100
	% from total teeth sample	6.2	2.2	0.6	0	0	9
Coronal	n	3	16	25	1	0	45
	% from C-shaped group	6.7	35.6	55.6	2.2	0	100
	% from total teeth sample	0.6	3.2	5	0.2	0	9
Middle	n	0	9	30	5	1	45
	% from C-shaped group	0	20	66.7	11.1	2.2	100
	% from total teeth sample	0	1.8	6	1	0.2	9
Apical	n	0	1	21	12	11	45
	% from C-shaped group	0	2.2	46.7	26.7	24.4	100
	% from total teeth sample	0	0.2	4.2	2.4	2.2	9

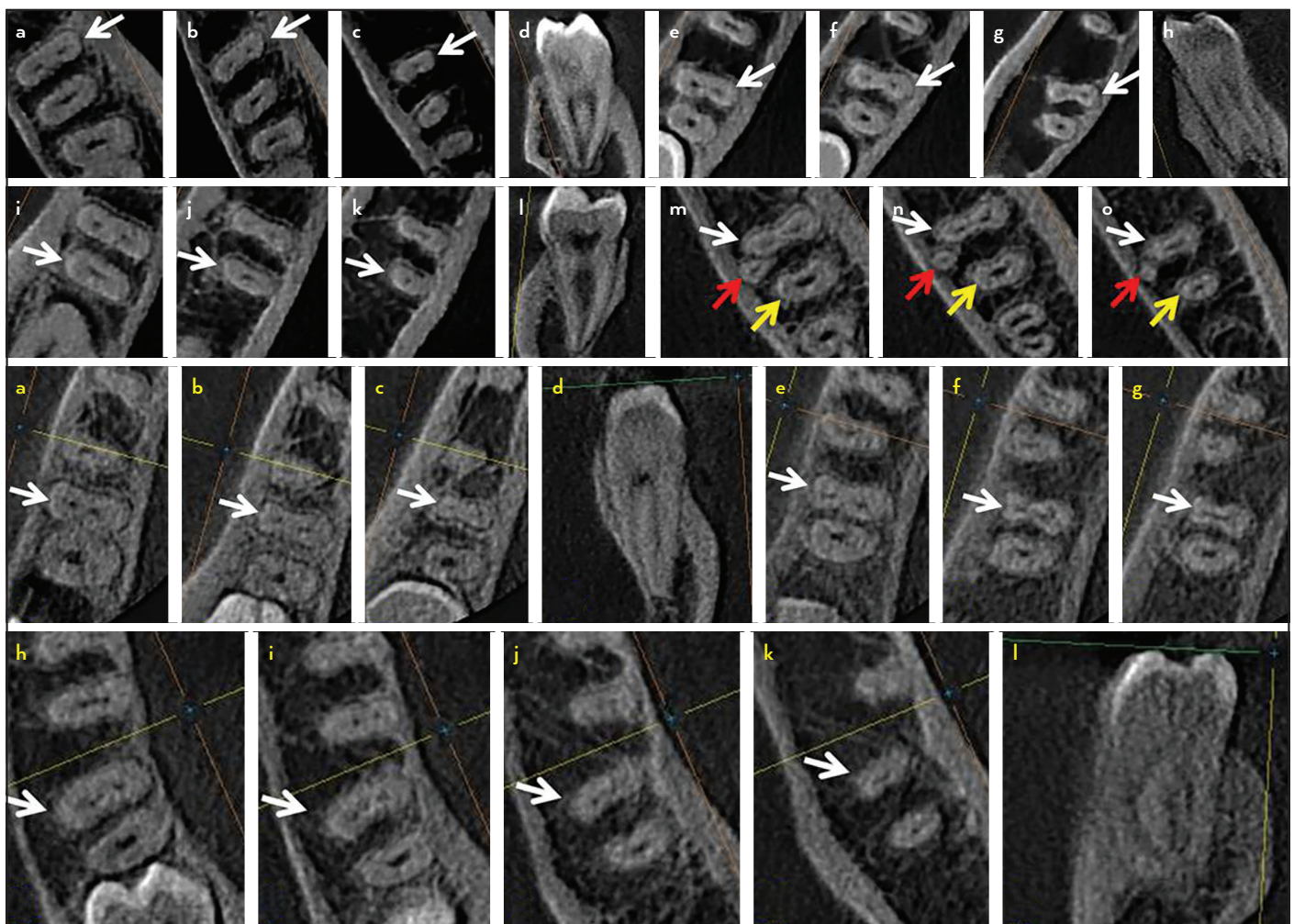


Figure 3. Main root canal types found in MSMs roots with two separated roots (white arrows). Mesial root: Type II canal: (a) coronal, (b) middle, (c) apical, (d) sagittal view and Type IV canal: (e) coronal, (f) middle, (g) apical and (h) sagittal view. Distal root: Type I canal: (i) coronal, (j) middle, (k) apical and (l) sagittal view. Three-rooted MSM showing Type II canal in mesial root (white arrows) and Type I canal in distal (yellow arrows) and DL root (red arrows): (m) coronal, (n) middle and (o) apical. Unusual root canal types found in mesial roots of MSMs: Type 2-3-2 canal: (a) coronal, (b) middle, (c) apical and (d) sagittal view; Type 2-3-1 canal: (e) coronal, (f) middle and (g) apical; Type 2-3-2-1 canal: (h) cervical, (i) coronal, (j) middle (k) apical and (l) sagittal view

coronal to middle level, class changed in 18 teeth, remains unchanged in 27 teeth. From middle to apical level, class changed in 22 teeth, remains unchanged in 23 teeth.

Table 4 shows the distribution of the bilateral and unilateral occurrences of C-shaped canals. MSMs with C-shaped canals observed in 30 individuals with bilateral occurrence in 15 indi-

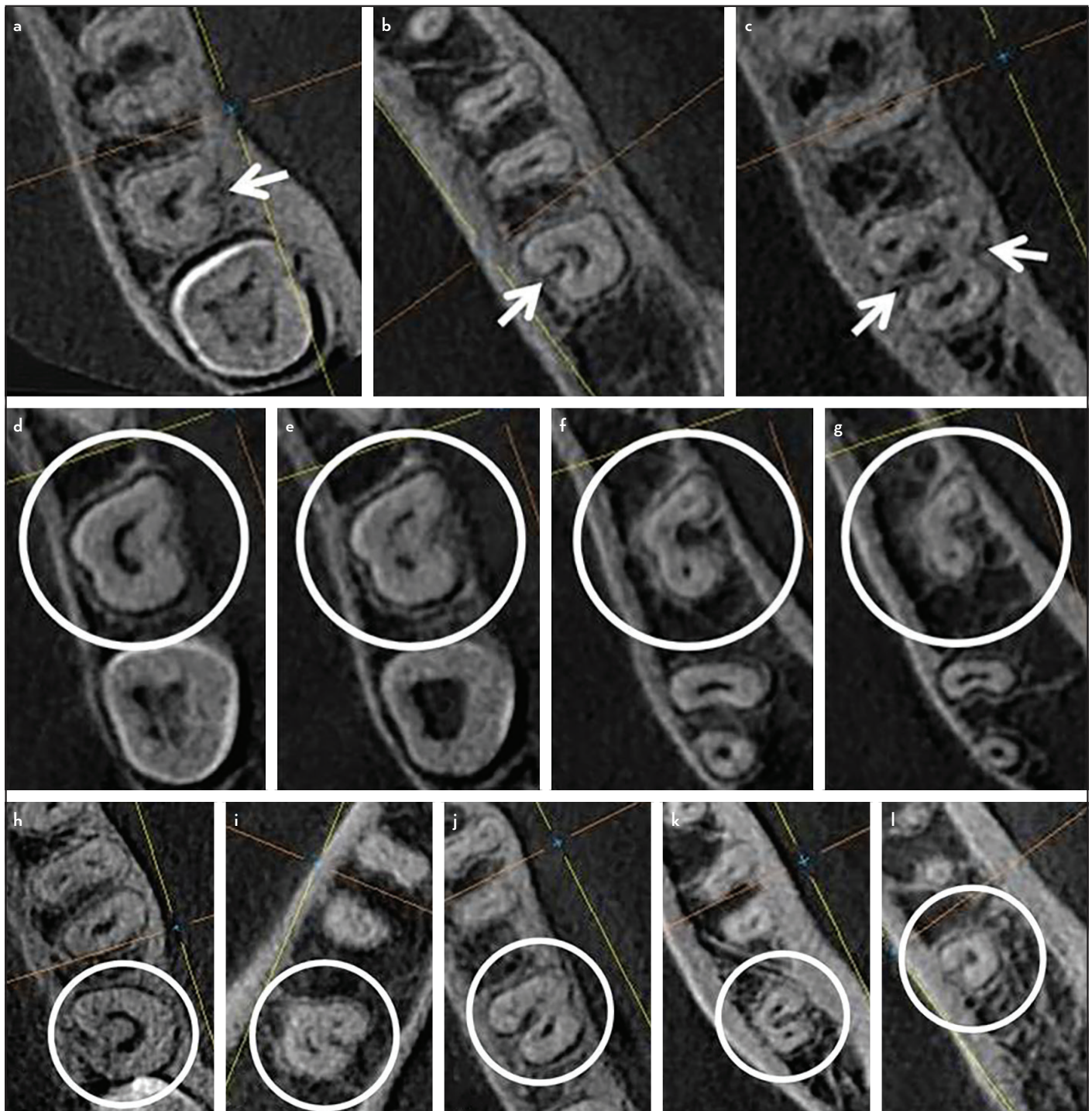


Figure 4. Root morphology of MSMs with fused two roots showing C-shaped cross section (white arrows): (a) Buccal groove, (b) Lingual groove and (c) Buccal and lingual grooves. C-shaped canal system at different root levels (white circles): (d) Canal orifice, (e) Coronal third, (f) Middle third and (g) apical third. Classes of C-shaped canals (white circles): (h) C1: continuous C-shaped canal, (i) C2: Mesiobuccal-Distal canal and a Mesiolingual canal (semicolon-shaped), (j) C3c: three separate canals, (k) C3d: two separate canals and (l) C4: single round or oval canal

viduals (50%). Frequency of bilateral distribution was more in females than males, while unilateral occurrence did not differ with gender or tooth location.

Variations in morphology of root canal systems according to Zhang et al. (3)

Only variants 1, 3, 6, 8, 9 and 10 were observed within the included 500 MSMs (Fig. 5). Variant 3 represented the most common variant (71%), followed by variant 1 (18.6%). The other

variants were found in smaller percentages (variant 10: 5.2%, variant 9: 3.2%, variant 8: 1.4% and variant 6: 0.6%). No significant difference of variants distribution was found with gender or tooth location. Only 75.6% of individuals presented similar variants on both sides.

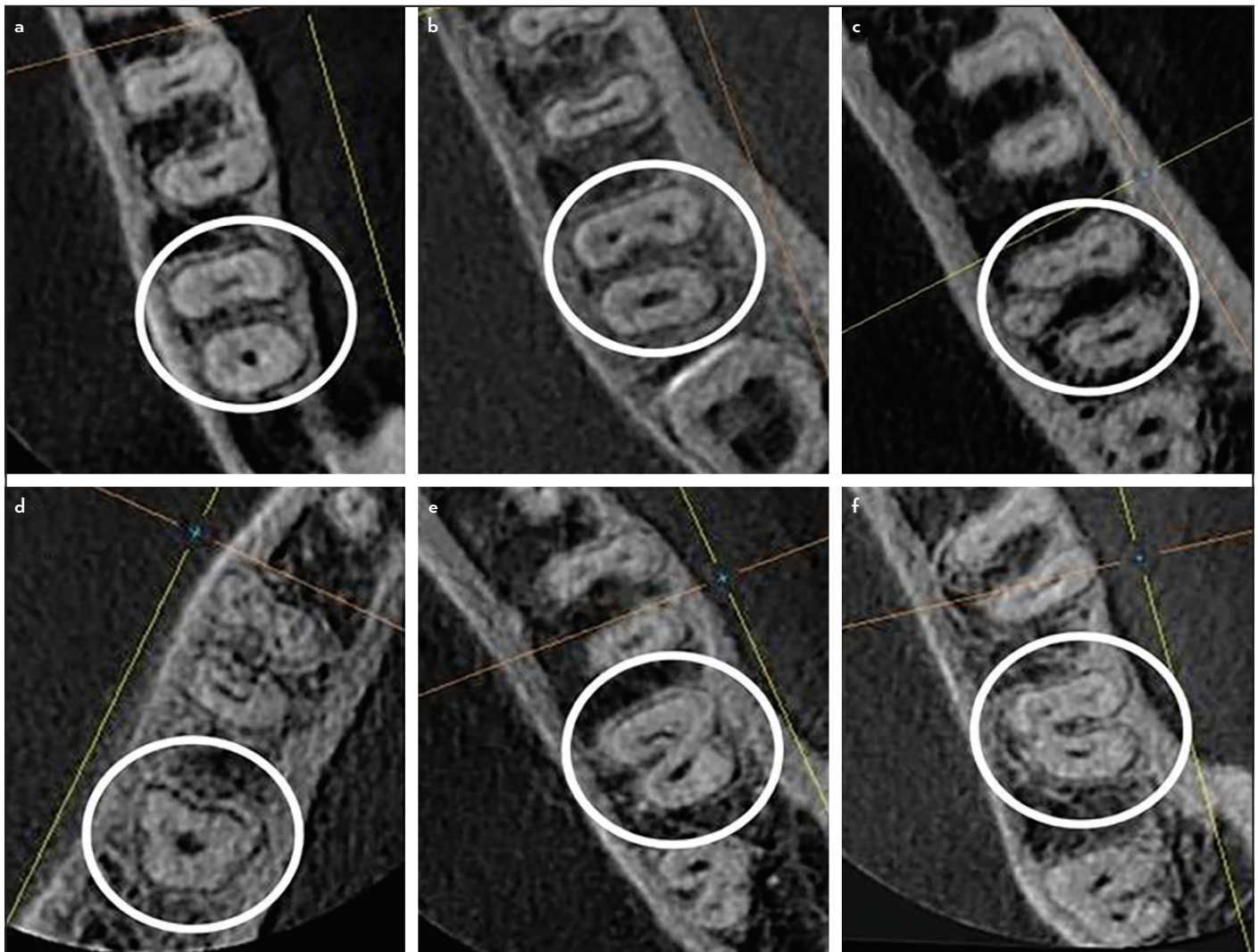
DISCUSSION

Anatomical variations of external and internal teeth morphologies associated with ethnicity have been well documented

TABLE 4. Distribution of unilateral and bilateral occurrences of C-shaped canals in relation to gender and tooth position

Occurrences	Number of individuals			Number of Teeth*		
	Male	Female	Total n (%)	Male	Female	Total n (%)
Unilateral						
Right	4	3	7 (23.3)	4	3	7 (15.6)
Left	4	4	8 (26.7)	4	4	8 (17.7)
Bilateral	5	10	15 (50)	10	20	30 (66.7)
Total	13	17	30 (100)	18	27	45 (100)

*P value=0.160 (>0.05)

**Figure 5.** Zhang et al. variants of roots and root canals (white circles): (a) Variant 1, (b) Variant 3, (c) Variant 6, (d) Variant 8, (e) Variant 9 and (f) Variant 10

in the literature through numerous studies and researches among different populations. Differences in root and root canal morphology of MSMs have been reported by several studies around the world with different percentages of each anatomical feature (2-8). The current study presented the first description of the root and canal anatomy of Yemeni MSMs.

CBCT was chosen as the evaluation method because it represents an advanced effective method for studying tooth ex-

ternal and internal anatomy due to the valuable information obtained from its coronal, sagittal, and axial plans. Although micro-CT can provide greater anatomical details of minor anatomical features such as accessory canals, foramina, apical delta and isthmi, it cannot be used clinically due to its high radiation doses. Additional advantages of CBCT involve improved detection of additional roots and canals, no superimposition of anatomical structures and decreased image distortion when compared to the two-dimensional digital radiography (23).

Yemeni MSMs had mostly separated two roots (89.6%). This is close to the findings reported in Iranians (79.2%, 81.6%) (7, 24), Turkish (85.4%) (10), Indians (88.8%) (25), Belgians (83.93%) and Chileans (86.61%) (9). The observed one-rooted MSMs in Yemeni population was 0.8% which is similar with the findings in Turkish (1.29%) (10). Nevertheless, higher percentages were reported in Iranians (19.8%) (7), Indians (8.7%) (25), Chileans (8.93%) (9), Belgians (14.29%) (9) and Chinese (22%) (3). We found only 0.6% of MSMs were three-rooted (RE), which was in accordance with studies in Iranians (0.6%) (24) and Belgians (0.89%) (9) but was higher than that reported in Koreans (0.3%) (26). However, higher percentages were reported in Thai (1.2%) (6), Turkish (3.45%) (10), Brazilians (3.5%) (2), and Chileans (3.57%) (9). No statistical gender-related differences were found in the occurrence of the number of roots of molars within this study, which was similar to Demirbuga et al. study findings in Turkish (10). MSMs with fused roots were 9% in this study, similar to fused roots reported in Turkish (8.97%) (10). However, higher percentages (24% and 39%) were found in Chinese (3, 4).

MSMs with three orifices were the most common in this study (77%), followed by two orifices (21%). This is similar to findings in Turkish (72.8% with three orifices and 22.8% with two) (10) and Chinese populations (46% with three orifices followed by 38% with two) (3).

The cross section of the roots of separated two-rooted MSMs was different in both roots such that mesial root was ribbon-shaped and distal root was kidney-shaped. Therefore, extreme care should be exercised while preparing root canals to avoid any complications that may occur due to thin dentin sections (danger zones) (27).

Mesial root of MSMs with separated two roots showed mainly type II canal, followed by type IV. This agrees with the results in Iranians (7), but disagrees with numbers reported in Sudanese (5), Chinese (3), Iranians (24) and Turkish (10) where mesial roots mainly had type IV canal. Our results also do not agree with findings in Belgians and Chileans (9) where type III canal was the most common type followed by type V. We found distal root had mostly type I canal which was the same as in Thai (6), Sudanese (5), Iranians (7, 24), Chinese (3), Turkish (10), and Belgians and Chileans (9).

Root canal type 2-3-2-1 was found in 1.3% of the mesial roots of MSMs (in six molars: one in male/left side and five in females/right side). It is considered as Vertucci non-classifiable type (Fig. 3). This configuration can be described using the classification formula suggested by Ahmed et al. (28) which describes the tooth number, its roots number and canal type in each root. Five of these six MSMs had Vertucci type I canal in their distal root and Vertucci type V in the sixth tooth. Therefore, according to this formula, these teeth will be coded as follows: $^{237} M^{2-3-2-1} D^1$ (on the left side), $^{247} M^{2-3-2-1} D^1$ and $^{247} M^{2-3-2-1} D^{1-2-1}$ (on the right side). The types of root canals that were mainly found in the MSMs with separated two roots in this study present less complicated anatomy than other complex types found in low percentages. However, they should be expected and looked for when treating such teeth.

MSMs with C-shaped root showed mainly both lingual and buccal grooves, followed by lingual groove only, and then by buccal groove only, unlike findings in studies of Saudi Arabians (17), Koreans (8) and Chinese (4, 20) which showed mainly only a lingual groove. Moreover, Wadhvani et al. (29) reported MSMs mainly with a buccal groove only in Indians.

C-shaped canals in this study were found in 9% of MSMs, which is similar to that found in Saudi Arabians (9.1%) (17). Closer percentages were reported in Chileans (8.93%) (9), Indians (8.1%, 9.7%) (25, 29), Sudanese (10%) (5), and Belgians (10.71%) (9). However, it was far lower than results in Iranians (17.6%, 21.4%) (7, 24), Lebanese (19.1%) (18), Chinese (29%, 38.6%) (3, 4), Koreans (39.8%, 44.5%) (8, 14) and Malaysians (48.7%) (30). Nevertheless, the incidence of C-shaped canals in Yemenis was higher than Brazilians (3.5%) (2), and Turkish (4.1%) (10).

C-shaped canals were found more in females than males with no statistically significant difference, which is similar to reports in Chinese (4), Indians (29) and Iranians (7). Nevertheless, statistically significant differences were found in Koreans (14), Saudis (17) and Malaysians (30). Regarding tooth location, C-shaped canals occurred almost even on both sides in this study with no significant difference, which is similar to reports in Chinese (4), Indians (29), and Koreans (14).

C1 was found to be the prevalent shape at orifice level which agreed with the findings in Chinese (4). C3c was the dominant shape coronally, followed by C2. C3c was also the dominant shape in the middle third. These findings differed from those of Zheng et al. (4) where C1 followed by C3d were the dominant shapes coronally and C3d was the most prevalent in the middle third. However, C3c followed by C3d were the dominant shapes apically in both Yemenis and Chinese. A study in Iranians (7) reported different results in which C1 was the most frequent in the coronal third and C3d was the major shape in both middle and apical thirds. Moreover, Kim et al. (14) reported that C2 is the most common configuration at the orifice level.

C-shaped canal configuration remains unchanged from orifice to apical level in 4.4%. Similar findings were recorded in Iranians (7) and Chinese (4) where 4.9% and 5.9% of C-shaped canals remained unchanged along the root length, respectively. This agrees with the results of Fan et al. (20) who reported that C-shaped canals vary in shape and number along the root length. Therefore, the shape of the canal orifice cannot be considered as an indicator of the C-shaped canal anatomy along the tooth root to its apex. There was no constant change in the configuration of the C-shape canal between two adjacent root levels. This was also reported by Zheng et al. (4).

The occurrence of C1 and C2 shapes decreased from the coronal to the apical levels, however, C3c shape increased toward the middle level and C3d type increased toward the apical level. This revealed a high possibility of division of C-shaped canals into two or three canals towards the apex. Similar results were reported earlier in Chinese (20). This necessitates the emphasis of applying the available techniques for canal debridement to ensure proper cleaning of such complex anatomy at different root levels.

The bilateral and unilateral occurrences of C-shaped canals were found to be equal. Janani et al. (7) reported a slightly higher occurrence of bilateral C-shaped canals (15.6%) than their unilateral occurrence (11.76%) in Iranians with no significant difference. However, there was a much higher percentage of bilateral C-shaped canals occurrence (81.3%) than unilateral occurrence (18.7%) in Chinese (4). Similarly, a 71% of bilateral occurrence of C-shaped canals was reported in Koreans (14). The unilateral occurrence of C-shaped canals was higher in Saudis (53.85%) (17). In relation to gender, bilateral occurrence of C-shaped canals in this study was more in females than males unlike Zheng et al. (4) who showed no difference of bilateral distribution with gender. Unilateral occurrence of C-shaped canals showed no significant difference regarding gender or tooth location in this study, similar to findings in Chinese (4).

Six variants (1, 3, 6, 8, 9 and 10) were observed in the root and root canal morphology of the studied MSMs. Other studies showed more variants such as seven variants (1, 3, 4, 6, 8, 9 and 10) in Brazilians (2), and eight variants (1, 3, 4, 5, 6, 8, 9 and 10) in Chinese (3). Variant 3 was the most common morphology in Yemenis followed by variant 1, similar to previous study reports in Brazilians (2) and Chinese (3). Yemeni MSMs showed a higher percentage of variant 3 (71%) than that found in Thai (54%) (6), Brazilians (54%) (2), and Chinese (42%) (3).

Root and canal morphology of Yemeni MSMs when compared with different populations showed the presence of morphological differences that should be taken into consideration during clinical practice. Therefore, proper clinical exploration and thorough radiographical examination during endodontic treatment are essential to diagnose the correct number of roots and their canals, thus, avoiding missing any root canal with possible subsequent treatment failure; and to identify the canal shape at each root level, thus, facilitating planning for canal debridement and subsequent obturation.

CONCLUSION

Yemeni permanent MSMs have mainly two separated roots and the prevalence of three-rooted MSMs was relatively low. Various canals configurations were found in MSMs among the studied Yemeni population. Vertucci type II and I canal configurations predominate in mesial and distal roots, respectively. The occurrence of C-shaped roots and canals must be considered when treating these molars, mainly in females. This anatomical variation must be identified to ensure successful root canal treatment. Individual evaluation of each MSM is necessary when performing endodontic treatment on both sides in spite of bilateral similarity of many anatomical features of MSMs.

The results of the present study further confirm that CBCT is a clinically effective tool for diagnosis and radiographic evaluation of the anatomical features of C-shaped canals with their varying morphology along the root length for proper canal debridement and obturation.

Disclosures

Conflict of interest: The authors deny any conflict of interest.

Ethics Committee Approval: The protocol of this descriptive observational cross-sectional study was approved by the Medical Ethics Committee of Fac-

ulty of Medicine and Health Sciences at University of Science and Technology (UST), Sana'a, Yemen (MECA NO.: EAC/UST138).

Peer-review: Externally peer-reviewed.

Financial Disclosure: This study was partially funded by the University of Science and Technology, Sana'a, Yemen.

Authorship contributions: Concept – E.M.S., H.A.A.; Design – E.M.S., H.A.A., A.A.M.; Supervision – H.A.A., A.A.M.; Funding - E.M.S.; Materials - E.M.S.; Data collection &/or processing – E.M.S., A.A.M.; Analysis and/or interpretation – E.M.S., H.A.A., A.A.M.; Literature search – E.M.S., H.A.A., A.A.M.; Writing – E.M.S., H.A.A., A.A.M.; Critical Review – E.M.S., H.A.A., A.A.M.

REFERENCES

- Vertucci FJ. Root canal anatomy of the human permanent teeth. *Oral Surg Oral Med Oral Pathol* 1984; 58(5):589–99.
- Silva EJ, Nejaim Y, Silva AV, Haiter-Neto F, Cohenca N. Evaluation of root canal configuration of mandibular molars in a Brazilian population by using cone-beam computed tomography: an in vivo study. *J Endod* 2013; 39(7):849–52.
- Zhang R, Wang H, Tian YY, Yu X, Hu T, Dummer PM. Use of cone-beam computed tomography to evaluate root and canal morphology of mandibular molars in Chinese individuals. *Int Endod J* 2011; 44(11):990–9.
- Zheng Q, Zhang L, Zhou X, Wang Q, Wang Y, Tang L, et al. C-shaped root canal system in mandibular second molars in a Chinese population evaluated by cone-beam computed tomography. *Int Endod J* 2011; 44(9):857–62.
- Ahmed H, Abu-bakr N, Yahia N, Ibrahim Y. Root and canal morphology of permanent mandibular molars in a Sudanese population. *Int Endod J* 2007; 40(10):766–71.
- Gulabivala K, Opananon A, Ng YL, Alavi A. Root and canal morphology of Thai mandibular molars. *Int Endod J* 2002; 35(1):56–62.
- Janani M, Rahimi S, Jafari F, Johari M, Nikniaz S, Ghasemi N. Anatomic features of C-shaped mandibular second molars in a selected Iranian population using CBCT. *Iran Endod J* 2018; 13(1):120–5.
- Jin GC, Lee SJ, Roh BD. Anatomical study of C-shaped canals in mandibular second molars by analysis of computed tomography. *J Endod* 2006; 32(1):10–3.
- Torres A, Jacobs R, Lambrechts P, Brizuela C, Cabrera C, Concha G, et al. Characterization of mandibular molar root and canal morphology using cone beam computed tomography and its variability in Belgian and Chilean population samples. *Imaging Sci Dent* 2015; 45(2):95–101.
- Demirbuga S, Sekerci AE, Dinçer AN, Cayabatmaz M, Zorba YO. Use of cone-beam computed tomography to evaluate root and canal morphology of mandibular first and second molars in Turkish individuals. *Med Oral Patol Oral Cir Bucal* 2013; 18(4):e737–44.
- Fan B, Yang J, Gutmann JL, Fan M. Root canal systems in mandibular first premolars with C-shaped root configurations. Part I: Microcomputed tomography mapping of the radicular groove and associated root canal cross-sections. *J Endod* 2008; 34(11):1337–41.
- Jo HH, Min JB, Hwang HK. Analysis of C-shaped root canal configuration in maxillary molars in a Korean population using cone-beam computed tomography. *Restor Dent Endod* 2016; 41(1):55–62.
- Manning SA. Root canal anatomy of mandibular second molars. Part II. C-shaped canals. *Int Endod J* 1990; 23(1):40–5.
- Kim HS, Jung D, Lee H, Han YS, Oh S, Sim HY. C-shaped root canals of mandibular second molars in a Korean population: a CBCT analysis. *Restor Dent Endod* 2018; 43(4):e42.
- Al-Fouzan KS. C-shaped root canals in mandibular second molars in a Saudi Arabian population. *Int Endod J* 2002; 35(6):499–504.
- Ahmad IA. Root and root canal morphology of Saudi Arabian permanent dentition. *Saudi Endod J* 2015; 5(2):99–106.
- Alfawaz H, Alqedairi A, Alkhayyal AK, Almobarak AA, Alhusain MF, Martins JNR. Prevalence of C-shaped canal system in mandibular first and second molars in a Saudi population assessed via cone beam computed tomography: a retrospective study. *Clin Oral Investig* 2019; 23(1):107–12.
- Haddad GY, Nehme WB, Ounsi HF. Diagnosis, classification, and frequency of C-shaped canals in mandibular second molars in the Lebanese population. *J Endod* 1999; 25(4):268–71.
- Walton RE, Vertucci FJ. *Internal Anatomy*. In: Walton RE, Torabinejad M, editors. *Endodontics: principles and practice*. 4th ed. St. Louis, Missouri: Saunders; 2009. p. 216–29.

20. Fan B, Cheung GS, Fan M, Gutmann JL, Bian Z. C-shaped canal system in mandibular second molars: Part I-Anatomical features. *J Endod* 2004; 30(12):899–903.
21. Sert S, Bayirli GS. Evaluation of the root canal configurations of the mandibular and maxillary permanent teeth by gender in the Turkish population. *J Endod* 2004; 30(6):391–8.
22. Kartal N, Yanikoğlu FC. Root canal morphology of mandibular incisors. *J Endod* 1992; 18(11):562–4.
23. Ordinola-Zapata R, Bramante CM, Versiani MA, Moldauer BI, Topham G, Gutmann JL, et al. Comparative accuracy of the Clearing Technique, CBCT and Micro-CT methods in studying the mesial root canal configuration of mandibular first molars. *Int Endod J* 2017; 50(1):90–6.
24. Madani ZS, Mehraban N, Moudi E, Bijani A. Root and canal morphology of mandibular molars in a selected Iranian population using cone-beam computed tomography. *Iran Endod J* 2017; 12(2):143–8.
25. Felsypremila G, Vinothkumar TS, Kandaswamy D. Anatomic symmetry of root and root canal morphology of posterior teeth in Indian subpopulation using cone beam computed tomography: A retrospective study. *Eur J Dent* 2015; 9(4):500–7.
26. Choi MR, Moon YM, Seo MS. Prevalence and features of distolingual roots in mandibular molars analyzed by cone-beam computed tomography. *Imaging Sci Dent* 2015; 45(4):221–6.
27. Sauáia TS, Gomes BP, Pinheiro ET, Zaia AA, Ferraz CC, Souza-Filho FJ, et al. Thickness of dentine in mesial roots of mandibular molars with different lengths. *Int Endod J* 2010; 43(7):555–9.
28. Ahmed HMA, Versiani MA, De-Deus G, Dummer PMH. A new system for classifying root and root canal morphology. *Int Endod J* 2017; 50(8):761–70.
29. Wadhwani S, Singh MP, Agarwal M, Somasundaram P, Rawtiya M, Wadhwani PK. Prevalence of C-shaped canals in mandibular second and third molars in a central India population: A cone beam computed tomography analysis. *J Conserv Dent* 2017; 20(5):351–4.
30. Pan JYY, Parolia A, Chuah SR, Bhatia S, Mutalik S, Pau A. Root canal morphology of permanent teeth in a Malaysian subpopulation using cone-beam computed tomography. *BMC Oral Health* 2019; 19(1):14.