

# Successful Pregnancy Outcome Immediately after Methotrexate Treatment for Cesarean Section Scar Pregnancy

Ibrahim A. Abdelazim<sup>1,2\*</sup>, Mohannad Abu-Faza<sup>1</sup>, Gulmira Zhurabekova<sup>3</sup>, Svetlana Shikanova<sup>4</sup>, Sakiyeva Kanshaiym<sup>4</sup>, Bakyt Karimova<sup>4</sup>, Mukhit Sarsembayev<sup>4</sup>, Tatyana Starchenko<sup>4</sup>

<sup>1</sup>Department of Obstetrics and Gynecology, Ahmadi Hospital, Kuwait Oil Company, Ahmadi, Kuwait, <sup>2</sup>Department of Obstetrics and Gynecology, Ain Shams University, Cairo, Egypt, Departments of <sup>3</sup>Normal and Topographical Anatomy and <sup>4</sup>Obstetrics and Gynecology No. 1, West Kazakhstan Marat Ospanov State Medical University, Aktobe, Kazakhstan

## Abstract

A 27-year-old cesarean section scar pregnancy (CSSP) case diagnosed by the vaginal ultrasound which showed gestational sac located in the lower uterine anterior quadrant close to the site of the previous scars (with yolk sac inside) with  $\beta$ -hCG 15,373 mIU/ml in September 2017 was managed by intramuscular (IM) multidose methotrexate (MTX). The studied woman discharged home when the  $\beta$ -hCG decreased to 11,630 mIU/ml on the 1<sup>st</sup> week after the first MTX dose. On the 5<sup>th</sup> week after the first dose of IM-MTX, the  $\beta$ -hCG dropped to zero and the gestational sac completely disappeared. She was counseled about the risk of pregnancy in the first 6 months after the MTX and the possibility of the CSSP recurrence. She presented on December 16, 2018, with preterm delivery at 35 weeks' gestation. After delivery, her neonate admitted to the neonatal intensive care unit (NICU) due to mild respiratory distress and discharged from the NICU on the 4<sup>th</sup> day in good condition. Multi-dose MTX regimen for the treatment of CSSP supported by many authors with follow-up by  $\beta$ -hCG and vaginal ultrasound. This report highlights the successful outcome immediately after the proper management of CSSP cases.

**Keywords:** Cesarean section scar pregnancy, methotrexate, pregnancy

## INTRODUCTION

Cesarean section scar pregnancy (CSSP) is an intrauterine pregnancy that occurs following implantation of the gestational sac over the previous uterine scars.<sup>[1]</sup>

Previous uterine scar is the only risk factor for CSSP. The true incidence of CSSP estimated as 1/1800–1/2500 of all cesarean deliveries,<sup>[1]</sup> and the incidence of CSSP increased due to increased rate of cesarean deliveries and improved imaging tools.<sup>[2]</sup>

The CSSP is often misdiagnosed as inevitable miscarriage or ectopic pregnancy.<sup>[3]</sup>

This report highlights the successful outcome immediately after the proper management of CSSP cases.

### Article History:

Received 3 January 2019

Received in revised form 21 January 2019

Accepted 7 March 2019

Available online 24 October 2019

## CASE REPORT

A 27-year-old CSSP case diagnosed by the vaginal ultrasound which showed gestational sac located in the lower uterine anterior quadrant close to the site of the previous scars (with yolk sac inside) with  $\beta$ -hCG 15373 mIU/ml in September 2017 was managed by intramuscular (IM) multi-dose methotrexate (MTX). IM-MTX injection was alternating with leucovorin (active form of folic acid). She was followed up by the  $\beta$ -hCG, vaginal ultrasound, and hematological parameters.

The studied woman discharged home when the  $\beta$ -hCG decreased to 11,630 on the 1<sup>st</sup> week after the first MTX dose.

**Address for correspondence:** Prof. Ibrahim A. Abdelazim, Department of Obstetrics and Gynecology, Ahmadi Hospital, Kuwait Oil Company, P. O. Box: 9758, 61008 Ahmadi, Kuwait.  
E-mail: dr.ibrahimanwar@gmail.com

This is an open access journal, and articles are distributed under the terms of the Creative Commons Attribution-NonCommercial-ShareAlike 4.0 License, which allows others to remix, tweak, and build upon the work non-commercially, as long as appropriate credit is given and the new creations are licensed under the identical terms.

**For reprints contact:** reprints@medknow.com

**How to cite this article:** Abdelazim IA, Abu-Faza M, Zhurabekova G, Shikanova S, Kanshaiym S, Karimova B, *et al.* Successful pregnancy outcome immediately after methotrexate treatment for cesarean section scar pregnancy. *Gynecol Minim Invasive Ther* 2019;8:185-7.

### Access this article online

#### Quick Response Code:



**Website:**  
www.e-gmit.com

**DOI:**  
10.4103/GMIT.GMIT\_134\_18

On the 5<sup>th</sup> week after the first dose of IM-MTX, the  $\beta$ -hCG dropped to zero and the gestational sac completely disappeared. She was counseled about the risk of pregnancy in the first 6 months after the MTX and the possibility of the CSSP recurrence.

She presented at December 16, 2018, with preterm delivery at 35 weeks' gestation (the last dose of MTX was taken on October 5, 2017, and her 1<sup>st</sup> day of the LMP was April 14, 2018). After delivery, her neonate admitted to the neonatal intensive care unit (NICU) due to mild respiratory distress and discharged from the NICU in the 4<sup>th</sup> day in good condition.

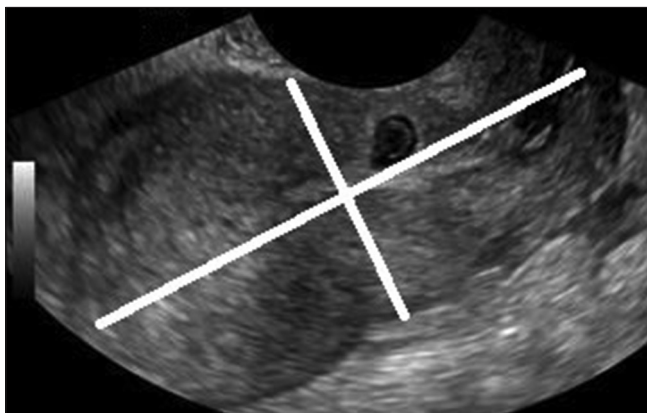
Written consent was taken from the studied woman and approval from the local ethical committee of the obstetrics and gynecology department to use the patient's medical records and data for publication and medical education.

## DISCUSSION

CSSP was diagnosed in women with previous uterine scar (s) based on positive pregnancy test and the following ultrasound findings:<sup>[3,4]</sup> (1) empty uterus, (2) gestational sac located in the lower uterine anterior quadrant close to the site of the uterine scar with closed cervix(s) [Figure 1]  $\pm$  yolk sac [Figure 2]  $\pm$  fetal pole and/or heart-beats; (3) thin layer of myometrial muscles between the gestational sac and the bladder wall, and (4) multiple vessels around the gestational sac indicating the placental implantation site.

The CSSP without fetal cardiac activity and no yolk sac and/or fetal echo can be managed by the ultrasound and  $\beta$ -hCG follow-up  $\pm$  IM-MTX.<sup>[3]</sup>

The CSSP with fetal cardiac activity can be managed either termination or continuation of the pregnancy. The continuation of pregnancy increases the risk of hemorrhage and emergency hysterectomy.<sup>[3]</sup>



**Figure 1:** Transvaginal ultrasound showing cesarean section scar pregnancy

The risk of CSSP recurrence is 1% and the treatment of CSSP should be individualized based on the patient's age and future fertility.<sup>[4]</sup>

The suggested treatments for CSSP are (1) surgical excision with subsequent uterine repair, (2) suction aspiration followed by balloon compression or hysterectomy (3). MTX (local and/or systemic).<sup>[5-8]</sup>

MTX is the most common treatment option for CSSP including (1) systemic single-dose IM-MTX regimen of 1 mg/kg of body weight,<sup>[5]</sup> (2) systemic multi-dose IM-MTX regimen,<sup>[7]</sup> (3) local MTX injection inside the gestation sac (ultrasound guided) is the most effective treatment for CSSP between 6–8 weeks' gestation (it stopped fetal cardiac activity and considered if future fertility desired).<sup>[5]</sup>

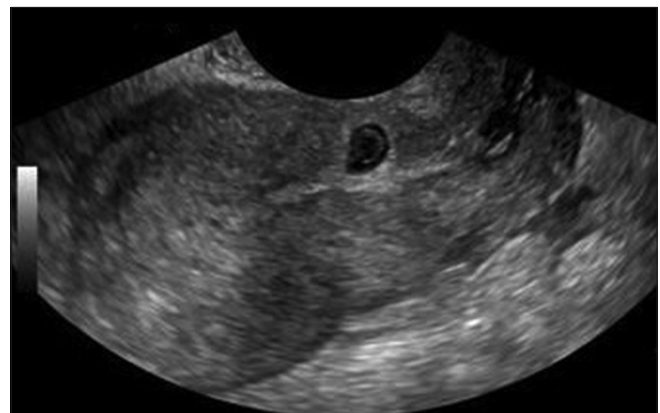Embolization of the uterine artery with intra-gestational MTX treatment or ultrasound-guided local and systemic MTX treatment was similarly effective in treating CSSP and both treatment likely to fail for CSSP with gestational sac  $>5$  cm.<sup>[9]</sup>

The studied CSSP case managed according to the protocol by systemic multi-dose IM-MTX with follow-up by  $\beta$ -hCG, vaginal ultrasound, and blood picture. On the 5<sup>th</sup> week after the first dose of IM-MTX, the  $\beta$ -hCG dropped to zero and the gestational sac completely disappeared.

Multi-dose IM-MTX regimen for CSSP with ultrasound and biochemical ( $\beta$ -hCG) follow-up was recommended by many authors.<sup>[3]</sup>

The  $\beta$ -hCG returned to nonpregnant level 6 weeks after the multi-dose MTX regimen for the treatment of CSSP.<sup>[10]</sup>

Uludag *et al.* compared the use of systemic and local MTX in the treatment of CSSP, and they found that the mean times for  $\beta$ -hCG normalization and the uterine-mass disappearance were significantly shorter in local MTX group than in systemic MTX group.<sup>[10]</sup>



**Figure 2:** Transvaginal ultrasound shows cesarean section scar pregnancy with yolk sac inside

However, oral ulcers<sup>[10]</sup> with decreased hematological parameters recorded as side effects of multi-dose IM-MTX treatment for CSSP.<sup>[10]</sup>

The studied woman did not develop any complication or side effects following the multi-dose IM-MTX regimen. This report represents the first case of successful pregnancy outcome immediately after multi-dose IM-MTX treatment for CSSP to highlight the successful outcome immediately after the proper management of CSSP cases.

## CONCLUSION

There is no single best treatment to terminate the CSSP and the procedure with the least complications should be selected. Multi-dose MTX regimen for the treatment of CSSP was supported by many authors with follow-up by  $\beta$ -hCG and vaginal ultrasound.

This report highlights the successful outcome immediately after the proper management of CSSP cases.

## Ethical approval

The local Obstetrics and Gynecology Department Ethical Committee of Ahmadi hospital has approved this study. The Institutional Review Board Project (approval number) OBGYN\_REC\_18.12.20 obtained on 20<sup>th</sup> December in 2018.

## Declaration of patient consent

The authors certify that they have obtained all appropriate patient consent forms. In the form, the patient has given her consent for her images and other clinical information to be reported in the journal. The patient understands that her name and initials will not be published and due efforts will be made to conceal identity, but anonymity cannot be guaranteed.

## Acknowledgment

We are grateful to woman agreed and gave consent to publish her data as a case report.

## Financial support and sponsorship

Nil.

## Conflicts of interest

There are no conflicts of interest.

## REFERENCES

1. Gao L, Huang Z, Zhang X, Zhou N, Huang X, Wang X, *et al.* Reproductive outcomes following cesarean scar pregnancy – A case series and review of the literature. *Eur J Obstet Gynecol Reprod Biol* 2016;200:102-7.
2. Fu LP. Therapeutic approach for the cesarean scar pregnancy. *Medicine (Baltimore)* 2018;97:e0476.
3. Timor-Tritsch IE, Monteagudo A, Cali G, Vintzileos A, Viscarello R, Al-Khan A, *et al.* Cesarean scar pregnancy is a precursor of morbidly adherent placenta. *Ultrasound Obstet Gynecol* 2014;44:346-53.
4. Gupta S, Pineda G, Rubin S, Timor-Tritsch IE. Four consecutive recurrent cesarean scar pregnancies in a single patient. *J Ultrasound Med* 2013;32:1878-80.
5. Yin XH, Yang SZ, Wang ZQ, Jia HY, Shi M. Injection of MTX for the treatment of cesarean scar pregnancy: Comparison between different methods. *Int J Clin Exp Med* 2014;7:1867-72.
6. Kutuk MS, Uysal G, Dolanbay M, Ozgun MT. Successful medical treatment of cesarean scar ectopic pregnancies with systemic multidose methotrexate: Single-center experience. *J Obstet Gynaecol Res* 2014;40:1700-6.
7. Wang DB, Chen YH, Zhang ZF, Chen P, Liu KR, Li Y, *et al.* Evaluation of the transvaginal resection of low-segment cesarean scar ectopic pregnancies. *Fertil Steril* 2014;101:602-6.
8. Wang Z, Shan L, Xiong H. Transvaginal removal of ectopic pregnancy tissue and repair of uterine defect for cesarean scar pregnancy. *Clin Exp Obstet Gynecol* 2013;40:546-7.
9. Wang M, Yang Z, Li Y, Chen B, Wang J, Ma X, *et al.* Conservative management of cesarean scar pregnancies: A prospective randomized controlled trial at a single center. *Int J Clin Exp Med* 2015;8:18972-80.
10. Uludag SZ, Kutuk MS, Ak M, Ozgun MT, Dolanbay M, Aygen EM, *et al.* Comparison of systemic and local methotrexate treatments in cesarean scar pregnancies: Time to change conventional treatment and follow-up protocols. *Eur J Obstet Gynecol Reprod Biol* 2016;206:131-5.