

HER-2/neu and E-cadherin Expression and Microsatellite Instability in Gastric Dysplasia

L Ahmadi¹, S Kamkari¹, P Mokarram², K Bagheri Lankarani³, N Tabibi¹,
H Ashktorab⁴, M Vasei^{5*}

1. Department of Pathology, Shiraz Institute of Cancer Research, Shiraz University of Medical Sciences, Shiraz, Iran
2. Department of Biochemistry, Shiraz University, Medical Sciences, Shiraz Iran
3. Department of Internal Medicine, Center for Health Research, Shiraz University of Medical Sciences, Shiraz, Iran
4. Department of Medicine, Howard University College of Medicine, 2041 Georgia avenue, N.W., Washington, DC 20060.
5. Department of Pathology, Shariati Hospital, Tehran University of Medical Sciences, Tehran, Iran

***Corresponding Author:**
Mohammad Vasei, MD
Department of Pathology, Tehran University of Medical Sciences, Tehran, Iran
Tel: + 98 21 84902205
Fax: + 98 21 82415400
E-mail: vaseim@sums.ac.ir
Received: 02 Nov. 2010
Accepted: 10 Feb. 2011

ABSTRACT

BACKGROUND

Gastric dysplasia (GD) is a precursor lesion of gastric adenocarcinoma. Intestinal type gastric carcinoma commonly shows microsatellite instability (MSI) and the diffuse type is associated with down regulation of E-cadherin. HER-2/neu is over-expressed in some cases of gastric cancer. In this study, MSI and expression rates of HER-2/neu and E-cadherin in GD were evaluated.

METHODS

Paraffin blocks of 21 cases of low grade dysplasia (LD), 11 cases of high grade dysplasia (HD) and 25 cases of indefinite for dysplasia (ID) were collected. After deparaffinization and antigen retrieval, the sections were incubated with antibodies against E-cadherin, hMLH1, hMSH2 and HER-2/neu. The streptavidin-biotin complex method was used followed by peroxidase enzyme development with diaminobenzidine.

RESULTS

HER-2/neu was positive in six cases of HD (50%), four LD (21%) and two ID (9%). E-cadherin was absent in two cases of LD and showed normal expression in all HD and ID cases. hMLH1 expression was absent or markedly decreased only in the zones of dysplasia in HD (3/11), LD (3/21) and ID (4/25). Absence or diminished expression of hMSH2 was seen in HD (3/11), LD (2/21) and ID (3/25) cases. HER-2/neu expression showed close association with diminished expression of hMLH1 or hMSH2 ($p < 0.05$).

CONCLUSION

Stepwise increase in the expression rate of HER-2/neu was seen in ID, LD and HD cases implying its role in cancer evolution. The absence of hMLH1 and hMSH2 in GD may predispose individuals to over-expression of other oncogenes such as HER-2/neu. Abnormal expression of E-cadherin is not a frequent finding in GD.

KEYWORDS

E-cadherin; HER-2/neu; hMLH1; hMSH2; Stomach; Dysplasia

INTRODUCTION

Gastric cancer is one of the most common cancers worldwide. Screening for precursor lesions and subsequent endoscopic follow-up allow detection of this tumor at an early and treatable stage of malignant transformation. In order to apply new therapeutic approaches, genes involved in various stages of cancer evolution need to be identified. Gastric dysplasia (GD) is a known precursor lesion of gastric cancer. Several studies show that dysplastic lesions precede the development of cancer and removal of dysplasia decreases cancer risk.¹

Gastric cancer is usually divided into two types, intestinal and diffuse, according to its histopathologic features. The intestinal type is usually associated with microsatellite instability (MSI). Gastric carcinomas with a high-frequency of MSI are associated with specific clinico-pathological characteristics such as: antral location, more abundant lymphoid infiltrate, less lymph node metastasis and better survival rate.²⁻⁶

Microsatellite instability comprises length mutation in tandem oligonucleotide repeats. It is a hallmark of the replication error phenotype, initially described in hereditary nonpolyposis colorectal carcinoma and later observed in some sporadic tumors from different sites.^{6,7} In humans, at least six proteins (hMLH1, hMSH2, hPMS1, hPMS2, hMSH6 and hMLH3) comprise the mismatch repair enzyme system (MMR). Defective DNA MMR usually results from genetic or epigenetic alterations in hMLH1 or hMSH2, but rarely in hMSH6 or hPMS2.⁸⁻¹⁰

MSI has also been reported in early and advanced gastric cancers caused by hypermethylation of the hMLH1 promoter region.¹¹⁻¹³ Such gene inactivations strongly correlate with a microsatellite instability-high phenotype (MSI-H) and result in a loss of protein expression identifiable by immunohistochemistry (IHC).¹⁴ The diffuse type of gastric cancer is

usually associated with decreased expression of the E-cadherin molecule. E-cadherin is an adhesion molecule involved in maintenance of epithelial integrity. Direct evidence of an E-cadherin mutation that triggers tumorigenesis has been clarified with the detection of a germ line mutation of the gene CDH1 in hereditary diffuse gastric cancer.¹⁵ This molecule is also down regulated in sporadic diffuse type gastric cancers because of a somatic mutation or hypermethylation of the promoter region in the early stages of tumorigenesis.^{16,17}

HER-2/neu is a proto-oncogene which belongs to the epidermal growth factor receptor family. HER-2/neu is reported to be over-expressed in gastric carcinomas at a range of 8% to 56%,¹⁸⁻²¹ with higher expression rates in advanced gastric cancer.^{22,23}

Mechanisms of the genetic changes in the development of GD have not been clearly recognized. Very limited data are available that address expression of E-cadherin in gastric dysplasia.²⁴ To the best of our knowledge, there have been a limited number of comprehensive studies on HER-2/neu²⁵ and MSI in GD.²⁶ To disclose the molecular mechanisms involved in GD, we aimed to assess alterations in E-cadherin, HER-2/neu, hMLH1 and hMSH2 expressions in gastric adenocarcinoma.

MATERIALS AND METHODS

From 2000 to 2006, all gastric biopsy reports from the Department of Pathology at Shiraz Medical University were retrieved. The slides were reviewed and diagnoses were reconfirmed using the Vienna classification.²⁷ Dysplasia was defined when cytologic and architectural alterations included increased nuclear size, nuclear hyperchromasia, glandular pleomorphism, loss of polarity and failure of maturation toward the surface epithelium were noted. Paraffin blocks of the cases diagnosed as low grade dysplasia (LD) and high grade dysplasia (HD) were retrieved from the archives. Twenty-five

cases of indefinite for dysplasia (ID), were also included in this study.

Five-micron sections from paraffin blocks were prepared on poly L-lysine coated slides. After deparaffinization and antigen retrieval, the sections were incubated with specific antibodies against the molecules. Commercially available antibodies to HER-2/neu (polyclonal, Dako, Denmark, 1:650), E-cadherin (clone, 36B5, Novocastra, UK, 1:50), hMLH1 (clone: G 168-15, BD Bioscience, USA, 1:50) and hMSH2 (clone, G219-1129, BD Bioscience, USA, 1:100) were used.

Sections were immersed in citrate and tris/EDTA buffers and processed in a water bath by boiling for 30 min for E-cadherin and HER-2/neu. The boiling time for hMLH1 and hMSH2 was 60 min with subsequent incubation in an autoclave (15 min at 120°C). After washing, sections were treated by the streptavidin-biotin complex method using a DAKO Universal LSAB kit (DAKO, Denmark) with diaminobenzidine tetrahydrochloride colorization. In the evaluation of hMLH1 and hMSH2, the dysplastic glands were regarded as negative only when stromal cells or lymphocytes in the adjacent area of dysplasia showed a positive nuclear reaction. For MSH2 staining, slides were only analyzed when the cytoplasmic reaction did not disturb evaluation of the nuclei.

We used the chi-square test to analyze statistical differences between LG, HG and ID for biomarker gene expression and a p -value of <0.05 was considered significant.

RESULTS

In the HD group, cases ranged from 44 to 80 years of age with the male to female ratio of 4.5. In LG, the age range was from 39 to 80 and the male to female ratio was 1.5. The most common site in HD, LD and ID cases was the antrum. Immunostaining for HER-2/neu was noted in six cases of HD which were membranous in three cases (two cases, 1+; one case,

2+) and cytoplasmic in three. Staining was limited to the dysplastic glands and not seen in the adjacent normal mucosa (Figure 1).

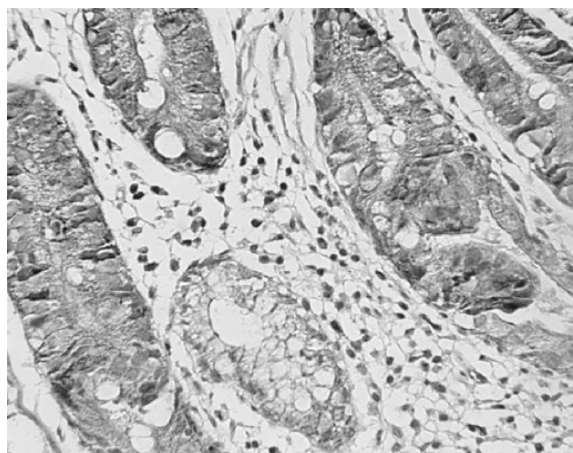


Fig. 1: Membranous expression of HER2/neu in the area of dysplasia and absence of expression in normal glands. Original magnification 400x.

In LD, four cases showed cytoplasmic HER-2/neu expression (19%), of which two had 1+ membranous staining. In ID, two cases stained positive in the cytoplasm with 1+ membranous accentuation in one case (Table 1). There was a significant association between HD and expression of HER-2/neu ($p = 0.005$).

Table 1: Expression of HER-2/neu and abnormal expression of E-cadherin, hMLH1 and hMSH2 in gastric dysplasia.

	HER-2/ neu (%)	E-cadherin loss (%)	MSH2 loss (%)	MLH1 loss (%)
ID (25)	2 / 23 (9)	0	4 / 24 (17)	3 / 24 (12)
LD (21)	4 / 19 (21)	2 / 20 (10)	3 / 20 (15)	3 / 20 (15)
HD (12)	6 / 12 (50)*	0	3 / 11 (27)	3 / 11 (27)

*Expression of this molecule is significantly higher ($p = 0.005$) in HD compared to the LD and ID groups.

One HD case had no hMLH1 expression and two cases showed a decrease in staining (Figure 2). MSH2 expression was absent in two HD cases and one case had diminished expression. Two cases had absent and marked decreased expression of both hMSH2 and hMLH1, respectively. In the LD group, three cases showed a decrease in hMLH1, of which two had decreased hMSH2. Three cases showed marked decrease in hMLH1

among the ID group. Lack of the hMSH2 molecule was seen in three cases and a decrease in expression was noted in one. One other case showed a decrease in both molecules. In all groups, the absence or decrease of expression of both molecules were limited to the dysplastic area.

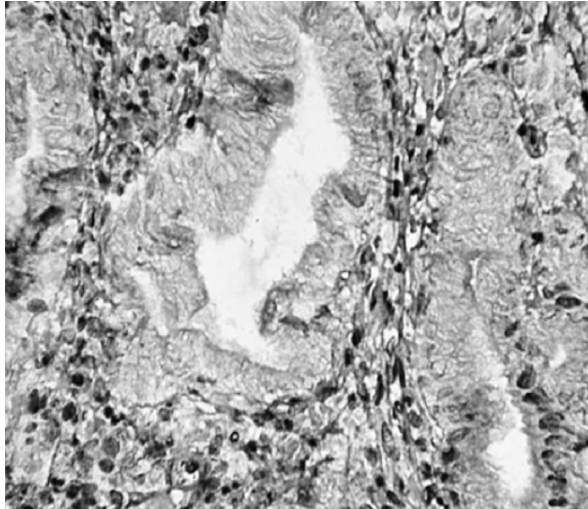


Fig. 2: Absence of expression of h-MLH1 in the nuclei of dysplastic glands with normal expression in the adjacent normal mucosa and stromal cells. Original magnification 400x.

Totally, of the 14 cases which showed absent or decreased expression in hMLH1 or hMSH2, there were six cases which expressed HER-2/neu. In contrast, in 31 cases with normal expression, only seven cases showed expression of the HER-2/neu molecule ($p < 0.05$). In HD, three cases which showed decreased or absent hMLH1 or hMSH2 showed expression of HER-2/neu with 2+ staining intensity.

E-cadherin reaction was focally absent in two LD cases. No aberrant cytoplasmic expression of E-cadherin was seen. All cases of HD and ID showed strong membranous patterns of the E-cadherin molecule.

DISCUSSION

We observed that HER-2/neu was expressed in 50% of HD cases, 21% of LD and 9% in ID. The expression of HER-2/neu was limited to dysplastic glands and not seen in the adjacent normal mucosa. The expression was mainly

cytoplasmic with membranous accentuation in some cases.

Concerning gastric carcinomas, several studies reported different frequencies of HER-2/neu expression that ranged from 8 to 55 %.¹⁸⁻²³ HER-2/neu expression in breast cancer is usually regarded as clinically significant when only membranous staining is seen. But there are many reports which imply that both membranous and cytoplasmic expressions are significant in gastric carcinoma.²⁸⁻³¹ By an IHC study on 56 cases of gastric cancer, Lee et al. observed only cytoplasmic staining in 21 cases.

Strong membrane staining was found in 14 cases, of which all were intestinal type adenocarcinoma.³¹

Both cytoplasmic and membranous HER-2/neu proteins were confirmed to be a 185-kDa whole molecule by immunoblotting.²¹ Garcia et al. showed that cytosolic HER-2 level of gastric carcinoma cells was associated with an unfavorable outcome.³² It has been suggested that because proteins are synthesized in the ribosomes, the antibody may detect cytoplasmic precursors of the final product.³³ As with breast cancer, it has been observed that only cases with membrane reactivity are linked to HER-2 gene amplification and clinical response to Herceptin therapy.³⁴

The association between expression of HER-2/neu and GD is not well understood. There is only one report addressing the absence of membranous staining in GD.²⁵ Cytoplasmic as well as membranous expression of HER-2/neu were detected in gastric adenoma. Immunoreactivity in the area of tumoral transformation was seen only at the membrane.

This membranous expression was not observed in hyperplastic polyps and adenomas without malignant changes.³⁵ A high frequency of expression of HER-2/neu was observed in the chronic gastritis area with intestinal metaplasia in the territory of gastric carcinoma.²⁰ Wang et al. showed that patients with advanced gastric cancer had HER-2/neu expression on

the non-tumor stomach tissues.²²

As a result of their study, the HER-2/neu proto-oncogene of two specimens was amplified 2 to 4-fold to normal control status. In these two cases, HER-2/neu was also amplified at histologically normal tissue adjacent to the tumor tissue. They did not notice the presence of atypia or dysplasia in area of the tumors. Garcia et al. studied fifty-two patients with primary gastric adenocarcinoma in a prospective study. HER-2/neu protein levels were significantly higher in membranous than in cytosolic samples, both in neoplastic tissue and in adjacent mucosa samples. Nevertheless, there was a significant positive relation between membranous and cytosolic HER-2/neu protein contents in both neoplastic tissue and adjacent mucosa samples but no difference in the membranous HER-2/neu protein content.

However, the cytosolic HER-2/neu content was significantly higher in neoplastic tissues than in adjacent mucosa.³⁰

Our findings suggest that HER-2/neu protein expression may play a role in the progression from normal to neoplastic gastric mucosa and cytoplasmic expression of this molecule may be seen at early stages of gastric carcinogenesis, i.e. GD. Further confirmatory studies such as mRNA expression by RT-PCR as well as western blot are suggested to validate our IHC findings.

Loss of normal DNA MMR promotes tumorigenesis and inactivation of the DNA MMR genes, hMLH1 and hMSH2, strongly correlate with microsatellite instability (MSI).

These tumors have a better prognosis than tumors with no defective DNA MMR. Defective DNA MMR may account for the favorable prognosis associated with gastric carcinoma and play a significant role in its pathogenesis. Aberrant methylation of the hMLH1 promoter and lack of hMLH1 expression in sporadic gastric carcinomas with high-frequency microsatellite instability have been reported.^{4,36,37}

DNA MMR enzyme deficiency, which leads to MSI, is shown in early gastric cancer.³⁸ However studies that disclose MSI status in precancerous gastric lesions are not comprehensive. In one study performed by Lui et al., MSI was detected in 11 out of 41 (26.8%) dysplasia samples and in 9 of 51 (17.6%) intestinal metaplasia (IM) samples respectively.²⁶ Three cases of dysplasia and one case of IM showed high MSI. Eight cases of dysplasia as well as eight cases of IM also displayed low-level MSI. No association was detected between MSI and dysplasia grade. Therefore, Lui et al. suggested that accumulation of MSI in dysplasia and intestinal metaplasia of gastric mucosa may be an early molecular event during gastric carcinogenesis and may contribute to the acquisition of transformed cell phenotype and the development of gastric cancer.

Mitochondrial MSI (mtMSI) was detected in 3 (12.5%) out of 24 patients with GD.³⁹ mtMSI-positive GD showed a poor prognosis compared to mtMSI-negative through progression to high-grade dysplasia or gastric cancer. This infers that mtMSI may be an important early event in the progression of gastric carcinogenesis, especially in intestinal-type gastric cancer.

Rugge et al. have shown that in European populations at high risk of gastric cancer, DNA repair system alterations are early molecular events in gastric carcinogenesis. They found a significant correlation between MSI phenotype and MLH1/MSH2 protein loss and suggested that immunohistochemistry should be considered as a suitable method for MSI assessment in gastric precancerous lesions.⁴⁰

We have seen a close association between the presence of MSI and expression of HER-2/neu. This may imply that impairment in the function of a repair enzyme system may provide a situation for genetic alteration and HER-2/neu overexpression. This relation has also been observed in gastric cancer by Lin et al.⁴¹

The E-cadherin mediated cell adhesion system acts as an invasive suppressor system, and tumors with reduced E-cadherin expression have a higher frequency of lymph node involvement and distant metastasis. This abnormal E-cadherin expression seems to be an early event in tumorigenesis.⁴² Abnormal expression of E-cadherin occurs in a considerable proportion of gastric carcinomas and correlates with loss of differentiation.¹⁶ In our study we found that only 2 out of 20 LD cases lacked E-cadherin expression whereas all HD showed normal expression. GD is usually from type 1 GD which is the precursor of intestinal type gastric cancer. Alterations in E-cadherin expression are mainly limited to approximately half of the diffuse type of gastric cancer. Thus it may be plausible that we can not see this abnormal expression in the majority of dysplasia cases.

There are two reports in the literature, both from China, with controversial results regarding E-cadherin expression in GD. Zhou et al. have reported abnormal (absent or cytoplasmic) expression in 16 cases of dysplastic out of 44 gastric cancers,²⁴ Zheng et al. did not observe any alteration in the expression in 23 GD.⁴³

We have examined dysplastic glands only in the biopsy specimens whereas the above mentioned researchers carried out their study on large gastrectomy specimens. Because of the heterogeneity of E-cadherin expression more investigation is needed to compare the results of endoscopic biopsy material with large tissues that are available after gastric resection.

There are no immunohistochemical or molecular assays that can stratify with certainty the risk of progression to cancer. Given the low rate of transformation of low-grade dysplasia, annual endoscopic surveillance with re-biopsy is advocated. A diagnosis of ID should also prompt endoscopic surveillance.⁴⁴ In this study we found a significant number of GD and ID that showed MSI, of which some GD were positive for HER/2-neu expression.

Immunohistochemical staining of GD biopsy cases may give some indication for closer follow up of those patients. We recommend performing additional cohort studies for assessment of these markers as predictive factors for cancer progression and the need for annual endoscopic surveillance.

ACKNOWLEDGEMENT

This work is supported in part by a grant from the Shiraz Institute of Cancer Research. The ethical issue of this study was approved by the Dissertation Committee at Shiraz Medical School.

CONFLICT OF INTEREST

The authors declare no conflict of interest related to this work.

REFERENCES

1. Haber MH. Histologic precursors of gastrointestinal tract malignancy. *Gastroenterol Clin North Am* 2002;**31**:395-419.
2. Kim KM, Kwon MS, Hong SJ, Min KO, Seo EJ, Lee KY, et al. Genetic classification of intestinal-type and diffuse-type gastric cancers based on chromosomal loss and microsatellite instability. *Virchows Arch* 2003;**443**:491-500.
3. Fiocca R, Luinetti O, Villani L, Mastracci L, Quilici P, Grillo F, et al. Molecular mechanisms involved in the pathogenesis of gastric carcinoma: interactions between genetic alterations, cellular phenotype and cancer histotype. *Hepatogastroenterology* 2001;**48**:1523-30.
4. Leung SY, Yuen ST, Chung LP, Chu KM, Chan AS, Ho JC. hMLH1 promoter methylation and lack of hMLH1 expression in sporadic gastric carcinomas with high-frequency microsatellite instability. *Cancer Res* 1999;**59**:159-64.
5. Ottini L, Palli D, Falchetti M, D'Amico C, Amorosi A, Saieva C, et al. Microsatellite instability in gastric cancer is associated with tumor location and family history in a high-risk population from Tuscany. *Cancer Res* 1997;**57**:4523-9.
6. Chiaravalli AM, Furlan D, Facco C, Tibiletti MG, Dionigi A, Casati B, et al. Immunohistochemical pattern of hMSH2/hMLH1 in familial and sporadic colorectal, gastric, endometrial and ovarian carcinomas with instability in microsatellite sequences. *Virchows Arch* 2001;**438**:39-48.
7. Lothe RA. Microsatellite instability in human solid tumors. *Mol Med Today* 1997;**3**:61-8.

8. Kolodner RD, Marsischky GT. Eukaryotic DNA mismatch repair. *Curr Opin Genet Dev* 1999;**9**:89-96.
9. Loukola A, Eklin K, Laiho P, Salovaara R, Kristo P, Järvinen H, et al. Microsatellite marker analysis in screening for hereditary nonpolyposis colorectal cancer (HNPCC). *Cancer Res* 2001;**61**:4545-9.
10. Boland CR, Thibodeau SN, Hamilton SR, Sidransky D, Eshleman JR, Burt RW, et al. A National Cancer Institute Workshop on Microsatellite Instability for cancer detection and familial predisposition: development of international criteria for the determination of microsatellite instability in colorectal cancer. *Cancer Res* 1998;**58**:5248-57.
11. Fleisher AS, Esteller M, Tamura G, Rashid A, Stine OC, Yin J, et al. Hypermethylation of the hMLH1 gene promoter is associated with microsatellite instability in early human gastric neoplasia. *Oncogene* 2001;**20**:329-35.
12. Suzuki H, Itoh F, Toyota M, Kikuchi T, Kakiuchi H, Hinoda Y, et al. Distinct methylation pattern and microsatellite instability in sporadic gastric cancer. *Int J Cancer* 1999;**83**:309-13.
13. Thibodeau SN, French AJ, Roche PC, Cunningham JM, Tester DJ, Lindor NM, et al. Altered expression of hMSH2 and hMLH1 in tumors with microsatellite instability and genetic alterations in mismatch repair genes. *Cancer Res* 1996;**56**:4836-40.
14. Marcus VA, Madlensky L, Gryfe R, Kim H, So K, Millar A, et al. Immunohistochemistry for hMLH1 and hMSH2: a practical test for DNA mismatch repair-deficient tumors. *Am J Surg Pathol* 1999;**23**:1248-55.
15. Guilford P, Hopkins J, Harraway J, McLeod M, McLeod N, Harawira P, et al. E-cadherin germline mutations in familial gastric cancer. *Nature* 1998;**392**:402-5.
16. Becker KF, Atkinson MJ, Reich U, Becker I, Nekarda H, Siewert JR, et al. E-cadherin gene mutations provide clues to diffuse type gastric carcinomas. *Cancer Res* 1994;**54**:3845-52.
17. Tamura G, Yin J, Wang S, Fleisher AS, Zou T, Abraham JM, et al. E-Cadherin gene promoter hypermethylation in primary human gastric carcinomas. *J Natl Cancer Inst* 2000;**92**:569-73.
18. Takehana T, Kunitomo K, Kono K, Kitahara F, Iizuka H, Matsumoto Y, et al. Status of c-erbB-2 in gastric adenocarcinoma: a comparative study of immunohistochemistry, fluorescence in situ hybridization and enzyme-linked immuno-sorbent assay. *Int J Cancer* 2002;**98**:833-7.
19. Lee HR, Kim JH, Uhm HD, Ahn JB, Rha SY, Cho JY, et al. Overexpression of c-ErbB-2 protein in gastric cancer by immunohistochemical stain. *Oncology* 1996;**53**:192-7.
20. Slesak B, Harlozinska A, Porebska I, Bojarowski T, Lapinska J, Rzeszutko M, et al. Expression of epidermal growth factor receptor family proteins (EGFR, c-erbB-2 and c-erbB-3) in gastric cancer and chronic gastritis. *Anticancer Res* 1998;**18**:2727-32.
21. Ohguri T, Sato Y, Koizumi W, Saigenji K, Kameya T. An immunohistochemical study of c-erbB-2 protein in gastric carcinomas and lymph-node metastases: is the c-erbB-2 protein really a prognostic indicator? *Int J Cancer* 1993;**53**:75-9.
22. Wang YL, Sheu BS, Yang HB, Lin PW, Chang YC. Overexpression of c-erbB-2 proteins in tumor and non-tumor parts of gastric adenocarcinoma--emphasis on its relation to H. pylori infection and clinicohistological characteristics. *Hepatogastroenterology* 2002;**49**:1172-6.
23. Ross JS, McKenna BJ. The HER-2/neu oncogene in tumors of the gastrointestinal tract. *Cancer Invest* 2001;**19**:554-68.
24. Zhou YN, Xu CP, Han B, Li M, Qiao L, Fang DC, et al. Expression of E-cadherin and beta-catenin in gastric carcinoma and its correlation with the clinicopathological features and patient survival. *World J Gastroenterol* 2002;**8**:987-93.
25. Li J, Zhao A, Lu Y, Wang Y. Expression of p185erbB2 and p21ras in carcinoma, dysplasia, and intestinal metaplasia of the stomach: an immunohistochemical and in situ hybridization study. *Semin Surg Oncol* 1994;**10**:95-9.
26. Liu P, Zhang XY, Shao Y, Zhang DF. Microsatellite instability in gastric cancer and pre-cancerous lesions. *World J Gastroenterol* 2005;**11**:4904-7.
27. Schlemper RJ, Riddell RH, Kato Y, Borchard F, Cooper HS, Dawsey SM, et al. The Vienna classification of gastrointestinal epithelial neoplasia. *Gut* 2000;**47**:251-5.
28. Yonemura Y, Ninomiya I, Ohoyama S, Kimura H, Yamaguchi A, Fushida S, et al. Expression of c-erbB-2 oncoprotein in gastric carcinoma. Immunoreactivity for c-erbB-2 protein is an independent indicator of poor short-term prognosis in patients with gastric carcinoma. *Cancer* 1991;**67**:2914-8.
29. Kameda T, Yasui W, Yoshida K, Tsujino T, Nakayama H, Ito M, et al. Expression of ERBB2 in human gastric carcinomas: relationship between p185ERBB2 expression and the gene amplification. *Cancer Res* 1990;**50**:8002-9.
30. García I, Vizoso F, Andicoechea A, Fernandez P, Suarez C, García-Muñoz JL, et al. C-erbB-2 oncoprotein content in gastric cancer and in adjacent mucosa. *Int J Biol Markers* 2000;**15**:231-4.
31. Lee EY, Cibull ML, Strodel WE, Haley JV. Expression of HER-2/neu oncoprotein and epidermal growth factor receptor and prognosis in gastric carcinoma. *Arch Pathol Lab Med* 1994;**118**:235-9.
32. García I, Vizoso F, Martín A, Sanz L, Abdel-Lah O, Raigoso P, et al. Clinical significance of the epidermal growth factor receptor and HER2 receptor in resectable gastric cancer. *Ann Surg Oncol* 2003;**10**:234-41.
33. Jaehne J, Urmacher C, Thaler HT, Friedlander-Klar H, Cordon-Cardo C, Meyer HJ. Expression of Her2/neu oncogene product p185 in correlation to clinicopathological and prognostic factors of gastric carcinoma. *J Cancer Res Clin Oncol* 1992;**118**:474-9.
34. David L, Seruca R, Nesland JM, Soares P, Sansonetty F, Holm R, et al. c-erbB-2 expression in primary gastric carci-

- nomas and their metastases. *Mod Pathol* 1992;**5**:384-90.
35. Nogueira AM, Carneiro F, Seruca R, Cirnes L, Veiga I, Machado JC, et al. Microsatellite instability in hyperplastic and adenomatous polyps of the stomach. *Cancer* 1999;**86**:1649-56.
 36. Fleisher AS, Esteller M, Wang S, Tamura G, Suzuki H, Yin J, et al. Hypermethylation of the hMLH1 gene promoter in human gastric cancers with microsatellite instability. *Cancer Res* 1999;**59**:1090-5.
 37. Bevilacqua RA, Simpson AJ. Methylation of the hMLH1 promoter but no hMLH1 mutations in sporadic gastric carcinomas with high-level microsatellite instability. *Int J Cancer* 2000;**87**:200-3.
 38. Bacani J, Zwingerman R, Di Nicola N, Spencer S, Wegrzynowski T, Mitchell K, et al. Tumor microsatellite instability in early onset gastric cancer. *J Mol Diagn* 2005;**7**:465-77.
 39. Jeong CW, Lee JH, Sohn SS, Ryu SW, Kim DK. Mitochondrial microsatellite instability in gastric cancer and gastric epithelial dysplasia as a precancerous lesion. *Cancer Epidemiol* 2010;**34**:323-7.
 40. Rugge M, Cassaro M, Di Mario F, Leo G, Leandro G, Russo VM, et al. The long term outcome of gastric non-invasive neoplasia. *Gut* 2003;**52**:1111-6.
 41. Lin JT, Wu MS, Shun CT, Lee WJ, Sheu JC, Wang TH. Occurrence of microsatellite instability in gastric carcinoma is associated with enhanced expression of erbB-2 oncoprotein. *Cancer Res* 1995;**55**:1428-30.
 42. Hara A, Yashima K, Yasugi A, Koda M, Kawaguchi K, Harada K, et al. Expression of Fhit, Mlh1, p16INK4A and E-cadherin in early gastric neoplasia: Correlation with histological grade and gastric phenotype. *Oncol Rep* 2007;**18**:553-9.
 43. Zheng ZH, Sun XJ, Ma MC, Hao DM, Liu YH, Sun KL. Studies of promoter methylation status and protein expression of E-cadherin gene in associated progression stages of gastric cancer. *Yi Chuan Xue Bao* 2003;**30**:103-8.
 44. Srivastava A, Lauwers GY. Gastric epithelial dysplasia: the Western perspective. *Dig Liver Dis* 2008;**40**:641-9.