

Pediatrics

Efficacy of transurethral cystolithotripsy assisted by percutaneous evacuation and the benefit of genetic analysis in a pediatric cystinuria patient with a large bladder stone

Tomoki Okada^a, Kazumi Taguchi^{a,*}, Taiki Kato^a, Shinichi Sakamoto^b, Tomohiko Ichikawa^b, Takahiro Yasui^a

^a Department of Nephro-urology, Nagoya City University Graduate School of Medical Sciences, Aichi, Japan

^b Department of Urology, Graduate School of Medicine, Chiba University, Chiba, Japan



ARTICLE INFO

Keywords:

Cystinuria

Genetic analysis

Transurethral cystolithotripsy

ABSTRACT

Cystinuria is an inherited disease, and the defective reabsorption of cysteine causes often requires operations for large urinary stones from childhood. It is rare to be diagnosed only with bladder stones and essential to select an operative procedure according to the age of the patient and the size of the stone.

We report the case of a 2-year-old boy with cystinuria diagnosed with a large bladder stone and investigate the efficacy of transurethral cystolithotripsy assisted by percutaneous evacuation. Additional genetic analysis for the entire family revealed benefit for the life-span treatment of cystinuria.

Introduction

Cystinuria is an inherited disease known for the mutations in two genes (SLC7A9 and SLC3A1), characterized by the formation of cystine stones.¹ This disease often causes serious issues in both surgical management because the stones are larger and preventative medicine because the frequency of recurrences is higher than other types of kidney stones. In this article, we report a case of pediatric cystine bladder stone treated by a novel surgical technique, transurethral cystolithotripsy (TUCL) assisted by percutaneous evacuation. Additionally, a genetic analysis was performed for the patient and his family.

Case presentation

The patient was a healthy 2-year-old boy, who was the third child of healthy parents. His parents and sisters had no history of urinary stones. He was referred to our hospital due to urinary tract infection (UTI). Urinary sediments contained over 100 leukocytes per high-power field. Blood examination showed elevated levels of C-reactive protein (23.5 mg/dL) and 20,500 leukocytes/ μ L. An abdominal X-ray image and computed tomography (CT) revealed a stone (30 mm) in the bladder (Fig. 1A, B, and C). We diagnosed the condition as UTI with a bladder

stone, and the patient was administered ceftriaxone. After explaining treatment options to his parents and obtaining their consent, we performed TUCL assisted by percutaneous evacuation.

Under general anesthesia, a 7.5 Fr nephroscope (KARL STORZ Inc., Tuttlingen, Germany) was inserted into the bladder. A percutaneous tract was created using a 14 G intravenous needle, which was inserted under ultrasound-guided direct vision from the nephroscope (Fig. 2A). Then, we performed lithotripsy with a holmium:YAG laser (Quanta System Inc., Milan, Italy), which was applied with 5–10 W. After the fragmentation, we dilated the percutaneous tract up to 9.5 Fr using a one-step dilator and placed an 8.5/9.5 Fr metal sheath (KARL STORZ Inc.) (Fig. 2B). The stone fragments were completely extracted from the tract. Finally, the 8.5/9.5 Fr metal sheath was removed, and only a urethral catheter was placed. Six days after the surgery, the urethral catheter was removed, and voiding cystourethrography was performed, which showed no vesicoureteral reflux (VUR) or urethral stricture (Fig. 3A and B).

The stone was composed of cystine, and the patient's 24-h urine collection results revealed that the urinary concentration of cystine was 538.8 μ mol/day. Thus, a diagnosis of cystinuria was established.

Thereafter, we collected urine samples from his family for 24 hours. The results of urinary cystine concentration in the father, mother, eldest

* Corresponding author. Department of Nephro-urology, Nagoya City University Graduate School of Medical Sciences, 1 Kawasumi, Mizuho-cho, Mizuho-ku, Nagoya, 467-8601, Japan.

E-mail address: ktaguchi@med.nagoya-cu.ac.jp (K. Taguchi).

<https://doi.org/10.1016/j.eucr.2020.101473>

Received 1 October 2020; Accepted 28 October 2020

Available online 28 October 2020

2214-4420/© 2020 The Authors.

Published by Elsevier Inc.

This is an open access article under the CC BY-NC-ND license

(<http://creativecommons.org/licenses/by-nc-nd/4.0/>).

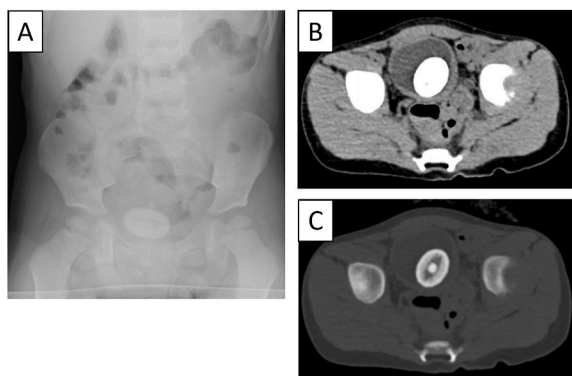


Fig. 1. Preoperative abdominal X-ray (A) and computed tomography (B) show a bladder stone (30 mm).

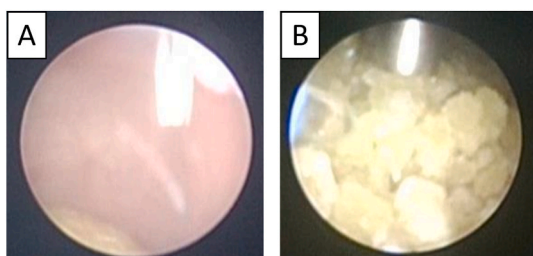


Fig. 2. Intraoperative pictures of the transurethral cystolithotripsy combined with cystostomy. (A) Pre-lithotripsy with 14 G intravenous catheter. (B) Post-lithotripsy with 8.5/9.5 Fr sheath.

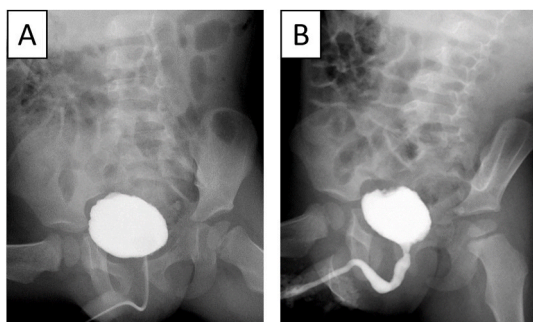


Fig. 3. Postoperative voiding cystourethrography shows (A) no vesicoureteral reflux and (B) no urethral stricture.

daughter, and second daughter were 517.3, 506.9, 22.4, and 14.6 $\mu\text{mol}/\text{day}$, respectively. Given that his parents had high urinary cystine concentrations, genetic analysis was performed for the patient and his family. The patient had a c.1533C > T (P482L) homozygous mutation on chromosome 19. His parents had the same mutation but were heterozygous, whereas his sisters had no such mutation.

Discussion

Cystinuria is characterized by the defective reabsorption of cysteine, lysine, ornithine, and arginine in the brush border membrane of the proximal renal tubule and in the epithelial cells of the gastrointestinal tract and is caused by mutations in two genes, SLC3A1 and SLC7A9. Recurring urinary stones with high cystine concentration are formed in this disease, which accounts for 6%–8% of all urinary stones in children.¹

In general, bladder stone formation in children starts with poor nutrition and frequent UTI secondary to high-grade VUR.² Primary

bladder stones have almost disappeared in developed countries owing to increased access to a balanced diet.² In our case, neither nutritional nor anatomical abnormalities including VUR were found to be the primary cause of the bladder stone. Interestingly, a retrospective image screening revealed a 1 cm renal pelvic stone in an ultrasound image taken 2 months before the patient visited our clinic; we then found a 3 cm bladder stone with a nucleus of 1 cm using abdominal radiography and CT (Fig. 1C). Therefore, we speculated that the urinary stone formed in the kidney due to cystinuria had reached the bladder and grown without being excreted. Previous research has indicated that the size of the urethra is relatively small compared with that of the ureter in children,³ suggesting that our patient might have had some difficulty passing the bladder stone through his urethra.

Surgical operations applicable for children with bladder stones are open cystolithotomy (CL), percutaneous cystolithotripsy (PCCL), and TUCL.⁴ CL is a technique that has been used for a long time; it can be performed on any stone and allows for easy collection of stones. On the other hand, PCCL and TUCL, which require a significantly shorter hospital stay compared to that for CL, had become alternative methods to CL in the last few decades. However, prior studies reported that post-operative complications such as paralytic ileus and abdominal distention owing to the escape of irrigating fluid into the abdominal cavity increased with the percutaneous approach. Additionally, the application of a transurethral approach is sometimes limited in children with a narrow urethra. In this case, TUCL assisted by percutaneous evacuation could be safely performed with percutaneous access under the endoscopic vision and allowed for a more efficient collection of fragments compared with either treatment. Thus, this technique is applicable to a wider range of stone sizes, and therefore, we believe that it is an effective surgical procedure for pediatric bladder stones.

We also examined genetic mutations in this patient as well as his family members. In a cohort of Japanese cystinuria patients, the c.1533C > T (P482L) mutation in SLC7A9 was present in over 80% of the cases.⁵ In this case, the patient and his parents had a homozygous and heterozygous P482L mutation, respectively. On the other hand, his sisters had no such mutation, suggesting that they had no risk of developing cystinuria. However, the patient and the parents required close follow-up and were recommended increased fluid intake, since the heterozygous P482L mutation has been reported to be a risk of stone formation.⁵

Conclusion

TUCL assisted by percutaneous evacuation is an effective procedure for large pediatric bladder stones. We can obtain useful information for onset prevention and early diagnosis by genetic analysis of patients with cystinuria and their families.

Funding

This research did not receive any specific grant from funding agencies in the public, commercial, or not-for-profit sectors.

Declaration of competing interest

None.

References

- Saravakos P, Kokkinou V, Giannatos E. Cystinuria: current diagnosis and management. *Urology*. 2014;83:693–699. <https://doi.org/10.1016/j.urology.2013.10.013>.
- Rizvi SAH, Naqvi SAA, Hussain Z, et al. Pediatric urolithiasis: developing nation perspectives. *J Urol*. 2002;168:1522–1525. <https://doi.org/10.1097/01.ju.0000028601.63446.51>.

3. Orkiszewski M, Madej J. The meatal/urethral width in healthy uncircumcised boys. *J Pediatr Urol.* 2010;6:130–133. <https://doi.org/10.1016/j.jpuro.2009.07.007>.
4. Donaldson JF, Ruhayel Y, Skolarikos A, et al. Treatment of bladder stones in adults and children: a systematic review and meta-analysis on behalf of the European Association of Urology Urolithiasis Guideline Panel. *Eur Urol.* 2019;76:352–367. <https://doi.org/10.1016/j.eururo.2019.06.018>.
5. Shigeta Y, Kanai Y, Chairoungdua A, et al. A novel missense mutation of SLC7A9 frequent in Japanese cystinuria cases affecting the C-terminus of the transporter. *Kidney Int.* 2006;69:1198–1206. <https://doi.org/10.1038/sj.ki.5000241>.