

Cutaneous Eruptions in the Course of COVID-19 Among Geriatric Patients in a Nursing Home in Poland

Joanna Rybak-d'Obyrn¹, Waldemar Placek¹, Agnieszka Owczarczyk-Saczonek¹,
Maria Derkaczew¹, Ewelina Joniec¹, Robert Hofman¹, Małgorzata Stompór²

¹Department of Dermatology, Sexually Transmitted Diseases and Clinical Immunology, Collegium Medicum, University of Warmia and Mazury, Olsztyn, Poland; ²Department of Family Medicine and Infectious Diseases, Collegium Medicum, University of Warmia and Mazury, Olsztyn, Poland

Correspondence: Maria Derkaczew, Tel +48 607654914, Email m.derkaczew@gmail.com

Purpose: The aim of this study was to assess the incidence and characteristics of COVID-19 cutaneous manifestations among geriatric patients infected with the SARS-CoV-2 virus.

Patients and Methods: Sixty-four nursing home residents in Dobre Miasto, Poland (mean age: 79 years) infected with SARS-CoV-2 were monitored for skin lesions during the epidemic outbreak in 2020. Only five of them presented COVID-19 dermatological manifestation: vesicular (4 cases) and erythematous (1 case) skin lesions, which appeared after the remaining symptoms of the disease had resolved.

Results: The average time between COVID-19 onset and cutaneous manifestation was 22 days. Skin lesions persisted in five cases 112, 17, 21, 19 and 27 days, respectively, and were often accompanied by pruritus and neuropathic pain.

Conclusion: Skin manifestations of SARS-CoV-2 infection might be misdiagnosed or overlooked, particularly among elderly patients with chronic diseases. The recognition of skin lesions due to COVID-19 might improve patients' quality of life by reducing the intensity of symptoms such as pruritus or neuropathic pain.

Keywords: geriatrics, dermatology, skin manifestation, vesicular

Introduction

COVID-19 (coronavirus disease 2019) is a viral disease caused by SARS-CoV-2 (severe acute respiratory syndrome coronavirus 2).¹ The first cases of COVID-19 were reported in 2019, whereas at the end of February 2022 the number of confirmed SARS-CoV-2 infections worldwide exceeded 430 million, with more than 5.9 million deaths due to COVID-19.² The initial symptoms relate to the respiratory system and include fever, cough and dyspnea, followed by hematological, gastroenterological, cardiological, nephrological, neurological, psychiatric and dermatological disorders.³ Older adults are particularly vulnerable to being exposed to coronavirus infection, and due to multimorbidity, their risk of complications and death in the course of COVID-19 increases.² The pathophysiology of the disease is multifactorial: association with the immune response, hypercoagulability state, monocytic/macrophage activation syndrome, culminating in exaggerated cytokine secretion, called "cytokine storm". Excessive activation of inflammatory mediator creation is considered a cause of damage to the endothelium; hypercoagulability leads to multiple thromboses in the microvasculature of the skin; changes in the cellular component of immunity with activation of the complement system, as well as the possibility of direct entry of SARS-CoV-2 via receptor ACE2 (angiotensin-converting enzyme 2) and protease TMPRSS2 (transmembrane serine protease 2) in the human endothelial cell in dermal blood vessels cannot be excluded such as possible mechanisms of skin lesions forming. The cutaneous lesions might be polymorphic and include six main patterns: maculopapular skin eruptions, chilblain-like acral pattern, urticarial rash, vesicular (varicella-like), livedo reticularis and vascular (purpuric "vasculitic") changes.^{4,5} Data from China at the beginning of the pandemic estimated

the prevalence of dermatological manifestations of COVID-19 as 0.2%. It is currently considered that skin eruptions appear in 5–20% of the patients.^{6–11} This number might be underestimated due to difficulties in detailed physical examinations as a result of the short time of contact between the doctor and an infectious patient and the increasing number of patients who receive telehealth services without physical examination of the patient.⁵ Older adults, due to common functional impairment, are even less often examined by physicians. The aim of this study was to estimate the occurrence of skin eruptions in the course of COVID-19 among geriatric patients in a nursing home.

Materials and Methods

The residents of the Nursing Home in Dobre Miasto, Poland with COVID-19 were followed during an epidemic outbreak in December 2020 for six months after the COVID-19 outbreak. The patients were observed from November 2020 to April 2021. Out of 64 patients, five of them presented skin changes. The skin condition of the patients was documented regularly in the care process by the nursing home staff – apart from three cases of bedsores immediately before or during the outbreak, no new skin lesions were observed, except for five presented cases. None of the patients had allergic cutaneous manifestations in their medical records or drug allergies. None of the residents had previously experienced the SARS-CoV-2 infection, and none had taken the coronavirus serological tests prior to the infection. The patients were not vaccinated – there were no vaccinations available at that time, and there were no symptoms of COVID observed among patients from January to November 2020. The SARS-CoV-2 infection in December 2020 was confirmed by RT-PCR (real-time reverse transcription polymerase chain reaction) detection of viral RNA in nasopharyngeal swabs. Among three patients with varicella-like skin lesions, Varicella zoster virus (VZV) etiology was excluded by negative results of a VZV IgM antibodies blood test. Other infectious backgrounds such as scabies were excluded (absence of characteristic skin lesions and typical onset and the absence of the mite or mite eggs or fecal matter (scybala), according to Centers for Disease Control and Prevention recommendation). The course of COVID-19 and patient treatment were documented by a review of patient records. The pain level assessment as an element of usual care in a nursing home was performed, and among patients reporting neuropathic pain symptoms (burning, tingling, pins and needles, itching, hyperesthesia to touch), the probability of neuropathic origin was established using a DN4 Questionnaire (Douleur Neuropathique 4 Questions), where a score of 4 or more points made neuropathic pain possible. All patients gave their informed consent to this study.

Case 1

A 91-year-old woman with Alzheimer's disease, hypertension, hypercholesterolemia and a history of ischemic stroke with no prior skin conditions was diagnosed with a moderate course of COVID-19 (symptoms: dry cough, fever, anorexia) without changes in arterial blood oxygen saturation. The patient was treated with metamizole, enoxaparin, amikacin and amoxicillin with clavulanic acid. Thirty-two days after a positive RT-PCR SARS-CoV-2 test result and 18 days after the COVID-19 symptoms had disappeared, multiple vesicles filled with serous content appeared on the skin of the chest, back, arms, elbows, axillae, shoulders and knees. Vesicles subsequently developed into erosions covered with scabs, and excoriations were visible. At the region of the elbows and knees, larger erythematous-exfoliative lesions were observed. The day before the appearance of the lesions, an intense generalized neuropathic body pain occurred (a score of 4 points on a DN4 Questionnaire), which lasted for about a month, and the skin lesions were severely painful and itchy. Varicella zoster virus etiology was excluded. Treatment included fexofenadine and topical diflucortolone valerate with gradual remission of lesions. For pain treatment, gabapentin and buprenorphine transdermal system were introduced. The skin lesions persisted for 112 days until the patient died of another cause. The timeline is presented in [Figure 1](#).

Case 2

An 81-year-old woman with generalized atherosclerosis, vascular dementia with a history of ischemic stroke with no prior skin conditions, was under observation due to mild clinical presentation of COVID-19 (symptoms: weakness and anorexia) without changes in arterial blood oxygen saturation. The patient was treated with enoxaparin. Eighteen days after the positive RT-PCR SARS-CoV-2 test result and eight days after the COVID-19 symptoms had resolved, numerous vesicles of various sizes, filled with serous content, appeared on the skin of the chest, back and upper limbs, axillae and

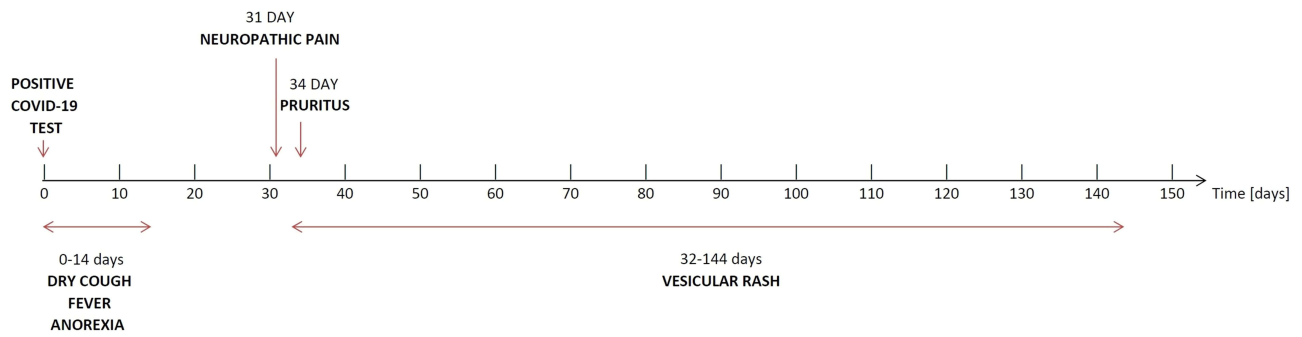


Figure 1 Timeline showing the most significant events in Case 1.

shoulders on an inflammatory background, from which erosions were covered with a subsequently formed scab. The skin lesions were very itchy. The etiology of Varicella zoster virus was excluded. Fexofenadine and topical emollients were used in the treatment. The symptoms lasted 21 days. The timeline is presented in [Figure 2](#).

Case 3

A 79-year-old man with Parkinson’s disease, a history of ischemic stroke and grade 4/5 decubitus ulcer on the right heel and no other prior skin conditions was diagnosed with a moderate course of COVID-19 (symptoms: fever, cough), without changes in arterial blood oxygen saturation. The patient was treated with paracetamol, enoxaparin and ceftriaxone. Twenty-two days after a positive SARS-CoV-2 RT-PCR test result and eight days after the resolution of COVID-19 symptoms, erythema appeared on the skin of the arms and forearms and on the abdomen, forming vesicles filled with serous content, subsequently evolving into erosions covered with a scab. No treatment except emollients was administered due to the lack of complaints. Skin lesions persisted for 17 days. The timeline is presented in [Figure 3](#).

Case 4

A 95-year-old woman with advanced Alzheimer’s disease and permanent atrial fibrillation on chronic anticoagulant therapy with acenocoumarol was under observation due to mild clinical presentation of COVID-19 (symptoms: weakness, anorexia)

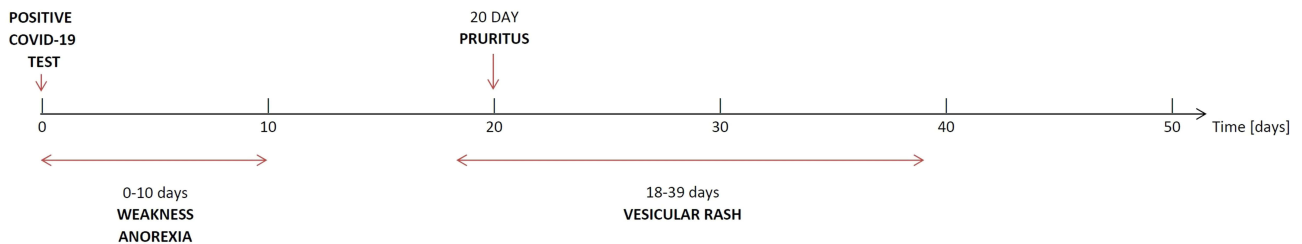


Figure 2 Timeline showing the most significant events in Case 2.

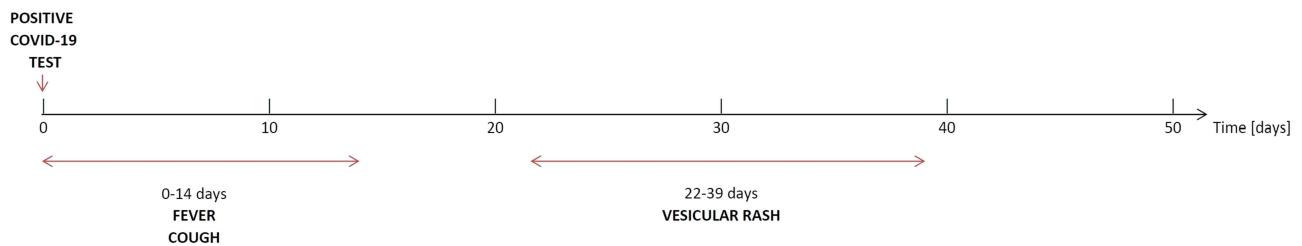


Figure 3 Timeline showing the most significant events in Case 3.

without changes in arterial blood oxygen saturation. One month before the infection, there were rosacea-like lesions observed on the skin of the nose and cheeks, which were successfully treated with topical metronidazole. Nineteen days after a positive RT-PCR SARS-CoV-2 test result and nine days after the COVID-19 symptoms had resolved, small non-pruritic clustered serous vesicles appeared on the skin of the left side of the chest, under the right breast and on the left side of the perineum on the unchanged skin followed by scab-covered erosions and post-inflammatory scaling. The day before the appearance of the skin lesions, the patient was suffering from severe neuropathic body pain and weakness (4 points in DN4 Questionnaire – Douleur Neuropathique 4 Questions), which lasted for five days. Varicella zoster virus infection was excluded. Topical diflucortolone valerate and emollients were applied as well as tramadol and pregabalin were used for pain treatment. The eruptions lasted 19 days. The timeline is presented in Figure 4.

Case 5

A 90-year-old woman with dementia, hypertension, hypercholesterolemia and no prior skin conditions was diagnosed and observed with mild clinical presentation of COVID-19 (symptoms: sub-febrile state, weakness, anorexia), without changes in arterial blood oxygen saturation. The patient was treated with enoxaparin and amoxicillin with clavulanic acid. Seventeen days after a positive RT-PCR SARS-CoV-2 test result and five days after the COVID-19 symptoms had resolved, well-demarcated erythematous-exfoliative lesions appeared on the skin in the breast area, subpectoral area, axillae, shoulders and on the parietal parts of the lower limbs, which were not very extensive. The patient complained of weakness and pruritus and was treated with topical hydrocortisone acetate and emollients. The skin lesions lasted 27 days. The timeline is presented in Figure 5.

Photographs of skin manifestations are presented in Figure 6.

Results

The five cases of patients with COVID-19 skin manifestation described above represent 7.81% of all patients with confirmed SARS-CoV-2 infection. The mean age of all infected patients was 79 years; the mean age of patients with skin lesions was 87.2 years. The group of patients with confirmed infection included 13 men and 51 women, and among those with skin lesions were one man and four women. The COVID-19 cutaneous manifestation started after the remaining symptoms of COVID-19 infection had resolved (on average 9.6 days after) and on average 21.6 days after receiving a positive SARS-CoV-2 RT-PCR test result. Skin lesions persisted, respectively, for 112, 17, 19, 21 and 27 days and were

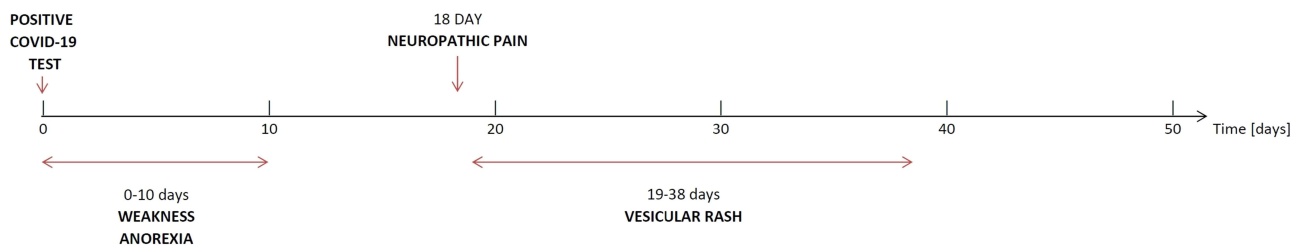


Figure 4 Timeline showing the most significant events in Case 4.

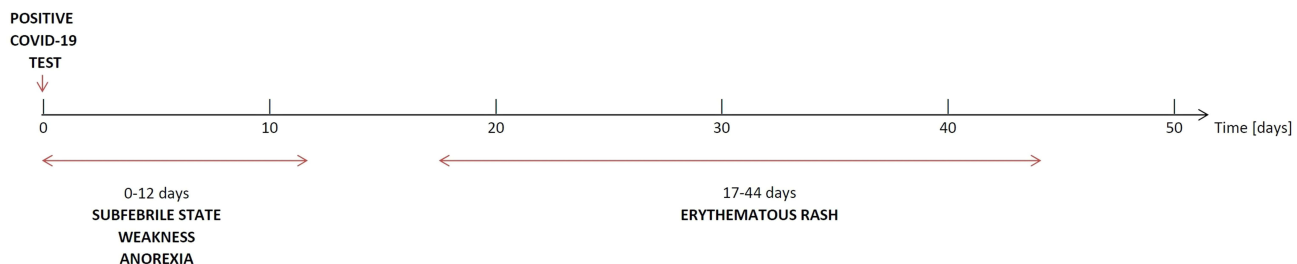


Figure 5 Timeline showing the most significant events in Case 5.

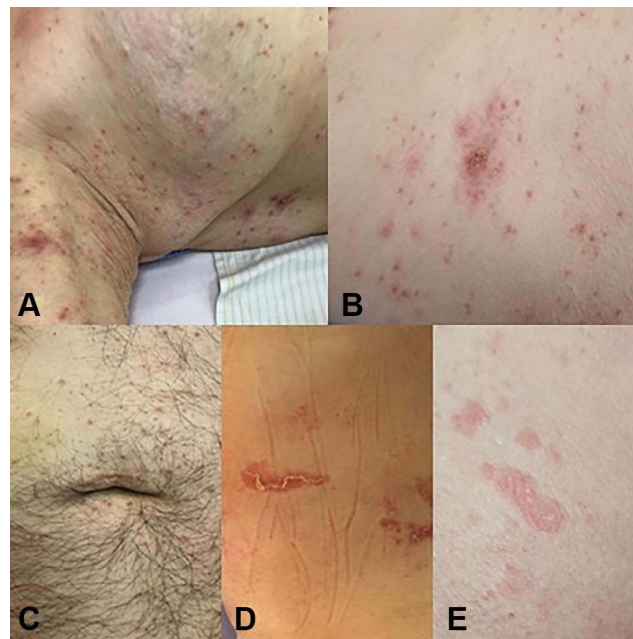


Figure 6 Photographs of skin manifestations in presented cases (A) Case 1; (B) Case 2; (C) Case 3; (D) Case 4; (E) Case 5.

often accompanied by pruritus and neuropathic pain. The characteristics of cutaneous manifestations, infection and treatment are shown in [Table 1](#).

Discussion

The Prevalence of Skin Changes

Reports concerning the prevalence of skin changes associated with SARS-CoV-2 infection show huge variability. In a study published in February 2020 based on data from more than 1000 patients in China, the prevalence of skin changes was estimated at 0.2%, although in a paper published in March 2020, COVID-19 skin manifestations were noted among 20.4% of patients from Lombardia.^{8,12} The newest meta-analysis of 43 publications concerning almost 1850 cases of COVID-19 showed the occurrence of skin lesions in 5.95% of patients.⁹ Among all residents of the nursing home in Dobre Miasto with confirmed SARS-CoV-2 infection, skin changes were observed in 7.81% of patients with a mild to moderate course of COVID-19.

Covid-19 Skin Manifestation Pattern and Patient Age

The classification provided by Galván Casas et al includes chilblain, vesicular, urticaria-like, maculopapular/erythematous skin eruptions and livedo reticularis/necrosis.⁶ Jamshidi et al also highlighted the presence of changes which they named vascular eruptions (ecchymosis, purpura, livedo or necrosis) and others that cannot be assigned to either of these groups.⁹ Freeman et al subdivided maculopapular/erythematous changes into macular erythema, morbilliform exanths and papulosquamous lesions.¹³ According to Galván Casas et al, the most frequent skin eruptions in the general population are: maculopapular (47%), less often urticaria-like (19%) and chilblain (19%), vesicular (9%) and livedo reticularis/necrotic changes (6%);⁶ similar results were reported by Zhao et al.¹¹ Studies of the frequency and character of skin lesions in the course of COVID-19 among patients older than 60 years of age are scarce, and their results are inconsistent. In a meta-analysis published by Jamshidi, it was shown that among the elderly, the most common were vascular lesions (mean age 72.3 years), although in a review by Jindal et al, patients in their sixties mostly presented vesicular and pseudo-chilblain lesions.^{9,14} Galván Casas et al reported common changes such as livedo reticularis in older patients.⁶ According to Muhammad et al, an association between old age and more frequent occurrence of ecchymosis, maculopapular exanthem and vesiculo-bullous rash was observed.¹⁵

Table 1 Characteristics of Cutaneous Manifestations, Infection and Treatment in Presented Cases

Characteristic	Case 1	Case 2	Case 3	Case 4	Case 5
Age (years)	91	81	79	95	90
Skin lesions	Vesicular	Vesicular	Vesicular	Vesicular	Erythematous
Associated symptoms	Neuropathic pain, intense itching	Intense itching	Not reported	Neuropathic pain	Itching
Skin lesions and associated symptoms treatment	Fexofenadine, topical diflucortolone valerate, gabapentin, buprenorphine transdermal system	Fexofenadine and topical emollients	Topical emollients	Topical diflucortolone valerate, emollients, tramadol, pregabalin	Topical hydrocortisone acetate and emollients
Skin lesions duration (days)	112	21	17	19	27
Timing after testing positive for COVID-19 (days)	32	18	22	19	17
Timing after the resolution of COVID-19 symptoms (days)	18	8	8	9	5
COVID-19 severity	Moderate	Mild	Moderate	Mild	Mild
COVID-19 symptoms	Dry cough, fever, anorexia	Weakness and anorexia	Fever, initially dry then productive cough	Weakness and anorexia	Subfebrile state, weakness, anorexia
COVID-19 treatment	Metamizole, enoxaparin, amikacin and amoxicillin with clavulanic acid	Enoxaparin	Paracetamol, enoxaparin and ceftriaxone	Acenocoumarol	Enoxaparin and amoxicillin with clavulanic acid

Abbreviation: COVID-19, coronavirus disease 2019.

The cutaneous manifestations of COVID-19 in the four out of five cases presented in this article were vesicular (80%). This type of lesions was first described as “varicella-like” by Marzano et al. However, the mild clinical features of these papulovesicular lesions, such as trunk involvement, little or no pruritus, and absence of mucosal lesions, distinguished this condition from chickenpox. Marzano et al established the prevalence of varicella-like eruptions in up to 54.5% of patients with COVID-19 skin changes in Spain, although according to other studies, it ranges from only 4% to 12.5% of all dermatoses in COVID-19.^{6,8,10,16,17} In the present study, the patients with vesicular lesions were much older than those described in the available literature, ie, 79–95 years, with a mean age of 86.5 years. Marzano et al reported that vesicular lesions occurred in patients at an average age of 60 years,¹⁷ but Fernandez-Nieto et al reported this type of lesions occurring in approximately 40-year old.¹⁸ The authors analyzed 24 cases of vesicular eruptions in COVID-19 and found that they occur in two forms: localized, monomorphic, on the trunk (25% of patients) and disseminated (75% of patients) - polymorphic, with papules or pustules appearing simultaneously with the vesicles, with the most common locations on the anterior and posterior surfaces of the trunk, followed by the extremities.¹⁸ Four patients in Dobre Miasto presented disseminated vesicular lesions which then developed into erosions covered with scabs, located mainly on the trunk and extremities. The skin eruptions in the fifth presented case were erythematous. This pattern was reported in the literature as one of the most common COVID-19 skin manifestations (particularly including macular erythema, morbilliform exanthems and papulosquamous lesions), predominantly localized on the trunk and limbs, being associated with pruritus in most cases.^{6,11,13}

Covid-19 Infection Symptoms and Duration

All of the presented patients suffered from mild to moderate COVID-19, which is consistent with other reports.^{7,17,18} According to results of Freeman et al, the most common symptoms of COVID-19 accompanied by vesicular rash were fever (72%) and cough (61%), sore throat (50%), headache (33%), apathy (33%), irritability (33%), pruritus of skin lesions (68–83%) and pain (in 9–50% of patients).^{13,17,18} Among residents from Dobre Miasto, the most common COVID-19 symptoms accompanying skin manifestations were cough, fever, weakness and anorexia. Two patients presented pruritus of the skin, one patient suffered from the pain of skin lesions and two patients suffered from generalized pain of neuropathic origin, requiring the use of strong analgesics, including opioids. It is worth noting that this type of pain in the course of COVID-19 infection was present only among patients with skin changes.

The duration of lesions reported in the literature ranges from 4 to 22 days (on average: 10 days), and in the majority of patients (79.2%), vesicles appeared after the resolution of COVID-19 symptoms, rarely simultaneously or in the prodromal phase of infection.^{9,18} In the present study, among patients with vesicular eruptions, skin lesions appeared on average 21.6 days after receiving a positive SARS-CoV-2 RT-PCR test result and 9.6 days after the symptoms of COVID-19 infection had resolved, which is not consistent with the results of other authors. Moreover, the duration of lesions in the present study among patients with vesical changes was much longer than in the available literature. Other studies have shown that the duration of skin lesions was about nine days (ranging from 1 to 18 days).⁹ Among patients in the Dobre Miasto nursing home, the duration of skin lesions was 112, 17, 21, 19 days, respectively (on average, 42 days). It is unclear why such a difference in skin lesion duration was observed among the elderly patients – it might have been a co-infection or activation of other mechanisms listed below. For the fifth woman (with erythema), skin symptoms started five days after the COVID-19 symptoms had resolved and lasted 27 days.

The Pathogenesis of Skin Changes

There is currently a discussion among researchers –about whether SARS-CoV-2 virus influences the skin directly or indirectly.^{19–21} It is possible that in certain patterns of skin exanthems, some mechanisms may prevail.

The first well-documented pathomechanism is related to hyperinflammation, ie, excessive activation of inflammatory mediators such as cytokine storm - sharp elevation of interleukin (IL)1, IL2, IL-6, IL7, IL10), granulocyte colony-stimulating factor (G-CSF), tumor necrosis factor (TNF) α and interferon (IFN)- γ . Hyperviremia and increased cytokines stimulate various cells in the skin, including lymphocytes, dendritic cells, macrophages, neutrophils, monocytes, and Langerhans cells and cause various skin manifestations. SARS-CoV-2 invasion activates cellular immunity components with activation of the complement system, which is considered a cause of damage to the endothelium and vasculitis (vascular lesions). Moreover, activation of the complement system can lead to mast cell degranulation (urticaria-like lesions). Type I interferons cause the immune response and thrombotic microangiopathy by a dose-dependent toxic effect on the microvasculature (chilblain lesions); another mechanism of multiple thromboses in the microvasculature of the skin formation is hypercoagulability (also chilblain-like or vascular lesions). The direct entry of SARS-CoV-2 via receptor ACE2 and protease TMPRSS2 in the human endothelial cell in dermal blood vessels also cannot be excluded, such as possible mechanism of skin lesions forming.^{4,5,9}

Moreover, because of the dysregulation of the immune system, COVID-19 patients are also susceptible to co-infection *de novo* or relapse of other viral exanthems, as proposed by Jamshidi et al (one study reported four COVID-19 patients presenting vesicular lesions, which microbiological and serological investigations demonstrated as being varicella infections).^{9,22} The presence of parasites can also favor the appearance of skin lesions, as they very often transmit viral infections (the mites *Sarcoptes scabiei*, *Demodex folliculorum*).^{9,23,24} According to the literature, the hypothesis of co-infection is strongly suggested for vesicular lesions due to their unique histological findings compared to other skin lesions of COVID-19. Unfortunately, in the presented cases, there was no access to histopathological examinations, and among backgrounds other than coronavirus infections only scabies and VZV were excluded. Nevertheless, there might have been the possibility of co-infection with other viruses such as parvovirus 18, herpes simplex virus type 1 and 2 (HSV-1, HSV-2) and poxviruses. The symptoms of these infections might be similar.^{10,22,23} This may be an explanation for such a long time of persistent skin symptoms at present study. This might also be the case

of the fifth presented patient with erythematous and exfoliative skin lesions. They may resemble pityriasis rosea (PR), Grover's disease, erythema multiforme and others.^{6,8,25–27} Dursun et al observed a fivefold increase in the number of PR cases during the SARS-CoV-2 pandemic, which may indicate reactivation of Human Herpesvirus (HHV), Epstein-Barr virus or the consequence of emotional stress during SARS-CoV-2 infection.¹⁹ Only a few case reports of PR in the course of COVID-19 with an asymptomatic or a mild course in patients aged 12–54 years have been published. The duration of the lesions ranged from 2 to 4 weeks. Pruritus as a common symptom was also present among these patients (approximately 75%).^{20,25,28–32} The nursing home resident with mild COVID-19 symptoms also complained of skin pruritus, which required topical treatment. The duration of the lesions was quite long (27 days), as in the cited literature, while the patient's age was more advanced than in the previously described cases. The hypothesis of co-infection might contribute to differential diagnosis performance if it could lead to an improved treatment plan.

In considering possible causes, many researchers, eg, Tatu et al, wondered why skin lesions appear only in a certain subset of patients. One of the hypotheses is that skin changes happen in areas of already susceptible skin, previously affected by a cutaneous lesion that created a *locus minoris resistentiae*, which underlies the Wolf's isotopic response, or Koebner type V phenomenon (mostly vesicular lesion formations).²³ Prior inflammation of the skin (eg, in previously healed zoster lesions) may cause a local susceptibility for SARS-CoV-2 invasion by causing upregulation of ACE2 receptor expression within basal epidermal cells. This mechanism of lesion formation is usually connected with trauma (eg, the scratching of itchy skin lesions).²³

There is also the potential for autoimmune complications of COVID-19.³³ Acute hemolytic anemia, Kawasaki-like disease, macrophage activating syndrome, Guillain-Barre syndrome (GBS), Miller Fisher syndrome (MFS), autoimmune thrombotic thrombocytopenic purpura, etc. From the start of the outbreak, several reports appeared on the autoimmune skin manifestations of COVID-19 infection. The production of autoantibodies following a viral infection that potentially leads to tissue injury (cross-reaction) is the suggested mechanism based on the concept of type II hypersensitivity. Regarding type IV hypersensitivity, it is suggested that T cells activated against the virus might damage the self-tissues by conducting an inflammatory environment or directly attacking the cells.³³

Adverse drug reactions as well may be related to skin eruption occurrence.³⁴ COVID-19 patients usually use medications that potentially can cause cutaneous rashes (for example, paracetamol has been reported to cause asymmetrical drug-related exanthema, azithromycin could be the cause of maculopapular lesions as a hypersensitivity reaction to azithromycin due to concurrent viral infection; hydroxychloroquine is one of the most likely medications to cause different skin rashes)^{9,34}. Moreover, many patients, particularly the elderly, are under chronic treatment with multiple drugs due to multimorbidity. Some drugs, such as beta-blockers, may have the potential to create a local susceptibility to viral eruptions themselves.³⁵ Among patients in nursing home, the long interval between COVID-19 treatment (antibiotics, paracetamol) and the occurrence of skin lesions make the possibility of toxicoderma less probable, but possible patient medication – SARS-CoV-2 interactions cannot be excluded.

Another possibility is that the skin changes among COVID-19 patients could be the result of an exacerbation of chronic skin diseases, or SARS-CoV-2 may trigger the onset of skin disease.³⁶ Reports from Turkey and the United States suggest that COVID-19 may exacerbate or trigger psoriasis.^{37,38} It is also interesting that Patric et al found that skin conditions (including psoriasis, atopic dermatitis, and cutaneous lupus) are associated with increased COVID-19 risk. There are shared components between these skin conditions and COVID-19 hyperinflammation and autoimmune response.³⁹ Moreover, patients face a possible worsening of chronic skin inflammatory conditions due to difficulty in accessing health care and treatment discontinuation.⁴⁰ Another trigger responsible for chronic skin disease exacerbation might be reduced physical activity due to temporary restrictions and increasing body weight or even obesity. Excess body weight and percentage of fat lead to hypertrophy of adipocytes which promotes the release of interleukin-6 and tumor necrosis factor- α , which may cause an exacerbation of chronic skin inflammatory conditions such as psoriasis or hidradenitis suppurativa.⁴⁰ For patients from a nursing home, except for rosacea and pressure ulcers, there were no previously observed chronic skin conditions.

There is evidence that not only the SARS-CoV-2 infection itself but also the COVID-19 vaccines can cause a variety of skin reactions. In the review article, Gambichler et al provide an overview of cutaneous findings related to vaccination starting from non-specific injection-site reactions, through type I hypersensitivity reactions (eg, urticaria, angio-oedema

and anaphylaxis), type IV hypersensitivity (“COVID arm”), inflammatory reactions in dermal filler or previous radiation sites or even BCG scars, to more common morbilliform and erythema multiforme-like rashes.⁴¹ Autoimmune-mediated skin findings after COVID-19 vaccination include leucocytoclastic vasculitis, lupus erythematosus and immune thrombocytopenia, functional angiopathies (chilblain-like lesions, erythromelalgia) as well as pityriasis rosea-like rashes and reactivation of herpes zoster. Molecular mimicry between SARS-CoV-2 and human components may explain some adverse skin reactions to COVID-19 vaccinations.⁴¹ Patients in the nursing home in the current study were not vaccinated because there were no vaccinations available at that time.

The Skin Lesions and Prognosis

Various mechanisms of forming skin eruptions are also the cause of certain organ complications in the course of COVID-19. The severity of the disease followed particular skin changes. For example, Galván Casas et al found that the most severe course of the disease was in patients with livedo - reticularis presentations, as shown by the increasing percentages of pneumonia, hospital admission and intensive care treatment.⁶ Jamshidi et al, in their meta-analysis, demonstrated that a mild disease course was mainly correlated with chilblain-like and urticaria-like lesions, and patients with vascular lesions experienced a more severe disease.⁹ The overall mortality rate was 4.5%, with the highest mortality rate (18.2%) among patients with vascular lesions and the lowest (2.2%) for those with urticaria-like lesions. This is why people with diagnosed vascular lesions should be treated as high-priority patients.⁹ The reason is that vasculitis causes not only skin changes but also organ failure. Vasculitis starts as an immune response against viral antigen with the involvement of ACE2 or as a result of a cytokine storm with primarily IL-6 elevation.²³ Of all cytokines that may represent therapeutic targets, IL-6 has been regarded as particularly important in COVID-19 pathogenesis and may be antagonized by existing drugs (tocilizumab). IL-6 is mainly produced by macrophages and T lymphocytes in response to pathogens and is pivotal in controlling several viral infections. In COVID-19, since IL-6 has been positively correlated with disease stages and radiologic changes, the potential prognostic value of IL-6 has been explored regarding the need for mechanical ventilation, mortality, or both, when considered alone or in combination with other variables.^{42,43}

The Treatment of Skin Lesions and Care Management Problems

According to current recommendations, COVID-19 skin lesions do not require specific treatment. A wait-and-see approach is suggested for the treatment of vesicular skin lesions. In patients with pruritus, oral antihistamines, topical corticosteroids and emollients are recommended.²¹ In bed-ridden patients, low-molecular-weight heparins (LMWH) are used as thromboembolic prophylaxis. Among the reported patients, antihistamines and topical corticosteroids were used to reduce skin pruritus and inflammation. For pain management, opioids and gamma-aminobutyric acid (GABA) receptor agonists were introduced due to the neuropathic nature of pain. Diagnosing and treating skin manifestations accompanying COVID-19 can be a challenge in connection with changes in health-care organization during a pandemic and a reduction in face-to-face consultation. The solution might be extensive use of telemedicine.^{44–46} Tele-dermatology services use phone calls, video consultations and even the use of popular phone applications like WhatsApp. For many patients with acute or chronic skin conditions it was the only way to obtain a dermatologist’s advice.

Conclusion

Exanthema associated with SARS-CoV-2 infection is still frequently missed by doctors or incorrectly diagnosed as other diseases, eg, viral, allergic, parasitic or erythematous, especially among older adults in whom various skin changes may be the symptom of other chronic diseases. In the current study, the patients with skin changes were much older than in previous reports, with coexisting multimorbidity, and the prevalence of skin lesions seems to be higher than in the available literature, where it might have been underestimated. The recognition and treating of skin changes in the course of COVID-19 and accompanying symptoms such as pruritus and pain may improve patients’ quality of life by not applying unnecessary diagnostic procedures and implementing effective treatment to reduce the intensity of the symptoms. The use of some systemic or topical medicaments helps to reduce symptoms such as a sensation of itching and burning, particularly among patients who, due to age, advanced disease or psychiatric condition, are often unable to describe their complaints comprehensively.

Abbreviations

COVID-19, coronavirus disease 2019; SARS-CoV-2, severe acute respiratory syndrome coronavirus 2; ACE2, angiotensin-converting enzyme 2; TMPRSS2, transmembrane serine protease 2; RT-PCR, real-time reverse transcription polymerase chain reaction; VZV, varicella zoster virus; DN4 Questionnaire, Douleur Neuropathique 4 Questions; HHV, Human Herpesvirus; LMWH, low-molecular-weight heparins.

Ethical Approval

The study was conducted in accordance with the Declaration of Helsinki. This study was approved by the Ethics Committee of the Warmia and Mazury Medical Chamber in Olsztyn (WMIL-KB/37/2022).

Informed Consent for Publication

Written and informed consent for publication of the cases was obtained from all patients.

Funding

This paper was not funded.

Disclosure

The authors report no conflicts of interest in this work.

References

1. Gorbalenya AE, Baker SC, Baric RS, et al. Severe acute respiratory syndrome-related coronavirus: the species and its viruses – a statement of the coronavirus study group. *Microbiology*. 2020. doi:10.1101/2020.02.07.937862
2. World Health Organization. Coronavirus (COVID-19) Dashboard. Available from: <https://covid19.who.int>. Accessed February 26, 2022.
3. AlSamman M, Caggiula A, Ganguli S, Misak M, Pourmand A. Non-respiratory presentations of COVID-19, a clinical review. *Am J Emerg Med*. 2020;38(11):2444–2454. doi:10.1016/j.ajem.2020.09.054
4. Singh H, Kaur H, Singh K, Sen CK. Cutaneous manifestations of COVID-19: a systematic review. *Adv Wound Care*. 2021;10(2):51–80. doi:10.1089/wound.2020.1309
5. Criado PR, Abdalla BMZ, de Assis IC, van Blaricum de Graaff Mello C, Caputo GC, Vieira IC. Are the cutaneous manifestations during or due to SARS-CoV-2 infection/COVID-19 frequent or not? Revision of possible pathophysiologic mechanisms. *Inflamm Res*. 2020;69(8):745–756. doi:10.1007/s00011-020-01370-w
6. Galván Casas C, Català A, Carretero Hernández G, et al. Classification of the cutaneous manifestations of COVID-19: a rapid prospective nationwide consensus study in Spain with 375 cases. *Br J Dermatol*. 2020;183(1):71–77. doi:10.1111/bjd.19163
7. Mawhirt SL, Frankel D, Diaz AM. Cutaneous manifestations in adult patients with COVID-19 and dermatologic conditions related to the COVID-19 pandemic in health care workers. *Curr Allergy Asthma Rep*. 2020;20(12):75. doi:10.1007/s11882-020-00974-w
8. Recalcati S. Cutaneous manifestations in COVID-19: a first perspective. *J Eur Acad Dermatol Venereol*. 2020;34(5). doi:10.1111/jdv.16387
9. Jamshidi P, Hajikhani B, Mirsaeidi M, Vahidnezhad H, Dadashi M, Nasiri MJ. Skin manifestations in COVID-19 patients: are they indicators for disease severity? A systematic review. *Front Med*. 2021;8:634208. doi:10.3389/fmed.2021.634208
10. Perna A, Passiatore M, Massaro A, et al. Skin manifestations in COVID-19 patients, state of the art. A systematic review. *Int J Dermatol*. 2021;60(5):547–553. doi:10.1111/ijd.15414
11. Zhao Q, Fang X, Pang Z, Zhang B, Liu H, Zhang F. COVID-19 and cutaneous manifestations: a systematic review. *J Eur Acad Dermatol Venereol*. 2020;34(11):2505–2510. doi:10.1111/jdv.16778
12. Guan W, Ni Z, Hu Y, et al. Clinical characteristics of coronavirus disease 2019 in China. *N Engl J Med*. 2020;382(18):1708–1720. doi:10.1056/NEJMoa2002032
13. Freeman EE, McMahon DE, Lipoff JB, et al. The spectrum of COVID-19-associated dermatologic manifestations: an international registry of 716 patients from 31 countries. *J Am Acad Dermatol*. 2020;83(4):1118–1129. doi:10.1016/j.jaad.2020.06.1016
14. Jindal R, Chauhan P. Cutaneous manifestations of coronavirus disease 2019 in 458 confirmed cases: a systematic review. *J Family Med Prim Care*. 2020;9(9):4563. doi:10.4103/jfmpe.jfmpe_872_20
15. Muhammad A, Iftikhar N, Mashhood A, et al. Dermatological manifestations of COVID-19 in patients reporting to a tertiary care hospital in Rawalpindi, Pakistan. *Cureus*. 2021. doi:10.7759/cureus.18973
16. De Giorgi V, Recalcati S, Jia Z, et al. Cutaneous manifestations related to coronavirus disease 2019 (COVID-19): a prospective study from China and Italy. *J Am Acad Dermatol*. 2020;83(2):674–675. doi:10.1016/j.jaad.2020.05.073
17. Marzano AV, Cassano N, Genovese G, Moltrasio C, Vena GA. Cutaneous manifestations in patients with COVID-19: a preliminary review of an emerging issue. *Br J Dermatol*. 2020;183(3):431–442. doi:10.1111/bjd.19264
18. Fernandez-Nieto D, Ortega-Quijano D, Jimenez-Cauhe J, et al. Clinical and histological characterization of vesicular COVID-19 rashes: a prospective study in a tertiary care hospital. *Clin Exp Dermatol*. 2020;45(7):872–875. doi:10.1111/ced.14277
19. Dursun R, Temiz SA. The clinics of HHV-6 infection in COVID-19 pandemic: pityriasis rosea and Kawasaki disease. *Dermatol Ther*. 2020;33:4. doi:10.1111/dth.13730

20. Drago F, Ciccarese G, Rebora A, Parodi A. Human herpesvirus-6, -7, and Epstein-Barr virus reactivation in pityriasis rosea during COVID-19. *J Med Virol*. 2021;93(4):1850–1851. doi:10.1002/jmv.26549
21. Genovese G, Moltrasio C, Berti E, Marzano AV. Skin manifestations associated with COVID-19: current knowledge and future perspectives. *Dermatology*. 2021;237(1):1–12. doi:10.1159/000512932
22. Tamai M, Maekawa A, Goto N, et al. Three cases of COVID-19 patients presenting with erythema. *J Dermatol*. 2020;47(10):1175–1178. doi:10.1111/1346-8138.15532
23. Tatu AL, Baroiu L, Fotea S, et al. A working hypothesis on vesicular lesions related to COVID-19 infection, koebner phenomena type V, and a short review of related data. *Clin Cosmet Investig Dermatol*. 2021;14:419–423. doi:10.2147/CCID.S307846
24. De Lucia M, Potestio L, Costanzo L, Fabbrocini G, Gallo L. Scabies outbreak during COVID-19: an Italian experience. *Int J Dermatol*. 2021;60(10):1307–1308. doi:10.1111/ijd.15809
25. Veraldi S, Romagnuolo M, Benzecry V. Pityriasis rosea-like eruption revealing COVID-19. *Australas J Dermatol*. 2021;62:2. doi:10.1111/ajd.13504
26. Sachdeva M, Gianotti R, Shah M, et al. Cutaneous manifestations of COVID-19: report of three cases and a review of literature. *J Dermatol Sci*. 2020;98(2):75–81. doi:10.1016/j.jdermsci.2020.04.011
27. Broccolo F, Drago F, Careddu AM, et al. Additional evidence that pityriasis rosea is associated with reactivation of human herpesvirus-6 and -7. *J Invest Dermatol*. 2005;124(6):1234–1240. doi:10.1111/j.0022-202X.2005.23719.x
28. Birlutiu V, Birlutiu RM, Iancu GM. Pityriasis rosea Gibert triggered by SARS-CoV-2 infection: a case report. *Medicine*. 2021;100(14):e25352. doi:10.1097/MD.00000000000025352
29. Ehsani AH, Nasimi M, Bigdelo Z. Pityriasis rosea as a cutaneous manifestation of COVID-19 infection. *J Eur Acad Dermatol Venereol*. 2020;34(9):e436–e437. doi:10.1111/jdv.16579
30. Martín Enguix D, Salazar Nieves M, Martín Romero DT. Erupción tipo pitiriasis rosada de Gibert en una paciente asintomática con positividad para COVID-19. *Medicina Clínica*. 2020;155(6):273. doi:10.1016/j.medcli.2020.05.024
31. Merhy R, Sarkis AS, Stephan F. Pityriasis rosea as a leading manifestation of COVID-19 infection. *J Eur Acad Dermatol Venereol*. 2021;35:4. doi:10.1111/jdv.17052
32. Johansen M, Chisolm SS, Aspey LD, Brahmabhatt M. Pityriasis rosea in otherwise asymptomatic confirmed COVID-19–positive patients: a report of 2 cases. *JAAD Case Rep*. 2021;7:93–94. doi:10.1016/j.jder.2020.10.035
33. Yazdanpanah N, Rezaei N. Autoimmune complications of COVID-19. *J Med Virol*. 2022;94(1):54–62. PMID: 34427929; PMCID: PMC8661629. doi:10.1002/jmv.27292
34. Chacón Acevedo KR, Barrero Garzón LI, Rincón Ramírez KL, et al. Toxicoderma en paciente con COVID-19. Reporte de caso. *Case Rep*. 2021;7(1):74–80. doi:10.15446/cr.v7n1.88223
35. Tatu AL, Elisei AM, Chioncel V, Miulescu M, Nwabudike LC. Immunologic adverse reactions of β -blockers and the skin. *Exp Ther Med*. 2019;18(2):955–959. doi:10.3892/etm.2019.7504
36. Ozaras R, Berk A, Ucar DH, Duman H, Kaya F, Mutlu H. Covid-19 and exacerbation of psoriasis. *Dermatol Ther*. 2020;33:4. doi:10.1111/dth.13632
37. Ö K, Metin A. Dermatological diseases presented before COVID -19: are patients with psoriasis and superficial fungal infections more vulnerable to the COVID -19? *Dermatol Ther*. 2020;33(4). doi:10.1111/dth.13509
38. Mathieu RJ, Cobb CBC, Telang GH, Firoz EF. New-onset pustular psoriasis in the setting of severe acute respiratory syndrome coronavirus 2 infection causing coronavirus disease 2019. *JAAD Case Rep*. 2020;6(12):1360–1362. doi:10.1016/j.jder.2020.10.013
39. Patrick MT, Zhang H, Wasikowski R, et al. Associations between COVID-19 and skin conditions identified through epidemiology and genomic studies. *J Allergy Clin Immunol*. 2021;147(3):857–869.e7. doi:10.1016/j.jaci.2021.01.006
40. Marasca C, Ruggiero A, Napolitano M, Fabbrocini G, Megna M. May COVID-19 outbreaks lead to a worsening of skin chronic inflammatory conditions? *Med Hypotheses*. 2020;143:109853. doi:10.1016/j.mehy.2020.109853
41. Gambichler T, Boms S, Susok L, et al. Cutaneous findings following COVID-19 vaccination: review of world literature and own experience. *Acad Dermatol Venereol*. 2022;36(2):172–180. doi:10.1111/jdv.17744
42. Capoferri G, Daikeler T, Mühleisen B, Trendelenburg M, Müller S. Cutaneous leukocytoclastic vasculitis secondary to COVID-19 infection leading to extensive skin necrosis. *Clin Dermatol*. 2022;S0738081X22000281. doi:10.1016/j.clindermatol.2022.02.013
43. Santa Cruz A, Mendes-Frias A, Oliveira AI, et al. Interleukin-6 is a biomarker for the development of fatal severe acute respiratory syndrome coronavirus 2 pneumonia. *Front Immunol*. 2021;12:613422. doi:10.3389/fimmu.2021.613422
44. Villani A, Megna M, Scalvenzi M, Fabbrocini G, Ruggiero A. Teledermatology and chronic skin diseases: real life experience in a Southern Italian Dermatologic Centre. *Dermatol Ther*. 2020;33:6. doi:10.1111/dth.13839
45. Marasca C, Ruggiero A, Fontanella G, Ferrillo M, Fabbrocini G, Villani A. Telemedicine and support groups could be used to improve adherence to treatment and health-related quality of life in patients affected by inflammatory skin conditions during the COVID-19 pandemic. *Clin Exp Dermatol*. 2020;45(6):749. doi:10.1111/ced.14245
46. Marasca C, De Rosa A, Fabbrocini G, et al. Psychological teleconsultations in patients suffering from chronic skin diseases during the COVID-19 era: a service to improve patients' quality of life. *J Dermatolog Treat*. 2022;33(3):1736–1737. doi:10.1080/09546634.2020.1809625

Clinical, Cosmetic and Investigational Dermatology

Dovepress

Publish your work in this journal

Clinical, Cosmetic and Investigational Dermatology is an international, peer-reviewed, open access, online journal that focuses on the latest clinical and experimental research in all aspects of skin disease and cosmetic interventions. This journal is indexed on CAS. The manuscript management system is completely online and includes a very quick and fair peer-review system, which is all easy to use. Visit <http://www.dovepress.com/testimonials.php> to read real quotes from published authors.

Submit your manuscript here: <https://www.dovepress.com/clinical-cosmetic-and-investigational-dermatology-journal>