



# Sacral Agenesis: A Neglected Deformity That Increases the Incidence of Postoperative Coronal Imbalance in Congenital Lumbosacral Deformities

Tianyuan Zhang, PhD<sup>1</sup>, Shibin Shu, PhD<sup>1</sup>, Wenting Jing, PhD<sup>1</sup>, Qi Gu, PhD<sup>2</sup>, Zhen Liu, MD<sup>1</sup>, Xu Sun, MD<sup>1</sup>, Bin Wang, MD<sup>1</sup>, Yong Qiu, MD<sup>1</sup>, Zezhang Zhu, MD<sup>1</sup> , and Hongda Bao, MD<sup>1</sup> 

Global Spine Journal  
2022, Vol. 12(5) 916–921  
© The Author(s) 2020  
Article reuse guidelines:  
sagepub.com/journals-permissions  
DOI: 10.1177/2192568220970509  
journals.sagepub.com/home/gsj



## Abstract

**Study Design:** A retrospective study.

**Objectives:** To identify if there is a link between sacral agenesis (SA) and post-operative coronal imbalance in patients with congenital lumbosacral deformities.

**Methods:** This study reviewed a consecutive series of patients with congenital lumbosacral deformities. They had a minimum follow-up of 2 years. According to different diagnosis, they were divided into SA and non-SA group. Comparison analysis was performed between patients with and without post-operative coronal imbalance and risk factors were identified.

**Results:** A total of 45 patients (18 in SA group and 27 in non-SA group) were recruited into this study, among whom 33 patients maintained coronal balance while 12 demonstrated postoperative coronal imbalance at last follow-up ( $14.32 \pm 7.67$  mm vs  $35.53 \pm 3.91$  mm,  $P < 0.001$ ). Univariate analysis showed that preoperative lumbar Cobb angle, immediate postoperative coronal balance distance and diagnosis of SA were significantly different between patients with and without post-operative coronal imbalance ( $P < 0.05$ ). Binary logistic regression analysis showed that SA was an independent risk factor for postoperative coronal imbalance.

**Conclusions:** As an independent risk factor for postoperative coronal imbalance, high level of suspicion of SA should be aware in children with congenital lumbosacral deformities. Sufficient bone grafts at sacroiliac joint are recommended for SA patients to prevent postoperative coronal imbalance.

## Keywords

congenital, scoliosis, lumbosacral, sacral agenesis, hemivertebra

## Introduction

Congenital lumbosacral deformities refer to the spinal anomalies located between L5 and sacrum that occurs during early embryonic development. It encompasses a wide variety of malformation, including L5 hemi- or butterfly vertebra, lumbosacral transitional vertebra, sacral agenesis (SA) and caudal spinal dysraphism.<sup>1,2</sup> Different from other spinal segments above, this region bears great vertical load and serves as the only mechanical connection between the axial skeleton and the lower extremities through the sacroiliac joints. Consequently, its teratogenesis may disturb the equilibrium of the whole spine

and cause the congenital scoliosis as well as proximal compensatory curvature.

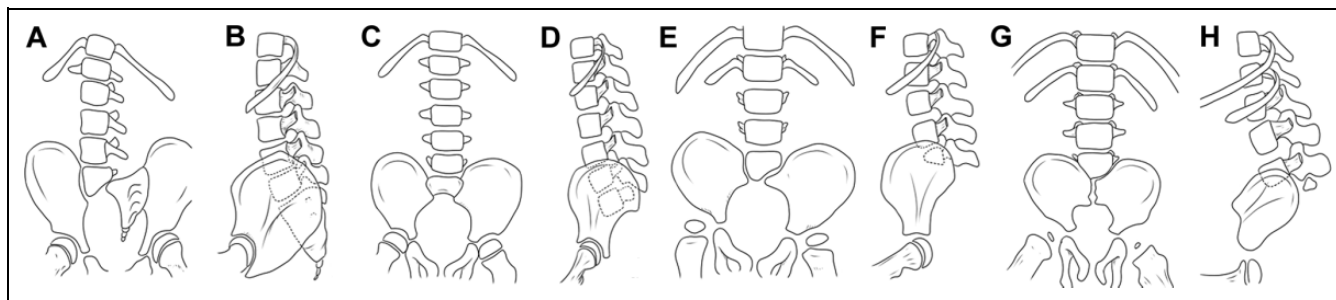
<sup>1</sup> Department of Spine Surgery, Nanjing Drum Tower Hospital, Medical School of Nanjing University, Nanjing, China

<sup>2</sup> Department of Spine Surgery, Nanjing Drum Tower Hospital, Clinical College of Nanjing Medical University, Nanjing, China

### Corresponding Author:

Hongda Bao, Department of Spine Surgery, Nanjing Drum Tower Hospital, Medical School of Nanjing University, Nanjing 210008, China.  
Email: baohongda123@gmail.com





**Figure 1.** Renshaw's classification of sacral agenesis. (A, B) Type I: either partial or total unilateral sacral agenesis; (C, D) Type II: partial sacral agenesis with a partial but bilaterally symmetrical defect and a stable articulation between the ilia and a normal or hypoplastic first sacral vertebra; (E, F) Type III: variable lumbar and total sacral agenesis with the ilia articulating with the sides of the lowest vertebra present; (G, H) Type IV: variable lumbar and total sacral agenesis, the caudal end-plate of the lowest vertebra resting above either fused ilia or an iliac amphiarthrosis.

However, unlike lumbar vertebra, the curvilinear shape of sacrum makes it difficult to evaluate on standard anteroposterior roentgenogram. Besides, anatomical variations occur continually in this region, making sacrum the most variable portion of the spine.<sup>3,4</sup> Hence, the malformation of sacrum is a frequently overlooked anomaly and few studies had discussed the implication of the deformed spinal base for trunk balance and stability. We think it is imperative to take the agenesis of sacrum into consideration when analyzing the congenital lumbosacral scoliosis.

In fact, SA, involving incomplete formation or complete absence, is a very heterogeneous entity and has several types of classification according to patterns of morphologic deficiency, among which Renshaw's 4 types classification (Figure 1) is the most classic one.<sup>5-7</sup> In this paper, we emphasized on the Type I SA—either total or partial unilateral and asymmetric SA. Patients with this unique sacral deformity had uneven sacral superior base and resultant lumbar scoliosis convex to the dysplasia side. We hypothesized that the horizontal and intact sacral superior base is indispensable to maintain the spinal steadiness and balance in congenital lumbosacral deformities.

Considering the above, we retrospectively analyzed the clinical features and surgical outcomes of patients with congenital lumbosacral deformities in our center and aimed to identify if there is a link between SA and post-operative coronal imbalance.

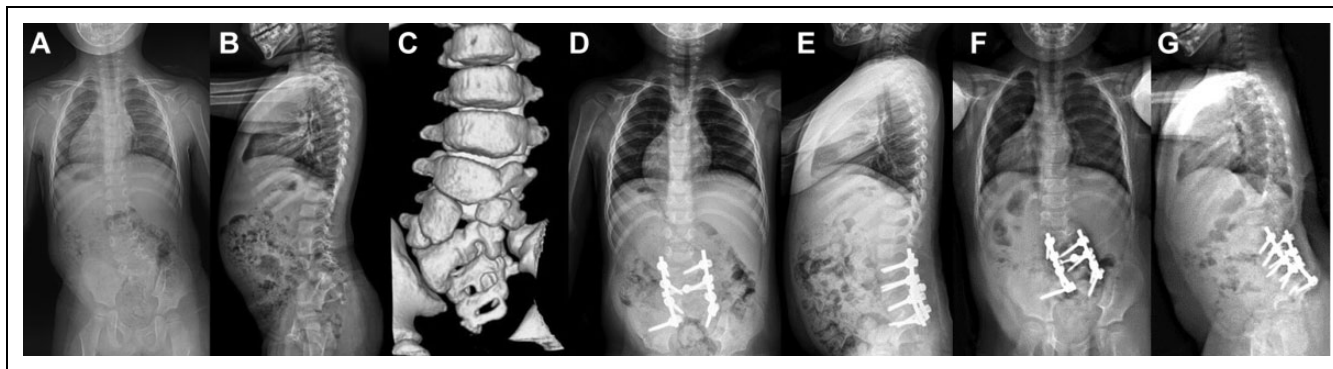
## Methods

This study was approved by the institutional review board of our hospital and informed consent was obtained from each subject. We performed a retrospective analysis of the prospectively collected data of patients with congenital lumbosacral spinal deformities who underwent surgery between August 2005 and August 2017. The inclusion criteria were as follow: (1) confirmed diagnosis of congenital lumbosacral deformities (Type I SA or lumbosacral hemivertebra) with major thoracolumbar/lumbar scoliotic curve more than 10°; (2) posterior-only lumbosacral fixation and fusion; (3) a minimum follow-up period of 2 years; (4) age smaller than 18 years at the time of surgery; (5) no or

slight neurologic deficiency. Patients who had previous surgical procedure of the spine, other types of SA except Renshaw Type I, congenital spinal deformities in the cervical or thoracic region, were excluded in the present study. Patients with Type I SA were grouped into SA group and patients with lumbosacral hemivertebra were grouped into non-SA group.

All patients included in this study underwent the posterior-only lumbosacral fixation and fusion. Patients were placed in the prone position under general anesthesia. The levels for instrumentation was identified and confirmed by the intraoperative X-ray. A midline skin incision was made in the lumbosacral region and the length of incision depended on the length of presumed fusion segments. After dissection and exposure of posterior elements of vertebra, pedicle screw was inserted at each level. After confirmation of the screws position, 2 pre-contouring rods were placed in the screws. A combination of compression-distraction, derotation and translation maneuvers were utilized to correct the deformity. Last but not least, the massive bone grafting was needed to imbed deeply in the defective zone between sacrum and pelvis (the assumed sacroiliac joint) for patients with SA. Additionally, hemivertebra resection after insertion of pedicle screws and interbody fusion were also required for patients with lumbosacral hemivertebra. A cross-link was routinely used to stabilize the implant constructs if possible. The implant materials were all titanium. The bone grafting materials were mixed, including autogenous bone and allogeneic bone. Somatosensory-evoked and motor-evoked potential monitoring were performed in the upper and lower extremities in all patients during surgery.

The selection of fusion levels also needed to be explicated. The upper instrumented vertebra (UIV) was often selected at the end vertebra of the lumbosacral curve. If there was a large and rigid compensatory curve above, it should be fused as well. The UIV should be leveled as much as possible during correction to avoid potential post-operative coronal imbalance. The selection of lower instrumented vertebra (LIV) was quite complicated. For patients with lumbosacral hemivertebra, we normally routinely chose S1 screws as distal fixation anchors. However, for patients with SA, the decision of distal fixation was depended on the severity of deformities, the amount of



**Figure 2.** Postoperative coronal imbalance in a patient with sacral agenesis. (A-C) A 4 years old boy was diagnosed with congenital lumbosacral deformity and preoperative CT reconstruction showed sacral agenesis on the left side associated with L5 malformation; (D-E) After surgery, the coronal deformity was corrected with iliac screw on the left and S1 screw on the right; (F-G) Three years after surgery, coronal imbalance reoccurred and trunk shifted to the left side due to the unstable spinal base.

sacrum defect and skeletal maturity. For young patients with moderate deformities, we chose S1 screws as distal anchors with short fusion levels; for patients with severe deformities and/or combined coronal imbalance, pelvic fixation with relative long fusion levels was necessary to achieve deformity correction. Sometimes, we couldn't find the trajectory for sacral screw insertion in the hypoplastic side of sacrum due to the large defect. In this condition, unilateral iliac screw was used instead (Figure 2).

Clinical data was collected from the medical records of our hospital. Required radiographic data included preoperative, postoperative and the last follow-up full spine radiographs. Computed tomography (CT) scans were also needed to routinely evaluate the status of bone fusion 2 years postoperatively. The radiographic parameters included measurements of main curve Cobb angle, coronal balance distance and pelvic obliquity angle. Correction of Cobb angle was calculated by postoperative Cobb angle minus preoperative Cobb angle. Coronal balance distance (CBD) was measured and quantified by the perpendicular distance between the coronal C7 plumb line (C7PL) and the central sacral vertical line (CSVL); CBD >30 mm was defined as coronal imbalance. Complications were also recorded during follow-up periods.

Statistical analysis was performed using the SPSS17 software (IBM, Inc., New York, NY, USA). Independent-t test and Chi-square test were used to compare the radiographic and demographic parameters between SA and non-SA groups. Comparison analysis was also performed between patients with and without post-operative coronal imbalance. To find out the independent risk factors associated with postoperative coronal imbalance, binary logistic regression was also performed with forward elimination (Conditional) using variables that were found significant in comparison study. P value < 0.05 was considered statistically significant.

## Results

Totally, 45 patients (30 boys and 15 girls) met inclusion criteria with an average age of  $8.13 \pm 3.54$  years (3-18 years) at the

time of surgery, among which 18 patients had SA and the rest were only with congenital lumbosacral hemivertebra. According to the different diagnoses, patients were divided into 2 groups: SA group and non-SA group. The mean time of follow-up was  $4.20 \pm 2.43$  years (2-10 years).

### Surgical Outcomes of SA and Non-SA Group

The 18 patients in the SA group had a younger age ( $6.67 \pm 2.66$  years vs.  $9.11 \pm 3.76$  years,  $p = 0.021$ ) and larger preoperative lumbar Cobb angle ( $38.06 \pm 7.78^\circ$  vs.  $25.40 \pm 9.51^\circ$ ,  $p < 0.001$ ) compared to non-SA group (Table 1). The coronal balance before surgery was similar between 2 groups, but showed significant difference during follow-up ( $26.97 \pm 9.99$  mm vs.  $15.31 \pm 10.46$  mm). The coronal balance distance in the SA group gradually increased postoperatively from  $22.24 \pm 9.91$  mm to  $26.97 \pm 9.99$  mm, demonstrating a deterioration of coronal malalignment. During follow-up, 3 patients in SA group encountered rod fracture and all of them underwent revision surgery.

### Analysis of Postoperative Coronal Imbalance

A total of 12 patients showed postoperative coronal imbalance (10 in SA group and 2 in non-SA group) at the last follow-up (Figures 2 and 3). The rest of patients belonged to the coronal balance group. The incidence of coronal imbalance was significantly higher in SA group (55.6% VS. 7.4%,  $p = 0.001$ ). Regarding to the risk factors of postoperative coronal imbalance in congenital lumbosacral deformities, comparison of the balanced and imbalanced group showed that preoperative lumbar Cobb angle, postoperative CBD and diagnosis of SA were significantly different ( $P < 0.05$ ) (Table 2). Then, binary logistic regression analysis containing these 3 elements was carried out. The results indicated that SA was the only risk factor for post-operative coronal imbalance in congenital lumbosacral deformities (Table 3).

## Discussions

The relationship between lumbar scoliosis and coronal imbalance of trunk had been discussed in previous literature. Schwender et al.<sup>8</sup> discovered that the magnitude and flexibility of the fractional curve played a role in coronal plane imbalance in certain curve patterns of adolescent idiopathic scoliosis and that sacral obliquity noted on the preoperative standing radiographs were also at-risk signs for persistent postoperative coronal imbalance. Even a few degrees of obliquity at the level of

the sacrum, if not compensated by the remainder of the spine, could result in a relatively large amount of coronal imbalance. Lee et al.<sup>9</sup> also emphasized the clinical importance of sacral slanting in patients with adolescent idiopathic scoliosis undergoing surgery. Bao et al.<sup>10</sup> pointed out that adult spinal deformity patients who had a rigid fractional curve were predisposed to postoperative coronal imbalance. However, few studies had focused on the potential effect of lumbosacral deformities, especially the SA, on the development of postoperative coronal trunk shift. For the first time, we concluded that SA was an important independent risk factor for postoperative coronal imbalance in congenital lumbosacral deformities.

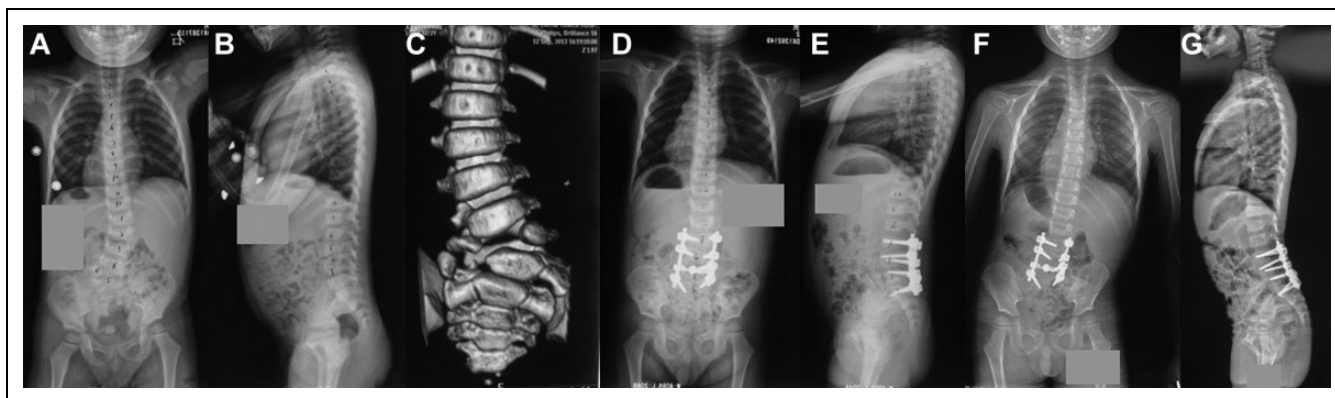
**Table 1.** Clinical and Radiographic Characteristics of SA and Non-SA Group.

	SA group (n = 18)	Non-SA group (n = 27)	P value
Age (years)	6.67 ± 2.66	9.11 ± 3.76	0.021
Gender			0.197
Male	10	20	
Female	8	7	
Follow-up time (years)	3.44 ± 1.65	4.70 ± 2.74	0.062
Length of fixed segments	4.11 ± 1.37	3.07 ± 0.83	0.003
Distal anchor			<0.001
Sacrum	10	27	
Pelvis	8	0	
Lumbar Cobb angle (°)			
Preoperative	38.06 ± 7.78	25.40 ± 9.51	<0.001
Postoperative	15.47 ± 10.24	10.04 ± 4.53	0.046
Follow-up	25.18 ± 19.58	14.77 ± 9.53	0.022
CBD (mm)			
Preoperative	19.22 ± 12.20	18.94 ± 13.52	0.944
Postoperative	22.24 ± 9.91	15.04 ± 7.71	0.009
Follow-up	26.97 ± 9.99	15.31 ± 10.46	0.001
Pelvic obliquity angle (°)			
Preoperative	3.27 ± 1.71	3.29 ± 1.78	0.972
Postoperative	2.84 ± 1.50	2.76 ± 1.46	0.860
Follow-up	2.33 ± 1.16	2.85 ± 2.25	0.373
Complications			
Rod fracture	3	0	-
Revision surgery	3	0	-

(SA = sacral agenesis, CBD = coronal balance distance).

Li et al.<sup>11</sup> analyzed the occurrence of postoperative coronal decompensation in young children with thoracolumbar hemivertebra and found that greater preoperative lowest instrumented vertebra (LIV) translation and higher postoperative LIV disc angle were 2 risk factors of postoperative coronal decompensation. However, different from deformities in the thoracolumbar region, the congenital deformities located in the lumbosacral region lack motion segments below to compensate for coronal imbalance. Therefore, due to its unique position, we should raise enough concern about postoperative coronal imbalance.

Anatomically, sacrum has many complex variations and its blurred or rugged upper surface is difficult to evaluate.<sup>3</sup> Thus, only with the aid of CT reconstruction, the diagnosis of SA could be confirmed. As mentioned before, SA is a very heterogeneous entity. The anatomic descriptions of the various anomalies in SA had been discussed by many authors and different types had been identified, but very little had been reported on the surgical outcomes. Our results revealed that compared to patients only with lumbosacral hemivertebra, patients combined with SA were predisposed to postoperative coronal imbalance. In Renshaw type I SA, the unilateral agenesis of the superior sacral base created an uneven foundation for the spinal column. As a result of the subsided foundation, the spine columns above would gradually lean to the subsided side, leading to coronal imbalance. This phenomenon occurred



**Figure 3.** Postoperative coronal imbalance in a patient with lumbosacral hemivertebra. (A-C) A 3 years old boy was diagnosed with congenital lumbosacral deformity and preoperative CT reconstruction showed 2 consecutive hemivertebra on the same side, named L4' and L5 hemivertebra respectively; (D-E) After resection of the L4' hemivertebra, the coronal deformity was corrected; (F-G) Three years after surgery, coronal imbalance occurred and trunk shifted to the right side because the reserved L5 hemivertebra also caused an unstable spinal base.

**Table 2.** Comparisons of Demographics and Radiological Parameters between Postoperative Coronal Balance and Imbalance Group.

	Balance group (n = 33)	Imbalance group (n = 12)	P value
Age (years)	8.67 ± 3.71	6.67 ± 2.64	0.094
Gender			0.475
Male	23	7	
Female	10	5	
Follow-up time (years)	4.55 ± 2.58	3.25 ± 1.71	0.114
Distal anchor			0.746
Sacrum	28	9	
Pelvis	5	3	
Length of fixed segments	3.48 ± 1.20	3.50 ± 1.17	0.970
Lumbar Cobb angle (°)			
Preoperative	27.47 ± 10.02	38.70 ± 8.47	0.001
Postoperative	10.87 ± 6.30	15.90 ± 10.18	0.053
Follow-up	18.30 ± 16.72	20.68 ± 9.79	0.647
Correction of Cobb angle (°)	16.60 ± 9.50	22.48 ± 8.67	0.067
CBD (mm)			
Preoperative	17.52 ± 13.25	23.27 ± 11.16	0.188
Postoperative	15.58 ± 8.46	24.36 ± 8.58	0.004
Follow-up	14.32 ± 7.67	35.53 ± 3.91	<0.001
Pelvic obliquity angle (°)			
Preoperative	3.08 ± 1.53	3.82 ± 2.19	0.212
Postoperative	2.72 ± 1.35	2.98 ± 1.78	0.616
Follow-up	2.87 ± 2.06	2.02 ± 1.14	0.182
Sacral agenesis			0.001
Yes	8	10	
No	25	2	

(CBD = coronal balance distance).

**Table 3.** Logistic Regression Analysis of Risk Factors for Postoperative Coronal Imbalance.

	B	SE	Wald	P value	Exp(B)	95%CI	
						Lower	Upper
Sacral agenesis	-2.749	0.87	9.88	0.002	0.064	0.012	0.355
Constant	2.526	0.73	11.81	0.001	12.500	-	-

in many cases of our series who developed trunk shift postoperatively, but was not frequently seen before surgery. One explanation could be the existence of preoperative lumbar compensatory curve in SA group which could compensate for the inclination of trunk. In some severe cases, the scoliotic lumbar vertebra could even touch the iliac wing.

Therefore, one of the most important surgical procedures for patients with SA was sufficient bone grafting at the sacroiliac joint or between the lower lumbar spine and pelvis on the aplasia side. But it must be noted that even with the imbedded bone grafts, sometimes the spine column above was inevitable to subside because of the great vertical load it beared before bone fusion. Under this circumstances, stronger holding power by distal anchors and postoperative brace protection were

recommended for those patients with SA. Heary et al.<sup>12</sup> thought that postoperative bracing may be beneficial for achieving the goal of a long-term, stable, bony arthrodesis, which met our demands for solid arthrodesis at the sacroiliac joint. Our experience was that for patients who with postoperative coronal imbalance, bracing was prescribed to prevent progressive trunk shift and the following implant failure. With this method, the coronal imbalance was controlled and no patients needed a revision surgery due to consistent or progressive coronal imbalance during follow-up.

In this study, only SA of Renshaw Type I was analyzed and other 3 types were not included due to different radiographic presentations and surgical interventions. In Type II, the superior sacral base was intact and agenesis of sacrum was often below S2 vertebra. In Type III or IV, the total sacrum was absent and the surgery was aimed at spinopelvic reconstruction, which is similar to the total sacrectomy for sacral tumors.<sup>13</sup> They are rarer than the other 2 types. We came across very few cases in clinical practice. Only in Type I, the dysplasia was asymmetric and raised the concern for coronal imbalance. Besides, the Type I SA is of less severity and may have less urologic and neurologic symptoms compared to other types.<sup>7,14-16</sup>

Our studies had several limitations. First, it was a retrospective study with the inherent risk of data inaccuracy. Second, the sample size was relatively small due to the low morbidity. Third, we mainly focused on the impact of congenital lumbosacral deformities on coronal plane and the sagittal parameters were not recorded due to the difficulty of measuring pelvic incidence in patients with SA. At last, concurrent congenital anomalies were not rare in SA. In our cohort, 2 patients had syringomyelia in the cervical region and 2 patients had diastematomyelia in the thoracic region. The high location of intraspinal anomalies didn't affect the fixation strategy and surgical outcome in the caudal region. Regarding to bone healing and strength of paraspinal muscles and surrounding soft tissue, it was very hard to accurately quantify and to investigate the influence of these factors.

## Conclusions

As an independent risk factor for postoperative coronal imbalance, high level of suspicion of SA should be aware in children with congenital lumbosacral deformities. Sufficient bone grafts at sacroiliac joint are recommended for SA patients.


## Declaration of Conflicting Interests


The author(s) declared no potential conflicts of interest with respect to the research, authorship, and/or publication of this article.

## Funding

The author(s) disclosed receipt of the following financial support for the research, authorship, and/or publication of this article: The Natural Science Foundation of Jiangsu Province (No. BK20180122) and the Special Funds for Health Science and Technology Development of Nanjing City (No. YKK18092) funds were received in support of this work. No relevant financial activities outside the submitted work.

**ORCID iD**

Zezhang Zhu, MD  <https://orcid.org/0000-0001-8569-3595>

Hongda Bao, MD  <https://orcid.org/0000-0002-6728-615X>

**References**

1. Naffaa L, Irani N, Saade C, Sreedher G. Congenital anomalies of lumbosacral spine: a pictorial review. *J Med Imaging Radiat Oncol.* 2017;61(2):216-224.
2. Grimme JD, Castillo M. Congenital anomalies of the spine. *Neuroimaging Clin N Am.* 2007;17(1):1-16.
3. Cheng JS, Song JK. Anatomy of the sacrum. *Neurosurg Focus.* 2003;15(2):E3.
4. Saker E, Oskouian RJ, Loukas M, Johnston JM, Tubbs RS, Conklin M. A never before reported variant of the sacrum. *Surg Radiol Anat.* 2017;39(7):807-809.
5. Renshaw TS. Sacral agenesis. *J Bone Joint Surg Am.* 1978;60(3):373-383.
6. White RI, Klauber GT. Sacral agenesis. Analysis of 22 cases. *Urology.* 1976;8(6):521-525.
7. Pang D. Sacral agenesis and caudal spinal cord malformations. *Neurosurgery.* 1993;32(5):755-778; discussion 778-779.
8. Schwender JD, Denis F. Coronal plane imbalance in adolescent idiopathic scoliosis with left lumbar curves exceeding 40 degrees: the role of the lumbosacral hemicurve. *Spine (Phila Pa 1976).* 2000;25(18):2358-2363.
9. Lee CS, Ha JK, Kim DG, et al. The clinical importance of sacral slanting in patients with adolescent idiopathic scoliosis undergoing surgery. *Spine J.* 2015;15(5):834-840.
10. Bao H, Yan P, Qiu Y, Liu Z, Zhu F. Coronal imbalance in degenerative lumbar scoliosis: prevalence and influence on surgical decision-making for spinal osteotomy. *Bone Joint J.* 2016;98-b(9):1227-1233.
11. Li S, Chen ZH, Qiu Y, et al. Coronal decompensation after posterior-only thoracolumbar hemivertebra resection and short fusion in young children with congenital scoliosis. *Spine (Phila Pa 1976).* 2018;43(9):654-660.
12. Heary R, Bono C, Kumar S. Bracing for scoliosis. *Neurosurg.* 2008;63(3):125-130.
13. Mindea SA, Chinthakunta S, Moldavsky M, Gudipally M, Khalil S. Biomechanical comparison of spinopelvic reconstruction techniques in the setting of total sacrectomy. *Spine (Phila Pa 1976).* 2012;37(26):E1622-E1627.
14. O'Neill OR, Piatt JH, Mitchell P, Roman-Goldstein S. Agenesis and dysgenesis of the sacrum: neurosurgical implications. *Pediatr Neurosurg.* 1995;22(1):20-28.
15. Wilmschurst JM, Kelly R, Borzyskowski M. Presentation and outcome of sacral agenesis: 20 years' experience. *Dev Med Child Neurol.* 1999;41(12):806-812.
16. Koontz WW, Prout GR. Agenesis of the sacrum and the neurogenic bladder. *JAMA.* 1968;203(7):481-486.