
Happy heart syndrome mimicking acute pulmonary embolism and acute coronary syndrome 🎬

 Ömer Doğan Alataş*,  Murat Biteker**

Departments of *Emergency, and **Cardiology, Muğla Sıtkı Koçman University Education and Research Hospital; Muğla-Turkey

Introduction

Takotsubo cardiomyopathy (TC), also named as the “broken heart syndrome (BHS),” “apical ballooning syndrome,” or “stress-induced cardiomyopathy,” is characterized by transient left ventricular systolic dysfunction without an evidence of obstructive coronary artery disease (1). Postmenopausal women account for approximately 90% of the cases (1). Recent studies have shown that TC can be triggered by negative as well as positive life events, owing to which it is also known as the “happy heart syndrome” (HHS) (2). However, it is frequently triggered by physically or emotionally stressful events such as the receipt of bad news; incidents of death, accidents, and natural disasters; or presence of complicated medical diseases as well as events

including surgical procedures, sepsis, trauma, or cerebrovascular diseases (3). Although acute pulmonary embolism has been listed as a potential contributor in TC, there are currently no case reports of TC mimicking acute pulmonary embolism in the literature. Here, we present a rare case of HHS mimicking acute pulmonary embolism that completely recovered with anticoagulant and diuretic therapies.

Case Report

A 65-year-old woman with no cardiovascular risk factors presented to our emergency department (ED) with retrosternal chest pain at rest. Her medical history included only hypothyroidism, which was being treated with 50 µg levothyroxine sodium once daily. The patient was admitted to the ED with a blood pressure of 84/45 mm Hg and a heart rate of 98 bpm. She was afebrile, with a respiratory rate of 25 breaths/min and an oxygen saturation of 95%. Physical examination revealed no jugular venous distention or lower extremity edema, and the lungs were clear on auscultation. The ECG showed sinus rhythm and an S1Q3T3 pattern (Fig. 1).

The patient's complete blood count and renal and liver function tests were all within the normal ranges. The routine laboratory tests conducted in ED revealed that the level of high-sensitivity cardiac troponin T was 86 ng/L (normal reference range, 0–52 ng/L), that of creatine kinase-MB was 8.61 ng/mL (normal reference range, 0–4.99 ng/mL), and that of D-dimer was 1213 ng/mL (normal reference range, 0–500 ng/mL). Echocardiogram was performed upon admission to ED, and the results showed normal tricuspid annular plane systolic excursion and a right ventricular diameter of 18 mm, an enlarged left ventricle of 51 mm at end-diastole with a reduced left ventricular ejection fraction of 32%, and a decreased motion of the left ventricular anterior–anteroseptal wall and apex (Fig. 2a, Video 1). Acute myocardial infarction was suspected due to regional wall motion abnormality and reduced left ventricular systolic function. On the other hand, subsegmental acute pulmonary embolism was also suspected due to the S1Q3T3 pattern on ECG and the slightly increased D-dimer levels. The patient was administered 325 mg of aspirin, 600 mg oral loading dose of clopidogrel, enoxaparin (30 mg intravenous bolus and 1 mg/kg twice a day subcutaneously 15 min after bo-

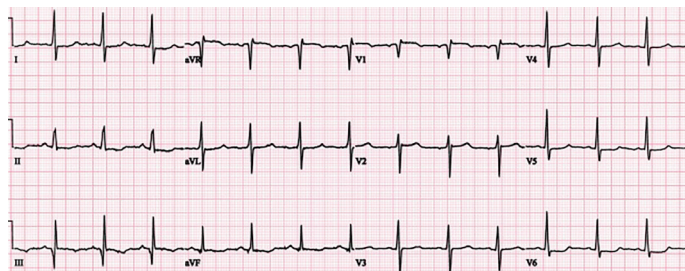


Figure 1. Electrocardiography showing S1Q3T3 (S wave in lead I and Q wave and inverted T wave in lead III)

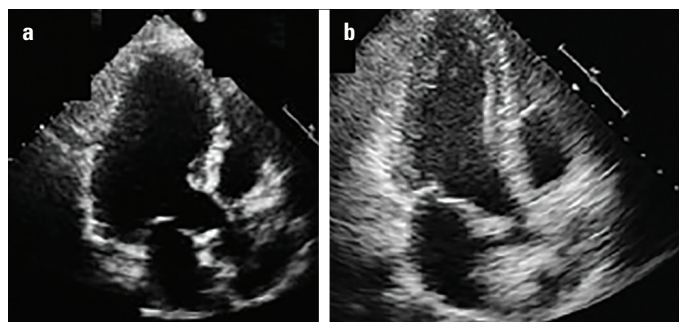


Figure 2. Apical two-chamber view in transthoracic echocardiography performed on admission showing akinesis of anterior and apical segments of the left ventricle (a). Transthoracic echocardiography performed on day 3 showing normal left ventricular systolic functions without any segmental wall motion abnormality (b)

lus), and 40 mg of intravenous furosemide in ED. The patient was transferred to the catheterization laboratory within 30 min of the first medical contact. However, coronary angiography revealed normal coronary arteries. Furthermore, computed tomography with angiogram was performed to rule out pulmonary embolism, which revealed normal pulmonary arteries without any thrombi. The detailed history obtained retrospectively revealed that the patient's complaints started immediately after learning that she would be a grandmother. Her hospital course was uneventful and her pain resolved within 3 h of admission. She was treated with standard heart failure therapy including angiotensin-converting enzyme inhibitors, beta-blockers, and diuretics.

Repeat echocardiography performed on day 1 displayed a normal-sized left ventricle with left ventricular apical hypokinesia and a left ventricular ejection fraction of 48%. On day 3, transthoracic echocardiogram revealed normal left ventricular systolic functions without any segmental wall motion abnormality (Fig. 2b). The ejection fraction was 64%. The patient was diagnosed with HHS and she was discharged home with routine patient–clinic appointment.

Discussion

In 1991, Dote et al. (4) first described TC in a series of five case in a Japanese population. In this syndrome, which was named after the shape of the octopus trap (takotsubo), the heart appears narrowed at the base with apical ballooning. Although the pathogenesis of HHS and BHS is not well understood, several etiologies have been proposed including catecholamine excess, coronary artery vasospasm, and estrogen deficiency (1-4). Although this syndrome has been named BHS, in 2016, Ghadri et al. (2) demonstrated that pleasant events, such as a surprise party, positive job interview, and winning jackpots, may trigger TC. The authors described 20 patients with this unique manifestation and named it HHS. Clinical presentation of patients with HHS was similar to those with the BHS, including symptoms, electrocardiographic and laboratory findings, and long-term outcomes (2).

Because TC shares similar clinical presentations with acute coronary syndrome and acute pulmonary embolism, it is easily misdiagnosed. Although acute pulmonary embolism is reported as a trigger for TC, the concurrence of TC and pulmonary embolism has rarely been reported (5).

Conclusion

The present patient was diagnosed with HHS based on the clinical, laboratory, angiographic, electrocardiographic, and echocardiographic findings. In cases that present with overlapping symptoms, it may be difficult to distinguish TC from pulmonary embolism and acute coronary syndrome. A history of recent emotional trauma, whether it was triggered by bad or good news, can prompt a clinician to consider TC as a diagnosis. The present case illustrates the challenges of distinguishing TC from acute coronary syndrome or pulmonary embolism. It is crucial that ED physicians recognize BHS and HHS as rare yet considerable reasons of acute chest pain and dyspnea. An assessment of the patient's medical history, particularly of previous emotional or physical triggers, is fundamental in the diagnosis of TC.

Informed consent: Written informed consent was obtained from the patient.

Video 1. Apical four-chamber view (left side of the video) in transthoracic echocardiography performed on admission show-

ing akinesis. Apical four-chamber view (right side of the video) in transthoracic echocardiography performed on day 3 showing the complete recovery of left ventricular systolic function.

References

1. Dawson DK. Acute stress-induced (takotsubo) cardiomyopathy. *Heart* 2018; 104: 96-102.
2. Ghadri JR, Sarcon A, Diekmann J, Bataiosu DR, Cammann VL, Jurisic S, et al.; InterTAK Co-investigators. Happy heart syndrome: role of positive emotional stress in takotsubo syndrome. *Eur Heart J* 2016; 37: 2823-9.
3. Nyman E, Mattsson E, Tornvall P. Trigger factors in takotsubo syndrome - A systematic review of case reports. *Eur J Intern Med* 2019; 63: 62-8.
4. Dote K, Sato H, Tateishi H, Uchida T, Ishihara M. Myocardial stunning due to simultaneous multivessel coronary spasms: a review of 5 cases. *J Cardiol* 1991; 21: 203-14.
5. Jin Q, Luo Q, Zhao Z, Zhao Q, Yu X, Yan L, et al. Takotsubo syndrome with pulmonary embolism: a case report and literature review. *BMC Cardiovasc Disord* 2018; 18: 229.

Address for Correspondence: Dr. Ömer Doğan Alataş,
Muğla Sıtkı Koçman Üniversitesi Eğitim ve Araştırma Hastanesi,
Acil Tıp Kliniği,
48000, Muğla- Türkiye
Phone: +90 554 877 40 79
E-mail: alatasomerdogan@gmail.com

©Copyright 2020 by Turkish Society of Cardiology - Available online
at www.anatoljcardiol.com
DOI:10.14744/AnatolJCardiol.2019.04052

