

Heterotrophic Ossification of the Flexor Retinaculum in a Patient with Ankylosing Spondylitis

Abstract

Carpal tunnel syndrome (CTS) is the most common peripheral neuropathy. This syndrome has various etiologies of which heterotopic ossification of the flexor retinaculum is a rare cause. Ankylosing spondylitis (AS) is a systemic, progressive inflammatory disease of unknown etiology that mainly affects the axial skeleton and rarely causes peripheral neurological symptoms. A 48-year-old woman presented with numbness and pain in her right hand. Ten years earlier, she was diagnosed with AS. Electrodiagnostic evaluation revealed severe median nerve compression at the right wrist. The patient underwent surgery for severe CTS. During the operation, the flexor retinaculum could not be incised due to marked stiffness. Ossification of the flexor retinaculum was seen, and the retinaculum was partially excised with an osteotome and Kerrison rongeur. The patient's complaints resolved almost totally after the operation. AS is a common systemic inflammatory disease that can produce heterotopic ossification of the flexor retinaculum. Preoperative wrist computed tomography should be obtained in patients with CTS and AS.

Keywords: Ankylosing spondylitis, carpal tunnel syndrome, heterotopic ossification

Introduction

Carpal tunnel syndrome (CTS) is the most common type of entrapment neuropathy of the peripheral nervous system. The main cause of CTS is increased pressure in the carpal tunnel. This affects the median nerve branches and causes pain and paresthesias, which commonly worsen at night. Chronic tenosynovitis of the flexor retinaculum occurs in the majority of CTS cases.^[1] Although various mass lesions within the carpal tunnel have been implicated in the etiology of CTS, only a few studies mention heterotopic ossification of the flexor retinaculum.^[2] Here, we present an unusual case of severe CTS due to heterotopic ossification of the flexor retinaculum in a patient with ankylosing spondylitis (AS).

Case Report

A 48-year-old woman presented with numbness and pain in her right hand. Ten years earlier, she was diagnosed with AS, which is well-controlled medically. On the neurological examination, Phalen's test and Tinel's sign were positive. She had right thenar muscle atrophy with normal muscle power. Electrodiagnostic evaluation

This is an open access journal, and articles are distributed under the terms of the Creative Commons Attribution-NonCommercial-ShareAlike 4.0 License, which allows others to remix, tweak, and build upon the work non-commercially, as long as appropriate credit is given and the new creations are licensed under the identical terms.

For reprints contact: reprints@medknow.com

revealed severe median nerve compression at the right wrist. The patient underwent surgery for severe CTS. A mini-incision was made on the palmar side of the hand. During the operation, the flexor retinaculum could not be incised due to marked stiffness. The incision was extended distally and proximally. Ossification of the flexor retinaculum was seen and the retinaculum was partially excised with an osteotome and Kerrison rongeur, which effectively decompressed the median nerve. The patient's complaints resolved almost totally after the operation. Postoperative wrist computed tomography (CT) and three-dimensional CT scan showed heterotopic ossification causing compression of the median nerve [Figures 1 and 2]. At the 1-year follow-up, she had no numbness or pain in her hand.

Discussion

Increased pressure in the carpal tunnel can seriously affect the median nerve and cause CTS.^[2,3] AS is a systemic, progressive inflammatory disease of unknown etiology that mainly affects the axial skeleton. AS rarely causes peripheral neurological symptoms. Hip ankylosis, which is typically accompanied by heterotopic ossification, occurs in about one-third of AS patients.

How to cite this article: Ilik MK. Heterotrophic ossification of the flexor retinaculum in a patient with ankylosing spondylitis. Asian J Neurosurg 2018;13:921-2.

Mustafa Kemal Ilik

Department of Neurosurgery,
Farabi Hospital, Konya, Turkey

Address for correspondence:

Dr. Mustafa Kemal Ilik,
Department of Neurosurgery,
Farabi Hospital, Kosova
Mahallesi Veysel Karani
Caddesi Ebru Sokak No: 14.
İlçe/İl: Selçuklu/Konya, Turkey.
E-mail: mkilik@gmail.com

Access this article online

Website: www.asianjns.org

DOI: 10.4103/ajns.AJNS_20_18

Quick Response Code:



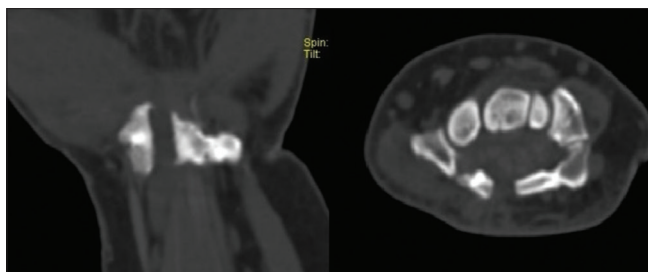


Figure 1: Postoperative axial computed tomography and sagittal computed tomography of the wrist demonstrated heterotopic ossification of retinaculum flexorum

Fibroblasts are the most numerous connective tissue cells in enthesis or ligament tissue and are reported to be associated with heterotopic ossification.^[4]

To the best of our knowledge, ossification of the flexor retinaculum coexisting with AS has never been described. A few studies have reported heterotopic ossification of the flexor retinaculum. Martínez *et al.* reported a case of CTS due to heterotopic ossification of the carpal tunnel without neurological injury or metabolic disorder.^[5] The etiology of heterotopic ossification is unclear, although there is some evidence of a complex interaction between local and systemic factors, including neuroendocrine, genetic, and extrinsic factors.^[5]

Conclusion

AS is a common systemic inflammatory disease that can produce heterotopic ossification of the flexor retinaculum. Preoperative wrist CT should be obtained in patients with CTS and AS, and a wider surgical incision should be used to identify the upper and lower limits of the flexor retinaculum during the operation.

Declaration of patient consent

The authors certify that they have obtained all appropriate patient consent forms. In the form, the patient has given her consent for her images and other clinical information to be reported in the journal. The patient understands that names and initials will not be published and due efforts will be made to conceal identity, but anonymity cannot be guaranteed.

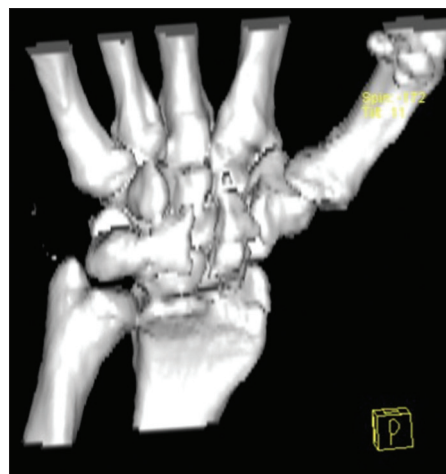


Figure 2: Three-dimensional computed tomography scan showed heterotopic ossification

Financial support and sponsorship

Nil.

Conflicts of interest

There are no conflicts of interest.

References

1. Erkol İnal E, Eroğlu P, Görükmez O, Özemri Sağ Ş, Yakut T. Association between the catechol-o-methyltransferase val158met polymorphism with susceptibility and severity of carpal tunnel syndrome. *Balkan J Med Genet* 2015;18:43-8.
2. Mizia E, Tomaszewski K, Depukat P, Klimek-Piotrowska W, Pasternak A, Mroz I, *et al.* Median nerve (anatomical variations) and carpal tunnel syndrome – Revisited. *Folia Med Cracov* 2013;53:37-46.
3. Eroglu U, Ozgural O, Yakar F, Kahiloğulları G. Endoscopic carpal tunnel decompression: Comparison of mid- and long-term outcomes of 30 endoscopic and 30 standard procedure carpal tunnel decompression operations. *Asian J Neurosurg* 2017;12:534-6.
4. Qin Y, He LD, Sheng ZJ, Yong MM, Sheng YS, Wei Dong X, *et al.* Increased CCL19 and CCL21 levels promote fibroblast ossification in ankylosing spondylitis hip ligament tissue. *BMC Musculoskelet Disord* 2014;15:316.
5. Martínez AA, Peguero A, Canales V, Herrera A. Carpal tunnel syndrome due to heterotopic ossification. *J Orthop Sci* 2003;8:596-8.