

This is an Open Access article licensed under the terms of the Creative Commons Attribution-NonCommercial-NoDerivs 3.0 License ([www.karger.com/OA-license](http://www.karger.com/OA-license)), applicable to the online version of the article only. Distribution for non-commercial purposes only.

# Remarkable Regression of an Osteolytic Lesion of Large Cell Lung Cancer Treated with Zoledronic Acid: A Case Report

Sadayuki Kawai Gengo Yamaura Katsuhiko Yasuda  
Takao Suzuki

Sendai Medical Center, Sendai, Japan

## Key Words

Zoledronic acid · Osteolytic lesion · Large cell lung cancer

## Abstract

Zoledronic acid suppresses osteoclastic changes and reduces the risk of cancer-induced skeletal-related events. Moreover, it has been reported to have antitumor effects. The authors here present a case of a male patient with large cell lung cancer who had an osteolytic lesion in the thoracic vertebrae. The cancer was moderately sensitive to radiation therapy but barely sensitive to chemotherapy with cytotoxic agents. However, it was markedly regressed after zoledronic acid monotherapy, and the patient's symptoms almost disappeared. This remarkable response of large cell lung cancer to zoledronic acid monotherapy is rare.

## Introduction

In recent years, bisphosphonates have become crucial in the management of cancer-induced skeletal-related events (SREs). Previous reports have indicated that zoledronic acid reduces the risk of SREs associated with solid cancers, including lung, breast and prostate cancers [1, 2], and that it has an antitumor effect against multiple myeloma [3]. Moreover, Gnani et al. [4] reported that zoledronic acid prolonged postoperative recurrence-free survival among early breast cancer patients. Here, we present a case of a male patient with large cell lung cancer who had an osteolytic lesion in the thoracic vertebrae. The cancer was barely sensitive to chemotherapy with cytotoxic agents; however, it markedly regressed after zoledronic acid monotherapy. To the best of our knowledge, this remarkable response of large cell lung cancer to zoledronic acid is rare, and we therefore wish to report this case.

## Case Report

The patient was a 59-year-old man who smoked 1 pack of cigarettes per day for 30 years. He visited an orthopedic hospital with upper back pain and anorexia in September 2004. Physical examination revealed marked myosis of the left pupil (Horner's syndrome) and dysesthesia from the left shoulder to the left hand. X-rays showed osteolytic changes in the first to third thoracic vertebrae. A diagnosis of metastatic bone cancer was made, and the patient was referred to our hospital.

For further evaluation, enhanced computed tomography (CT) and magnetic resonance imaging (MRI) were performed. Radiography revealed a heterogeneously enhanced mass in the left superior mediastinum that infiltrated the left side of the first to third thoracic vertebrae ([fig. 1](#)). Only the carcinoembryonic antigen (CEA) tumor marker was elevated at 190.2 ng/ml (normal value <3.4).

At first, lung cancer was suspected and a bronchoscopy was performed; however, no malignant cells were obtained by brush or sputum cytology. Furthermore, there were no other lesions in the body, including the digestive tract. As a result, a primary unknown cancer was diagnosed; however, the possibility of lung cancer could not be completely ruled out. After diagnosis, the patient underwent radiation at 46 Gy directed at the tumor and including the vertebrae. The tumor then regressed and CEA was reduced to 76.8 ng/ml, and pain also disappeared. Although chemotherapy was considered, it was not performed because there was no evidence of malignancy and because of the risks of chemotherapy.

In March 2006, the patient's pain worsened. Two cycles of carboplatin (AUC6) plus weekly paclitaxel (80 mg/m<sup>2</sup>) were administered for the primary unknown cancer. However, the tumor progressed and CEA was elevated, and therefore therapy was discontinued. Gemcitabine (1,000 mg/m<sup>2</sup>) therapy for lung cancer was then tried. After 9 administrations, the best overall response was stable disease (response evaluation criteria in solid tumors version 1.1). However, the pain gradually worsened and adverse events (gastrointestinal toxicity: grade 3, myelosuppression: grade 3, and repeated pneumonia: grade 3; common terminology criteria for adverse events version 3.0) also occurred. The patient wished to discontinue cytotoxic chemotherapy, and we agreed.

In Japan, zoledronic acid was approved in January 2005 for hypercalcemia induced by malignant disease. In April 2006, it was also approved for bone metastasis of malignant disease. Zoledronic acid (4 mg per month) was administered to the patient from September 2006. In January 2007, after 5 administrations, his pain reduced drastically. Moreover, CEA was also reduced and marked regression of the vertebral and left apical lesions was observed ([fig. 2](#), [fig. 3](#)). In March 2008, CT-guided biopsy revealed that the tumor was large cell lung cancer. Because the patient did not want to receive any cytotoxic chemotherapy, zoledronic acid monotherapy was continued until December 2008. No adverse events were observed. In February 2009, because of necrosis of the left upper and lower jaw, zoledronic acid was discontinued. In April 2009, due to aggravation of pain and dysesthesia of the lower limbs, the patient wished to undergo surgery involving the vertebrae despite the surgical risks. In the same month, laminectomy, posterior decompression and vertebral fusion were performed. Unfortunately, however, paralysis of the lower half of the body and bladder and rectal disturbance appeared postoperatively. Thereafter, the patient experienced pneumonia and a pressure ulcer, and he finally died in January 2010. Survival from the time of the appearance of symptoms was 5 years and 4 months.

## Discussion

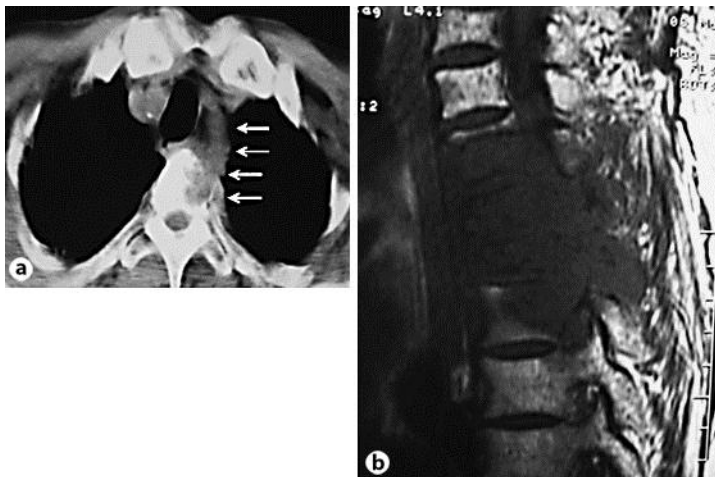
Nitrogen-containing bisphosphonates, including zoledronic acid, suppress osteoclast changes due to metastatic malignant disease by inducing apoptosis of osteoclasts [5]. Moreover, zoledronic acid has been shown to exert direct and indirect antitumor effects via immunologic mechanisms and anti-angiogenic effects in vitro and in vivo [6]. However, the detailed mechanisms behind these effects remain unclear.

Among clinical studies, a phase III study indicated that zoledronic acid decreased SREs due to bone metastasis of non-small cell lung cancer (NSCLC) [2]. However, no

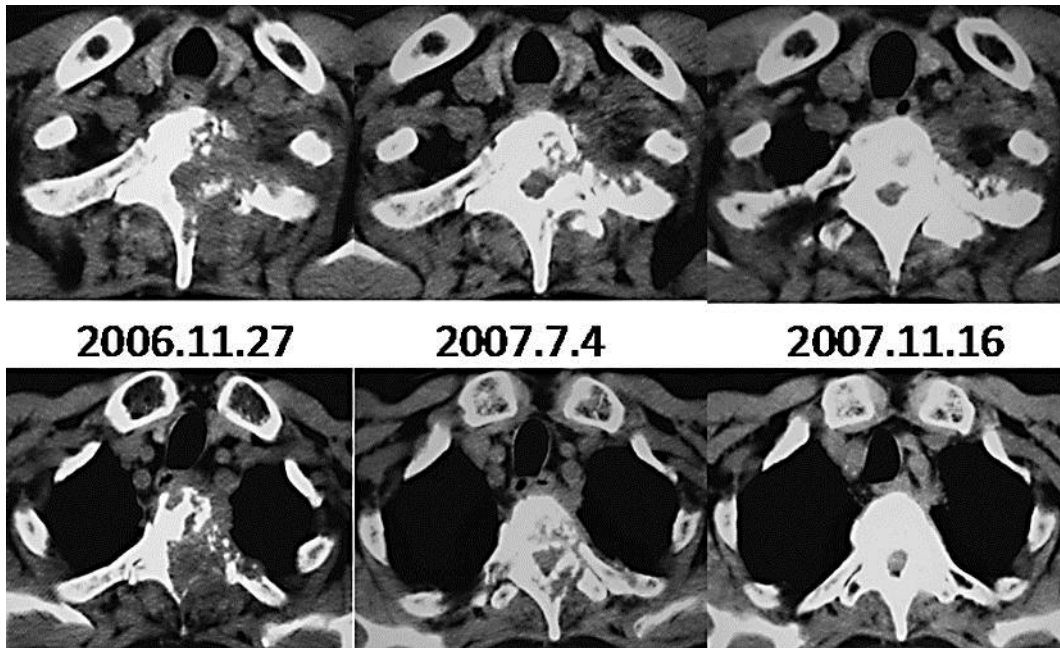
effect on tumor regression (including from bone metastasis) or contribution to prolonging overall survival has been established. Some clinical studies have indicated that high N-telopeptide of type I collagen (NTX), which reflects bone resorption, is a risk factor for SREs; however, it is also a possible predictive marker of tumor regression by zoledronic acid in NSCLC patients [7]. Furthermore, serum vascular endothelial growth factor levels in NSCLC patients with bone metastasis decreased following administration of zoledronic acid and this is correlated with tumor response [8]. Nagao et al. [9] reported that zoledronic acid monotherapy reduced extra osseous lesions associated with lung adenocarcinoma. Thus, it is supposed that certain types of NSCLC are sensitive to zoledronic acid. Our patient's symptoms rapidly improved and CEA was reduced after 5 administrations of zoledronic acid. NTX could thus be a surrogate marker of improvement. Though zoledronic acid is associated with some severe adverse events such as osteonecrosis of the jaw or renal dysfunction, a positive correlation between the number of cycles of therapy with zoledronic acid and progression-free and overall survival has been reported [10]. We suggest that it is important to continue zoledronic acid administration in NSCLC patients with bone lesions for as long as possible from the early stages of disease in order to determine the nature of responders, such as the case presented herein. At the moment, NTX may be considered a good marker of the effects of zoledronic acid therapy.

#### Disclosure Statement

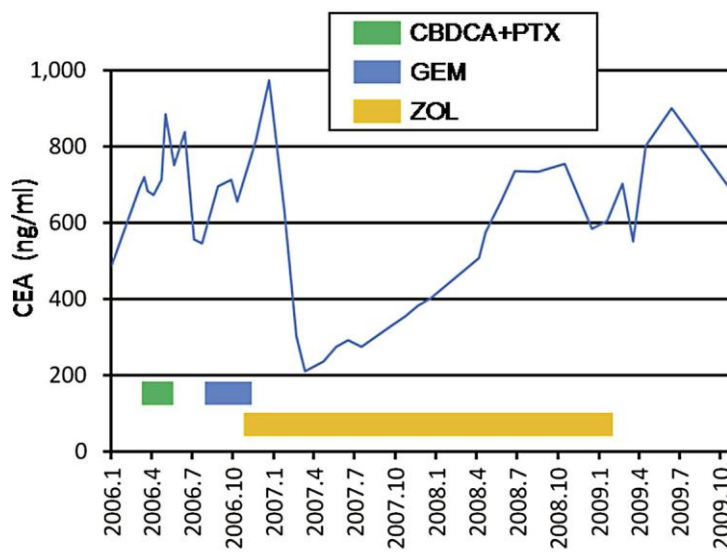
The authors declare no conflict of interest.



**Fig. 1.** a Enhanced CT examination performed on the patient's first visit. Arrows indicate the tumor. b A sagittal image of the osteolytic lesion of the thoracic vertebrae shown by MRI on the patient's first visit.



**Fig. 2.** Changes to the vertebral lesions after zoledronic acid monotherapy. The first (upper images) and second (lower images) vertebrae are shown.



**Fig. 3.** Time course of the serum CEA tumor marker from January 2006 to October 2009. The green, blue, and yellow lines indicate the period of administration of carboplatin (CBDCA) + paclitaxel (PTX), gemcitabine (GEM), and zoledronic acid (ZOL), respectively.

## References

- 1 Costa L: Bisphosphonates: reducing the risk of skeletal complications from bone metastasis. *Breast* 2007;(suppl 3):S16–S20.
- 2 Rosen LS, Gordon D, Tchekmedyian S, Yanagihara R, Hirsh V, Krzakowski M, Pawlicki M, de Souza P, Zheng M, Urbanowitz G, Reitsma D, Seaman JJ: Zoledronic acid versus placebo in the treatment of skeletal metastases in patients with lung cancer and other solid tumors: a phase III, double-blind, randomized trial –the Zoledronic Acid Lung Cancer and Other Solid Tumors Study Group. *J Clin Oncol* 2003;21:3150–3157.
- 3 Morgan GJ, Child JA, Gregory WM, Szubert AJ, Cocks K, Bell SE, Navarro-Coy N, Drayson MT, Owen RG, Feyler S, Ashcroft AJ, Ross FM, Byrne J, Roddie H, Rudin C, Cook G, Jackson GH, Wu P, Davies FE: Effects of zoledronic acid versus clodronic acid on skeletal morbidity in patients with newly diagnosed multiple myeloma (MRC Myeloma IX): secondary outcomes from a randomised controlled trial. *Lancet Oncol* 2011;12:743–752.
- 4 Gnant M, Mlineritsch B, Schippinger W, Luschin-Ebengreuth G, Pbstlberger S, Menzel C, Jakesz R, Seifert M, Hubalek M, Bjelic-Radisic V, Samonigg H, Tausch C, Eidtmann H, Steger G, Kwasny W, Dubsy P, Fridrik M, Fitzal F, Stierer M, Rucklinger E, Greil R, ABCSG-12 Trial Investigators, Marth C: Endocrine therapy plus zoledronic acid in premenopausal breast cancer. *N Engl J Med* 2009;360:679–691.
- 5 Roelofs AJ, Thompson K, Gordon S, Rogers MJ: Molecular mechanisms of action of bisphosphonates: current status. *Clin Cancer Res* 2006;12(20 Pt 2):6222s–6230s.
- 6 Guise TA: Antitumor effects of bisphosphonates: promising preclinical evidence. *Cancer Treat Rev* 2008;34(suppl V):S19–S24.
- 7 Hirsh V, Major PP, Lipton A, Cook RJ, Langer CJ, Smith MR, Brown JE, Coleman RE: Zoledronic acid and survival in patients with metastatic bone disease from lung cancer and elevated markers of osteoclast activity. *J Thorac Oncol* 2008;3:228–236.
- 8 Mahtani R, Khan R, Jahanzeb M: The potential application of zoledronic acid as anticancer therapy in patients with non-small-cell lung cancer. *Clin Lung Cancer* 2011;12:26–32.
- 9 Nagao S, Hattori N, Fujitaka K, Iwamoto H, Ohshimo S, Kanehara M, Ishikawa N, Haruta Y, Murai H, Kohno N: Regression of a primary pulmonary adenocarcinoma after zoledronic acid monotherapy. *Hiroshima J Med Sci* 2011;60:7–9.
- 10 Zarogoulidis K, Boutsikou E, Zarogoulidis P, Eleftheriadou E, Kontakiotis T, Lithoxopoulou H, Tzanakakis G, Kanakis I, Karamanos NK: The impact of zoledronic acid therapy in survival of lung cancer patients with bone metastasis. *Int J Cancer* 2009;125:1705–1709.