



## Case Report

## “EEG abnormalities” may represent a confounding factor in celiac disease: A 4-year follow-up family report



Pasquale Parisi<sup>a,\*</sup>, Luigi Principessa<sup>a</sup>, Alessandro Ferretti<sup>a</sup>, Danila D'Onofrio<sup>a</sup>, Ennio Del Giudice<sup>b</sup>, Claudia Pacchiarotti<sup>a</sup>, Maria Pia Villa<sup>a</sup>

<sup>a</sup> Pediatrics and Child Neurology Unit, NESMOS Dept., Faculty of Medicine and Psychology, Sapienza University of Rome, S. Andrea Hospital, Via di Grottarossa, 1035-1039, 00189 Rome, Italy

<sup>b</sup> Dept. of Pediatrics, University of Naples Federico II, Naples, Italy

## ARTICLE INFO

## Article history:

Received 9 January 2014

Received in revised form 20 January 2014

Accepted 30 January 2014

Available online 15 March 2014

## Keywords:

Celiac disease

Children

EEG abnormalities

Benign epilepsy of infancy

## ABSTRACT

**Objective:** The occurrence of celiac disease (CD), electroencephalographic (EEG) abnormalities (with “subtle” seizures or even without any clinical seizures), and neurological disorders has been reported since the 1980s, though there has been no definitive consensus about the possible causal relationship. This topic is further complicated by the occurrence in infancy of ‘clinical-EEG pictures’ called ‘benign epilepsy of infancy’.

**Methods and results:** Here, we report a 4-year follow-up on two siblings with newly diagnosed biopsy-proven celiac disease showing EEG abnormalities not responsive to a gluten-free diet.

**Conclusions:** This family report indicates that in patients with neurologically asymptomatic CD and EEG abnormalities, it is advisable to make a differential diagnosis between EEG abnormalities associated with CD and an incidental association with cortical hyperexcitability, with “subtle” seizures or even without any clinical seizures.

**Practice implications:** A long follow-up may sometimes be required, as it was in the family described here, to clarify the etiopathogenetic and therapeutic relationships between clinical and EEG features in CD.

© 2014 The Authors. Published by Elsevier Inc. This is an open access article under the CC BY-NC-ND license (<http://creativecommons.org/licenses/by-nc-nd/3.0/>).

### 1. Introduction

Celiac disease (CD) is a chronic autoimmune disorder of the small intestine. It occurs in genetically predisposed individuals expressing the HLA DQ2 or DQ8 and is caused by an inflammatory reaction to gliadin. The clinical manifestation of typical forms of CD gives rise to gastrointestinal symptoms. The atypical form is characterized by extraintestinal manifestations and neurological disorders such as seizures and headache. Celiac disease can occur in apparently healthy subjects (silent CD) or, later in life, in those with positive CD-related autoantibodies but with a normal intestinal biopsy (potential CD) [1]. The overall prevalence of CD ranges from 0.4% to 1.3% in childhood. The relative risk of epilepsy in individuals with CD or of CD in individuals with epilepsy, when compared with the general population, is 2.1 and 1.7, respectively [2]. The clinical spectrum of epilepsy in association with CD varies from focal (usually occipital) to generalized epilepsy, with varying outcomes and responses to gluten restriction [3].

**Abbreviations:** BECTS, benign epilepsy with centrotemporal spikes; BEI, benign epilepsy of infancy; CD, celiac disease; EEG, electroencephalography; GFD, gluten-free diet; GS, Gastaut syndrome; PS, Panayiotopoulos syndrome.

\* Corresponding author at: NESMOS Dept., Faculty of Medicine and Psychology, Sapienza University of Rome, S. Andrea Hospital, Via di Grottarossa, 1035-1039, 00189 Rome, Italy. Tel.: +39 330556796; fax: +39 06 33775941.

E-mail address: [pasquale.paris@uniroma1.it](mailto:pasquale.paris@uniroma1.it) (P. Parisi).

The investigation of EEG abnormalities in children with CD is complicated by the occurrence in infancy of ‘benign epilepsy of infancy’ (BEI). In particular, BEI is a specific electroclinical syndrome with onset during infancy, which basically has 3 phenotypes, according to Vigeveno et al. [4]. The form of benign partial epilepsy with vertex or central spikes or spikes and waves during sleep can have its onset also during early childhood. In any of these forms, there are “unprovoked seizures” as criteria for diagnosis sometimes, but not always, presenting as clustered seizures at the onset of the disease. To date, it is unclear if this form could be an earlier form of “benign epilepsy with centrotemporal spikes” (BECTS). The EEG abnormalities can be age-related, and their prevalence during childhood can be high; some authors used even higher figures for their prevalence [5], and, there is a possibility of incidental association vs “EEG abnormalities caused by CD”.

From the EEG point of view, the centrotemporal, occipital, frontal, parietal, and midline spikes are not specific to any syndrome as they also occur in 2–4% of young patients with nonepileptic disorders [6]. Moreover, occipital paroxysms are a nonspecific electroencephalographic manifestation observed in many epileptic and nonepileptic disorders. They are morphologically similar to the abnormalities observed in BECTS, the main difference being that the waves occur in the occipital rather than in the centrotemporal regions [7]. As in BEI, subclinical cortical hyperexcitability in healthy children (without associated

clinical recognizable seizures) may migrate to different brain areas as an expression of maturation, though no studies that have yet provided conclusive data exist, suggesting that this migrating hyperexcitability is age-related.

## 2. Family report

A 5-year-old Italian boy was referred to us because of first and only simple febrile seizures. There was no family history of epilepsy or migraine. His birth and neurological and psychomotor development were normal. Following admission, a sleep EEG revealed left temporal spike-and-wave discharges and generalized abnormal activity.

Owing to the patient's poor growth, diarrhea, and recurrent oral aphthosis, we decided to perform a CD screening, which disclosed positive CD antibodies. A small bowel biopsy confirmed the diagnosis of CD. The DQ2 HLA was also positive. The patient was placed on a GFD. After the diet was started, the patient's antibody levels dropped progressively and disappeared together with the symptoms described. An awake EEG, performed 10, 16, and 19 months after the start of the diet, revealed the persistence of the aforementioned abnormalities; therefore, the patient underwent a neuroradiological and cognitive profile examination, which were normal.

Sleep EEG was performed 2 and 4 years after the start of the diet, which revealed the presence of EEG paroxysmal abnormalities in large-type triphasic sharp waves in the central regions; these abnormalities were prevalently on the right and were fairly active during sleep. The child had always been seizure-free, and his cognitive profile had remained unchanged over time. The patient's younger sister was hospitalized for clinical and diagnostic examinations owing to a suspected iron deficiency and poor growth at the age of 4 years. Given the family's

medical history, a CD screening and an EEG examination were also performed on the patient's sister.

As the CD antibodies, DQ2 HLA, and intestinal biopsy proved to be positive in the sister, she was also placed on a GFD with rapid resumption of growth. Her awake EEG recorded several bursts of bilateral occipital spikes (Fig. 1A) and widespread polyspikes and sharp waves. The subsequent EEGs revealed a migration of the abnormalities from the occipital to the temporal region, with sharp waves and biphasic and triphasic spikes being described in the left centrotemporal region (Fig. 1B). A polysomnography performed 2 years later confirmed the presence of this migration, with paroxysmal abnormalities with no apparent clinical correlates which were fairly active in sleep. The patient's neuroimaging and cognitive profiles were always normal.

## 3. Discussion

The association between CD and epilepsy is well known: individuals with CD have an increased risk of developing neurological complications, but the reason is still unclear [8]. Owing to the persistence of some anomalies despite the GFD and to the characteristic migration of EEG abnormalities in a posterior–anterior direction observed in the younger sister, the hypothesis of BECTS was considered in our patient. The absence of the characteristic migration in a posterior–anterior direction in the boy is likely to be due to the fact that he was older when he underwent the first EEG. The presumptive diagnosis of BECTS (without clinical seizures or with subtle, not recognized seizures) was supported by the high prevalence of this disease in childhood, by the patient's age at onset of symptoms, by the abnormalities being detected in both siblings, and by the preservation of the cognitive profile.

This hypothesis was subsequently abandoned owing to the lack of a clinical correlate, which is a fundamental requirement in the diagnosis

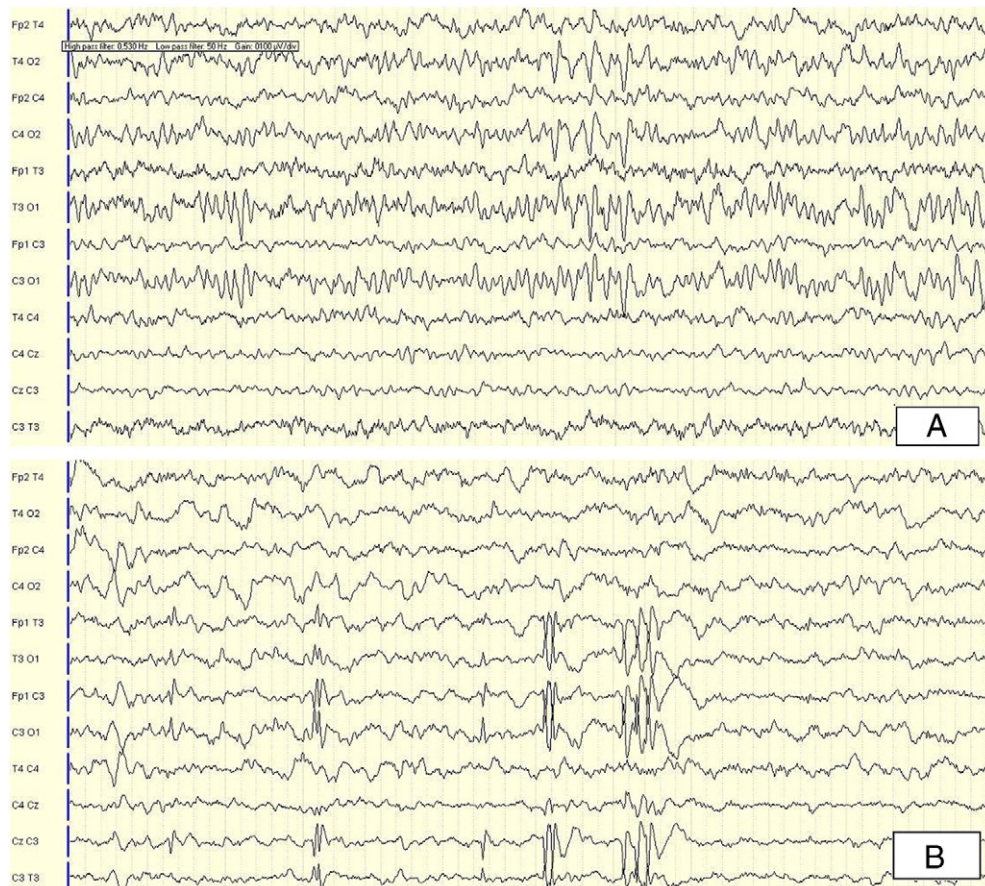


Fig. 1. (A) Bilateral occipital spikes; (B) sharp waves and biphasic and triphasic spikes in the left centrotemporal region.

of BECTS or BEI. We cannot, however, rule out the possibility that minimal, rare clinical seizures might have escaped detection both by the parents and during the two polysomnographies that were performed.

To our knowledge, there are no scientific studies on large populations of subjects with celiac disease with subclinical EEG abnormalities and, in particular, on their behavior after initiation of a GFD.

Since nonspecific abnormalities in the healthy pediatric population have been reported, the abnormal EEG findings observed in our patients with CD may merely be an incidental finding. Capdevila et al. [9] reported that a polysomnography detected neuronal hyperexcitability in 1.45% of healthy children, most of whom presented spike and spike-and-wave patterns in the centrotemporal regions, suggesting some similarities with the interictal epileptiform discharges of BECTS. Moreover, while family history and genetic susceptibility in CD are well documented, no data exist on neuronal hyperexcitability. Indeed, the presence of EEG abnormalities may merely be an incidental finding.

Electroencephalographic abnormalities may therefore be due to the following: (i) subclinical expressions of neuronal hyperexcitability related to CD; (ii) EEG abnormalities related to BECTS whose clinical manifestations escaped detection; and (iii) sporadic abnormalities as may be found in a small portion of healthy children. Moreover, is there a statistically significant prevalence of subclinical EEG abnormalities in patients with CD compared with the healthy pediatric population?

Clinicians should be aware of the possibility that CD and epilepsy could be more often diagnosed in the same child compared with the general population, so careful judgment of each clinical situation, first, depending on clinical and then on complementary evaluations, is needed in order to differentiate between incidental vs cause-and-effect relation between CD and epilepsy.

The presented family did not have BEI, at least, according to the definition of ILAE. There is just a possibility of incidental association vs “EEG abnormalities caused by CD”. However, an incidental finding, as it seems to be the case in the presented family, could be more frequent at this age but not excluding, of course, a direct association of cause-and-effect relation between these two disorders. In any case, other possible relations between CD and epilepsy not of the cause-and-effect type should also be kept in mind.

Finally, we think that the presented family deserves to be reported because this intriguing situation is frequent in pediatric neurology: in fact, often, the epileptiform abnormalities, especially those with centrotemporal location, can be present, even without seizures, during childhood in the relatives of patients with epileptic seizures.

In this regard, it would be interesting to conduct a study designed to investigate the presence of EEG abnormalities in children in whom a diagnosis of CD is made, though before the initiation of a GFD, and to monitor these abnormalities over time. This family report suggests that in patients who have CD associated with EEG abnormalities, but who are neurologically asymptomatic, it may be advisable to consider a differential diagnosis between EEG abnormalities caused by CD and a simple incidental association with neuronal hyperexcitability without clinical seizures, as we suppose it happened in this described family. On the other hand, it should be stressed that, rarely, the same EEG picture may be associated with subclinical BECTS, and (taking into account that the subtle clinical manifestations of BECTS are often observed exclusively during sleep), in such cases, an all-night polysomnography can be crucial for the correct differential diagnosis.

### Financial disclosure

The authors have no financial relationships to disclose with regard to this article.

### References

- [1] Nenna R, Tiberti C, Petrarca L, Lucantoni F, Mennini M, Luparia RP, et al. The celiac iceberg: characterization of the disease in primary school children. *J Pediatr Gastroenterol Nutr* 2013;56:416–21.
- [2] Lionetti E, Francavilla R, Pavone P, Pavone L, Francavilla T, Pulvirenti A, et al. The neurology of coeliac disease in childhood: what is the evidence? A systematic review and meta-analysis. *Dev Med Child Neurol* 2010;52:700–7.
- [3] Mavroudi A, Karatza E, Papastavrou T, Panteliadis C, Spiroglou K. Successful treatment of epilepsy and celiac disease with a gluten-free diet. *Pediatr Neurol* 2005;33:292–5.
- [4] Vigeveno F, Bureau M. Idiopathic and/or benign localization-related epilepsies in infants and young children. In: Roger J, Bureau M, Dravet Ch, Genton P, Tassinari CA, Wolf P, editors. *Epileptic Syndromes in Infancy, Childhood and Adolescence*. 4th ed. Montrouge, France: John Libbey Eurotext; 2005. p. 171–9.
- [5] Borusiak P, Zillbauer M, Jenke AC. Prevalence of epileptiform discharges in healthy children — new data from a prospective study using digital EEG. *Epilepsia* 2010;51:1185–8.
- [6] Michael M, Tsatsou K, Ferrie CD. Panayiotopoulos syndrome: an important childhood autonomic epilepsy to be differentiated from occipital epilepsy and acute non-epileptic disorders. *Brain Dev* 2010;32:4–9.
- [7] Kivity S, Ephraim T, Weitz R, Tamir A. Childhood epilepsy with occipital paroxysms: clinical variants in 134 patients. *Epilepsia* 2000;41:1522–33.
- [8] Luostarinen L, Pirttilä T, Collin P. Coeliac disease presenting with neurological disorders. *Eur Neurol* 1999;42:132–5.
- [9] Capdevila OS, Dayyat E, Kheirandish-Gozal L, Gozal D. Prevalence of epileptiform activity in healthy children during sleep. *Sleep Med* 2008;9:303–9.