

Emphysematous pyelonephritis and cystitis in a patient with uremia and anuria

A case report and literature review

Qiang Wang, MD, PhD^a, Meifeng Sun^b, Chengjun Ma, MD^a, Hailin Lv, MD^a, Peng Lu, MD^a, Qi Wang, MD^a, Guangyi Liu, MD, PhD^a, Zhao Hu, MD^a, Yanxia Gao, MD^{a,*}

Abstract

Introduction: Emphysematous pyelonephritis (EPN) or cystitis (EC) is a severe infection of the urinary tract with high mortality. EPN is uncommon among the patients of end stage of renal failure (ESRD)

Case presentation: A 38-year-old male with uremia and anuria who was on hemodialysis was found to have gas formation in the bilateral pelvis, ureters, and urinary bladder by CT scan. The diagnosis was emphysematous pyelonephritis and cystitis. And Foley catheter was placed and bladder irrigation was performed. *Escherichia coli* infection was identified in urine culture and antibiotic was prescribed accordingly. Gas disappeared completely and the patient recovered uneventfully.

Conclusion: This is the first case report of asymptomatic EPN and EC in uremic patient, and conservative management was optimistic in this condition. More attention should be paid to EPN and EC happening to ESRD patients.

Abbreviations: EC = emphysematous cystitis, EPN = emphysematous pyelonephritis, ESRD = end stage of renal failure.

Keywords: emphysematous cystitis, emphysematous pyelonephritis, *Escherichia coli*, hemodialysis, uremia

1. Introduction

Emphysematous pyelonephritis (EPN) or cystitis (EC), usually occurred in diabetes, is a severe infection of the urinary tract with mortality of 8.7% to 21%.^[1,2] The characteristic is gas accumulation in the renal parenchyma, collecting system, perirenal tissues, and urinary bladder.^[3] *Escherichia coli* (*E coli*) was the most common encountered bacteria in this condition,^[4] and other bacteria like *Klebsiella*, *Proteus*, *Pseudomonas*, *Clostridium*, *Streptococcus*, *Proteus mirabilis*, *Enterobacter aerogenes*, *Coagulase-negative Staphylococcus* and even fungi were also seen.^[5,6] Computed tomography (CT) is recommended for the classification of this disease. Besides intravenous antibiotics, invasive treatment including nephrectomy and

percutaneous drainage should be considered based on the classification and condition of the patients.^[7]

Normally, it happens to elderly patients. We now present a case of a young uremic male with both EPN and EC.

2. Method

The study was approved by the Research Ethics Committee of the Qilu Hospital of Shandong University. Informed consent was obtained from the patient for the publication of the report.

3. Case presentation

A 38-year-old male with anuria had been on hemodialysis for 6 years. He was diagnosed with Type 1 diabetes 15-year ago and was admitted to the nephrology division with a one-week history of fever. Quite unexpectedly, the fever ceased shortly after admission without medication. He had no abdominal pain or tenderness. At presentation, blood tests revealed normal WBC count, higher neutrophil and monocyte percentages, and anemia (hemoglobin 80 g/L). His glucose was 16.64 mmol/L, albumin was 40 g/L, glycosylated hemoglobin A1C (HbA1c) was 8.14%, CRP was 34.29 mg/L, and ESR was 40 mm/h. The CT scan of abdomen revealed gas formation at bilateral renal pelvis and ureters, and a clear gas-fluid level inside the bladder (Fig. 1A–C). The findings were consistent with emphysematous pyelonephritis (EPN) and cystitis (EC). Around 400 mL laurel-green milk-like urine was collected after the placement of the Foley catheter, bladder irrigation using normal saline was then ordered being performed twice a day. Blood glucose was controlled. Subsequently, *E coli* was found to be positive in the urine culture, and intravenous levofloxacin was initiated according to the drug-susceptibility test results, which was administered for 14 days. The gas in the urinary tract disappeared after the treatment (Fig. 1D–E), and CRP and ESR returned to normal as well. The

Editor: N/A.

This work was supported by the Natural Science Foundation of Shandong province, China (ZR2014JH054), and the Youth foundation of Qilu Hospital of Shandong University (Qingdao) (QDKY2017QN01).

The authors have no funding and no conflicts of interest to disclose.

Supplemental Digital Content is available for this article.

^a Department of Nephrology, Qilu Hospital of Shandong University (Qingdao),

^b Department of Rehabilitation, Affiliated Hospital of Qingdao University, PR China.

* Correspondence: Yanxia Gao, Department of Nephrology, Qilu Hospital of Shandong University (Qingdao), No. 758 Hefei Road, Qingdao, PR China (e-mail: gaoyanxia31@163.Com).

Copyright © 2018 the Author(s). Published by Wolters Kluwer Health, Inc. This is an open access article distributed under the terms of the Creative Commons Attribution-Non Commercial License 4.0 (CCBY-NC), where it is permissible to download, share, remix, transform, and buildup the work provided it is properly cited. The work cannot be used commercially without permission from the journal.

Medicine (2018) 97:45(e11272)

Received: 30 March 2018 / Accepted: 24 May 2018

<http://dx.doi.org/10.1097/MD.00000000000011272>

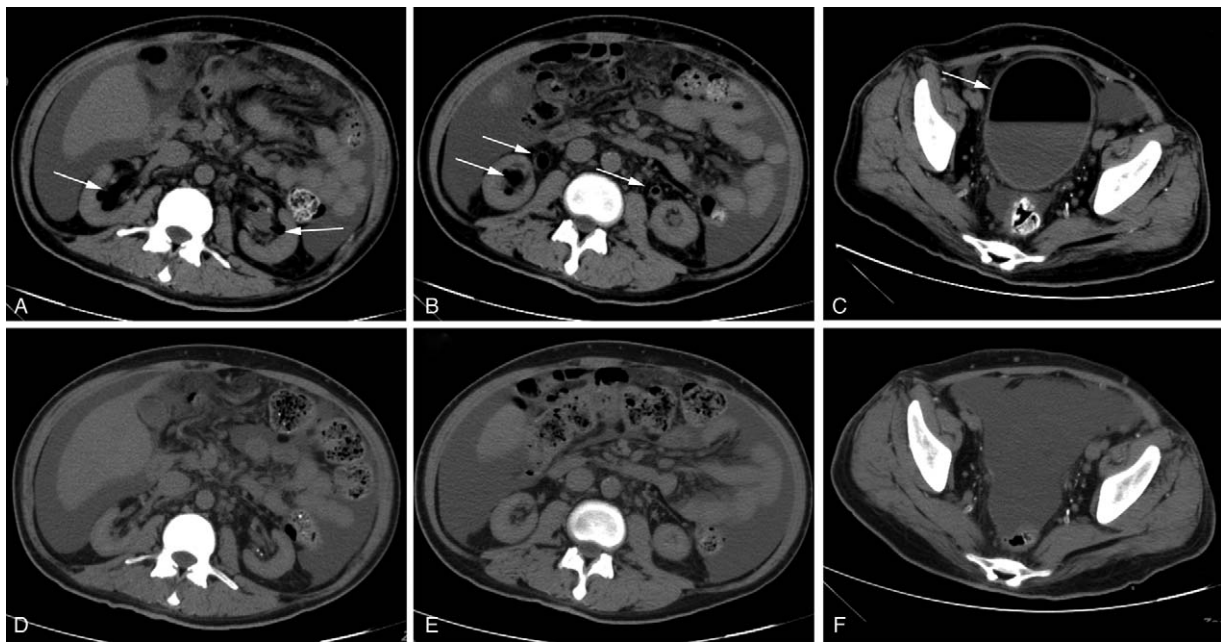


Figure 1. Gas formation in bilateral renal pelvis (A), ureters (B), and urinary bladder (C). No gas existed in the above locations after treatment (D–F).

patient was asymptomatic throughout his hospitalization. No gas formation was demonstrated in his CT scan at 1-month follow-up (Supplemental Fig. 1, <http://links.lww.com/MD/C624>).

4. Discussion

Emphysematous pyelonephritis was a necrotizing infection of renal parenchyma. More and more cases were reported nowadays. However, combined bilateral EPN and EC were still uncommon among the patients of end stage of renal failure (ESRD). Fever, flank pain, nausea and vomiting were the common presenting symptoms, with rapid occurrence of renal failure or shock sometimes. This patient was diagnosed with ESRD with anuria 6-year ago. Based on his history and symptoms, the patient was considered to have neurogenic bladder with small amount of residual urine accumulated over the time not being able to urinate. The milk-like urine must be originated from bacterial metabolites and exudation of urinary tract. Urine and blood cultures (both aerobic and anaerobe) were conducted. Consistent with most of the literatures, the patient's pathogen was *E coli* and he does have a history of diabetes. The diagnoses of EPN and EC were therefore confirmed.

Two different categories of EPN based on CT were adopted in the literatures. Wan et al^[8] divided it into 2 types, Type I EPN: renal parenchymal with absence of fluid content or the presence of streaky/mottled gas; Type II EPN: the presence of renal or perirenal fluid accompanied by a bubbly gas pattern or presence of gas in the collecting system. The other criteria proposed by Huang et al^[9] including 4 classes. Class 1: Gas located only in collecting system- emphysematous pyelitis; Class 2: Gas inside the renal parenchyma without extra renal extension; Class 3A: Gas or abscess extending into perinephric space; Class 3B: Gas or abscess spreading into paranephric space; Class 4: EPN in solitary kidney or bilateral involvement. Based on Wan's categorization and Huang's classification, this patient was allocated to Type I and Class 4, respectively. So far, no randomized controlled study

completed to observe the correlation between the prognoses and categories yet.

The management of EPN was still controversial; moreover, there was no reported experience we could refer to for the treatment of asymptomatic EPN and EC. The prognosis of EC was relatively better, and appropriate intravenous antibiotics are usually recommended.^[10] Based on CT imagine, emergent nephrectomy should be considered for the initial management of type I EPN, and percutaneous drainage was recommended for the treatment of type II EPN.^[7] Risk factors such as hypoalbuminemia, shock, bacteremia, the need for hemodialysis, and polymicrobial infections were associated with higher mortality.^[5] Two or more factors indicated highest mortality and required aggressive management, but none of these risk factors existed in this patient. Moreover, Lin's study showed that invasive treatment approach might predict CKD (chronic kidney disease) development, and appropriate antibiotics treatment alone still got fair prognosis. However, unlike asymptomatic bacteriuria in diabetic patients, appropriate and prompt management was necessary for the treatment of EPN and EC with apparent imaging evidence and their potent mortality, albeit this patient was asymptomatic. Levofloxacin was therefore administrated and the outcome was closely monitored with aggressive surgical approach used only if necessary. Consequently, gas in the pelvis and ureters was absorbed completely. It indicated that asymptomatic EPN and EC may have good prognosis.

More attention should be paid to EPN and EC complicated with CKD or ESRD. To date, 20 cases of EPN with ESRD were able to be retrieved on PubMed.^[11–15] However, 4 of the 20 patients have to be excluded due to a lack of detailed information. Of the rest 16 patients with 7 males and 9 females, 2 were on peritoneal dialysis and 14 were on hemodialysis. The average age was 60.25 years old (38–80). The common bacteria were *E. coli* (56.2%) and *Klebsiella* (12.5%). Overall, 4 patients recovered after being treated with antibiotic only, and 2 patients died

(12.5%). Most cases (68.8%) happened in patients with diabetic nephropathy. Several factors may be involved in the pathogenesis of EPN and EC in this group: growth of bacteria was convenient in hyperglycemic condition; rinse action of urine was reduced while CKD progress to anuria and oliguria; renal blood supply was losing as the eGFR reduced, thus urinary tract is prone to necrosis due to stress or infection; lower immunity of CKD patients, especially when complicated with diabetes.^[11,16] Generally speaking, the prognosis of EPN in ESRD patients is optimistic with appropriate treatment according to the data as above.

This case has 4 features, asymptomatic: no symptoms of urethritis or micturition desire, even when fluid and gas were identified in his urinary bladder from the abdominal CT. The fever was not associated with the infection because it vanished without treatment; younger age: 38 years old was the youngest one in previous literatures;^[11] bilateral EPN: incidence of bilateral EPN was uncommon; intravenous antibiotic only: conservative management resulted in a good outcome.

In summary, this is the first case report of asymptomatic EPN and EC in uremic patient. Conservative management could be considered in the treatment of these patients. For anuric patient, the prevention of recurrence of EPN and EC could be a challenge. More case studies and long-time follow-up are warranted.

Author contributions

Writing – original draft: Qiang Wang, Meifeng Sun.

Data curation: Chengjun Ma, Hailin Lv, Qi Wang.

Software: Peng Lu.

Investigation: Guangyi Liu.

Writing – review & editing: Zhao Hu.

Visualization: Yanxia Gao.

References

- [1] Lu YC, Chiang BJ, Pong YH, et al. Emphysematous pyelonephritis: clinical characteristics and prognostic factors. *Int J Urol* 2014;21:277–82.

- [2] Schicho A, Stroszczyński C, Wiggermann P. Emphysematous cystitis: mortality, risk factors, and pathogens of a rare disease. *Clin Pract* 2017;7:930.
- [3] Shokeir AA, El-Azab M, Mohsen T, et al. Emphysematous pyelonephritis: a 15-year experience with 20 cases. *Urology* 1997;49:343–6.
- [4] Lu YC, Hong JH, Chiang BJ, et al. Recommended initial antimicrobial therapy for emphysematous pyelonephritis: 51 cases and 14-year-experience of a tertiary referral center. *Medicine* 2016;95:e3573.
- [5] Lu YC, Chiang BJ, Pong YH, et al. Predictors of failure of conservative treatment among patients with emphysematous pyelonephritis. *BMC Infect Dis* 2014;14:418.
- [6] Sokhal AK, Kumar M, Purkait B, et al. Emphysematous pyelonephritis: changing trend of clinical spectrum, pathogenesis, management and outcome. *Turk J Urol* 2017;43:202–9.
- [7] Lin WR, Chen M, Hsu JM, et al. Emphysematous pyelonephritis: patient characteristics and management approach. *Urol Int* 2014;93:29–33.
- [8] Wan YL, Lee TY, Bullard MJ, et al. Acute gas-producing bacterial renal infection: correlation between imaging findings and clinical outcome. *Radiology* 1996;198:433–8.
- [9] Huang JJ, Tseng CC. Emphysematous pyelonephritis: clinicoradiological classification, management, prognosis, and pathogenesis. *Arch Intern Med* 2000;160:797–805.
- [10] Bjurlin MA, Hurley SD, Kim DY, et al. Clinical outcomes of nonoperative management in emphysematous urinary tract infections. *Urology* 2012;79:1281–5.
- [11] Vlachopoulos G, Kassimatis T, Zerva A, et al. Successful medical treatment of emphysematous pyelonephritis in chronic hemodialysis. *Hemodial Int* 2015;19:E54–58.
- [12] Suzuki R, Abe T, Uchida H, et al. Successful management of bilateral emphysematous pyelonephritis with abscess formation in a chronic hemodialysis patient: a case report. *CEN Case Rep* 2015;4:90–4.
- [13] Hamouda M, Aloui S, Skhiri H, et al. Emphysematous pyelonephritis in a diabetic patient on maintenance hemodialysis: a case report. *Arab J Nephrol Transplant* 2014;7:109–11.
- [14] Voss DM, Chalmers N, Cumming AD. End-stage renal failure in a solitary kidney from emphysematous pyelonephritis. *Nephron* 1996;72:348–9.
- [15] Lin YC, Lin YC, Lin HD, et al. Risk factors of renal failure and severe complications in patients with emphysematous pyelonephritis—a single-center 15-year experience. *Am J Med Sci* 2012;343:186–91.
- [16] Tseng CC, Wu JJ, Wang MC, et al. Host and bacterial virulence factors predisposing to emphysematous pyelonephritis. *Am J Kidney Dis* 2005;46:432–9.