

Posture-Dependent Collapse of the Optic Nerve Subarachnoid Space: A Combined MRI and Modeling Study

We have read with great interest the intriguing article, “Posture-Dependent Collapse of the Optic Nerve Subarachnoid Space: A Combined MRI and Modeling Study.”¹ The authors describe a “collapse” of the optic nerve subarachnoid space (SAS) following a change of posture (head-down position to head-up position). Their conclusions are based on magnetic resonance imaging (MRI) findings and a Poiseuille flow model, which is zero-dimensional in space.

Although we agree that on 3-T T2-weighted MRI imaging, the SAS looks empty—except for cerebrospinal fluid (CSF)—the anatomic reality shows a complex system of trabeculae and septae crossing the SAS between the arachnoid and the pia layer within the SAS that should not be neglected in a model² (Fig. 1). The “real” SAS is therefore not empty and

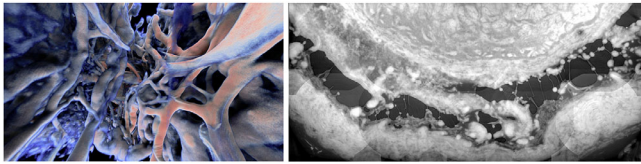


FIGURE 1. Micro-computed tomography images in a human demonstrated trabeculae and septae in the subarachnoid “empty” space.

cannot fully collapse. There is no doubt that a reduced influx of CSF will result in a reduced total volume of the SAS. We therefore strongly suspect that the images presented in the article lack the sufficient resolution to correctly resolve these features. Arguably, the best terminology for such a setting in which CSF falls below an MRI-detectable threshold would be a compartmentalized optic nerve sheath. In its wake, CSF dynamics and CSF content are dramatically altered, thus probably influencing the integrity of optic nerve function.

If we follow this line of thought a bit further, it becomes questionable whether a “collapsed” SAS can be applied to the concept of the transmural pressure difference (TLPD), as the definition of the TLPD is defined as the difference

between intraocular pressure and cerebrospinal fluid pressure. The difference between two fluids! In a collapsed SAS, there is no CSF. What area is involved in such a setting? Since pressure represents a force per unit area ($P = F/A$), we are wondering which area is involved in such a setting. What is the area of a collapsed SAS? We do not think that the formula for the TLPD can be applied meaningfully in such a situation.

In conclusion, we suspect that the flow modeling is oversimplistic since the optic nerve SAS is represented as a uniform flow in an empty space that does not represent the reality.

Hanspeter E. Killer¹
 Jatta Berberat²
 Peter Wostyn³
 Achmed Pircher⁴
 Diego Rossinelli⁵

¹Department of Biomedicine, University Hospital Basel & University Basel, Basel, Switzerland; ²Department of Neuro-radiology, Cantonal Hospital Aarau, Aarau, Switzerland; ³Department of Psychiatry, PC Sint-Amandus, Beernem, Belgium; ⁴Department of Neuroscience/Ophthalmology, Uppsala University, Uppsala, Sweden; and ⁵Institute of Physiology, University of Zurich, Zürich, Switzerland.
 E-mail: profesrielkiller@gmail.com.

References

- Holmlund P, Støverud KH, Wählin A, Wiklund U, Malm J, Jóhannesson G, Eklund A. Posture-dependent collapse of the optic nerve subarachnoid space: a combined MRI and modeling study. *Invest Ophthalmol Vis Sci.* 2021;62(4):26.
- Killer HE, Laeng HR, Flammer J, Groscurth P. Architecture of arachnoid trabeculae, pillars, and septa in the subarachnoid space of the human optic nerve: anatomy and clinical considerations. *Br J Ophthalmol.* 2003;87(6):777–781.

Citation: *Invest Ophthalmol Vis Sci.* 2021;62(15):16.
<https://doi.org/10.1167/iovs.62.15.16>