

# Giant hydatid cyst in the posterior fossa of a child

Fakhr Fakhouri, Abdelwahed Ghajar<sup>1</sup>, Nihad Mahli<sup>2</sup>, Nihad Shoumal<sup>3</sup>

Division of Neurosurgery, Department of Surgery, <sup>1</sup>Associated Professor of Neurosurgery and Chief of Division of Neurosurgery, Department of Surgery, <sup>2</sup>Professor of General Surgery and Chief of Department of Surgery, <sup>3</sup>Neurosurgery resident, Division of Neurosurgery, Department of Surgery, Aleppo University Hospital, Aleppo, Syria

## ABSTRACT

The hydatid cyst (HC) is endemic in Mediterranean region including Syria. The central nervous system is involved in 2–3% of cases. HC in cerebellum is very rare. We report a case that presented as an emergency for high intracranial pressure and deteriorating Glasgow coma scale. Close monitoring and precise surgical management using Dowling's technique resulted in very good outcome with full recovery. We highlight the need for very careful surgical treatment because cyst rupture and secondary hydatidosis due to spillage of the cyst contents can dramatically worsen the outcome. HC should be taken into consideration in countries where hydatid infestation is endemic.

**Key words:** Children, Dowling's technique, elevated intracranial pressure, hydatid cyst, posterior fossa

## Introduction

Hydatid infestation is endemic in many parts of the world including the Mediterranean region, Middle East, Southern Asia, Latin America, and Australia.<sup>[1-3]</sup> However, it is now also seen in western countries because of travel and migration.<sup>[4]</sup> An intracranial hydatid cyst (HC) is a relatively rare entity, accounting for only 1–2% of all intracranial space-occupying lesions.<sup>[1,2,5]</sup> Cerebral HCs are most frequently supratentorial while those located in the posterior fossa are very rare.<sup>[6,7]</sup> Here, we report a case of a child presented with acute hydrocephalus due to a large posterior fossa HC. Close monitoring and proper surgical technique resulted in very good outcome.

## Case Reports

A 5-year-old girl presented with a 3-month history of progressive headache, intermittent vomiting, and difficulty in walking. The headache was generalized and worsened in the morning. On admission, she was showed a deterioration in the level of consciousness (her Glasgow coma scale was 12) with bilateral admitted for high intracranial pressure with Glasgow coma

scale being 12. She had bilateral papilledema. Brain computed tomography (CT) revealed a right sided large cerebellar cystic mass surrounded by mild edema. CT also showed marked ventriculomegaly and periventricular edema [Figure 1]. The patient was admitted in the Intensive Care Unit and started on steroid. About 24 h later, she became fully alert and was examined thoroughly. She had a wide gait with a tendency to fall to the right side. Positive cerebellar signs (finger nose sign, heel knee sign) were confined to the right side. Routine blood analysis was within normal limits. Abdominal ultrasonography revealed two small cysts in right hepatic lobe measuring 9 and 10 mm in diameter [Figure 2]. Chest X-ray was normal [Figure 3]. Brain magnetic resonance imaging (MRI) showed a cystic lesion in the posterior fossa that was hypointense on T1-weighted sequences with minimally enhancing cyst wall [Figure 4]. On T2-weighted sequences, it was hyperintense [Figure 5]. MRI also confirmed pericystic edema better seen on flair sequences [Figure 6].

The day after, she underwent suboccipital craniectomy, and a relatively large cerebellar HC (approximately 6 cm in diameter) was removed using hydrodissection as described in Dowling's technique [Figure 7]. The diagnosis was confirmed by pathological examination of the cyst. The postoperative course was uneventful, and the patient was discharged 10 days later with complete neurological recovery. Albendazole was prescribed for 4 weeks.

## Discussion

Hydatid disease is caused by encysted larvae of the dog tapeworm *Echinococcus granulosus*. It is endemic in Middle East, Mediterranean countries, South America, North Africa, and Australia especially in a rural area. Man is infected either by eating contaminated food or by direct contact with an infected dog. Central nervous system involvement occurs in only about

### Access this article online

#### Quick Response Code:



#### Website:

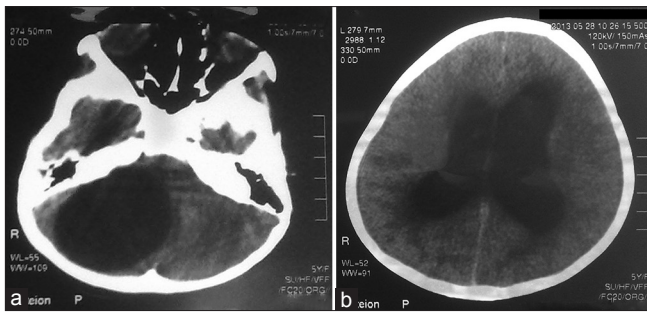
www.asianjns.org

#### DOI:

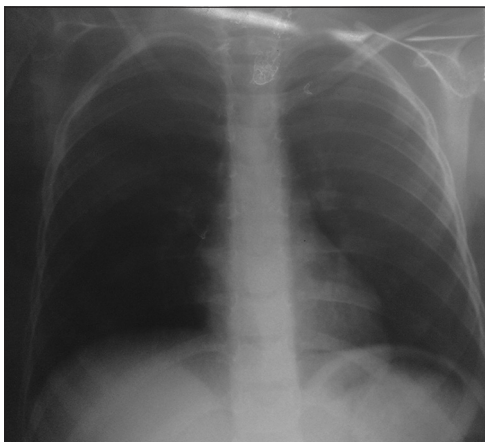
10.4103/1793-5482.162719

### Address for correspondence:

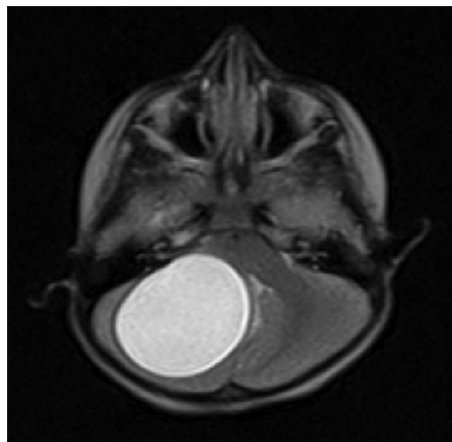
Dr. Fakhr Fakhouri, Department of Neurosurgical, Aleppo University Hospital, Aleppo, Syria.  
E-mail: fakhrf@msn.com



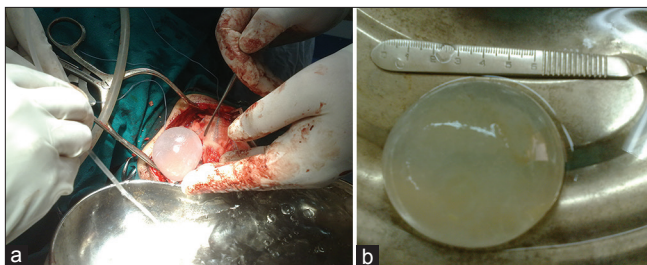
**Figure 1:** Computed tomography scan showing (a) posterior fossa cyst (left), (b) marked ventriculomegaly and periventricular extravasation (right)



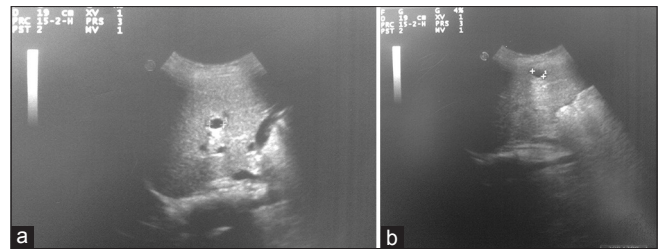
**Figure 3:** Chest X-ray was normal



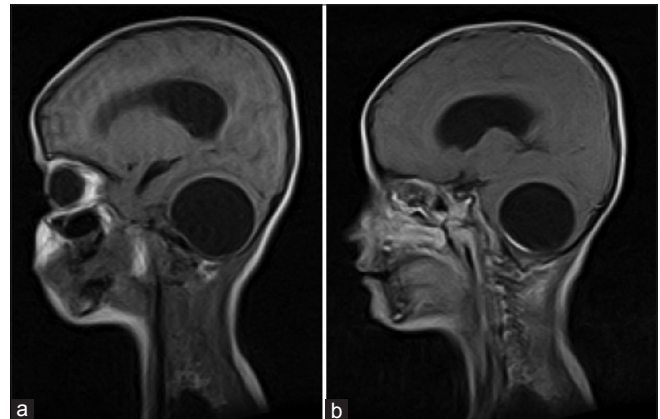
**Figure 5:** T2-weighted magnetic resonance imaging showing hyperintense cystic component



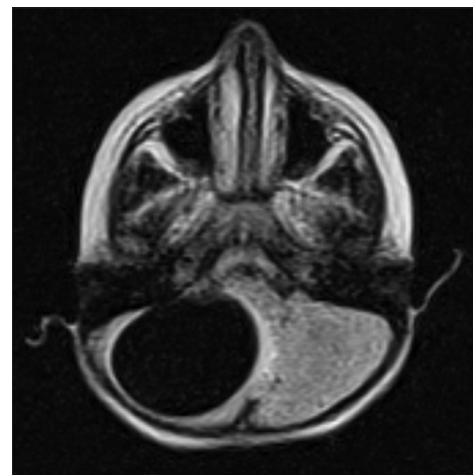
**Figure 7:** Intra-operative view showing the cyst (a) as it is delivered (left), and (b) when compared to ruler scalpel (right)



**Figure 2:** (a and b) Abdominal ultrasonography showing two small hepatic cysts



**Figure 4:** T1-weighted magnetic resonance imaging (a) before (left) and (b) after (right) contrast administration



**Figure 6:** Diffusion-weighted magnetic resonance imaging showing mild edema around the cyst

3% and produces cerebral cysts that are usually confined to the white matter.<sup>[8]</sup> Cerebral HC is more common in the pediatric population, probably related to a patent ductus arteriosus.<sup>[2,9]</sup> Intracranial HC is most commonly located in the supratentorial compartment,<sup>[10]</sup> and less commonly in the cavernous sinus,<sup>[11]</sup> eyeball,<sup>[12]</sup> pons,<sup>[13]</sup> and cerebellum.<sup>[14]</sup>

Cerebral HC's are slowly growing so it is frequently diagnosed several months or even years after the onset of symptoms, which are usually attributed to high intracranial pressure such as headaches and vomiting, or less commonly to

focal neurological deficit.<sup>[15]</sup> Rarely could HC present as an emergency as in our case. The growth rate of HC has been reported between 1 and 5 cm/year to 10 cm.<sup>[16]</sup> Solitary intracranial HC's are common than multiple intracranial cysts.<sup>[17]</sup>

Computed tomography and MRI reveal distinctive features of solitary HC. HC generally does not enhance, although rim enhancement may occur if there is an inflammatory reaction.<sup>[8]</sup> In our case, there was little enhancement. However, large rounded cystic lesion which is isodense and isointense, respectively, to cerebrospinal fluid with slight to no rim enhancement should raise the suspicion of HC. Brain edema is usually minimal. Magnetic resonance (MR) spectroscopy and MR diffusion-weighted imaging might help in the diagnosis of intracranial HC in difficult cases.<sup>[18,19]</sup>

A variety of surgical techniques is used for removal of the HC's.<sup>[20]</sup> The most important complication of the surgical treatment is secondary hydatidosis due to spillage of the cyst contents. The popular technique is Dowling's technique of hydrodissection in which normal saline irrigation is used with mild force between the cyst wall and brain interface in order to deliver the cyst intact.<sup>[21]</sup> This is often possible because the adhesions around the cyst wall are minimal. In our case, we performed this procedure successfully. Adjunctive medical therapy with albendazole may be used. In our patient, it was necessary because of concomitant hepatic cyst.<sup>[22]</sup>

## Conclusion

Even though HC in cerebellum is very rare, in an endemic area, it should be considered in the differential diagnosis of posterior fossa cysts. Dowling's technique is the safest surgical technique as cyst can be delivered intact with the best outcome.

## References

- Braham E, Bellil S, Bellil K, Chelly I, Mekni A, Haouet S, *et al.* Hydatid cyst of the posterior fossa. *Med Mal Infect* 2007;37:281-3.
- Ersahin Y, Mutluer S, Güzelbag E. Intracranial hydatid cysts in children. *Neurosurgery* 1993;33:219-24.
- Onal C, Unal F, Barlas O, Izgi N, Hepgul K, Turantan MI, *et al.* Long-term follow-up and results of thirty pediatric intracranial hydatid cysts: Half a century of experience in the Department of Neurosurgery of the School of Medicine at the University of Istanbul (1952-2001). *Pediatr Neurosurg* 2001;35:72-81.
- Kocaman S, Ersahin Y, Mutluer S. Cerebral hydatid cysts in children. *J Neurosci Nurs* 1999;31:270-7.
- Ravalji M, Kumar S, Shah AK, Vaghela DU, Makwana GJ, Singh K. CT and MRI features of the typical and atypical intracranial hydatid cysts: Report of five cases. *Indian J Radiol Imaging* 2006;16:727-32.
- Yasha TC, Shibu P, Srikanth SG, Shankar SK. 13-year-old boy with cerebellar cystic mass. *Neurol India* 2006;54:100-1.
- Polat P, Kantarci M, Alper F, Suma S, Koruyucu MB, Okur A. Hydatid disease from head to toe. *Radiographics* 2003;23:475-94.
- Mark S. Greenberg: *Handbook of Neurosurgery*. 6<sup>th</sup> ed. New York: Thieme; 2006. p. 238-9.
- Onal C, Barlas O, Orakdögen M, Hepgül K, Izgi N, Unal F. Three unusual cases of intracranial hydatid cyst in the pediatric age group. *Pediatr Neurosurg* 1997;26:208-13.
- Balasubramaniam V, Ramanujam PB, Ramamurthi B. Hydatid disease of the nervous system. *Neurol India* 1970;18 Suppl 1:92-5.
- Rivierez M, el-Azhari A, el Tantaoui M, Alaoui M. Hydatid cyst of the cavernous sinus. A case. *Neurochirurgie* 1992;38:46-9.
- Sinav S, Demirci A, Sinav B, Oge F, Sullu Y, Kandemir B. A primary intraocular hydatid cyst. *Acta Ophthalmol (Copenh)* 1991;69:802-4.
- Abbassioun K, Amirjamshidi A, Moinipoor MT. Hydatid cyst of the pons. *Surg Neurol* 1986;26:297-300.
- Jiménez-Mejías ME, Castillo-Ojeda E, Cuello Contreras JA, García Gutiérrez D, Romero Arce J, Pachón Diaz J. Cerebral hydatidosis. Analysis of a series of 23 cases. *Med Clin (Barc)* 1991;97:125-32.
- Braham M, Hlel K, Ayadi A, Bedoui A, Hmila F, Mahjoub B, *et al.* Cerebral hydatid cysts in children: 4 cases. *Med Mal Infect* 2006;36:434-7.
- Sierra J, Oviedo J, Berthier M, Leiguarda R. Growth rate of secondary hydatid cysts of the brain. Case report. *J Neurosurg* 1985;62:781-2.
- Lunardi P, Missori P, Di Lorenzo N, Fortuna A. Cerebral hydatidosis in childhood: A retrospective survey with emphasis on long-term follow-up. *Neurosurgery* 1991;29:515-7.
- Ciurea AV, Fountas KN, Coman TC, Machinis TG, Kapsalaki EZ, Fezoulidis NI, *et al.* Long-term surgical outcome in patients with intracranial hydatid cyst. *Acta Neurochir (Wien)* 2006;148:421-6.
- Coates R, von Sinner W, Rahm B. MR imaging of an intracerebral hydatid cyst. *AJNR Am J Neuroradiol* 1990;11:1249-50.
- Arana Iniquez R. *Echinococcus*. Infection of the nervous system. In: Vinken PJ, Bruyn GW, editors. *Hand Book of Clinical Neurology*. Part 3. Amsterdam: Elsevier/North Holland Biomedical Press; 1978. p. 175-208.
- Carrea R, Dowling E Jr, Guevara JA. Surgical treatment of hydatid cysts of the central nervous system in the pediatric age (Dowling's technique). *Childs Brain* 1975;1:4-21.
- Drugs for parasitic infections. *Med Lett Drugs Ther* 1995;37:99-108.

**How to cite this article:** Fakhouri F, Ghajar A, Mahli N, Shoumal N. Giant hydatid cyst in the posterior fossa of a child. *Asian J Neurosurg* 2015;10:322-4.

**Source of Support:** Nil, **Conflict of Interest:** None declared.