

# Central Hypothyroidism and Novel Clinical Phenotypes in Hemizygous Truncation of *TBL1X*

Marta García,<sup>1</sup> Ana C. Barreda-Bonis,<sup>2</sup> Paula Jiménez,<sup>1</sup> Ignacio Rabanal,<sup>3</sup> Arancha Ortiz,<sup>4</sup> Elena Vallespín,<sup>5</sup> Ángela del Pozo,<sup>6</sup> Juan Martínez-San Millán,<sup>7</sup> Isabel González-Casado,<sup>2</sup> and José C. Moreno<sup>1</sup>

<sup>1</sup>Thyroid Molecular Laboratory, Institute for Medical and Molecular Genetics (INGEMM), La Paz University Hospital, Autonomous University of Madrid, 28046 Madrid, Spain; <sup>2</sup>Pediatric Endocrinology, La Paz University Hospital, 28046 Madrid, Spain; <sup>3</sup>Pediatric Otorhinolaryngology, La Paz University Hospital, 28046 Madrid, Spain; <sup>4</sup>Child and Adolescent Psychiatry, La Paz University Hospital, 28046 Madrid, Spain; <sup>5</sup>Functional and Structural Genomics, Institute for Medical and Molecular Genetics (INGEMM), La Paz University Hospital, 28046 Madrid, Spain; <sup>6</sup>Bioinformatics Unit, Institute for Medical and Molecular Genetics (INGEMM), La Paz University Hospital, 28046 Madrid, Spain; and <sup>7</sup>Department of Radiology, Ramón y Cajal Hospital, 28039 Madrid, Spain

ORCID numbers: 0000-0003-0427-2751 (M. García); 0000-0001-5664-5308 (J. C. Moreno).

Transducin  $\beta$ -like 1 X-linked (*TBL1X*) gene encodes a subunit of the nuclear corepressor-silencing mediator for retinoid and thyroid hormone receptor complex (NCoR-SMRT) involved in repression of thyroid hormone action in the pituitary and hypothalamus. *TBL1X* defects were recently associated with central hypothyroidism and hearing loss. The current study aims to describe the clinical and genetic characterization of a male diagnosed with central hypothyroidism through thyroid hormone profiling, TRH test, brain MRI, audiometry, and psychological evaluation. Next-generation sequencing of known genes involved in thyroid disorders was implemented. The 6-year-old boy was diagnosed with central hypothyroidism [free T4: 10.42 pmol/L (normal: 12 to 22 pmol/L); TSH: 1.57 mIU/L (normal: 0.7 to 5.7 mIU/L)], with a mildly reduced TSH response to TRH. He was further diagnosed with attention-deficit/hyperactivity disorder (ADHD) at 7 years, alternating episodes of encopresis and constipation, and frequent headaches. MRI showed a normal pituitary but detected a Chiari malformation type I (CMI). At 10 years, audiometry identified poor hearing threshold at high frequencies. Sequencing revealed a nonsense hemizygous mutation in *TBL1X* [c.1015C>T; p.(Arg339Ter)] largely truncating its WD-40 repeat domain involved in nuclear protein-protein interactions. In conclusion, to our knowledge, we identified the first severely truncating *TBL1X* mutation in a patient with central hypothyroidism, hypoacusia, and novel clinical features like ADHD, gastrointestinal dysmotility, and CMI. Given the relevance of *TBL1X* and NCoR-SMRT for the regulation of transcriptional programs at different tissues (pituitary, cochlea, brain, fossa posterior, and cerebellum), severe mutations in *TBL1X* may lead to a distinct syndrome with a phenotypic spectrum wider than previously reported.

Copyright © 2019 Endocrine Society

This article has been published under the terms of the Creative Commons Attribution Non-Commercial, No-Derivatives License (CC BY-NC-ND; <https://creativecommons.org/licenses/by-nc-nd/4.0/>).

**Freeform/Key Words:** central hypothyroidism, attention deficit hyperactivity disorder, Chiari malformation type I, 22 hearing loss, *TBL1X* gene

Central congenital hypothyroidism (CCH) is an underdiagnosed disorder characterized by deficient production of thyroid hormones due to reduced TSH synthesis, secretion, or bioactivity, which fails to properly stimulate an otherwise normal thyroid gland [1, 2]. To date,

Abbreviations: ADHD, attention-deficit/hyperactivity disorder; ASD, autism spectrum disorder; CCH, central congenital hypothyroidism; CMI, Chiari malformation type I; ENS, enteric neuron system; FT4, free T4; GI, gastrointestinal; NCoR-SMRT, nuclear corepressor-silencing mediator for retinoid and thyroid hormone receptor complex; TR, thyroid hormone receptor; TRB, thyroid hormone receptor B isoform.

defects in only four genes have been identified in patients with CCH: *TSHB* (encoding the B-subunit of the TSH glycoprotein hormone), *TRHR* (the specific 7-transmembrane domain receptor for hypothalamic TRH), *IGSF1* (a protein regulating the expression of TRHR in pituitary thyrotropes), and the recently identified *TBLIX* (transducin  $\beta$ -like 1 X-linked), a subunit of the nuclear corepressor-silencing mediator for retinoid and thyroid hormone receptor complex (NCoR-SMRT) complex modulating thyroid hormone action in thyrotropes [3].

*TBLIX* is located at the Xp22.3-p22.2 chromosome and encodes a protein highly expressed in pituitary and present in the hypothalamus, representing an essential subunit of the NCoR-SMRT involved in T3-regulated gene expression [3–5].

A recent publication reported the identification of missense and splice-site point mutations in *TBLIX* in six unrelated families, variably presenting congenital T4 deficiency or normal T4 levels at birth [3]. Defects in this gene have also been associated with hearing loss [3, 6]. *TBLX1* was linked to autism in genomewide association studies; however, neurodevelopmental defects have not been yet reported in patients with *TBLIX* defects [3]. The pathogenic mechanism(s) underlying this X-linked disorder remains unknown.

Here, we present, to our knowledge, the first *nonsense* and *de novo* mutation in the *TBLIX* gene in a patient with CCH, hearing loss, attention-deficit and hyperactivity disorder (ADHD), encephalitis, and CMI.

## 1. Materials and Methods

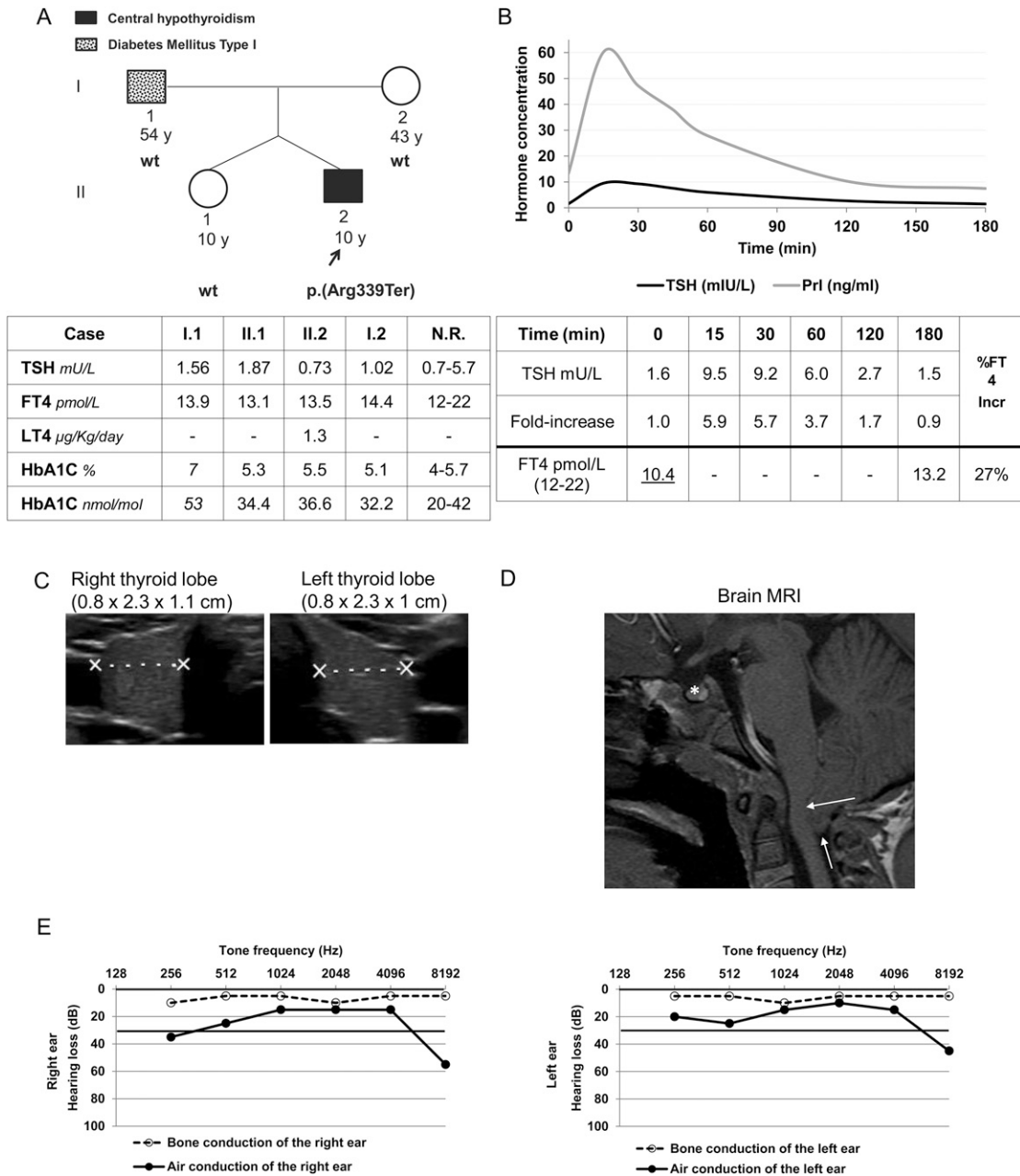
The coding regions of the candidate genes for CCH (*TSHB*, *TRHR*, and *IGSF1*) were amplified by PCR using appropriate primers flanking each exon. PCR products were purified and directly sequenced on an automated DNA sequencer (3100 Genetic Analyzer; Applied Biosystems, Foster City, CA). A targeted panel of next-generation sequencing, including the coding region and flanking intronic boundaries of 252 genes involved in (human and experimental) thyroid disorders, was investigated using the NextSeq 500 platform (Illumina, San Diego, CA) as reported [7]. Genes included known or plausible candidates for hypothalamic/pituitary (*TSHB*, *TRHR*, *TRH*, *IGSF1*, *TBLIX*, *NCOR1*, *RXRG*, *RXRA*, *THRB*, *THRA*, *TBLXR1*, *GPS2*, *HDAC3*, *NCOA1*, *NCOA2*, *NCOA3*, *NCOA4*, *GATA2*, *NR4A1*, *PITX2*, *PITX1*, *PCSK1*, *CGA*, *LHX3*, *BMP4*, *SOX2*, *CREB1*, *MED1*, *MED12*, *DIO2*, *SLC16A2*) or primary nonautoimmune hypothyroidism (*TPO*, *TG*, *TSHR*, *DUOX2*, *DUOX1*, *DUOXA1*, *DUOXA2*, *NKX2-1*, *PAX8*, *SLC26A4*, *NKX2-5*, *RUNX2*, *TBX5*, *SLC5A5*, *FOXE1*). The complete list of genes is available upon request. Genetic variants were filtered on population frequency and pathogenic prediction criteria using five publicly available databases (dbSNP, 1000 Genomes Project, The Exome Aggregation Consortium, Human Gene Mutation Database, and ClinVar). The presence of the mutation identified in the index case was investigated in the patient's parents and sister by Sanger sequencing.

The patient was clinically (hormonally, imaging) and genetically characterized. Serum TSH, free T4 (FT4), total T3, prolactin, and cortisol were determined with chemiluminescent immunoanalysis in the Centaur XP (Siemens, Healthineers, Erlangen, Germany). IGF1, IGFBP3, and ACTH were measured with chemiluminescent immunoanalysis in the Immulite 2000 (Siemens, Healthineers, Erlangen, Germany). TRH stimulation test was performed as previously reported [8]. Thyroid volume was calculated from three-dimensional measurements of each lobule on ultrasounds according to the formula, volume (mL) =  $0.479 \times \text{depth} \times \text{width} \times \text{length}$  (cm), and compared with standards of the local population [9]. Informed consent for genetic studies was obtained from parents of the patient, according to protocols from the ethical committee of our institution.

## 2. Results

### A. Clinical Case

The patient is a 10-year-old male of Spanish descent, born to nonconsanguineous parents in a twin pregnancy derived from *in vitro* fertilization of own parental sperm and oocytes (Fig. 1A).



**Figure 1.** Clinical and biochemical features of the patient with a *TBLIX* defect. (A) Pedigree of members of the family showing patient born of twin pregnancy from nonconsanguineous parents. Thyroid hormone profile and glycosylated hemoglobin were used to evaluate hypothyroidism and diabetes, respectively, in all members of the family. Italics represent values above normal ranges. (B) Thyrotropin response of the index patient (6 y of age without levothyroxine treatment) at the TRH test during 180 min. TSH and prolactin (Prl) values are represented in the graph through time during the 3 h of the test. Fold increase of TSH was calculated by dividing the TSH value at each time (0, 15, 30, 60, 120, or 180 min) by the TSH level at the beginning of the test (0 min). FT4 increase 3 h after TRH administration was calculated as reported [8], as an indirect measure of TSH bioactivity, and was normal. Underlining represents values below normal ranges. (C) Thyroid ultrasound at 6 y and 9 mo of age, representing three-dimensional measures of each lobule, showed mild hypoplasia of the gland. (D) Brain MRI in the index case at 6.5 y of age showing normal pituitary morphology and size (white asterisk) but a downward herniation of cerebellar tonsils protruding through the foramen magnum (CMI), which compresses the spinal cord (white arrows). (E) Hearing loss per frequency in the right and left ear of the index patient is represented in left and right panels, respectively. %FT<sub>4</sub> Incr, percentage of FT<sub>4</sub> increase; N.R., normal range; wt, wild-type.

His father has type 1 diabetes mellitus and a familial history of type 2 diabetes mellitus but no antecedents of hypothyroidism. His mother and twin sister showed an unremarkable phenotype (Fig. 1A).

The patient was not detected by the TSH-based Neonatal Screening Program for Congenital Hypothyroidism and had normal growth, weight gain, and neurologic development in infancy. At 5 years of age, he showed refractory episodes of constipation with encopresis requiring osmotic laxatives. At 6 years, he was referred to Pediatric Endocrinology for evaluation of abnormal thyroid function tests, including low FT4 (10.16 pmol/L; normal, 12 to 22 pmol/L) but normal TSH (1.06 mIU/L; normal, 0.7 to 5.7 mIU/L), consistent with central hypothyroidism (Table 1). TT3 was normal (1.46 ng/mL; normal, 0.8 to 2 ng/mL) (Table 1). Antithyroglobulin antibodies (<15 IU/mL; normal, <60 IU/mL) and antithyroid peroxidase antibodies (<28 IU/mL; normal, <60 IU/mL) were negative, ruling out autoimmune thyroid disease. A 180-minute TRH test was performed to investigate the origin of his hypothyroidism, showing reduced TSH stimulation (low TSH secretion capacity) and full recovery of the basal TSH level at the end of the test (Fig. 1B), suggesting a pituitary defect. His TSH-FT4 relation was studied in the model of Dietrich *et al.* [10]. Although initial values fell inside the green area representing the normal dynamic relationship between the two parameters, later determinations showed ratios falling outside such area, suggesting an evolving thyrotropic failure (data not shown). He did not have clear symptoms of hypothyroidism but performed poorly at school, requiring the help of extra teaching. Levothyroxine replacement was started at a low dose of 1.1 µg/kg/d, which normalized his FT4 levels (15.70 pmol/L) while notably reducing TSH (0.37 mIU/L) (Table 1), both characteristics of central hypothyroidism. Neck ultrasounds showed mild hypoplasia of the thyroid gland with 1.84 mL volume (p50: 3.05 mL) [9] (Fig. 1C). No defect in other pituitary axes was identified, with basal cortisol, ACTH, IGF1, IGFBP3, FSH, LH, and testosterone within normal ranges (Table 1). Brain MRI showed normal pituitary size and shape, but a CMI was identified, consisting of the aberrant displacement of the cerebellar tonsils into the foramen magnum (Fig. 1D). At 7 years of age, the patient was formally diagnosed with ADHD. Pharmacological treatment of ADHD was indicated, but he did not receive therapy due to parental decision. At 10 years of age, a pure-tone audiometry was performed, which identified poor hearing thresholds in the air conduction at high frequencies compared with the age-specific reference interval [11] (Fig. 1E). The patient showed adequate growth during his infancy and childhood, with weight and height around p50 (Spanish growth curves, 2010) (data not shown). In the last clinical visit at 10 years of

**Table 1. Long-Term Follow-up of Thyroid and Other Pituitary Axes Profiles of the Patient With *TBL1X* Defect**

Characteristic	Age, y									
	5.5	6.25	6.3 <sup>a</sup>	6.75	7	7.75	8.3	8.8	9.3	10
TSH, mIU/L (0.7–5.7)	1.69	1.06	1.57	<i>0.37</i>	<i>0.53</i>	<i>0.66</i>	1.17	<i>0.66</i>	1.05	0.73
FT4, pmol/L (12–22)	<i>11.58</i>	<i>10.16</i>	<i>10.42</i>	15.70	14.70	14.54	12.48	12.09	<i>11.60</i>	13.5
TT3, ng/mL (0.8–2)	—	—	1.46	1.16	—	—	—	—	—	1.08
L-T4 dose, µg/kg/d	—	—	—	1.1	1.25	1.18	1.18	1.3	1.35	1.9
ACTH, pg/mL (5–46)	—	—	13	—	—	—	—	—	28	—
Cortisol, µg/dL (5–25)	—	—	9.9	—	—	—	—	—	21.3	—
IGF1, ng/mL	—	—	179	—	—	—	—	—	210	—
IGFBP3, µg/mL	—	—	4.00	—	—	—	—	—	4.06	—
FSH, mIU/mL (1.5–12.4)	—	—	<i>1.45</i>	—	—	—	—	—	<i>3.73</i>	—
LH, mIU/mL (1.7–8.6)	—	—	<i>&lt;0.1</i>	—	—	—	—	—	<i>0.11</i>	—
Testosterone, ng/mL (1.8–15.9)	—	—	<i>0.02</i>	—	—	—	—	—	<i>&lt;0.1</i>	—

Hormone parameters are represented in chronological order along the patient's life. Italics represent hormone values below normal ranges. Values in parentheses represent reference ranges.

Abbreviations: L-T4, levothyroxine; TT3, total T3; —, not determined.

<sup>a</sup>Age at clinical diagnosis of the patient, when the TRH test was performed.

age, his height [141.4 cm (p57), +0.19 SD], weight [35.2 kg (p45), -0.15 SD], and body mass index 17.61 (p40), -0.27 SD) were normal, as was his gonadal development, with bilateral testicular volumes of 3 mL in agreement with pubertal Tanner I stage [12].

### B. Identification of the TBL1X Mutation

Molecular analysis for mutations by Sanger sequencing of three candidate genes associated with central hypothyroidism (*TRHR*, *TSHB*, and *IGSF1*) did not reveal any defects in the patient. Targeted next-generation sequencing of a panel of genes including candidates for central and primary hypothyroidism identified a rare nonsense hemizygous mutation in exon 11 of the *TBL1X* gene (c.1015C>T), changing arginine 339 into a stop codon [p.(Arg339Ter)] (transcript accession number NM\_005647.3). The mutation was confirmed by Sanger sequencing and investigated in the family. The p.(Arg339Ter) was a *de novo* mutation because it was not identified in parents or the (dizygotic twin) sister of the patient (Fig. 1A and Fig. 2A), whose paternity was confirmed by a panel of 20 single tandem repeat microsatellite markers studied in the four members of the family (data not shown). This variant was not reported in databases for genomic variants.

TBL1X protein structure contains an N-terminal (LisH), a putative F box domain for protein dimerization, and a C-terminal WD40 domain with eight WD repeats for interaction with other nuclear proteins [4] (Fig. 2B). The p.(Arg339Ter) is predicted to have deleterious effects on the function of TBL1X given its N-terminal location from the highly conserved WD40 repeat domain, which would become largely truncated. The mRNA containing c.1015C>T was not translated and characterized *in vitro*. Most mutant mRNAs containing nonsense mutations are unstable and degraded through nonsense-mediated decay. Nevertheless, if such mRNA were stable, it would encode a protein lacking six of the eight WD repeat domains by which TBL1X interacts with other nuclear factors toward the activation/repression of target gene transcription (Fig. 2B).

## 3. Discussion

TBL1X is an essential subunit of the NCoR-SMRT corepressor complexes that regulate transcription of many different genes [19]. TBL1X binds to its receptor protein TBL1XR1 (another component of NCoR-SMRT) and also interacts with other partners within corepressor complexes (Fig. 2C–2F). The function of such complexes is exerted through remodeling of nuclear chromatin by histone-deacetylase 3 and interaction with classical DNA-binding nuclear receptors at the promoter of target genes. Importantly, NCoR-SMRT regulates T3-dependent gene expression through the thyroid hormone receptors (TRs) and retinoid-dependent expression through retinoic acid receptors (RAR, RXR) [4]. Furthermore, TBL1X regulates  $\beta$  catenin–mediated Wnt-responsive genes, controlling cell proliferation and cell fate [20, 21], and is also involved in synaptogenesis and synaptic activity and homeostasis [15] (Fig. 2E–2F).

Given the involvement of TBL1X in multiple intracellular signaling pathways [15, 19–21], it may seem surprising that those mutations so far known in this protein lead to limited phenotypes of deafness and central hypothyroidism.

Many patients with CCH are detected at peripubertal ages in countries with TSH-based neonatal screening programs [1]. First patients reported with *TBL1X* mutations were detected through a T4-based neonatal screening with variable degrees of hypothyroxinemia [3].

Our patient was diagnosed with CCH at the age of 6 years by an abnormal thyroid hormone profile in the course of an etiological study of encopresis and constipation while not presenting typical symptoms of hypothyroidism. The TRH test showed poor TSH surge but normal secretion dynamics [8]. His TSH curve is in contrast with those found in previous patients with *TBLX1* mutations (reported normal) probably because point mutations in the Dutch study plausibly led to milder effects on the protein function [3]. Our patient presented with mild thyroid hypoplasia, similar to patients previously described with *TBL1X* and *IGSF1*





(nTREs). In the absence of T3, unoccupied TRs allow basal transcription and secretion of TSH through interaction with the NCoR-SMRT complex, including TBL1X, whose defect may explain central hypothyroidism. (D) TR-T3 regulates the expression of genes involved in ear development, like pendrin (*SLC26A4*), prestin (*SLC26A5*), or potassium voltage-gated channel subfamily Q member 4 (*KCNQ4*) [13, 14]. Therefore, it is likely that auditory defects in *TBLX1* deficiency could be mediated by dysregulation of TR-T3-dependent transcription. (E) NCoR-SMRT corepressor complexes regulate transcription of genes involved in synaptic homeostasis, like brain-derived neurotrophic factor (*BDNF*), cyclin D1 (*CCND1*), and achaete-scute homolog 2 (*ASCL2*) of brain neurons, associated with neurodevelopmental disorders like ADHD and ASDs [15]. NCoR-SMRT also regulates the expression of genes of the ENS. Notably, another component of the complex, highly expressed in ENS, is the methyl-CpG binding protein 2 (MECP2). This protein is involved in Rett syndrome (a distinct neurodevelopmental disorder), which prominently shows severe GI dysmotility [16]. (F) Finally, NCoR-SMRT regulates TR-dependent transcription in cerebellar growth and differentiation [17], and notably, TBL1XR1 plays a role in the expression of Wnt signaling proteins like dickkopf Wnt signaling pathway inhibitor 1 (*DKK1*) and LDL receptor-related protein 4 (*LRP4*) implicated in posterior fossa development of the skull, with TBL1XR1 defects being associated with CMI [18].

defects [3, 22]. This reduction in thyroid volume is attributable to weak trophic stimulation of the gland by low TSH levels [22].

*TSHB* promoter is negatively regulated by T3 through interaction with the nuclear thyroid hormone receptor B isoform (TRB). However, in the absence of the T3 ligand, unoccupied TR allows the basal transcription and secretion of TSH through interaction with the NCoR-SMRT complex, including TBL1X (Fig. 2C) [3]. Therefore, it is not surprising that patients with *TBL1X* mutations show central hypothyroidism due to inadequate basal TSH secretion and stimulation of the thyroid gland (Fig. 2C). TBL1X is also expressed in the parvocellular neurons of the paraventricular nucleus of the hypothalamus, suggesting coexpression with TRH [3]. Therefore, it could be speculated that the mechanism of TBL1X-dependent hypothyroidism may involve not only defective (pituitary) TSH synthesis but also abnormal (hypothalamic) TRH signaling.

Sensorineural hearing loss was specifically searched for during the course of this study, after identification of the *TBL1X* mutation in the patient. Hypoacusia was bilateral and mild, being restricted to high tones and so far not involving clinically relevant disability. Follow-up of the patient's audition capacity is warranted because deafness related to *TBL1X* deletions seems to progress with age [6]. It is interesting to note that mutations in the *TBL1X* receptor (*TBL1XR1*) cause Pierpont syndrome, a constellation of features also including deafness [23].

Thyroid hormone is essential in development and differentiation of the inner ear, participating in its maturation from early fetal stages [13, 14, 24]. In this organ, thyroid hormone action is mediated by TRB, where T3 binding induces the exchange of transcriptional corepressors and coactivators, encompassing *TBL1X* (Fig. 2D). Thyroid hormone receptor  $\beta$  (*Thrb*)-deficient mice are deaf and have multiple morphological defects in the cochlea, a phenotype similar to that observed in humans with genetic defects in *TBL1X* [25–27]. Interestingly, defects in T3-TRB target genes like *SLC26A4* (pendrin), *SLC26A5* (prestin), or *KCNQ4* also present phenotypes of sensorineural deafness [28–30]. Therefore, it is likely that auditory defects related to *TBL1X* (and *TBL1XR1*) deficiency could be mediated by abnormal interactions within the NCoR-SMRT complex and dysregulation of TRB-dependent expression in the inner ear [3, 6] (Fig. 2D).

ADHD and learning difficulties at school were revealed at 6 years of age in the course of an extended clinical study. Following the 5th edition of the Diagnostic and Statistical Manual of Mental Disorders (DSM-5), these neurodevelopmental features fall in the scope of autism spectrum disorders (ASDs) [31].

ASDs have been consistently linked to defects in synaptogenesis and synapsis homeostasis [15]. The NCoR-SMRT corepressor complexes are known to regulate transcription of genes related to ASDs, like *BDNF* (brain-derived neurotrophic factor), or Wnt target genes like *CCND1* (cyclin D1) or *ASCL2* (achaete-scute family bHLH transcription factor 2) [15], all important for synaptic homeostasis (Fig. 2E). Interestingly, polymorphisms in *TBL1X* have

been associated with ASDs in a Genome Wide Association Study (GWAS) study [32]; however, no neurodevelopmental defects have been reported so far in patients with *TBLX1* defects [3]. It is tempting to speculate that such patients, harboring missense (point) mutations in the gene, may retain residual protein function, leading to absent or milder neurodevelopmental phenotypes. In our case, cognition and behavior of parents are normal, in full consistency with the *de novo* nature of the mutation in the patient. Furthermore, maternal hypothyroidism during pregnancy cannot be claimed here as a factor influencing this phenotype because, again, the mutation is not inherited and the patient's twin sister has normal behavior and learning capacity.

Encopresis or fecal incontinence is a disabling disorder derived from alterations of motility in the gastrointestinal (GI) tract, especially the colonic part, which may alternate with constipation episodes. The pathogenesis is not well understood, but genetic factors are proposed [33]. Strikingly, encopresis is very prevalent in patients with neurodevelopmental disorders like ADHD or autism [34, 35], and inversely, a notable proportion of children with functional defecation disorders presents with ADHD [36]. This may suggest etiological connections between these entities because motility of the GI tract is performed by the smooth muscle cells governed by the enteric neuron system (ENS). The NCoR-SMRT complex system is equally important for synaptic development and plasticity of ENS neurons, as it is for brain neurons. *MECP2*, another integral component of the NCoR-SMRT, is highly expressed in ENS, where it regulates intestinal motility [16]. Mutations in *MECP2* cause Rett syndrome, a neurodevelopmental disorder characterized by severe cognitive impairment, motor dyspraxia, and seizures but also GI dysmotility. Therefore, it is tempting to speculate that encopretic/constipation symptoms in our patient relate to dysregulation of ENS gene transcription involved in normal intestinal motility (Fig. 2E).

CMI is a rare congenital abnormality of the craniocerebral junction, leading to a variety of neurologic symptoms [37]. Our patient complained of exertional headaches, especially after the practice of sports.

CMI is suspected to have a genetic basis because familial clustering has been reported [38, 39]. Thyroid hormone signaling through at least three different TRs ( $TR\beta$ ,  $TR\alpha$ 1,  $TR\alpha$ 2) is crucial in cerebellar growth and differentiation [17]. Recently, Wnt- $\beta$  catenin signaling has been implicated in the development of CMI [38]. Notably, the catenin-based regulation of transcription is governed by *TLB1X-TBL1XR1*, which are negative regulators of  $\beta$  catenin [20, 21]. Because CMI has been reported in relation to a *TBL1XR1* mutation [18], it is tempting to speculate that the *TBL1X* defect in our patient could also cause CMI by dysregulated transcription of Wnt- $\beta$  catenin target genes involved in the development of the cerebellum or patterning of the cranial mesenchyme forming the posterior fossa of the skull [39] (Fig. 2F).

In summary, we have described, to our knowledge, the first severely truncated *TBL1X* mutant identified in a male with central hypothyroidism and hypoacusia and expanded the phenotypic spectrum of the syndrome to neurodevelopmental disorders, GI dysmotility, and CMI as novel features.

## Acknowledgments

We thank the patient and his family for their close collaboration and Mrs. Mercedes Tanarro for her expert technical assistance.

**Financial Support:** This work was supported in part by the grants ENDOSCREEN S2010/BMD-2396 (to J.C.M.) from research funding of the Madrid Autonomous Region and the European Regional Development Fund.

**Correspondence:** José C. Moreno, MD, PhD, Thyroid Molecular Laboratory, Institute for Medical and Molecular Genetics (INGEMM), La Paz University Hospital, Paseo de la Castellana, 261, 28046 Madrid, Spain. E-mail: [josecarlos.moreno@salud.madrid.org](mailto:josecarlos.moreno@salud.madrid.org).

**Disclosure Summary:** The authors have nothing to disclose.

---

## References and Notes

1. Persani L. Clinical review: central hypothyroidism: pathogenic, diagnostic, and therapeutic challenges. *J Clin Endocrinol Metab.* 2012;**97**(9):3068–3078.



2. García M, Fernández A, Moreno JC. Central hypothyroidism in children. *Endocr Dev*. 2014;**26**:79–107.
3. Heinen CA, Losekoot M, Sun Y, Watson PJ, Fairall L, Joustra SD, Zwaveling-Soonawala N, Oostdijk W, van den Akker EL, Alders M, Santen GW, van Rijn RR, Dreschler WA, Surovtseva OV, Biermasz NR, Hennekam RC, Wit JM, Schwabe JW, Boelen A, Fliers E, van Trotsenburg AS. Mutations in TBL1X are associated with central hypothyroidism. *J Clin Endocrinol Metab*. 2016;**101**(12):4564–4573.
4. Yoon HG, Chan DW, Huang ZQ, Li J, Fondell JD, Qin J, Wong J. Purification and functional characterization of the human N-CoR complex: the roles of HDAC3, TBL1 and TBLR1. *EMBO J*. 2003;**22**(6):1336–1346.
5. Astapova I, Vella KR, Ramadoss P, Holtz KA, Rodwin BA, Liao XH, Weiss RE, Rosenberg MA, Rosenzweig A, Hollenberg AN. The nuclear receptor corepressor (NCoR) controls thyroid hormone sensitivity and the set point of the hypothalamic-pituitary-thyroid axis. *Mol Endocrinol*. 2011;**25**(2):212–224.
6. Bassi MT, Ramesar RS, Caciotti B, Winship IM, De Grandi A, Riboni M, Townes PL, Beighton P, Ballabio A, Borsani G. X-linked late-onset sensorineural deafness caused by a deletion involving OA1 and a novel gene containing WD-40 repeats. *Am J Hum Genet*. 1999;**64**(6):1604–1616.
7. García M, González de Buitrago J, Jiménez-Rosés M, Pardo L, Hinkle PM, Moreno JC. Central hypothyroidism due to a TRHR mutation causing impaired ligand affinity and transactivation of Gq. *J Clin Endocrinol Metab*. 2017;**102**(7):2433–2442.
8. van Tijn DA, de Vijlder JJ, Vulsma T. Role of the thyrotropin-releasing hormone stimulation test in diagnosis of congenital central hypothyroidism in infants. *J Clin Endocrinol Metab*. 2008;**93**(2):410–419.
9. García-Ascaso MT. Iodine Nutritional Status in Children Between 3 and 14 Years of Age: Individual, familial, dietetical, analytical and echographical variables [dissertation] [in Spanish]. Madrid, Spain: Autonomous University of Madrid; 2013.
10. Dietrich JW, Landgrafe G, Fotiadou EH. TSH and thyrotropic agonists: key actors in thyroid homeostasis. *J Thyroid Res*. 2012;**2012**:351864.
11. Rodríguez Valiente A, Roldán Fidalgo A, García Berrocal JR, Ramírez Camacho R. Hearing threshold levels for an otologically screened population in Spain. *Int J Audiol*. 2015;**54**(8):499–506.
12. Joustra SD, van der Plas EM, Goede J, Oostdijk W, Delemarre-van de Waal HA, Hack WW, van Buuren S, Wit JM. New reference charts for testicular volume in Dutch children and adolescents allow the calculation of standard deviation scores. *Acta Paediatr*. 2015;**104**(6):e271–e278.
13. Winter H, Braig C, Zimmermann U, Geisler HS, Fränzer JT, Weber T, Ley M, Engel J, Knirsch M, Bauer K, Christ S, Walsh EJ, McGee J, Köpschall I, Rohbock K, Knipper M. Thyroid hormone receptors TRalpha1 and TRbeta differentially regulate gene expression of Kcnq4 and prestin during final differentiation of outer hair cells. *J Cell Sci*. 2006;**119**(Pt 14):2975–2984.
14. Cordas EA, Ng L, Hernandez A, Kaneshige M, Cheng SY, Forrest D. Thyroid hormone receptors control developmental maturation of the middle ear and the size of the ossicular bones. *Endocrinology*. 2012;**153**(3):1548–1560.
15. Bourgeron T. From the genetic architecture to synaptic plasticity in autism spectrum disorder. *Nat Rev Neurosci*. 2015;**16**(9):551–563.
16. Wahba G, Schock SC, Cudd S, Grynspan D, Humphreys P, Staines WA. Activity and MeCP2-dependent regulation of nNOS levels in enteric neurons. *Neurogastroenterol Motil*. 2016;**28**(11):1723–1730.
17. Koibuchi N. The role of thyroid hormone on cerebellar development. *Cerebellum*. 2008;**7**(4):530–533.
18. Slavotinek A, Pua H, Hodoglugil U, Abadie J, Shieh J, Van Ziffle J, Kvale M, Lee H, Kwok PY, Risch N, Sabbadini M. Pierpont syndrome associated with the p.Tyr446Cys missense mutation in TBL1XR1. *Eur J Med Genet*. 2017;**60**(10):504–508.
19. Perissi V, Jepsen K, Glass CK, Rosenfeld MG. Deconstructing repression: evolving models of corepressor action. *Nat Rev Genet*. 2010;**11**(2):109–123.
20. MacDonald BT, Tamai K, He X. Wnt/beta-catenin signaling: components, mechanisms, and diseases. *Dev Cell*. 2009;**17**(1):9–26.
21. Choi HK, Choi KC, Yoo JY, Song M, Ko SJ, Kim CH, Ahn JH, Chun KH, Yook JI, Yoon HG. Reversible SUMOylation of TBL1-TBLR1 regulates  $\beta$ -catenin-mediated Wnt signaling. *Mol Cell*. 2011;**43**(2):203–216.
22. Joustra SD, Heinen CA, Schoenmakers N, Bonomi M, Ballieux BE, Turgeon MO, Bernard DJ, Fliers E, van Trotsenburg AS, Losekoot M, Persani L, Wit JM, Biermasz NR, Pereira AM, Oostdijk W; IGSF1 Clinical Care Group. IGSF1 deficiency: lessons from an extensive case series and recommendations for clinical management. *J Clin Endocrinol Metab*. 2016;**101**(4):1627–1636.
23. Heinen CA, Jongejan A, Watson PJ, Redeker B, Boelen A, Boudzovitch-Surovtseva O, Forzano F, Hordijk R, Kelley R, Olney AH, Pierpont ME, Schaefer GB, Stewart F, van Trotsenburg AS, Fliers E,

- Schwabe JW, Hennekam RC. A specific mutation in TBL1XR1 causes Pierpont syndrome. *J Med Genet.* 2016;**53**(5):330–337.
24. Ng L, Kelley MW, Forrest D. Making sense with thyroid hormone—the role of T(3) in auditory development. *Nat Rev Endocrinol.* 2013;**9**(5):296–307.
25. Brucker-Davis F, Skarulis MC, Pikus A, Ishizawar D, Mastroianni MA, Koby M, Weintraub BD. Prevalence and mechanisms of hearing loss in patients with resistance to thyroid hormone. *J Clin Endocrinol Metab.* 1996;**81**(8):2768–2772.
26. Griffith AJ, Szymko YM, Kaneshige M, Quiñónez RE, Kaneshige K, Heintz KA, Mastroianni MA, Kelley MW, Cheng SY. Knock-in mouse model for resistance to thyroid hormone (RTH): an RTH mutation in the thyroid hormone receptor beta gene disrupts cochlear morphogenesis. *J Assoc Res Otolaryngol.* 2002;**3**(3):279–288.
27. Guenther MG, Lane WS, Fischle W, Verdin E, Lazar MA, Shiekhhattar R. A core SMRT corepressor complex containing HDAC3 and TBL1, a WD40-repeat protein linked to deafness. *Genes Dev.* 2000;**14**(9):1048–1057.
28. Liu XZ, Ouyang XM, Xia XJ, Zheng J, Pandya A, Li F, Du LL, Welch KO, Petit C, Smith RJ, Webb BT, Yan D, Arnos KS, Corey D, Dallos P, Nance WE, Chen ZY. Prestin, a cochlear motor protein, is defective in non-syndromic hearing loss. *Hum Mol Genet.* 2003;**12**(10):1155–1162.
29. Wémeau JL, Kopp P. Pendred syndrome. *Best Pract Res Clin Endocrinol Metab.* 2017;**31**(2):213–224.
30. Naito T, Nishio SY, Iwasa Y, Yano T, Kumakawa K, Abe S, Ishikawa K, Kojima H, Namba A, Oshikawa C, Usami S. Comprehensive genetic screening of KCNQ4 in a large autosomal dominant nonsyndromic hearing loss cohort: genotype-phenotype correlations and a founder mutation. *PLoS One.* 2013;**8**(5):e63231.
31. Huguet G, Ey E, Bourgeron T. The genetic landscapes of autism spectrum disorders. *Annu Rev Genomics Hum Genet.* 2013;**14**(1):191–213.
32. Chung RH, Ma D, Wang K, Hedges DJ, Jaworski JM, Gilbert JR, Cuccaro ML, Wright HH, Abramson RK, Konidari I, Whitehead PL, Schellenberg GD, Hakonarson H, Haines JL, Pericak-Vance MA, Martin ER. An X chromosome-wide association study in autism families identifies TBL1X as a novel autism spectrum disorder candidate gene in males. *Mol Autism.* 2011;**2**(1):18.
33. Mikkelsen EJ. Enuresis and encopresis: ten years of progress. *J Am Acad Child Adolesc Psychiatry.* 2001;**40**(10):1146–1158.
34. Johnston BD, Wright JA. Attentional dysfunction in children with encopresis. *J Dev Behav Pediatr.* 1993;**14**(6):381–385.
35. Yektaş Ç, Cansız MA, Tufan AE. Increased frequency of encopresis in a child diagnosed with attention deficit/hyperactivity disorder and encopresis after atomoxetine use: a case report. *Clin Neuropharmacol.* 2016;**39**(4):212–213.
36. Kuizenga-Wessel S, Koppen IJN, Vriesman MH, Di Lorenzo C, van Dijk M, Beelen MLR, Groeneweg M, Stoffelsen RJ, Benninga MA. Attention deficit hyperactivity disorder and functional defecation disorders in children. *J Pediatr Gastroenterol Nutr.* 2018;**66**(2):244–249.
37. Meadows J, Kraut M, Guarnieri M, Haroun RI, Carson BS. Asymptomatic Chiari type I malformations identified on magnetic resonance imaging. *J Neurosurg.* 2000;**92**(6):920–926.
38. Schanker BD, Walcott BP, Nahed BV, Kahle KT, Li YM, Coumans JV. Familial Chiari malformation: case series. *Neurosurg Focus.* 2011;**31**(3):E1.
39. Merello E, Tattini L, Magi A, Accogli A, Piatelli G, Pavanello M, Tortora D, Cama A, Kibar Z, Capra V, De Marco P. Exome sequencing of two Italian pedigrees with non-isolated Chiari malformation type I reveals candidate genes for cranio-facial development. *Eur J Hum Genet.* 2017;**25**(8):952–959.