

# Cryoprobe Transbronchial Lung Biopsy: How we do it?

Karan Madan, Saurabh Mittal, Nishkarsh Gupta<sup>1</sup>, Vijay Hadda, Anant Mohan, Randeep Guleria

Departments of Pulmonary Medicine and Sleep Disorders and <sup>1</sup>Oncoanesthesia, All India Institute of Medical Sciences, New Delhi, India

## ABSTRACT

Transbronchial lung biopsy (TBLB) is commonly utilized for diagnosis of diffuse parenchymal lung diseases. TBLB has a high yield in granulomatous interstitial lung diseases like sarcoidosis, but small size of biopsies limits its utility in idiopathic interstitial pneumonia. Surgical lung biopsy provides large size tissue, but there is associated morbidity, longer hospital stay, the risk of air leak, and mortality. Cryoprobe-TBLB, a relatively newer diagnostic procedure, provides larger biopsies than TBLB that are usually crush artifact free and enable the pathologist to provide diagnosis with greater confidence. We describe our technique of performing cryoprobe-TBLB.

**KEY WORDS:** Bronchoscopy, diffuse parenchymal lung disease, transbronchial lung biopsy

**Address for correspondence:** Dr. Karan Madan, Department of Pulmonary Medicine and Sleep Disorders, All India Institute of Medical Sciences, Ansari Nagar, New Delhi - 110 029, India. E-mail: drkaranmadan@gmail.com

## INTRODUCTION

Different operators have described varying techniques to perform cryoprobe transbronchial lung biopsy (TBLB). Need for procedure technique standardization has been highlighted to minimize the risk of complications.<sup>[1]</sup> Herein, we describe a method for performing cryoprobe-TBLB which minimizes the risk of airway bleeding and pneumothorax.

## TECHNIQUE

### Equipment

Essential equipment includes a cryostation (comprising the console and cryogen gas) along with 1.9 mm diameter flexible cryoprobe (900 mm length) and foot switch for activation. 2.4 mm cryoprobe is also available, but we use a thinner probe so that resistance during the passage of cryoprobe through flexible bronchoscope can be better appreciated and it may be less traumatic. The cryoprobe works on Joule-Thomson principle which states that a

highly pressurized gas when released, rapidly expands and creates very low-temperature environment.

The gases commonly used include carbon dioxide, nitrous oxide, and helium. We use a cryostation utilizing nitrous oxide which when released causes probe temperature to fall to  $-89^{\circ}\text{C}$  within a few seconds. Fogarty balloon catheter (diameter 4.5 Fr) is employed for bronchial occlusion following each lung biopsy to prevent blood from flooding the nonbiopsied lung segments. Availability of ultrasonography is desirable to screen for pneumothorax following biopsy. A therapeutic flexible bronchoscope (working channel of 3.0 mm or greater) along with standard equipment and anesthesia workstation for rigid bronchoscopy should be available.

### Patient selection

Adults with diffuse interstitial lung disease (ILD) are most commonly considered. A normal prothrombin time and a platelet count of at least  $50,000/\text{mm}^3$  is desirable. Patients with pulmonary hypertension and resting hypoxemia are high-risk candidates and a detailed risk-benefit

Video available on: [www.lungindia.com](http://www.lungindia.com)

Access this article online

Quick Response Code:



Website:

[www.lungindia.com](http://www.lungindia.com)

DOI:

10.4103/lungindia.lungindia\_52\_17

This is an open access journal, and articles are distributed under the terms of the Creative Commons Attribution-NonCommercial-ShareAlike 4.0 License, which allows others to remix, tweak, and build upon the work non-commercially, as long as appropriate credit is given and the new creations are licensed under the identical terms.

**For reprints contact:** [reprints@medknow.com](mailto:reprints@medknow.com)

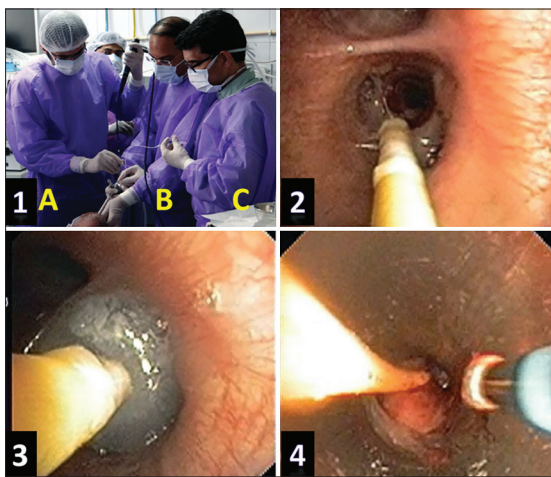
**How to cite this article:** Madan K, Mittal S, Gupta N, Hadda V, Mohan A, Guleria R. Cryoprobe transbronchial lung biopsy: How we do it?. Lung India 2018;35:520-2.

assessment may be undertaken before subjecting them for the procedure.


**Procedure**

Site of biopsy should be chosen based on the area of involvement. In diffuse lung diseases, we prefer the right lower lobe to obtain the biopsy. Patient is preoxygenated with 100% oxygen using face mask connected to the anesthesia circuit. Following induction (using fentanyl and propofol) of anesthesia and administration of muscle relaxant (atracurium), patient is intubated with size 11 ventilating rigid tracheo-bronchoscope (Karl Storz, Germany), ventilation provided from the anesthesia circuit connected to the ventilating port of the rigid bronchoscope and scope is gently maneuvered into the bronchus intermedius and positioned proximal to lower lobe segments. Direction of scope insertion is in line with the tracheal long axis and negotiation is gentle to prevent the risk of tracheal injury. 2% lidocaine gel is applied over the exterior surface of the rigid bronchoscope before insertion to minimize possibility of laryngeal-tracheal trauma. Minimal manipulation of rigid bronchoscope is performed once it is in place. The 4.5 mm rigid optical telescope (Karl Storz, Germany) utilized for providing optics during intubation is removed and a 6.0 mm diameter flexible video-bronchoscope (3.0 mm channel, Olympus BF-1T180, Olympus Corporation, Japan) is then introduced through the rigid bronchoscope barrel along with a Fogarty balloon catheter (diameter 4.5 Fr, inflatable using 1.5 mL of normal saline) and positioned at the origin of the lower lobe basal segments [Figure 1, Panel 1]. The Fogarty balloon is not introduced through the flexible bronchoscope channel but along the side of the flexible bronchoscope, through

the rigid bronchoscope channel. As a safety precaution, the Fogarty balloon is inflated to check the completeness of occlusion of basal segments to provide tamponade, then deflated and position marked at its rigid bronchoscope proximal exit site to prevent displacement following biopsy extraction [Figure 1, Panels 2 and 3]. After flexible bronchoscopic suction and clearance of secretions, the biopsy valve of the flexible bronchoscope is removed. This helps in easy passage of flexible cryoprobe and better assessment of appreciating the probe resistance on distal negotiation. A flexible 1.9 mm cryoprobe (length 900 mm, ERBE, Germany) is introduced through the working channel of bronchoscope and advanced into the chosen segment till resistance is felt. The probe is retracted by 2–3 cm and the foot pedal of cryostation is activated for 5 s. We do not use fluoroscopy for the performance of cryoprobe-TBLB, but its use may be desirable for accurate localization of the cryoprobe tip. At this time, the anesthetist withholds the ventilation, and apneic oxygenation is continued. The cryoprobe is then pulled back forcefully along with the flexible bronchoscope [Figure 1, Panel 4]. The cryoprobe is not withdrawn through the channel of the flexible bronchoscope as doing that shall lead to the larger lung biopsy specimen to detach. The cryoprobe and the flexible bronchoscope are pulled together with a quick pulling movement. As soon as there is a giveaway of the resistance and the cryoprobe tip (with biopsy attached) is visualized, the assistant immediately inflates the Fogarty balloon [Figure 1, Panel 3]. Inflation is maintained for 45 s during which time the apnea is continued. Fogarty balloon inflation is performed following each and every biopsy without waiting for the bleeding to be visualized. This is performed because bleeding following cryoprobe-TBLB can be sometimes massive and can lead to rapid airway flooding with blood. Therefore, prophylactic Fogarty balloon inflation following biopsy is routine. During this time, the assistant separates the biopsy piece from the cryoprobe [Figure 2] and collects it in a formalin fixative vial and the flexible bronchoscope is quickly reintroduced to check for any active bleeding. Fogarty balloon position and adequate inflation. 45 s following the biopsy, ventilation is resumed or earlier if there is desaturation. During ventilation, peak airway pressures should be kept below 30 cm H<sub>2</sub>O with a respiratory rate maintained between 12 and 15 breaths/min to minimize the risk of barotrauma. The balloon is deflated 90 s after



**Figure 1:** Panel 1 - Operator positioning during procedure. Primary operator (A) handles the flexible bronchoscope passed through the rigid bronchoscope and performs the cryoprobe-transbronchial lung biopsy. Assisting operators (B and C) hold the rigid bronchoscope and Fogarty balloon, respectively. Panel 2 - The Fogarty balloon is positioned just proximal to the segmental openings from where cryoprobe-transbronchial lung biopsy will be performed. Panel 3 - Prebiopsy check to ensure Fogarty balloon is able to completely occlude the biopsied segments. Panel 4 - Cryoprobe tip with biopsy attached during the retrieval step



**Figure 2:** Left panel - The cryobiopsy seen attached to the flexible cryoprobe tip following extraction. Right panel - The finally obtained cryobiopsy seen separate from the cryoprobe with sizing scale

the biopsy extraction step, under flexible bronchoscopic vision. If bleeding is ongoing, balloon is reinflated again for 90 s else, the next biopsy is performed in a similar manner. Usually, a total of 2–4 biopsies are performed. After excluding any significant airway bleeding and flexible bronchoscopic suction to remove spilled over blood/clots, the flexible bronchoscope is removed, and the rigid optical telescope is reinserted. The aggressive suction of stable clot from the primarily biopsied segment should be avoided. Rigid bronchoscope is removed gently to avoid any airway injury during extubation. A supraglottic airway (I-gel) of appropriate size is inserted thereafter and ventilation is resumed with careful attention to airway pressures as previously described. After adequate recovery from anesthesia, the supraglottic airway is removed and the patient shifted to the observation room for recovery. The endoscopic view while performing the procedure is shown in Video 1 available at [www.lungindia.com](http://www.lungindia.com).

A screening ultrasound of thorax is performed immediately following procedure/during procedure if pneumothorax is suspected, to exclude pneumothorax. A chest radiograph is obtained 2 h later as pneumothorax/pneumomediastinum can occur as delayed complications. In an uneventful procedure, patient can be discharged home the day of the procedure.

## CONCLUSION

Concerns with cryoprobe-TBLB include the risk of bleeding, pneumomediastinum, pneumothorax with some studies reporting postprocedure pneumothorax in nearly one-fourth subjects.<sup>[2,3]</sup> Excessive bleeding has been reported when performed using a flexible bronchoscope exclusively.<sup>[4]</sup> We recommend rigid bronchoscopy in all patients as the risk of airway bleeding, and possible airway loss is higher without rigid bronchoscopy.<sup>[4]</sup> Second, general anaesthesia enables apnea while taking biopsy that minimizes the risk of pneumothorax. The technique we describe is applicable to adult patients only, as in

children different size of equipment may be required and complications rates may be higher. In patients with focal lung lesions, radial probe endobronchial ultrasound can be used to localize the lesion followed by cryoprobe biopsy from the same area.

One of the major considerations regarding utilization of cryoprobe-TBLB is the availability of rigid bronchoscopy facilities. The procedure definitely has a higher incidence of complications as compared with conventional TBLB, but the morbidity is lesser than that of surgical (open or video-assisted thoracic surgery) biopsy. The procedure should be reserved for patients, wherein it is expected that conventional TBLB may not provide a large enough tissue for accurate diagnosis or if TBLB was performed and failed to provide a diagnosis. Most ILD's in our country remain uncharacterized due to the lack of tissue diagnosis, and this technique may help in better understanding of ILD epidemiology in India and optimize patient management.<sup>[5]</sup>

## Financial support and sponsorship

Nil.

## Conflicts of interest

There are no conflicts of interest.

## REFERENCES

1. Poletti V, Hetzel J. Transbronchial cryobiopsy in diffuse parenchymal lung disease: Need for procedural standardization. *Respiration* 2015;90:275-8.
2. Casoni GL, Tomassetti S, Cavazza A, Colby TV, Dubini A, Ryu JH, *et al.* Transbronchial lung cryobiopsy in the diagnosis of fibrotic interstitial lung diseases. *PLoS One* 2014;9:e86716.
3. Madan K, Mehta S, Gupta N, Hadda V, Mohan A, Guleria R. Pneumomediastinum and extensive subcutaneous emphysema after cryoprobe transbronchial lung biopsy. *Ann Am Thorac Soc* 2016;13:2101-3.
4. Dhooria S, Sehgal IS, Bal A, Aggarwal AN, Behera D, Agarwal R. Transbronchial lung biopsy with a flexible cryoprobe during rigid bronchoscopy: Standardizing the procedure. *Lung India* 2016;33:248-9.
5. Madan K, Hadda V, Mohan A, Guleria R. The ILD-India registry: Look before you leap. *Am J Respir Crit Care Med* 2017;195:836-7.