

Available online at [www.sciencedirect.com](http://www.sciencedirect.com)

ScienceDirect

journal homepage: <http://Elsevier.com/locate/radcr>

## Case Report

## Adult presentation of symptomatic left lung agenesis

Omer Kaya MD<sup>a,\*</sup>, Bozkurt Gulek MD<sup>a</sup>, Cengiz Yilmaz MD<sup>a</sup>, Gokhan Soker MD<sup>a</sup>, Kaan Esen MD<sup>b</sup>, Mehmet Ali Akin MD<sup>a</sup>, Okan Dilek MD<sup>a</sup><sup>a</sup> Department of Radiology, Adana Numune Teaching and Research Hospital, Ege Bagatur Boulevard, 01240, Yuregir, Adana, Turkey<sup>b</sup> Department of Radiology, Faculty of Medicine, Mersin University, 34th Street, 33110, Yenisehir, Mersin, Turkey

## ARTICLE INFO

## Article history:

Received 4 June 2016

Accepted 22 November 2016

Available online 13 January 2017

## Keywords:

Agenesis

Lung

## ABSTRACT

Pulmonary agenesis is a rarely encountered congenital anomaly, and its average prevalence is about 1 in 100,000 births. Anomalies of the cardiovascular, musculoskeletal, gastrointestinal, or genitourinary systems may accompany in nearly half of the cases. The diagnosis of pulmonary agenesis is usually made during childhood, but the diagnosis may be delayed until adulthood in case of an absence of comorbid anomalies. Herein, we present a case of pulmonary agenesis that was diagnosed during adulthood.

© 2016 the Authors. Published by Elsevier Inc. under copyright license from the University of Washington. This is an open access article under the CC BY-NC-ND license (<http://creativecommons.org/licenses/by-nc-nd/4.0/>).

## Case presentation

A 24-year-old woman applied to our hospital with mild respiratory distress and wheezing, associated with intermittent chest pain, more prominent at the left side. Her history revealed no such complaints during childhood. Her complaints started during adolescence and was aggravated with effort. No respiratory sounds could be detected at the lower left hemithorax during physical examination. Spirometry test results were compatible with restrictive pulmonary disease: FVC: 2.18 L (pred % 61), FEV1: 1.94 L (pred % 63), FEV1/FVC: 89 (pred % 106).

Thoracic computed tomography examination revealed total absence of the left lung. Also noted was compensatory increase in the right lung volume which partially extended to the left hemithorax. The heart and the main vasculature were positioned at the middle and lower portions of the left

hemithorax (Fig. 1). The descending aorta was located laterally to the right side of the heart (Fig. 2). It was also noted that the pulmonary conus comprised only the right pulmonary artery (Fig. 3). The left pulmonary artery was absent, together with the left pulmonary veins (Fig. 4). The electrocardiographic and radiologic tests did not reveal any additional cardiac anomalies.

Thorough interpretation of topographic computed tomography scanograms and slices demonstrated accompanying cervical, thoracic, and lumbar vertebral scoliotic deformities (Fig. 5). In addition to these findings, the left-sided osseous structures of the shoulder and the left breast were smaller than their right-sided symmetricals (Fig. 6). Abdominopelvic sonography was unremarkable.

A therapy regimen consisting of “formoterol 9 mcg + budesonide 320 mcg” (2 × 1 daily) was planned for symptomatic relief of respiratory complaints.

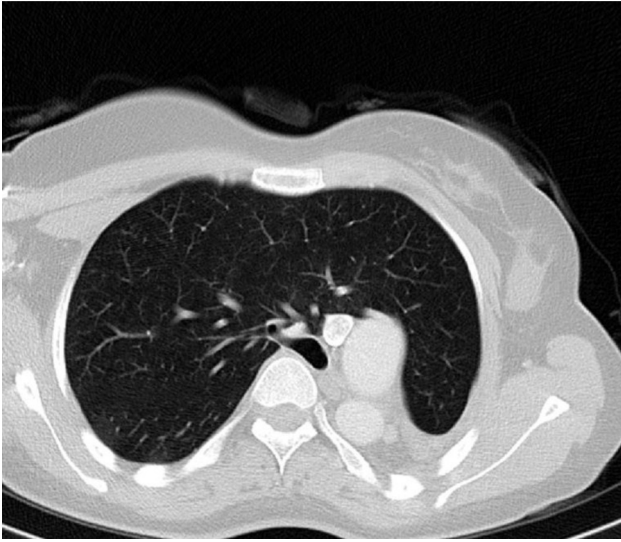
Competing Interests: The authors declare that they have no competing interest.

\* Corresponding author.

E-mail address: [dr.omerkaya@gmail.com](mailto:dr.omerkaya@gmail.com) (O. Kaya).

<http://dx.doi.org/10.1016/j.radcr.2016.11.023>

1930-0433/© 2016 the Authors. Published by Elsevier Inc. under copyright license from the University of Washington. This is an open access article under the CC BY-NC-ND license (<http://creativecommons.org/licenses/by-nc-nd/4.0/>).



**Fig. 1 – Axial computed tomography (CT) image of the thorax reveals total absence of the left lung. Also noted is compensatory increase in the right lung volume partially extending to the left hemithorax.**

## Discussion

Pulmonary agenesis is a rare condition [1,2]. Its prevalence is similar in males and females. Some studies suggest a higher

rate for the left pulmonary agenesis in comparison to right, while still most others indicate a similar rate for both the right- and left-sided pulmonary agenesis. A longer life expectancy is an issue in the left-sided pulmonary agenesis, when compared to the right-sided version [3]. The underlying reason for the poor prognosis and shorter life expectancy in the right-sided pulmonary agenesis is thought to be the mediastinal shift and carinal malrotation, which lead to blockage of pulmonary drainage, and in turn to an increase in the tendency to develop pulmonary infections [4].

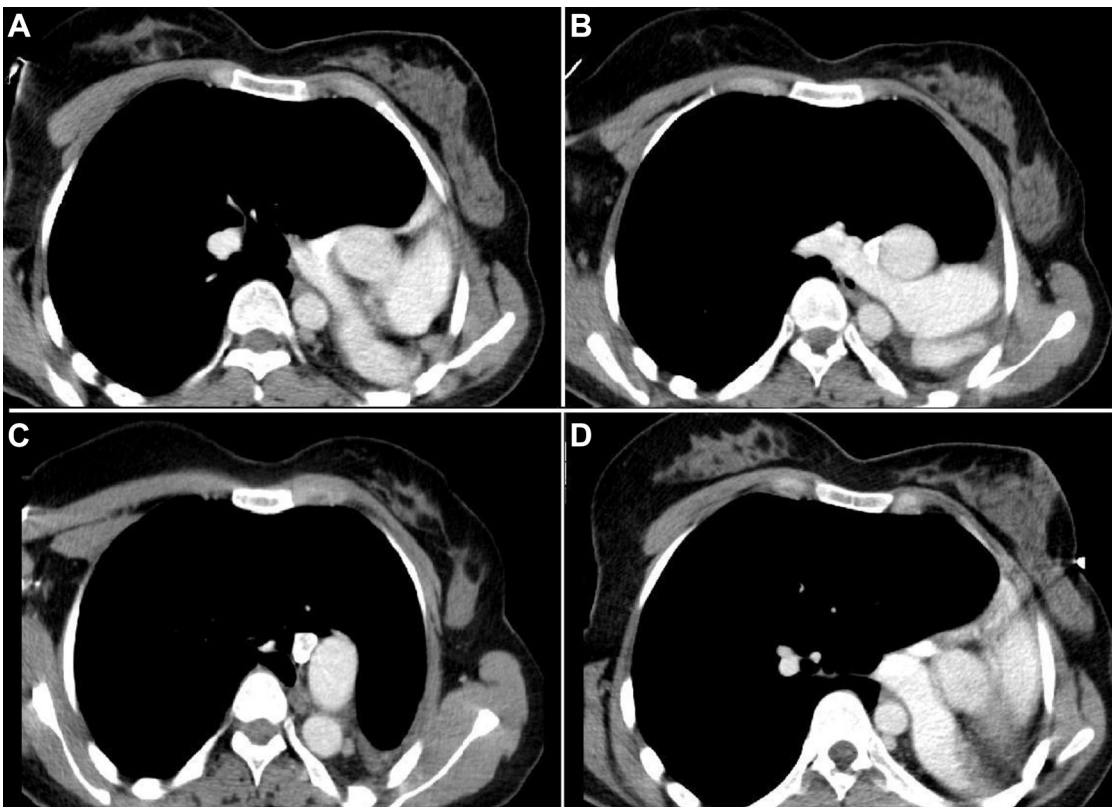
The embryogenesis of the pulmonary system begins at the fourth gestational week, by the differentiation of the laryngotracheal bud (respiratory diverticulum). Certain negative effects have been held responsible for the development of pulmonary agenesis during this period. Even though the etiology is not fully understood, it is thought that vitamin A or folic acid deficiency or the mother's use of salicylates may be the cause [5].

Pulmonary agenesis has been classified by Schneider into three categorical groups according to the developmental stage of the primitive pulmonary bud. This classification has been modified by Boyden [6] and is as follows:

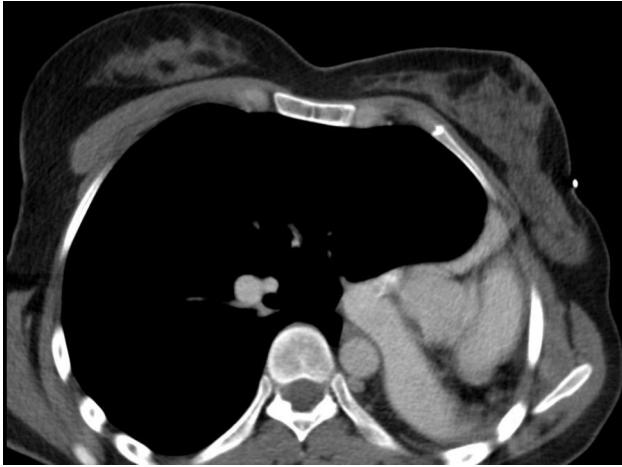
Type 1 (agenesis): Complete absence of lung and bronchus and no vascular supply to the affected side.

Type 2 (aplasia): Rudimentary bronchus with complete absence of pulmonary parenchyma.

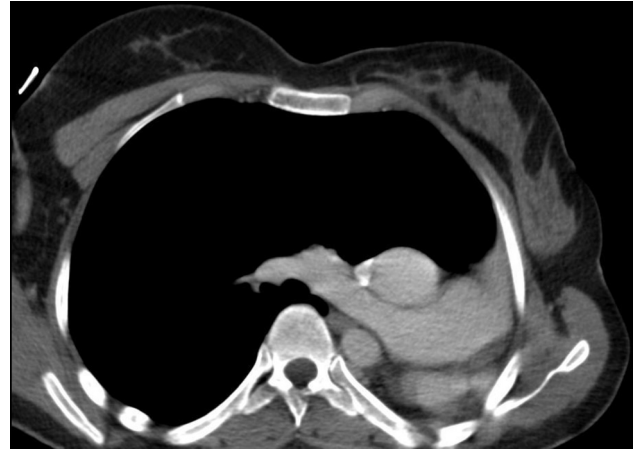Type 3 (hypoplasia): Presence of variable amounts of bronchial tree, pulmonary parenchyma, and supporting vasculature.



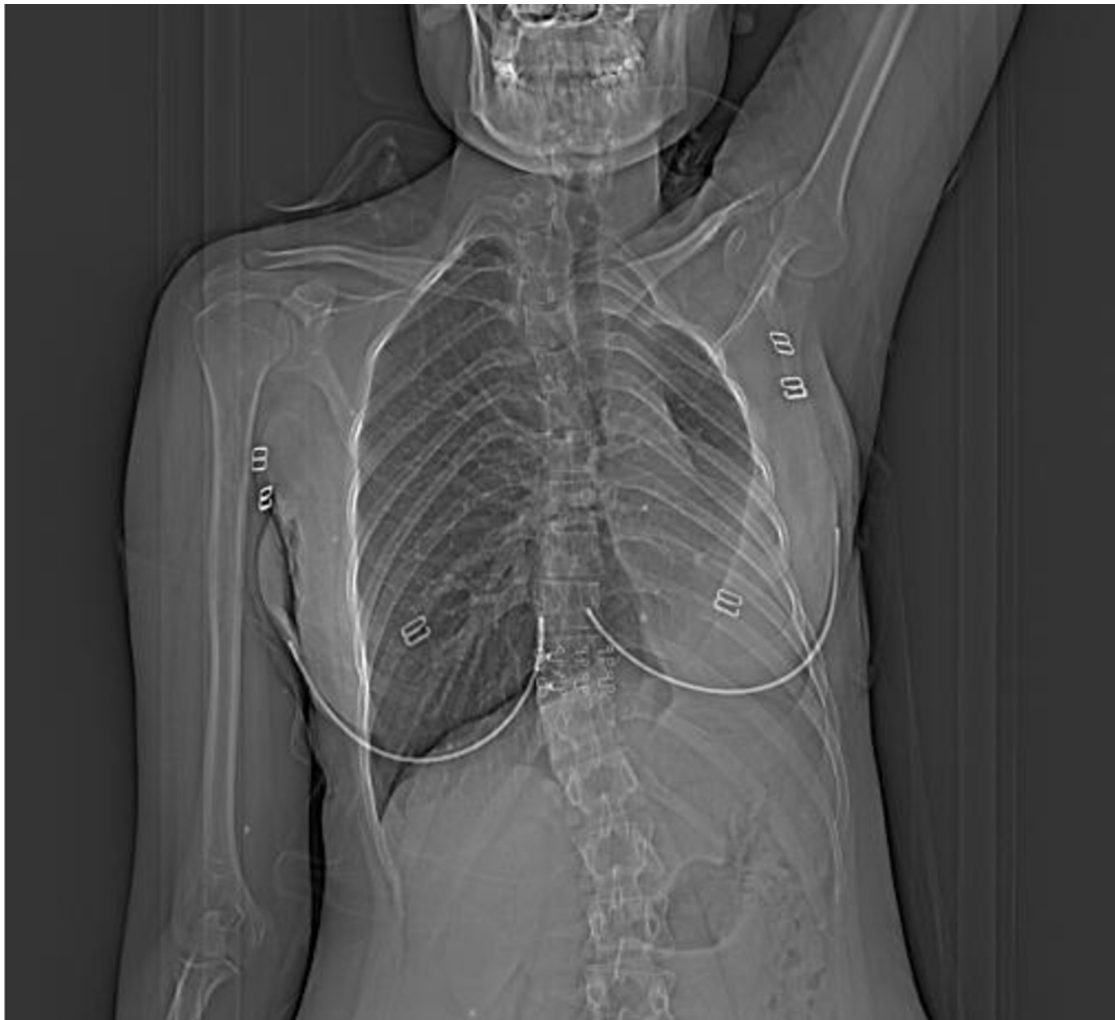**Fig. 2 – Axial computed tomography (CT) image of the thorax shows the abnormal course of the descending aorta localized at the right side of the heart. Each parts (A-D) of figure shows a different level of descending aorta.**



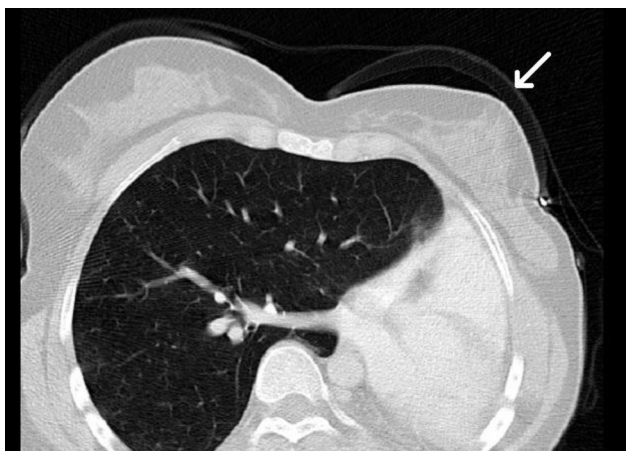
**Fig. 3** – Axial computed tomography (CT) image of the thorax obtained at the level of the pulmonary arteries. Note absence of the left pulmonary artery. The right pulmonary artery is normal.



**Fig. 4** – Axial computed tomography (CT) image of the thorax obtained at the level of the pulmonary veins. Note absence of the left pulmonary vein. The right pulmonary vein is normal.



**Fig. 5** – Scout views of the computed tomography (CT). It demonstrates the scoliotic deformities of the cervical, thoracic, and lumbar spine.



**Fig. 6 – Axial computed tomography (CT) image of the thorax reveals a small left breast (arrow). The right breast is normal.**

In half of the cases, cardiovascular, musculoskeletal, gastrointestinal, or genitourinary system anomalies accompany pulmonary agenesis. In a study conducted by Booth et al, accompanying vertebral and rib anomalies have been reported [7]. Congenital cardiac diseases are present in one-third of the cases. Cardiac anomalies such as tricuspid insufficiency, Tetralogy of Fallot, total pulmonary venous return anomaly, patent ductus arteriosus, coarctation of the aorta, and atrial and ventricular septal defects are known to accompany pulmonary agenesis [8]. Managoli et al have reported a case of pulmonary agenesis in which accompanying renal agenesis and adrenal gland-originated neuroblastoma were present [9].

In unilateral pulmonary agenesis, clinical findings may vary according to the accompanying comorbid anomalies. Patients may reach adulthood or may even live their entire lives without developing any symptoms. Some cases may present with a decrease in vital capacity, together with effort-induced respiratory restraint. Adults may demonstrate an increase in the frequency of respiratory infections and the development of respiratory disease. Recurrence of respiratory infections increases the risk of respiratory distress [2].

#### REFERENCES

- [1] Conway K, Gibson RL, Perkins J, Cunningham ML. Pulmonary agenesis: expansion of the VCFS phenotype. *Am J Med Genet* 2002;113(1):89–92.
- [2] Richard S. Pulmonary abnormalities of developmental origin. In: Richard S, editor. *Synopsis of Diseases of the Chest*. 2nd ed. Philadelphia: W. B. Saunders Company; 1994. p. 256–86.
- [3] Oyamada A, Gasul BM, Holinger PH. Agenesis of the lung. *Am J Dis Child* 1953;85(2):182–201.
- [4] Kisku KH, Panigrahi MK, Sudhakar R, Nagarajan A, Ravikumar R, Daniel JR. Agenesis of lung—a report of two cases. *Lung India* 2008;25(1):28–30.
- [5] Roque AS, Burton EM, Boedy RF, Falls G, Bhatia JS. Unilateral pulmonary agenesis without mediastinal displacement. *South Med J* 1997;90(3):335–7.
- [6] Boyden E. Developmental anomalies of lung. *Am J Surg* 1955;89:79–88.
- [7] Booth JB, Berry CL. Unilateral pulmonary agenesis. *Arch Dis Child* 1967;42(224):361–74.
- [8] Yetim TD, Bayaroğulları H, Yağcıoğlu HP, Anca V, Anca SG. Congenital agenesis of the left lung: a rare case. *J Clin Imaging Sci* 2011;1(3):1–3.
- [9] Managoli S, Chaturvedi P, Krishna Y, Gagane V, Gagane N. Unilateral pulmonary agenesis and renal anomalies associated with in situ neuroblastoma of the adrenal gland. *Indian J Pediatr* 2004;71(6):545–7.