

## Case Report

# Surgical Treatment of Intrapelvic Pseudotumour after Hip Resurfacing Arthroplasty: Case Report and Literature Review

**Cristian Barrientos,<sup>1,2</sup> Julian Brañes,<sup>3</sup> José-Luis Llanos,<sup>4</sup> Alvaro Martinez,<sup>3</sup> and Maximiliano Barahona <sup>1,2</sup>**

<sup>1</sup>Orthopaedic Department at Hospital Clinico Universidad de Chile, Santos Dumontt 999, Santiago, Chile

<sup>2</sup>Hospital Clinico Universidad de Chile, 999 Santos Dumont av., Independencia, Santiago 8380456, Chile

<sup>3</sup>Orthopaedic Department at Hospital San José, 1196 San Jose av. Independencia, Santiago 8380419, Chile

<sup>4</sup>Coloproctology Surgery at Hospital Clinico Universidad de Chile, Santos Dumontt 999, Santiago, Chile

Correspondence should be addressed to Maximiliano Barahona; [maxbarahonavasquez@gmail.com](mailto:maxbarahonavasquez@gmail.com)

Received 23 April 2018; Revised 8 August 2018; Accepted 15 August 2018; Published 25 October 2018

Academic Editor: Koichi Sairyo

Copyright © 2018 Cristian Barrientos et al. This is an open access article distributed under the Creative Commons Attribution License, which permits unrestricted use, distribution, and reproduction in any medium, provided the original work is properly cited.

Hip replacement is the surgery of the last century due to its impact on the quality of life. A pseudotumour is a rare complication of hip arthroplasty, and it is related to a metal-bearing surface. Pseudotumour is a challenging scenario for hip surgeons due to poor clinical outcomes. The patient consulted for hip pain and paresthesia in the left lower extremity, and analyses showed that the cause was a sizeable intrapelvic pseudotumour. A multidisciplinary team surgery was planned. At first, an infraumbilical approach was made to resect the intrapelvic-retroperitoneum portion of the pseudotumour. Then, a posterolateral hip approach was performed, to resect the remaining portion of the pseudotumour and revision arthroplasty. At five years of follow-up, there are no clinical or imaging signs of recurrence of the pseudotumour. Treatment evidence is limited to a series of cases and expert opinions; we encourage complete resection and revision arthroplasty.

## 1. Introduction

Hip replacement is the surgery of the last century due to its impact on the life of quality [1]. Different types of prosthesis design exist. In traditional total hip replacement (THR), the head of the femur is removed, and a stem is placed inside the femoral metaphysis. In the early 1990s, hip resurfacing arthroplasty (HRA) was introduced; there was no significant difference in the acetabulum component, but in the femoral side, only the femur head is replaced and a short stem is used; therefore, the metaphysis of the femur remains intact. So, compared to THR, HRA preserves more bone, has lower stress shielding, and has lower surgery morbidity (i.e., less bleeding). A few case series have shown good results in the short and medium terms [2, 3].

Two major concerns for HRA are described: a higher incidence of neck fracture because, for design, more stress

is placed in the neck of the femur and the other concern is metal ion risk [4]. All prosthesis models have a bearing surface: one in the acetabulum and other in the femoral head. Different materials have been used as a bearing surface, such as polyethylene, ceramic, and metal. The amount and size of the debris depend on the material used as a bearing surface and are associated with the aseptic loosening of the prosthesis [5]. HRA uses metal on metal-bearing surface only, and this bearing surface is related to a particular complication known as a pseudotumour.

The most specific histological finding of a pseudotumor is a lymphocytic immune response described as an aseptic lymphocytic injury-associated vasculitis (ALVAL) [6]. Its formation has been associated with high serum levels of cobalt and chromium; however, the physiopathology remains unclear given that the most frequent findings consist of an infiltrate of monocytes, reparative tissue, giant cells, and areas of necrosis [7, 8].

The surgical treatment of pseudotumour is a theme of discussion, and only a few clinical series have been published [9]. Treatment should include pseudotumour resection and revision hip arthroplasty (RHA). The extension of the pseudotumour resection is on a debate and, sometimes due to its extension, is not completely resected. RHA consists of removing all the prosthetic components, including the bearing surface and replacing them with a new prosthesis [10].

Our purpose is to report the case of a patient in which a complete resection of an intrapelvic pseudotumor that compromised the retroperitoneum, following an HRA, was performed, showing no signs of recurrence after five years of follow-up.

## 2. Case Report

A 46-year-old female patient underwent a left hip resurfacing arthroplasty (Birmingham®, UK) for severe hip osteoarthritis, secondary to developmental hip dysplasia, in 2005. She had a good initial outcome with no complications. The surgery was performed in another centre.

She consulted with us for the first time six years later (2011) complaining about hip pain and paresthesia in the anterior left thigh, which progressively compromised her function. She denied fever or other signs of infection. Physical exams revealed a mild claudication gait and limited active and passive hip flexion. No palpable masses or skin lesions were observed. Laboratory analyses showed a WBC, ESR, and CRP within normal limits. No signs of osteolysis were found in the hip anteroposterior radiography; nevertheless, a vertical cup was noted (Figure 1). It was compared with the immediate postsurgery radiography, and no change was noted.

Computed tomography and an MRI demonstrated a bilobulate hypodense mass of approximately 34 × 19 cm that extended from the retroperitoneum, compromising the left iliopsoas muscle and an intimate contact with the femoral vessels, to the left hip and the left femoral-cutaneous nerve (Figures 2 and 3). A routine hip arthrocentesis was performed to rule out infection. The cytochemical and Gram analyses were negative for infection. Cultures were negative after 14 days.

Thus, a pseudotumour was the diagnosis, and surgery led by an orthopaedic surgeon and a coloproctology surgeon was planned. The aim was to remove the pseudotumor entirely and to perform an RHA. As the CT shows (Figure 2(d)), the intrapelvic mass was significant, so it was decided to start with a laparotomy by the coloproctology surgeon.

First, the patient was positioned supine, and an infraumbilical laparotomy was performed; the left paracolic gutter was dissected to address the retroperitoneum. The iliac vessels and the left ureter were protected, and an irregular cystic mass was observed in direct contact with the psoas muscle and femoral bundle. It was punctured, and an abundant grey milky-like fluid was obtained. The membrane of the cyst was carefully removed, protecting the vessels and the femoral nerve. The lesion was completely resected, and samples were sent for biopsy and cultures (Figure 4).

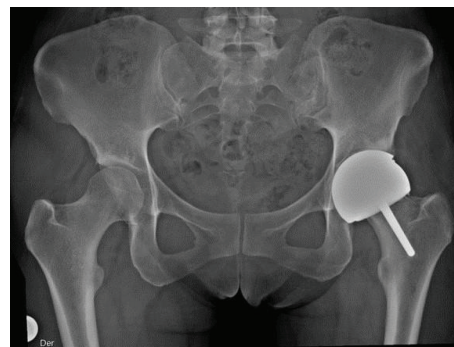


FIGURE 1: Postoperative AP radiograph showing the left hip's resurfacing arthroplasty. Femoral head was 46 mm. Acetabular cup was 52 mm and was placed too vertical; malposition of the components is a risk factor for pseudotumour [8].

Then, the patient was repositioned in lateral decubitus, and a posterolateral hip approach was performed. The capsule was looking distend; it was punctured and then, a 30 cc fluid was obtained, similar to the liquid found in the retroperitoneum. After capsulotomy and femoral neck osteotomy, all arthroplasty components were removed, noticing an anterosuperior wall defect in the acetabulum. After complete pseudotumour resection, RHA was performed (Figure 5). The acetabular cup component was a cementless 56 mm Dynasty® (Wright Medical, Memphis, USA), and the femoral component was a high offset femoral cementless stem (Stellaris®, Mathys, Bettlach, Switzerland, no. 17). The bearing surface used was polyethylene-ceramic, being Dynasty® polyethylene liner, on the acetabulum and a 40 mm ceramic on the femoral head (BIOLOX®, Mathys, Bettlach, Switzerland). Post surgery, an anteroposterior pelvic radiograph was taken (Figure 6). After fourteen days, tissue cultures obtained at surgery were negative for infection.

Histopathological findings confirm the pseudotumour. The analyses reported an extensive aseptic inflammatory infiltrate of macrophages with detritus inside near a necrotic tissue area (Figure 7(a)). A PAS histochemical stain confirmed these findings. No signs of ALVAL were observed. Also, reparative tissue was found with black particulate material corresponding to the prosthetic material near the neoformation of blood vessels and fibroblast (Figure 7(b)).

No early- or late-surgery complication is reported. Since post surgery, the patient progressively recovers the hip's range of motion and normal gait. In the last follow-up, 60 months postoperatively, the patient is in excellent condition with no functional limitations and a full hip range of motion. Radiological exams, which included an annual MRI, showed no pseudotumour formation and no arthroplasty loosening. The MRI at five years of follow-up is shown in Figure 8.

## 3. Discussion

Pseudotumour is a rare complication of hip arthroplasty, and it is related to a metal-bearing surface [11]. The treatment planned in this case, which included complete resection of

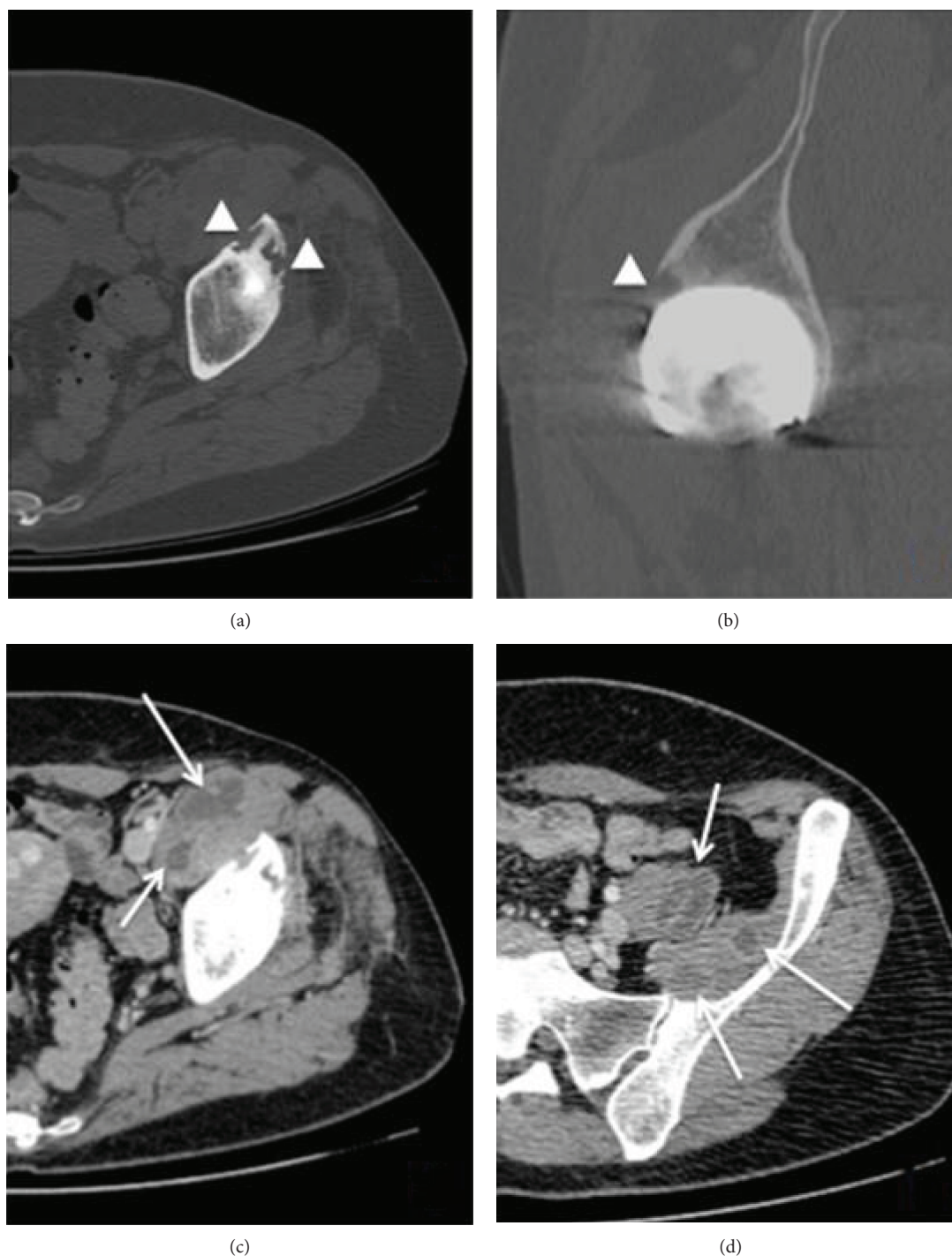


FIGURE 2: Computed tomography of the left hip: axial (a) and sagittal (b) views show periprosthetic osteolytic lesions (arrow head) in the anterior acetabular roof. Axial views (c, d) show a polylobate cystic lesion in the retroperitoneum compromising the left iliopsoas muscle with white arrows.

the pseudotumour and RHA, achieves excellent clinical outcomes, as the patient had no signs of pseudotumour after five years of follow-up.

It is well known that pseudotumour goes underdiagnosed; recent studies show that the prevalence of pseudotumour could be higher than previously reported [12]. In a cohort of 125 patients (143 hips, Birmingham® HRA), 28%

had pseudotumour in the CT study. Most patients (72.5%) were asymptomatic. The most common symptoms described were a hip pain, a palpable mass, or paresthesia [13]. Another study showed a substantially higher incidence of pseudotumour formation in metal-on-metal THA, reaching 42 patients (39%) diagnosed with a pseudotumour, while 13 (12%) of these were symptomatic and were revised [9].

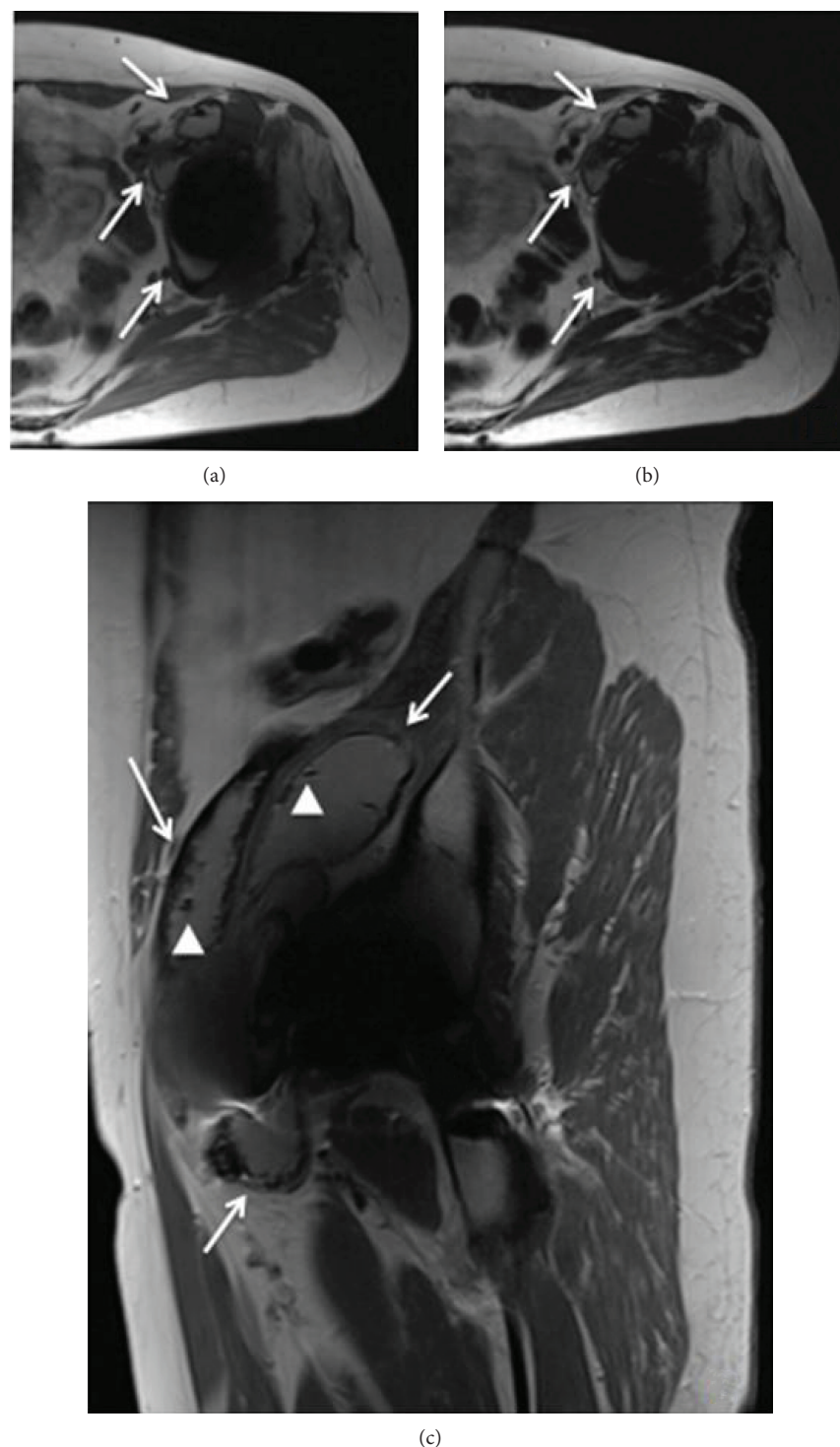


FIGURE 3: In the metal artefact reduction sequence magnetic resonance imaging (MARS MRI), axial T1 (a), axial T2 (b), and sagittal T1 (c) show the presence of two lesions of thick walls located anterior to the psoas and iliacus (arrows) muscle. Within the lesion, a small focus of artefact is seen (arrow heads). This finding is critical to determining that the aetiology of the pseudotumour is “metallosis.”

Moreover, delayed diagnosis drives to increase the size of the pseudotumour with more bone and soft tissue damage; therefore, there are more complications and poor clinical revision outcomes [14–16]. It is critical to remark that the longer the follow-up is, the higher the incidence of pseudotumour and its symptoms is.

Pseudotumour diagnosis is not easy as patients remain asymptomatic for a long time. As it is a well-known complication, screening with images must be performed on all prosthesis with a metal-bearing surface [17]. Moreover, we believe that the imaging study should include an MRI, which features high sensitivity and specificity for diagnosis, and a

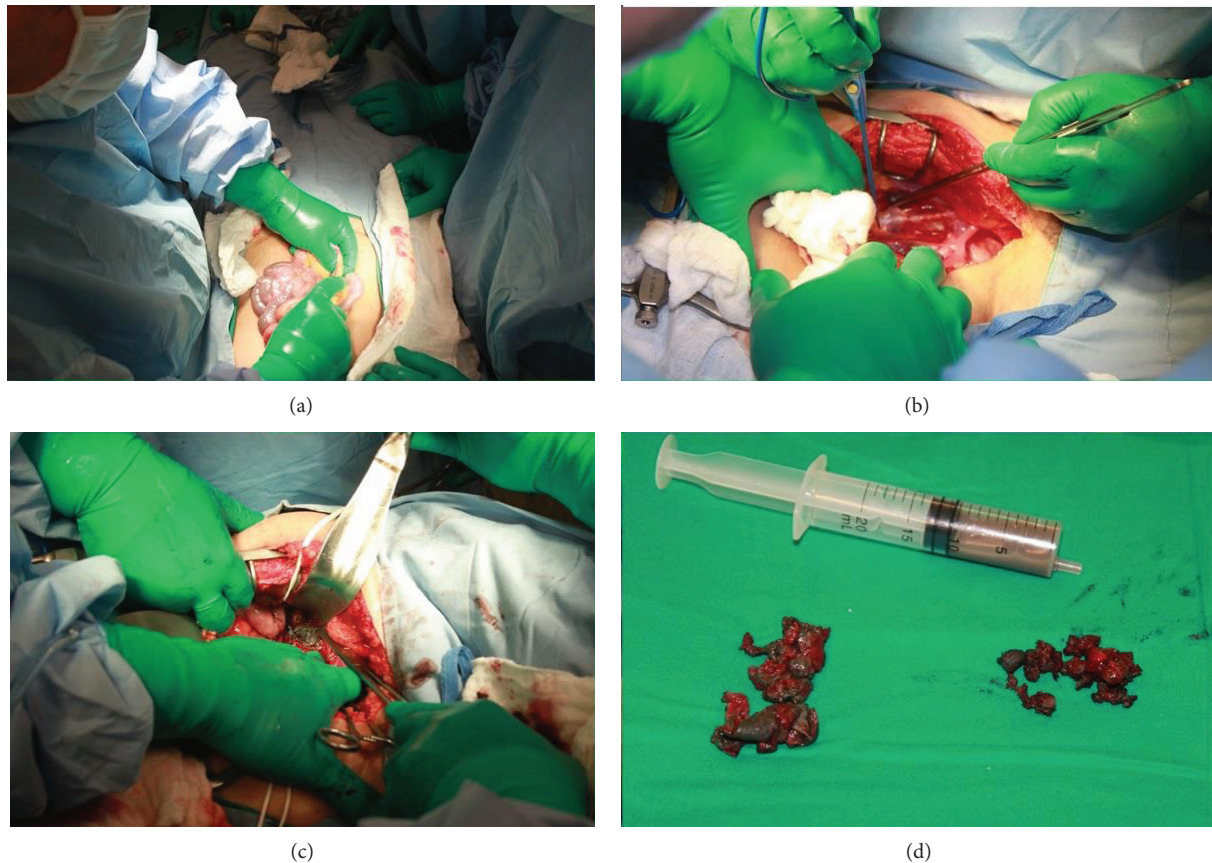


FIGURE 4: Four images from the first step of the surgery are shown. After a midline longitudinal infraumbilical approach, the left paracolic gutter was addressed (a) to obtain access to the retroperitoneum (b); a cystic tumour was observed in intimate contact with the iliopsoas muscle and the femoral nerve and vessels (c). The pseudotumour was punctured, and a grey milky-like fluid was obtained; then, the tumour was completely resected (d).

better definition of pseudotumour for diagnosis and operative planning [14, 18], especially in places where the measurement of metal ions in the blood is not available as it is in our case [19, 20].

Another issue that cannot be missed is that infection must be ruled out, as it is also a complication of THA and it transcends all prosthesis design [21]. For this, joint arthrocentesis and a synovial fluid analysis must be performed routinely. The liquid obtained must be sent to a traditional study and prolonged microbiological cultures for two weeks, according to international publications [22].

Regarding the aetiology of pseudotumours, current evidence attributes it to an adverse reaction to metal debris. Some studies indicate that this is due to a local inflammatory response to wear of the metal surface, which develops a granulomatous-like reaction proportional to the amount of the wear debris, and it correlates with the amount of metal ions in plasma [23, 24]. Beside the bearing surface, it has been reported as risk factor of hip dysplasia, malposition of prosthesis components, and larger size of the femoral head of the prosthesis hip dysplasia—all of them associated to excessive wear [8]. On the other hand, Willert et al. describe that pseudotumour is an aseptic lymphocyte-dominated vasculitis- (ALVAL-) associated lesion which is a delayed hypersensitivity reaction type and seems to be mildly related

to the amount of wear debris. The most characteristic histological features of ALVAL were diffuse and perivascular infiltrates of lymphocytes and plasma cell infiltrates of eosinophilic granulocytes and necrosis. Only a few metal particles were detected [6, 25–27]. According to the recently published histopathological classification of joint implant-related pathology, this case corresponds to a “type 1: particle type,” in which the hallmark is the infiltrate of macrophages often with foamy feature and multinuclear giant cell, in which prosthesis wear can be detected [22].

Pseudotumour, as it has been established in previous paragraphs, is not an exclusive complication of RHA, but of those that use metal on metal-bearing surface. Even more, few cases have been reported supporting that pseudotumour could also be triggered by metal ion release from the head-neck taper junction in cases where no metal on metal-bearing surface was used [28]. The highest incidence of this complication in resurfacing prosthesis happens because they use only metal on metal-bearing surface [29]. A series with extended follow-ups of Birmingham® HRA had shown a significant rate of early failure, being the most frequent cause of a metal ion adverse reaction confirmed by histological analysis [2, 30]. Ollivier et al. report a series of 463 Birmingham® hip resurfacing [31], in which 9 of them had macroscopic and histological evidence of adverse

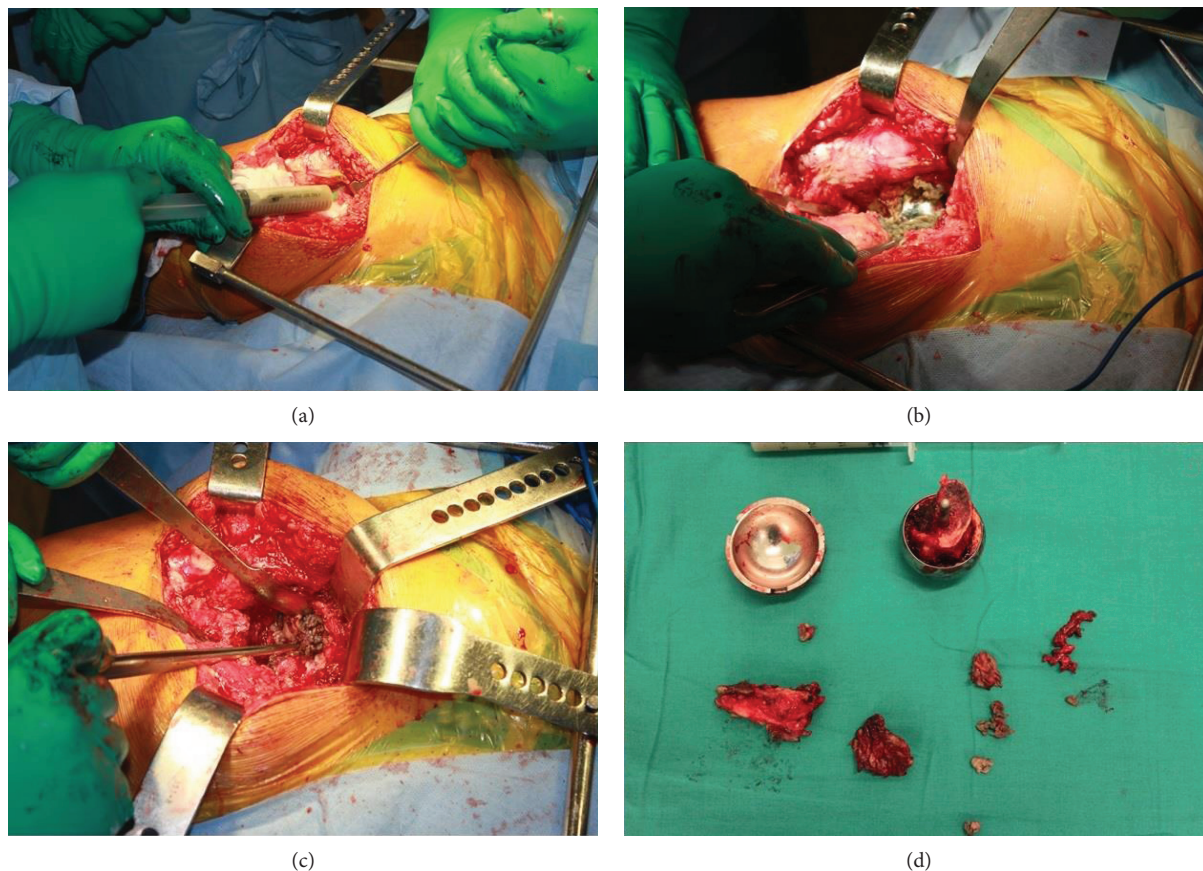


FIGURE 5: Four images from the second step of the surgery are shown. Through a posterolateral hip approach, an RHA was performed. The capsule was looking distend, so it was punctured (a), after capsulotomy the pseudotumour was evident (b), all components were removed, and an anterosuperior acetabulum wall defect was observed (c). Tumour sample, liquid and the hip prosthesis removed are shown in (d).

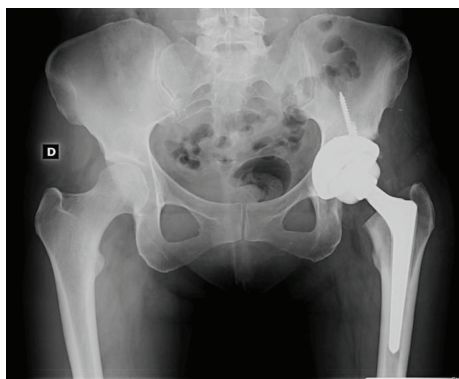


FIGURE 6: In an immediate post-RHA pelvis anteroposterior X-ray, an adequate position of the components is seen.

reaction to metal debris. The main risk factors in this study were female gender, a small femoral component, a high abduction angle, and obesity. They do not recommend the use of Birmingham® HRA in these patients [31]. A more extensive series of 4226 hips with three types of HRA found 58 failures associated with adverse reaction to metal debris. The median ion concentrations in the failed group were significantly higher than those in the control group. Increased wear from the metal-on-metal-bearing surface

was associated with an increased rate of failure secondary to an adverse reaction. Moreover, revision surgery seems to be useful to decrease the blood concentration of metal ions [32].

There are only case report evidences of the surgical treatment of this pathology [33–35]. Consensus exists to perform pseudotumour resection and RHA, mainly changing the metal-bearing surface; however, the amount of pseudotumour resection is not precise, and some authors prefer to resect what is around the hip, leaving the pseudotumour in more difficult areas to address such as the retroperitoneum [9, 36]. In our case, an aggressive tumour resection by a double approach was decided after considering the pseudotumour extension and neurological compromise. We believe that the complete resection of the pseudotumour is related to successful outcomes, and it is supported by some authors [32]. Until our last follow-up almost five years later, the patient had no clinical signs of pseudotumour, and annual MR imaging examinations had been negative. Tumour size and location matter, so it was technically challenging to remove it, as it was in close relation to the iliac and the femoral vessels. Retroperitoneum compromise is not often; Bosker et al. [9] described two cases where the pseudotumour extends into the abdominal space along the iliopsoas muscle. We believe that it is essential to perform surgery by a

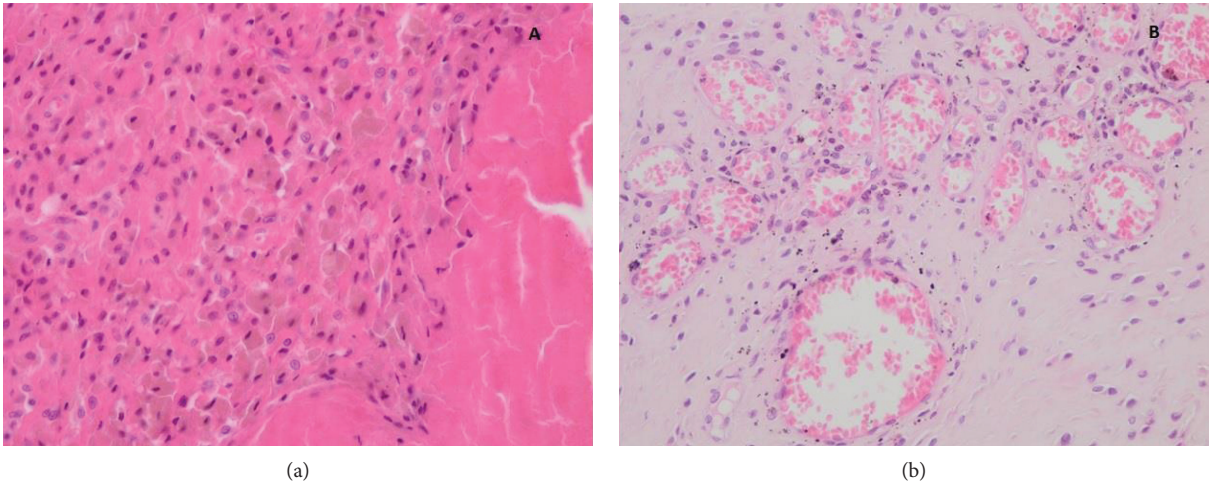


FIGURE 7: Histologic view of the soft tissue mass. (a) (40x) Hematoxylin and eosin (HE) shows an infiltrate of the macrophages with brown contents and detritus inside, near a necrotic area. (b) (100x) HE shows black particulates from the prosthetic material in a reparative tissue with fibroblast and neof ormation of blood vessels.

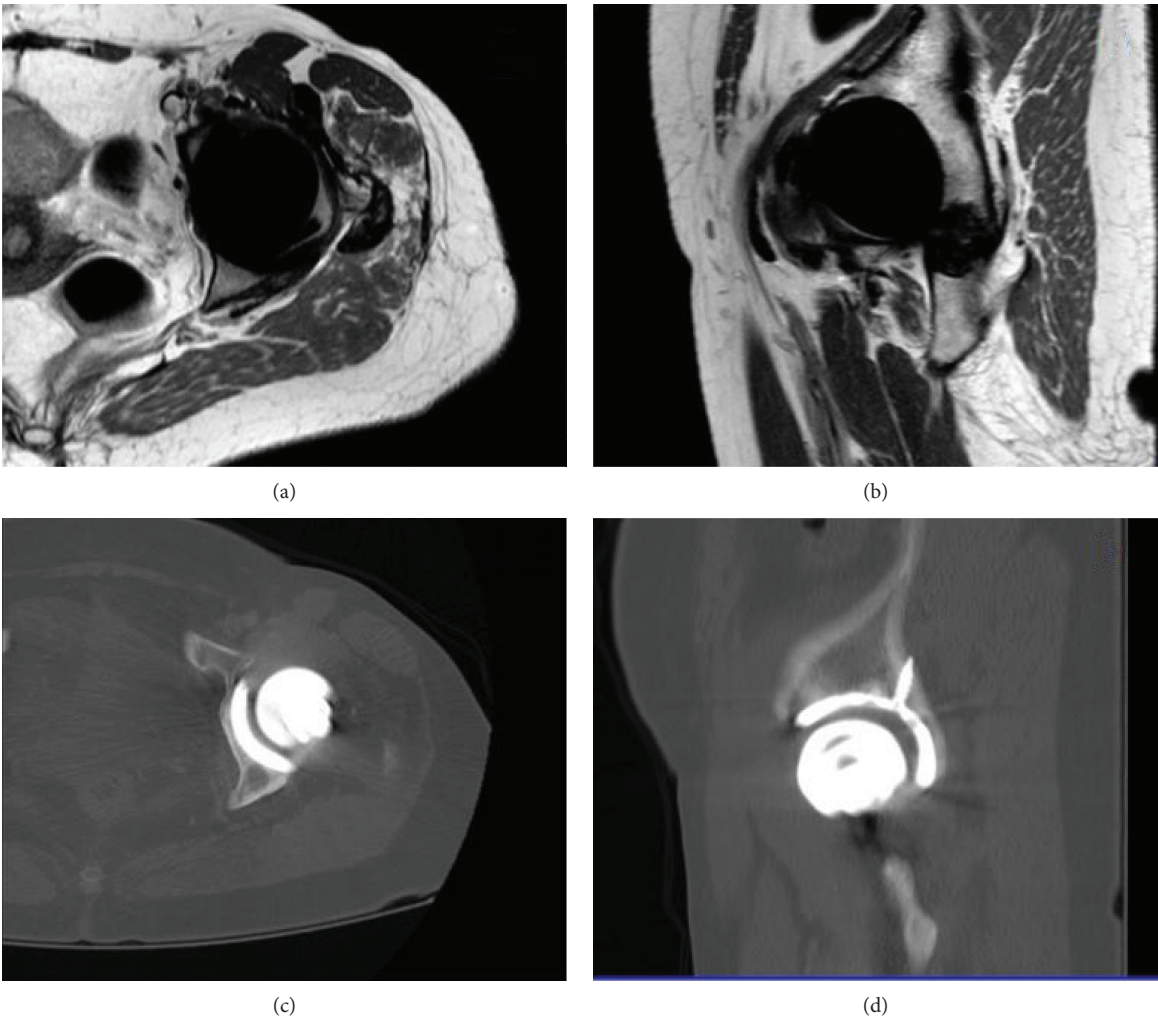


FIGURE 8: MRI (a) and (b) and CT (c) and (d) images taken five years post-RHA. There were no signs of pseudotumour after an extended follow-up.

multidisciplinary team and complete resection of the pseudotumour [37]. A vascular surgeon was prepared if needed in our case, and the first step was performed by a surgeon, which was more familiar with the retroperitoneum approach.

Regarding RHA, a bone defect caused by the pseudotumour is an issue. In this case, fortunately, it was resolved by standard components, and it was not necessary to use complex revision arthroplasty components that add morbidity to the surgery. However, we consider that performing a RHA is not easy or risk exempt. In a study that compares the result of 53 revisions of different implants of Birmingham® hip resurfacing, the author concluded that the incidence of major complications after RHAs for pseudotumour (50%) was significantly higher than that of after RHAs for other causes (14%). The authors concluded that the outcome of revision for pseudotumour (16 cases) is poor, so consideration should be given to an early RHA before the tumour grows and a significant bone defect is present [10].

#### 4. Conclusions

This case represents a rare but devastating complication related to metal-bearing surface arthroplasty, particularly to HRA. Currently, the evidence shows that the incidence of pseudotumours and the rate of revision for pseudotumours are higher than initially reported. So, the indication of a metal-bearing surface is questionable given the higher rate of early RHA compared to other bearing surfaces such as polyethylene or ceramic. The most remarkable of this case is that after complete pseudotumour resection and RHA, at five years of follow up, the patient achieved a complete range of motion, no pain, no limp, and no sign of recurrence in MRI. We encourage that for such cases, MRI for diagnosis should be performed, arthrocentesis to rule out infection, and complete resection of the pseudotumour and hip revision for treatment led by a multidisciplinary team. Also, we are in favour of not using the metal-bearing surface as the first option [38].

#### Conflicts of Interest

The authors declare no conflict of interest.

#### Acknowledgments

We thank the invaluable collaboration of Facundo Las Heras, MD, for his histopathological analysis of this and other related cases. He is a pathologist at our centre dedicated to musculoskeletal pathology and a professor at the University of Chile. Also, we would like to thank Jorge Diaz, MD, for his collaboration in the interpretation of CT and MRI images. Dr. Diaz is the chief of the musculoskeletal unit in the radiology department at the Hospital Clinico Universidad de Chile.

#### References

[1] I. D. Learmonth, C. Young, and C. Rorabeck, "The operation of the century: total hip replacement," *The Lancet*, vol. 370, no. 9597, pp. 1508–1519, 2007.

[2] J. Daniel, P. Pynsent, and D. McMinn, "Metal-on-metal resurfacing of the hip in patients under the age of 55 years with osteoarthritis," *The Journal of Bone and Joint Surgery. British volume*, vol. 86-B, no. 2, pp. 177–184, 2004.

[3] A. Shimmin, P. E. Beaulé, and P. Campbell, "Metal-on-metal hip resurfacing arthroplasty," *The Journal of Bone and Joint Surgery. American Volume*, vol. 90, no. 3, pp. 637–654, 2008.

[4] C. Delaunay, I. Petit, I. D. Learmonth, P. Oger, and P. A. Vendittoli, "Metal-on-metal bearings total hip arthroplasty: the cobalt and chromium ions release concern," *Orthopaedics & Traumatology, Surgery & Research*, vol. 96, no. 8, pp. 894–904, 2010.

[5] P. F. Lachiewicz, L. T. Kleeman, and T. Seyler, "Bearing surfaces for total hip arthroplasty," *The Journal of the American Academy of Orthopaedic Surgeons*, vol. 26, no. 2, pp. 45–57, 2018.

[6] H. G. Willert, G. H. Buchhorn, A. Fayyazi et al., "Metal-on-metal bearings and hypersensitivity in patients with artificial hip joints: A clinical and histomorphological study," *The Journal of Bone & Joint Surgery*, vol. 87, no. 1, pp. 28–36, 2005.

[7] P. Campbell, E. Ebramzadeh, S. Nelson, K. Takamura, K. De Smet, and H. C. Amstutz, "Histological features of pseudotumor-like tissues from metal-on-metal hips," *Clinical Orthopaedics and Related Research*, vol. 468, no. 9, pp. 2321–2327, 2010.

[8] H. Pandit, S. Glyn-Jones, P. McLardy-Smith et al., "Pseudotumours associated with metal-on-metal hip resurfacings," *The Journal of Bone and Joint Surgery. British volume*, vol. 90-B, no. 7, pp. 847–851, 2008.

[9] B. H. Bosker, H. B. Ettema, M. van Rossum et al., "Pseudotumor formation and serum ions after large head metal-on-metal stemmed total hip replacement. Risk factors, time course and revisions in 706 hips," *Archives of Orthopaedic and Trauma Surgery*, vol. 135, no. 3, pp. 417–425, 2015.

[10] G. Grammatopoulos, H. Pandit, Y.-M. Kwon et al., "Hip resurfacings revised for inflammatory pseudotumour have a poor outcome," *The Journal of Bone and Joint Surgery. British volume*, vol. 91-B, no. 8, pp. 1019–1024, 2009.

[11] D. Fu, W. Sun, J. Shen, X. Ma, Z. Cai, and Y. Hua, "Inflammatory pseudotumor around metal-on-polyethylene total hip arthroplasty in patients with ankylosing spondylitis: description of two cases and review of literature," *World Journal of Surgical Oncology*, vol. 13, no. 1, p. 57, 2015.

[12] B. Bosker, H. Ettema, M. Boomsma, B. Kollen, M. Maas, and C. Verheyen, "High incidence of pseudotumour formation after large-diameter metal-on-metal total hip replacement," *The Journal of Bone and Joint Surgery. British Volume*, vol. 94-B, no. 6, pp. 755–761, 2012.

[13] R. Bisschop, M. F. Boomsma, J. J. Van Raay, A. T. Tiebosch, M. Maas, and C. L. Gerritsma, "High prevalence of pseudotumors in patients with a Birmingham hip resurfacing prosthesis: a prospective cohort study of one hundred and twenty-nine patients," *The Journal of Bone & Joint Surgery*, vol. 95, no. 17, pp. 1554–1560, 2013.

[14] G. Grammatopoulos, H. Pandit, A. Kamali et al., "The correlation of wear with histological features after failed hip resurfacing arthroplasty," *The Journal of Bone & Joint Surgery*, vol. 95, no. 12, article e81, 2013.

[15] R. A. Brand and J. L. Marsh, "Particulate debris osteolysis simulating malignant tumor," *The Iowa Orthopaedic Journal*, vol. 24, p. 111, 2004.



- [16] C. Jeanrot, M. Ouaknine, P. Anract, M. Forest, and B. Tomeno, "Massive pelvic and femoral pseudotumoral osteolysis secondary to an uncemented total hip arthroplasty," *International Orthopaedics*, vol. 23, no. 1, pp. 37–40, 1999.
- [17] H. Wynn-Jones, R. Macnair, J. Wimhurst et al., "Silent soft tissue pathology is common with a modern metal-on-metal hip arthroplasty," *Acta Orthopaedica*, vol. 82, no. 3, pp. 301–307, 2011.
- [18] O. Lainiala, P. Elo, A. Reito, J. Pajamaki, T. Puolakka, and A. Eskelinen, "Comparison of extracapsular pseudotumors seen in magnetic resonance imaging and in revision surgery of 167 failed metal-on-metal hip replacements," *Acta Orthopaedica*, vol. 85, no. 5, pp. 474–479, 2014.
- [19] F. Hannemann, A. Hartmann, J. Schmitt et al., "European multidisciplinary consensus statement on the use and monitoring of metal-on-metal bearings for total hip replacement and hip resurfacing," *Orthopaedics & Traumatology: Surgery & Research.*, vol. 99, no. 3, pp. 263–271, 2013.
- [20] E. Robinson, J. Henckel, S. Sabah, K. Satchithananda, J. Skinner, and A. Hart, "Cross-sectional imaging of metal-on-metal hip arthroplasties: can we substitute MARS MRI with CT?," *Acta orthopaedica.*, vol. 85, no. 6, pp. 577–584, 2014.
- [21] M. M. Mikhael, A. D. Hanssen, and R. J. Sierra, "Failure of metal-on-metal total hip arthroplasty mimicking hip infection: a report of two cases," *The Journal of Bone & Joint Surgery*, vol. 91, no. 2, pp. 443–446, 2009.
- [22] V. Krenn, L. Morawietz, G. Perino et al., "Revised histopathological consensus classification of joint implant related pathology," *Pathology, Research and Practice*, vol. 210, no. 12, pp. 779–786, 2014.
- [23] D. Langton, T. Joyce, S. Jameson et al., "Adverse reaction to metal debris following hip resurfacing," *The Journal of Bone and Joint Surgery. British volume*, vol. 93, no. 2, pp. 164–171, 2011.
- [24] R. Sidaginamale, T. Joyce, J. Lord et al., "Blood metal ion testing is an effective screening tool to identify poorly performing metal-on-metal bearing surfaces," *Bone & Joint Research*, vol. 2, no. 5, pp. 84–95, 2013.
- [25] J. R. Berstock, R. P. Baker, G. C. Bannister, and C. P. Case, "Histology of failed metal-on-metal hip arthroplasty; three distinct sub-types," *Hip International*, vol. 24, no. 3, pp. 243–248, 2014.
- [26] A. K. Matthies, J. A. Skinner, H. Osmani, J. Henckel, and A. J. Hart, "Pseudotumors are common in well-positioned low-wearing metal-on-metal hips," *Clinical Orthopaedics and Related Research*, vol. 470, no. 7, pp. 1895–1906, 2012.
- [27] T. S. Watters, D. M. Cardona, K. S. Menon, E. N. Vinson, M. P. Bolognesi, and L. G. Dodd, "Aseptic lymphocyte-dominated vasculitis-associated lesion: a clinicopathologic review of an underrecognized cause of prosthetic failure," *American Journal of Clinical Pathology*, vol. 134, no. 6, pp. 886–893, 2010.
- [28] P. Bisseling, T. Tan, Z. Lu, P. A. Campbell, and J. L. Susante, "The absence of a metal-on-metal bearing does not preclude the formation of a destructive pseudotumor in the hip—a case report," *Acta Orthopaedica*, vol. 84, no. 4, pp. 437–441, 2013.
- [29] A. J. Hart, A. Matthies, J. Henckel, K. Ilo, J. Skinner, and P. C. Noble, "Understanding why metal-on-metal hip arthroplasties fail: a comparison between patients with well-functioning and revised Birmingham hip resurfacing arthroplasties. AAOS exhibit selection," *The Journal of Bone and Joint Surgery. American Volume*, vol. 94, no. 4, article e22, 2012.
- [30] J. W. Griffin, M. D'Apuzzo, and J. A. Browne, "Management of failed metal-on-metal total hip arthroplasty," *World Journal of Orthopedics*, vol. 3, no. 6, pp. 70–74, 2012.
- [31] B. Ollivere, S. Duckett, A. August, and M. Porteous, "The Birmingham hip resurfacing: 5-year clinical and radiographic results from a district general hospital," *International Orthopaedics*, vol. 34, no. 5, pp. 631–634, 2010.
- [32] O. Lainiala, A. Reito, P. Elo, J. Pajamaki, T. Puolakka, and A. Eskelinen, "Revision of metal-on-metal hip prostheses results in marked reduction of blood cobalt and chromium ion concentrations," *Clinical Orthopaedics and Related Research*, vol. 473, no. 7, pp. 2305–2313, 2015.
- [33] R. A. Clayton, I. Beggs, D. M. Salter, M. H. Grant, J. T. Patton, and D. E. Porter, "Inflammatory pseudotumor associated with femoral nerve palsy following metal-on-metal resurfacing of the hip," *The Journal of Bone and Joint Surgery-American Volume*, vol. 90, no. 9, pp. 1988–1993, 2008.
- [34] T. von Schewelov and L. Sanzen, "Catastrophic failure due to aggressive metallosis 4 years after hip resurfacing in a woman in her forties—a case report," *Acta Orthopaedica*, vol. 81, no. 3, pp. 402–404, 2010.
- [35] D. Boardman, F. Middleton, and T. Kavanagh, "A benign psoas mass following metal-on-metal resurfacing of the hip," *The Journal of Bone and Joint Surgery. British volume*, vol. 88-B, no. 3, pp. 402–404, 2006.
- [36] A. Rajpura, M. L. Porter, A. K. Gambhir, A. J. Freemont, and T. N. Board, "Clinical experience of revision of metal on metal hip arthroplasty for aseptic lymphocyte dominated vasculitis associated lesions (ALVAL)," *Hip International*, vol. 21, no. 1, pp. 43–51, 2011.
- [37] R. Berber, Y. Pappas, M. Khoo et al., "A new approach to managing patients with problematic metal hip implants: the use of an internet-enhanced multidisciplinary team meeting," *The Journal of Bone and Joint Surgery*, vol. 97, no. 4, article e20, 2015.
- [38] C. A. Engh Jr., H. Ho, and C. A. Engh, "Metal-on-metal hip arthroplasty: does early clinical outcome justify the chance of an adverse local tissue reaction?," *Clinical Orthopaedics and Related Research*, vol. 468, no. 2, pp. 406–412, 2010.