



## Case report

## Lateral hypertrophic cardiomyopathy: A case report

Emanuela Belmonte<sup>a</sup>, Luca Arcari<sup>a,b,\*</sup>, Giovanni Camastra<sup>a</sup>, Federica Ciolina<sup>c</sup>,  
Massimiliano Danti<sup>c</sup>, Stefano Sbarbati<sup>c</sup>, Salvatore Donato Musarò<sup>a</sup>, Luca Cacciotti<sup>a</sup>

<sup>a</sup> Cardiology Unit, Madre Giuseppina Vannini Hospital, Rome, Italy

<sup>b</sup> Department of Clinical, Internal, Anesthesiology and Cardiovascular Sciences, Sapienza University of Rome, Italy

<sup>c</sup> Radiology Unit, Madre Giuseppina Vannini Hospital, Rome, Italy

## ARTICLE INFO

## Keywords:

Lateral hypertrophic cardiomyopathy

Echocardiography

Cardiac magnetic resonance imaging

T1 mapping

Case report

## ABSTRACT

Hypertrophic cardiomyopathy (HCM) is the most common genetic cardiovascular disorder, more often presenting with asymmetrical septal hypertrophy. Here we report the case of a patient, affected by arterial hypertension, presenting to the emergency department with chest pain, electrocardiographic changes and troponin rise. Further diagnostic work-up ruled out ischemic heart disease and lead to the diagnosis of a rare HCM phenotype affecting the lateral wall of the left ventricle. Cardiac magnetic resonance imaging proved to be a reliable diagnostic test in this case thanks to its tissue characterization ability, allowing the identification of diffuse fibrosis through native T1 mapping, edema through T2 mapping and replacement fibrosis with late gadolinium enhancement, providing us with robust diagnostic and prognostic information. The association of arterial hypertension with atypical HCM forms emerged from multicentric studies, however, further research is needed to fully clarify the complex interactions between arterial hypertension and phenotypic expression of HCM.

## 1. Introduction

Hypertrophic cardiomyopathy (HCM) is the most common genetic heart disease, whose phenotypic expression, when apparent, presents as myocardial hypertrophy, often asymmetric and with a typical involvement of the interventricular septum (IVS) [1]. Microscopically, hypertrophy, hyperplasia, disarray, and loss of myocytes with development of fibrosis are observed [1]. However, the clinical and instrumental presentation of HCM remains extremely variable, ranging from individuals with a genetic mutation and no expressed phenotype to classic cases of septal hypertrophy, or even atypical apical and focal forms that can make the diagnosis challenging [2]. It is estimated that only a fraction of affected individuals actually receives a diagnosis HCM, this mostly happening through imaging techniques [1]. Here, we report a clinical case of a patient with an atypical form of HCM in which cardiac magnetic resonance (CMR) imaging provided important diagnostic and prognostic information.

## 2. Case report

A 45-year-old Bangladeshi man, height 170 cm, weight 70 kg, presented to our emergency department with oppressive chest pain that had started about 2 h prior. Blood pressure was 160/100 mmHg, heart rate 88 bpm, oxygen saturation 98 %. The patient did not

\* Corresponding author. Cardiology Unit, Madre Giuseppina Vannini Hospital, Rome, Italy.

E-mail address: [luca.arcari@uniroma1.it](mailto:luca.arcari@uniroma1.it) (L. Arcari).

<https://doi.org/10.1016/j.heliyon.2024.e38919>

Received 16 May 2024; Received in revised form 28 September 2024; Accepted 2 October 2024

Available online 19 October 2024

2405-8440/© 2024 Published by Elsevier Ltd.

<http://creativecommons.org/licenses/by-nc-nd/4.0/>.

This is an open access article under the CC BY-NC-ND license

refer history of cardiovascular events, syncope, or arrhythmic palpitations. He reported not being on any drug treatment and his family history was negative for cardiovascular events. The electrocardiogram (ECG) (Fig. 1) showed sinus rhythm at 60 bpm, normal atrioventricular and intraventricular conduction, repolarization abnormalities with negative and deep T-waves in the inferolateral region. Blood tests were within normal ranges (Hb 15 g/dl, NT-pro-BNP 74 pg/ml, AST 22 U/l; ALT 14 U/l) save for a slight increase of Troponin values at 22 ng/l and 27 ng/l on the second determination (normal values < 14 ng/l). Transthoracic echocardiogram (Fig. 2A, Video 1 and 2) revealed concentric hypertrophy of the left ventricle with marked hypertrophy in the anterior and lateral walls (maximum thickness detected in parasternal short-axis: 20 mm), apically displaced papillary muscle and preserved systolic function (left ventricular ejection fraction 68 %) without signs of increased filling pressures (nondilated left atrium, trans-tricuspid gradient <2.8 m/sec, E/e' 7); the mitral valve appeared redundant with systolic anterior motion (SAM) of the mitral leaflets, causing left ventricular outflow obstruction only during the Valsalva maneuver (peak gradient 35 mmHg) and associated with mild valvular regurgitation; no aortic stenosis was detected. Due to the clinical presentation characterized by a high risk for ischemic heart disease, related to the patient's risk factors and ethnicity, a coronary angiography was performed revealing patent coronary arteries. In the suspicion of an underlying cardiomyopathy, CMR with a Siemens Aera 1.5 T scanner was performed using a standardized protocol previously described in detail [3]. Briefly, this included the acquisition of long- and short-axis cine imaging, T2-STIR imaging, T1 mapping (MOLLI scheme 5(3)3, normal values < 1010 msec) and T2 mapping with a T2-prepared steady-state free precession pulse sequence (normal values < 50 msec); 10 minutes after contrast media administration (0,1 mmol/Kg body weight of gadoteric acid (Clariscyclic, GE)), an inversion recovery T1-weighted gradient echo acquisition was used for late gadolinium enhancement (LGE) imaging, acquiring a set of gapless short axis covering the entire ventricles, along with a 2- 3- and 4- chamber view; finally, post-contrast T1 mapping images were acquired using the same parameters as for native T1. The CMR examination confirmed the concentric left ventricular hypertrophy (LV end diastolic volume index; 74,4 ml/m<sup>2</sup>; LV end systolic volume: 25,6 ml/m<sup>2</sup>; LVEF 66 %; LV mass index 143,4 g/m<sup>2</sup>) predominantly affecting the LV lateral wall (thickness: 18 mm vs 12 mm at IVS level) (Fig. 2B, Video 3 and 4), with concomitant apical hypertrophy (thickness: 14 mm). SAM at rest was not observed. Native T1 (Fig. 3A) and T2 mapping (Fig. 3B) showed an increased signal within areas of larger hypertrophy (native T1 lateral wall: 1080 msec vs. 1004 msec of the IVS; T2 lateral wall: 53 msec vs. 47 msec of the IVS), like T2-STIR sequences (Fig. 3C). LGE images acquired 15 minutes after contrast administration showed a subtle and non-extensive (<10 %) non-ischemic intramyocardial enhancement in the lateral wall at the same level (Fig. 3D). Regional analysis of native T1 mapping did not show any area of reduced values suggesting Fabry disease. The CMR findings were consistent with an asymmetric HCM of the lateral wall, with mild myocardial edema and fibrosis in areas of larger hypertrophy. No relevant arrhythmias were detected at the ECG monitoring during in-hospital stay. The patient's treatment at discharge included an ACE inhibitor, aldosterone antagonist, beta-blocker, statin. An implantable cardioverter-defibrillator (ICD) was not considered given the low risk for sudden cardiac death (SCD) according to the HCM risk-score [4]. Six months later, the patient, who is in good general clinical condition, asymptomatic and with well-controlled blood pressure values under pharmacological treatment, continues outpatient follow-up at our hospital. Genetic testing was proposed but refused by the patient.

### 3. Discussion

We described the case of a patient with a rare form of predominantly lateral HCM, whose clinical presentation was chest pain.

When admitted to the emergency department, ECG abnormalities and a minimal troponin increase were detected. Although at this time point the bedside echocardiogram already raised suspicion of an underlying cardiomyopathy, it was deemed appropriate to exclude the presence of an acute coronary syndrome. Indeed, while chest pain is a common symptom associated with HCM [1], and a modest increase in troponin is also consistent with the disease [5], the age, sex, and geographic origin of the patient [6] led us to perform a coronary angiography, which subsequently yielded negative results. Though HCM was initially considered a disease free of coronary artery disease (CAD), it is now established that this can coexist with the underlying cardiomyopathy, contributing to worsen its prognosis [5]. Hence, it remains of relevance to exclude CAD in these patients, whenever the clinical presentation is consistent.

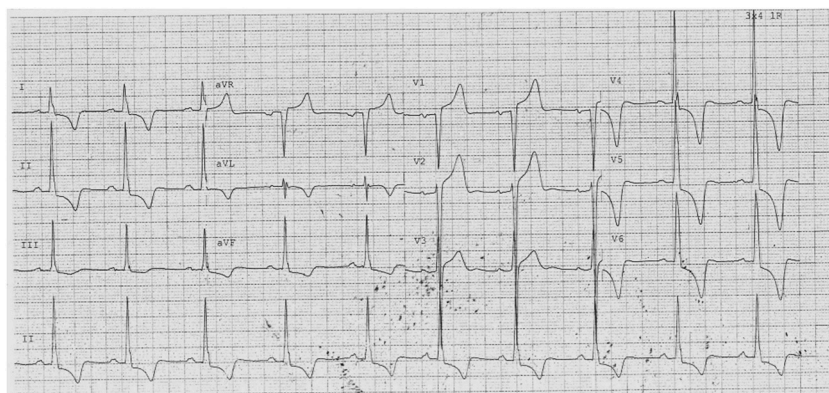
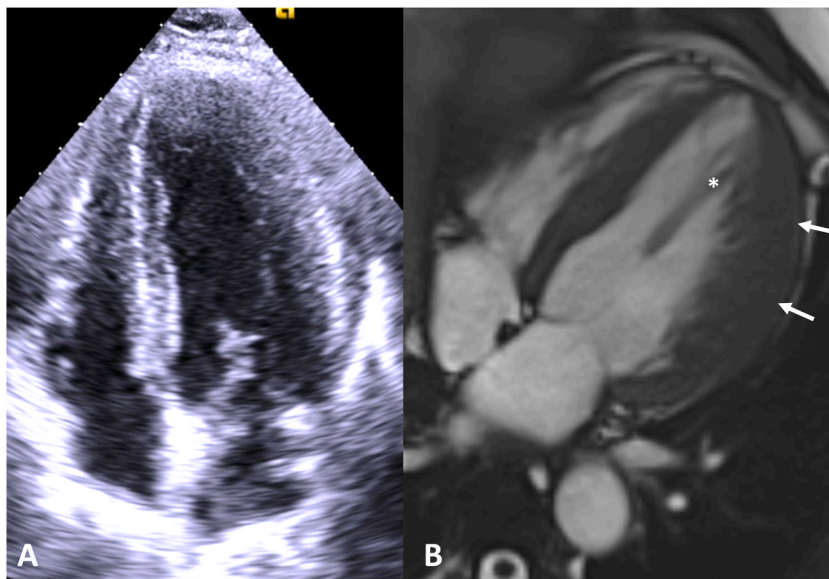
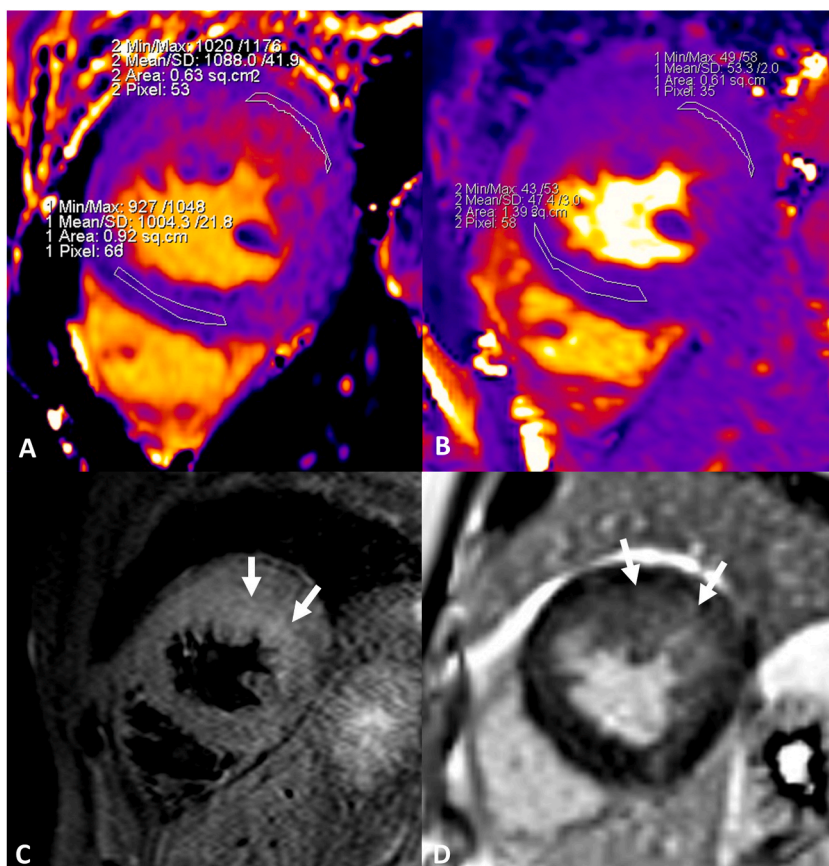


Fig. 1. 12-leads ECG showing sign of left ventricular hypertrophy and repolarization abnormalities (deep T-wave inversion).



**Fig. 2.** images from echocardiography, 4-chamber (panel A) and cardiac magnetic resonance cine imaging, 4-chamber (panel B) both taken in tele-diastole, showing hypertrophy of the lateral left ventricular wall. Presence of apically displaced papillary muscle (asterisk in panel B).



**Fig. 3.** cardiac magnetic resonance imaging at mid-short-axis level of the left ventricle (LV), showing increased native T1 of the lateral wall (panel A) as well as increased T2 in the same location (panel B) associated with increased signal intensity in T2-STIR imaging (arrows in panel C) and slight hyperintensity in the post contrast late gadolinium enhancement sequence (arrows in panel D); these findings are consistent with mild edema and non-ischemic fibrosis of the most hypertrophied LV areas.

Based on the age at presentation, clinical history not consistent with athlete's heart, electrocardiogram (repolarization abnormalities with marked T-wave inversion), echocardiographic findings (asymmetric hypertrophy of the left ventricle, albeit with atypical involvement), and the absence of systemic involvement suggestive of other forms of cardiomyopathy (including, in example, Leopard syndrome, Danon disease, Friedrich ataxia and mitochondrial cardiomyopathy), a CMR was performed with a clinical suspicion of HCM [7]. Compared to echocardiography, this technique has the advantage of providing highly accurate measurements of cardiac morphology and systolic function, as well as a histologically validated assessment of myocardial fibrosis [8] and edema [9]. In our patient, CMR findings of asymmetric hypertrophy of the left ventricular lateral wall, non-ischemic replacement fibrosis, increased native T1 and T2 mapping values were interpreted to be explained not solely by the presence of hypertension, but with an underlying HCM. The tissue mapping characterization, including globally elevated native T1 values and increase T2 mapping signifying edema in areas with LGE aided the differentiation against other forms of cardiomyopathy [10,11]. The isolated and prevalent lateral wall involvement characterizes a rare (approximately 1 %) but previously described subgroup both in echocardiographic [12] and CMR [13] studies. The coexistence of arterial hypertension with an atypical phenotypic expression of HCM has emerged from the results of large multicenter studies [14]; furthermore, it has been reported that the presence of arterial hypertension in patients with HCM is associated with a negative family history for sudden death and a higher prevalence of apical forms of hypertrophy [15]. Hypertension in HCM seems to be associated with an adverse clinical profile albeit without conveying significant changes in mortality rates. However, currently there is a lack of solid data fully clarifying the interaction between arterial hypertension and the phenotypic expression of HCM [16,17].

Finally, in terms of prognostic stratification of our patient, CMR provided several relevant information, specifically pertaining tissue characterization. Indeed, the presence of subtle myocardial edema (increased T2 mapping [11]) and diffuse fibrosis (increased native T1 mapping [18]) in the most hypertrophied areas supported the diagnosis of HCM [19], while the limited extension of the LGE, a negative prognostic factor when it should exceed 10 % of ventricular volume [20], confirmed the low risk of sudden death. Serial CMR examinations are to be planned in the follow-up to quickly identify any progression of the disease [21].

In conclusion, we reported the case of a patient presenting to the emergency department with a suspected acute coronary syndrome and instead found to be affected by a rare form of lateral HCM. CMR provided pivotal information to confirm the diagnosis and optimize the risk stratification. Further studies are needed to identify the complex interactions between arterial hypertension and the phenotypic manifestation of HCM.

**Ethics statement:** the study complied with the Declaration of Helsinki. Written informed consent was provided when appropriate.

#### Data availability statement

Data will be made available on request.

#### CRediT authorship contribution statement

**Emanuela Belmonte:** Writing – review & editing, Writing – original draft, Methodology, Investigation, Formal analysis, Data curation, Conceptualization. **Luca Arcari:** Writing – review & editing, Writing – original draft, Visualization, Methodology, Investigation, Data curation, Conceptualization. **Giovanni Camastra:** Writing – review & editing, Investigation. **Federica Ciolina:** Writing – review & editing, Investigation. **Massimiliano Danti:** Writing – review & editing, Methodology, Investigation, Conceptualization. **Stefano Sbarbati:** Writing – review & editing, Supervision. **Salvatore Donato Musarò:** Writing – review & editing, Supervision. **Luca Cacciotti:** Writing – review & editing, Supervision, Investigation.

#### Declaration of competing interest

The authors declare that they have no known competing financial interests or personal relationships that could have appeared to influence the work reported in this paper.

#### Acknowledgements

none.

#### Appendix A. Supplementary data

Supplementary data to this article can be found online at <https://doi.org/10.1016/j.heliyon.2024.e38919>.

#### References

- [1] S.J. Pascoe, Clinical course and management of hypertrophic cardiomyopathy, *N. Engl. J. Med.* 379 (2018) 1976–1977, <https://doi.org/10.1056/NEJMc1812159>.



- [2] M.S. Maron, Clinical utility of cardiovascular magnetic resonance in hypertrophic cardiomyopathy, *J. Cardiovasc. Magn. Reson.* 14 (2012) 1–21, <https://doi.org/10.1186/1532-429X-14-13/FIGURES/9>.
- [3] L. Arcari, G. Camastra, F. Ciolina, L.R. Limite, M. Danti, M. Sclafani, G. Ansalone, M.B. Musumeci, E. Nagel, V. Puntmann, S. Sbarbati, L. Cacciotti, Myocardial oedema contributes to interstitial expansion and associates with mechanical and electrocardiographic changes in takotsubo syndrome: a CMR T1 and T2 mapping study, *Eur. Hear. J. - Cardiovasc. Imaging.* (2023), <https://doi.org/10.1093/EHJCI/JEAD035>.
- [4] S.R. Ommen, S. Mital, M.A. Burke, S.M. Day, A. Deswal, P. Elliott, L.L. Evanovich, J. Hung, J.A. Joglar, P. Kantor, C. Kimmelstiel, M. Kittleson, M.S. Link, M. S. Maron, M.W. Martinez, C.Y. Miyake, H.V. Schaff, C.O. Semsarian, P. Sorajja, AHA/ACC guideline for the diagnosis and treatment of patients with hypertrophic cardiomyopathy: executive summary: a report of the American college of cardiology/American heart association joint committee on clinical practice guidelines, *J. Am. Coll. Cardiol.* 76 (2020) 3022–3055, <https://doi.org/10.1016/J.JACC.2020.08.044>, 2020.
- [5] H. Liao, H.C. Tan, Z. Wang, X. Chen, Y. He, S. He, Combined evaluation of coronary artery disease and high-sensitivity cardiac troponin T for prediction of adverse events in patients with hypertrophic cardiomyopathy, *BMC Cardiovasc. Disord.* 21 (2021), <https://doi.org/10.1186/S12872-021-02135-X>.
- [6] A.A.M. Hanif, M. Hasan, S.A. Khan, M. Hossain, A.A. Shamim, M. Hossaine, M.A. Ullah, S.K. Sarker, S.M.M. Rahman, M.M.I. Bulbul, D.K. Mitra, M.K. Mridha, Ten-years cardiovascular risk among Bangladeshi population using non-laboratory-based risk chart of the World Health Organization: findings from a nationally representative survey, *PLoS One* 16 (2021), <https://doi.org/10.1371/JOURNAL.PONE.0251967>.
- [7] E. Arbelo, A. Protonotarios, J.R. Gimeno, E. Arbustini, R. Barriales-Villa, C. Basso, C.R. Bezzina, E. Biagini, N.A. Blom, R.A. de Boer, T. De Winter, P.M. Elliott, M. Flather, P. Garcia-Pavia, K.H. Haugaa, J. Ingles, R.O. Jurtut, S. Klaassen, G. Limongelli, B. Loeys, J. Mogensen, I. Olivetto, A. Pantazis, S. Sharma, J.P. Van Tintelen, J.S. Ware, J.P. Kaski, P. Charron, M. Imazio, M. Abdelhamid, V. Aboyans, M. Arad, F.W. Asselbergs, R. Asteggiano, Z. Bilinska, D. Bonnet, H. Bundgaard, N.M. Cardim, J. Čelutkienė, M. Cikes, G.M. De Ferrari, V. Dusi, V. Falk, L. Fauchier, E. Gandjbakhch, T. Heliö, K. Koskinas, D. Kotecha, U. Landmesser, G. Lazaros, B.S. Lewis, A. Linhart, M.-L. Løchen, B. Meder, R. Mindham, J. Moon, J.C. Nielsen, S. Petersen, E. Prescott, M.N. Sheppard, G. Sinagra, M. Sitges, J. Tfelt-Hansen, R. Touyz, R. Veltrap, J. Veselka, K. Wahbi, A. Wilde, K. Zeppenfeld, B. Kichou, H. Sisakian, D. Scherr, B. Gerber, A. Džubur, M. Gospodinova, I. Planinc, H.H. Moustira, D. Zemánek, M.S.K. Jensen, A. Samir, K. Palm, T. Heliö, K. Wahbi, E. Schulze-Bahr, V. Haralambos, R. Sepp, B. Aðalsteinsdóttir, D. Ward, M. Blich, G. Sinagra, A. Poniku, O. Lunegova, A. Rudzitis, R. Kassab, J. Barysiene, S. Huijnen, T. Felice, E. Vataman, N. Pavlovic, N. Doghmi, F.W. Asselbergs, E.S. Kostovska, V.M. Almasa, E.K. Biernacka, D. Brito, M. Rosca, M. Zavatta, A. Ristic, E. Gonçalvesová, M. Sinkovec, V. Cañadas-Godoy, P.G. Platonov, A.M. Saguner, A.R. Al Saadi, I. Kammoun, A. Celik, E. Nesukay, T. Abdullaev, E. Prescott, S. James, E. Arbelo, C. Baigent, M. A. Borger, S. Bucciari, B. Ibanez, L. Køber, K.C. Koskinas, J.W. McEvoy, B. Mihaylova, R. Mindham, L. Neubeck, J.C. Nielsen, A. Pasquet, A. Rakisheva, B. Rocca, X. Rossello, I. Vaartjes, C. Vrints, A. Witkowski, K. Zeppenfeld, ESC Guidelines for the management of cardiomyopathies, *Eur. Heart J.* 44 (2023), <https://doi.org/10.1093/EURHEARTJ/EHAD194>, 2023.
- [8] N. Child, G. Suna, D. Dabir, M.-L. Yap, T. Rogers, M. Kathirgamanathan, E. Arroyo-Ucar, R. Hinojar, I. Mahmoud, C. Young, O. Wendler, M. Mayr, B. Sandhu, G. Morton, M. Muhly-Reinholz, S. Dimmeler, E. Nagel, V.O. Puntmann, Comparison of MOLLI, shMOLLI, and SASHA in discrimination between health and disease and relationship with histologically derived collagen volume fraction, *Eur. Heart J. Cardiovasc. Imaging.* 19 (2018) 768–776, <https://doi.org/10.1093/ehjci/jex309>.
- [9] R. Fernández-Jiménez, J. Sánchez-González, J. Aguero, M. del Trigo, C. Galán-Arriola, V. Fuster, B. Ibáñez, Fast T2 gradient-spin-echo (T2-GraSE) mapping for myocardial edema quantification: first in vivo validation in a porcine model of ischemia/reperfusion, *J. Cardiovasc. Magn. Reson.* 17 (2015) 1–9, <https://doi.org/10.1186/S12968-015-0199-9>, 2015.
- [10] P. Haaf, P. Garg, D.R. Messroghli, D.A. Broadbent, J.P. Greenwood, S. Plein, Cardiac T1 Mapping and Extracellular Volume (ECV) in clinical practice: a comprehensive review, *J. Cardiovasc. Magn. Reson.* 18 (2016) 1–12, <https://doi.org/10.1186/S12968-016-0308-4/FIGURES/6>.
- [11] Z. Xu, J. Wang, W. Cheng, K. Wan, W. Li, L. Pu, Y. Xu, J. Sun, Y. Han, Y. Chen, Incremental significance of myocardial oedema for prognosis in hypertrophic cardiomyopathy, *Eur. Hear. Journal. Cardiovasc. Imaging.* 24 (2023) 876–884, <https://doi.org/10.1093/EHJCI/JEAD065>.
- [12] B.J. Maron, J.S. Gottdiener, S.E. Epstein, Patterns and significance of distribution of left ventricular hypertrophy in hypertrophic cardiomyopathy. A wide angle, two dimensional echocardiographic study of 125 patients, *Am. J. Cardiol.* 48 (1981) 418–428, [https://doi.org/10.1016/0002-9149\(81\)90068-0](https://doi.org/10.1016/0002-9149(81)90068-0).
- [13] M.S. Maron, B.J. Maron, C. Harrigan, J. Burows, C.M. Gibson, I. Olivetto, L. Biller, J.R. Lesser, J.E. Udelson, W.J. Manning, E. Appelbaum, Hypertrophic cardiomyopathy phenotype revisited after 50 Years with cardiovascular magnetic resonance, *J. Am. Coll. Cardiol.* 54 (2009) 220–228, <https://doi.org/10.1016/J.JACC.2009.05.006>.
- [14] S. Neubauer, P. Kolm, C.Y. Ho, R.Y. Kwong, M.Y. Desai, S.F. Dolman, E. Appelbaum, P. Desvigne-Nickens, J.P. DiMarco, M.G. Friedrich, N. Geller, A.R. Harper, P. Jorolm, M. Jerosch-Herold, D.Y. Kim, M.S. Maron, J. Schulz-Menger, S.K. Piechnik, K. Thomson, C. Zhang, H. Watkins, W.S. Weintraub, C.M. Kramer, Distinct subgroups in hypertrophic cardiomyopathy in the NHLBI HCM registry, *J. Am. Coll. Cardiol.* 74 (2019) 2333–2345, <https://doi.org/10.1016/J.JACC.2019.08.1057>.
- [15] Q. Luo, J. Chen, T. Zhang, X. Tang, B. Yu, Retrospective analysis of clinical phenotype and prognosis of hypertrophic cardiomyopathy complicated with hypertension, *Sci. Rep.* 10 (2020), <https://doi.org/10.1038/S41598-019-57230-Z>.
- [16] Z. Wang, Y. Zheng, H. Ruan, L. Li, M. Zhang, L. Duan, S. He, The impact of hypertension on the prognosis of patients with hypertrophic cardiomyopathy: a single-center retrospective study, *PeerJ* 11 (2023), <https://doi.org/10.7717/PEERJ.14614>.
- [17] M. Arabadzian, S. Montgomery, M. Pleasure, B. Nicolas, M. Collins, M. Reuter, D. Massera, D. Shimbo, M.V. Sherrid, Clinical course of adults with co-occurring hypertrophic cardiomyopathy and hypertension: a scoping review, *Am. Hear. J. Plus Cardiol. Res. Pract.* 39 (2024) 100367, <https://doi.org/10.1016/J.AHJ.2024.100367>.
- [18] L. Arcari, R. Hinojar, J. Engel, T. Freiwald, S. Platschek, H. Zainal, H. Zhou, M. Vasquez, T. Keller, A. Rolf, H. Geiger, I. Hauser, T.J. Vogl, A.M. Zeiher, M. Volpe, E. Nagel, V.O. Puntmann, Native T1 and T2 provide distinctive signatures in hypertrophic cardiac conditions – comparison of uremic, hypertensive and hypertrophic cardiomyopathy, *Int. J. Cardiol.* 0 (2020), <https://doi.org/10.1016/j.ijcard.2020.03.002>.
- [19] G. Quarta, G.D. Aquaro, P. Pedrotti, G. Pontone, S. Dellegrottaglie, A. Iacovoni, P. Brambilla, S. Pradella, G. Todiore, F. Rigo, C. Bucciarelli-Ducci, G. Limongelli, A. Roghi, I. Olivetto, Cardiovascular magnetic resonance imaging in hypertrophic cardiomyopathy: the importance of clinical context, *Eur. Hear. Journal. Cardiovasc. Imaging.* 19 (2018) 601–610, <https://doi.org/10.1093/EHJCI/JEX323>.
- [20] R.H. Chan, B.J. Maron, I. Olivetto, M.J. Pencina, G.E. Assenza, T. Haas, J.R. Lesser, C. Gruner, A.M. Crean, H. Rakowski, J.E. Udelson, E. Rowin, M. Lombardi, F. Cecchi, B. Tomberli, P. Spirito, F. Formisano, E. Biagini, C. Rapezzi, C.N. De Cecco, C. Autore, E.F. Cook, S.N. Hong, C.M. Gibson, W.J. Manning, E. Appelbaum, M.S. Maron, Prognostic value of quantitative contrast-enhanced cardiovascular magnetic resonance for the evaluation of sudden death risk in patients with hypertrophic cardiomyopathy, *Circulation* 130 (2014) 484–495, <https://doi.org/10.1161/CIRCULATIONAHA.113.007094>.
- [21] M. Habib, A. Adler, K. Fardini, S. Hoss, K. Hanneman, E.J. Rowin, M.S. Maron, B.J. Maron, H. Rakowski, R.H. Chan, Progression of myocardial fibrosis in hypertrophic cardiomyopathy: a cardiac magnetic resonance study, *JACC, Cardiovasc. Imaging.* 14 (2021) 947–958, <https://doi.org/10.1016/J.JCMG.2020.09.037>.