

# Malignant solitary fibrous tumor of thoracic spine with distant metastases: Second reported case and review of the literature

## ABSTRACT

Solitary fibrous tumor (SFT) usually originates from the pleura because of abnormal proliferation of fibroblast cells. It is extremely rare for the tumor to originate from the spine. Here, we report the second case of malignant SFT of thoracic spine with distant metastases in a 35-years-old female.

**Key words:** Distant metastases; malignant; solitary fibrous tumor; thoracic spine.

## Introduction

Solitary fibrous tumor (SFT) is a rare neoplasm that was initially described in the visceral pleura and subsequently reported in extrapleural sites including the pericardium, peritoneum, mediastinum, lung, upper respiratory tract, thyroid, liver, testicle, nasal cavity, parotid, orbit, and meninges.<sup>[1]</sup> SFT development in the spine is an exceedingly rare event about which little is known. Aggressive forms with metastases account for <20% of cases.<sup>[2]</sup> We present a unique case of an intradural extramedullary malignant SFT having an extradural component with pulmonary metastases. To the best of our knowledge, this is the second case of malignant SFT spine with distant metastases reported in literature.<sup>[3]</sup>

## Case Report

A 35-year-old female, with no comorbidities, presented with a 1 year history of progressive backache that was followed by lower extremity weakness for 4 months. General examination was unremarkable. Neurological examination revealed paraparesis, hypertonia, increased deep tendon reflexes in the lower limbs, positive Babinski sign, sustained bilateral ankle clonus and a sensory level of D12 with impaired temperature and proprioceptive sensation. Spine tenderness was present in lower thoracic vertebrae with no other neurodeficit elicited. Other systemic examination was unremarkable.

Contrast-enhanced magnetic resonance imaging (MRI) of thoracolumbar spine revealed an intradural extramedullary mass (1.2 cm × 1.25 cm; which was predominantly hyperintense on T2 and hypointense on T1 images) compressing and displacing cord at D10–D11 level toward right side with extradural component (9.2 cm × 5.2 cm) extending into left neural foramen with widening at D10–D11 level. Multiple intralesional necrotic/cystic areas are seen [Figure 1a and b]. Contrast-enhanced computed tomography showed large well defined heterogeneously enhancing mass (9 cm × 8.2 cm × 6 cm) in left paravertebral region extending from D10 to D12 vertebrae. The mass was seen passing through D10–D12 neural foramina and causing its widening and extending into spinal canal causing rightward displacement of spinal cord [Figure 1c and d].

**RITUPARNA BISWAS, ANIRBAN HALDER<sup>1</sup>,  
PRASHANT P RAMTEKE<sup>2</sup>, RAMBHA PANDEY**

Department of Radiation Oncology, Dr. BRA IRCH, All India Institute of Medical Sciences, <sup>1</sup>Department of Radiation Oncology, VMMC and Safdarjung Hospital, <sup>2</sup>Department of Pathology, All India Institute of Medical Sciences, New Delhi, India

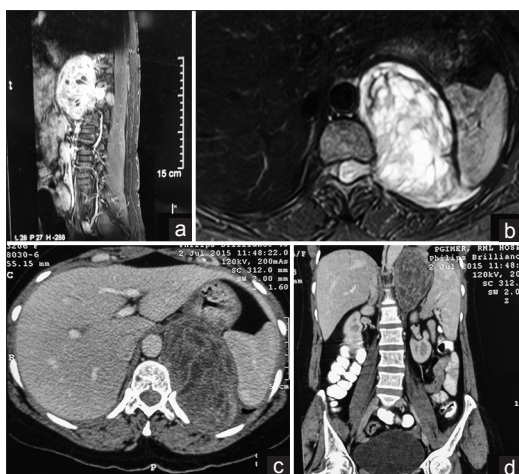**Address for correspondence:** Dr. Rambha Pandey, B3, Flat 3206, Vasant Kunj, New Delhi - 110 070, India. E-mail: rambha151@gmail.com

This is an open access article distributed under the terms of the Creative Commons Attribution-NonCommercial-ShareAlike 3.0 License, which allows others to remix, tweak, and build upon the work non-commercially, as long as the author is credited and the new creations are licensed under the identical terms.

For reprints contact: reprints@medknow.com

**How to cite this article:** Biswas R, Halder A, Ramteke PP, Pandey R. Malignant solitary fibrous tumor of thoracic spine with distant metastases: Second reported case and review of the literature. J Craniovert Jun Spine 2017;8:79-81.

Access this article online	
<b>Website:</b> www.jcvjs.com	<b>Quick Response Code</b> 
<b>DOI:</b> 10.4103/0974-8237.199868	

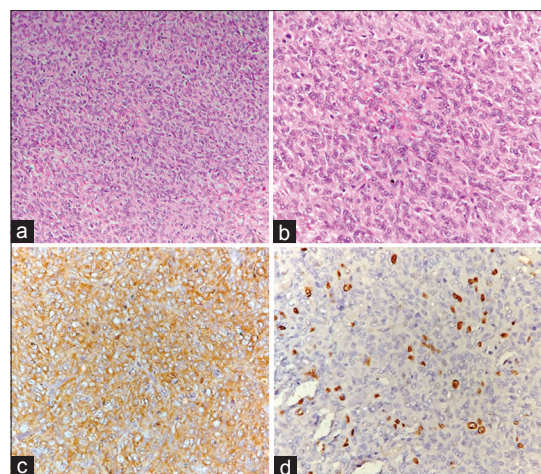


**Figure 1:** (a) Sagittal view and (b) axial view of T2 weighted magnetic resonance imaging spine showing intradural extramedullary mass with extradural component. (c) Axial view and (d) coronal view of contrast enhanced computed tomography scan showing left paravertebral mass

She underwent D10–D11 laminectomy with excision of intraspinal component of tumor by neurosurgeon from outside. Histopathology examination (HPE) features were suggestive of SFT [Figure 2a and b]. Mitotic activity was 6–8/10 HPF. The tumor cells were positive for CD34 (diffuse), CD99, EMA, Bcl2 and negative for CD31, S100, CD117, DOG1 on immunohistochemistry (IHC) [Figure 2c and d]. She was then referred to General Surgery Department of our institute where she was investigated for distant metastases which was negative, and then she underwent thoracotomy and excision of left paravertebral tumor. However, complete removal could not be done because of location. HPE and IHC revealed similar findings for SFT. Because of the incomplete surgical resection of the tumor and the high risk of locoregional and distant recurrence, adjuvant radiotherapy and chemotherapy was considered, but she went lost to follow-up for 5 months. When she turned up, an MRI whole spine and positron emission tomography (PET) scan was performed for assessment of extent of disease. MRI revealed a residual mass at the level of D11–D12 neural foramina on left side (1.5 cm × 1.2 cm × 1.5 cm) [Figure 3a and b] with mild fluorodeoxyglucose uptake and multiple subcentimetric nodular lesions in bilateral lungs suggestive of metastases on PET scan. She was administered palliative radiotherapy of 20 Gy in five fractions over 1 week to the primary residual site and planned for palliative chemotherapy with ifosfamide (1.4 g/m<sup>2</sup>; day 1–4) and epirubicin (60 mg/m<sup>2</sup>; day 1–2).

## Discussion

SFTs most often affect the pleura, but examples are increasingly being reported at other sites.<sup>[1]</sup> Spinal SFTs are usually intramedullary (58%) or intradural and extramedullary

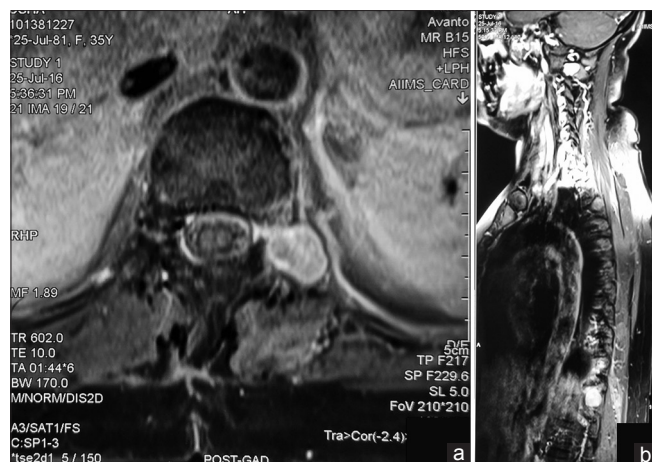


**Figure 2:** (a) Tumor is cellular and in diffuse growth pattern (H and E, ×100). (b) Tumor cells are round to oval with finely granular chromatin, indistinct cytoplasmic boundaries, and showing few mitosis (H and E, ×400). (c) CD34 is diffusely positive in tumor cells. (d) Ki-67 proliferation index is ~5-7%

(24%). The majority of symptoms with which patients were presenting at time of admission were pain, hypoesthesia, paresis, urinary dysfunction, or a combination of these.<sup>[2]</sup> Similarly, as in our case, the symptoms consisted of a backache, paraparesis, and loss of sensation in lower extremities. 56% of SFT patients are male, and most commonly it is seen on patients between 40 and 60 years old.<sup>[2]</sup>

Two-thirds of SFTs on MRI were isointense on T1-weighted imaging with the remainder being either heterogeneous or hypointense. Nearly, two-thirds of cases were hypointense on T2-weighted imaging with hyperintense being the next most common (17%). Over three-quarters of cases demonstrated diffuse or homogeneous contrast enhancement with gadolinium administration (78%); however, a significant portion demonstrated only partial or heterogeneous enhancement (21%).<sup>[2]</sup> The present case shows similar features to cases in the literature.

Typically, HPE features of SFTs are spindle cells embedded in a fibrous matrix in a patternless architecture and alternating hypercellular and hypocellular areas with perivascular hyalinization or myxoid degeneration. A hemangiopericytoma-like vascular pattern is usually present. Due to overlapping histologic features, differentiation of SFT from other soft tissue tumors may be difficult.<sup>[4]</sup> The performance of IHC staining is necessary to rule out other differential diagnoses. Typically, SFTs are positive for CD34, Bcl-2, and CD99 and negative for SMA, desmin, pan-cytokeratin, and S-100 protein on IHC. Findings such as nuclear atypia, increased cellularity, necrosis, and >4 mitoses/10 HPFs, are suggestive of the malignant potential of SFTs.<sup>[5]</sup> In the current case, light microscopic and IHC features were typical findings for malignant SFT rather than hemangiopericytoma.



**Figure 3: (a) Axial view and (b) Sagittal view of T2 weighted magnetic resonance imaging of spine showing residual tumor**

The majority of SFTs are benign, and the malignant form accounts for 9%–22%.<sup>[2]</sup> Based on previous case reports, malignant SFT showed rapid local recurrence and distant metastasis.<sup>[2,3]</sup>

At present, due to the rarity of the disease, standard therapies for malignant SFT have not been well established. Surgical *en bloc* removal has been recommended as the treatment of choice for SFT.<sup>[6]</sup> Recurrence occurred commonly in cases involving incomplete excision, possibly caused by the level of difficulty in achieving complete resection. In these cases, adjuvant chemotherapy or radiotherapy may play a role in the prevention of recurrence.<sup>[7]</sup> Stacchiotti *et al.* and Park *et al.* showed that conventional chemotherapy with anthracycline and ifosfamide is effective in controlling or stabilizing locally advanced and metastatic SFTs.<sup>[8,9]</sup> Our patient being in metastatic setting, received palliative radiotherapy at local site and was considered for palliative chemotherapy with ifosfamide and epirubicin.

## Conclusion

The authors report here the second case of malignant SFT of spine with distant metastases. Although malignant SFT

is extremely rare, it should be considered in the differential diagnosis of spindle cell tumors in the spine.

## Acknowledgment

Dr. Shambo Guha Roy, M.D., Department of Nuclear Medicine, All India Institute of Medical Sciences, New Delhi, India.

## Financial support and sponsorship

Nil.

## Conflicts of interest

There are no conflicts of interest.

## References

1. Caroli E, Salvati M, Orlando ER, Lenzi J, Santoro A, Giangaspero F. Solitary fibrous tumors of the meninges: Report of four cases and literature review. *Neurosurg Rev* 2004;27:246-51.
2. Fargen KM, Opalach KJ, Wakefield D, Jacob RP, Yachnis AT, Lister JR. The central nervous system solitary fibrous tumor: A review of clinical, imaging and pathologic findings among all reported cases from 1996 to 2010. *Clin Neurol Neurosurg* 2011;113:703-10.
3. Muñoz E, Prat A, Adamo B, Peralta S, Ramón y Cajal S, Valverde C. A rare case of malignant solitary fibrous tumor of the spinal cord. *Spine* 2008;33:E397-9.
4. Perry A, Scheithauer BW, Nascimento AG. The immunophenotypic spectrum of meningeal hemangiopericytoma: A comparison with fibrous meningioma and solitary fibrous tumor of meninges. *Am J Surg Pathol* 1991;96:1354-60.
5. Vallat-Decouvelaere AV, Dry SM, Fletcher CD. Atypical and malignant solitary fibrous tumors in extrathoracic locations: Evidence of their comparability to intra-thoracic tumors. *Am J Surg Pathol* 1998;22:1501-11.
6. Gold JS, Antonescu CR, Hajdu C, Ferrone CR, Hussain M, Lewis JJ, *et al.* Clinicopathologic correlates of solitary fibrous tumors. *Cancer* 2002;94:1057-68.
7. Cox DP, Daniels T, Jordan RC. Solitary fibrous tumor of the head and neck. *Oral Surg Oral Med Oral Pathol Oral Radiol Endod* 2010;110:79-84.
8. Stacchiotti S, Libertini M, Negri T, Palassini E, Gronchi A, Fatigoni S, *et al.* Response to chemotherapy of solitary fibrous tumour: A retrospective study. *Eur J Cancer* 2013;49:2376-83.
9. Park MS, Ravi V, Conley A, Patel SR, Trent JC, Lev DC, *et al.* The role of chemotherapy in advanced solitary fibrous tumors: A retrospective analysis. *Clin Sarcoma Res* 2013;3:7.