

Thoracic Spondylodiscitis Caused by Methicillin-resistant *Staphylococcus aureus* as a Superinfection of Pulmonary Tuberculous Granuloma in an Immunocompetent Patient: A Case Report

Pasquale Donnarumma¹ Roberto Tarantino¹ Valeria Palmarini¹ Tiziano De Giacomo² Roberto Delfini¹

¹Department of Neurosurgery, "Sapienza" University, Rome, Italy

²Department of Thoracic Surgery, "Sapienza" University, Rome, Italy

Global Spine J 2015;5:144–147.

Address for correspondence Pasquale Donnarumma, MD,

Department of Neurosurgery, "Sapienza" University of Rome, Viale del Policlinico 115, 00161, Rome, Italy

(e-mail: dott.pasquale.donnarumma@gmail.com).

Abstract

Study Design Case report.

Objective To describe a very rare case of an immunocompetent man who underwent surgery for thoracic spondylodiscitis caused by methicillin-resistant *Staphylococcus aureus* (MRSA) that developed as a superinfection of a pulmonary tuberculous granuloma.

Methods Posterior decompression and pedicle screw vertebral fixation were followed by T5–T6 anterior somatotomy with implant of an expandable mesh and lateral plating as symptoms worsened. During the anterior approach, an atypical resection of the left lower lobe was also performed.

Results A tuberculous granuloma was detected on histology. Ziehl-Neelsen stain confirmed the diagnosis. Culture also detected MRSA.

Conclusions Early medical management is the first choice for spondylodiscitis to eradicate the infection and alleviate pain. Immobilization of the affected spine segments can protect the patient from vertebral collapse and from the appearance of neurologic deficits. Surgery is suggested if there are compressive effects on the spinal cord, spinal epidural abscess, vertebral collapse, and deformity. We decided to remove the abscess and to restore the anterior column using an anterior approach. Moreover, in this case, an anterior approach allowed us to identify the etiology of the lesion and to determine the best chemotherapy regimen.

Keywords

- ▶ spondylodiscitis
- ▶ thoracotomy
- ▶ pulmonary tuberculous granuloma
- ▶ methicillin-resistant *Staphylococcus aureus* (MRSA)

Introduction

Spondylodiscitis is an infection involving the intervertebral disk, the vertebral body, or the posterior arch of the vertebra. *Mycobacterium tuberculosis* is the most common cause of spondylodiscitis worldwide, followed by *Staphylococcus aureus*, which is the predominant pathogen in pyogenic

spondylodiscitis.^{1,2} Even if chemotherapy is the first treatment, sometimes surgery is needed. We report the rare case of an immunocompetent patient who underwent surgery for thoracic spondylodiscitis caused by methicillin-resistant *S. aureus* (MRSA), which developed as a superinfection of a pulmonary tuberculous granuloma.

received
January 25, 2014
accepted
July 31, 2014
published online
August 30, 2014

© 2015 Georg Thieme Verlag KG
Stuttgart · New York

DOI <http://dx.doi.org/10.1055/s-0034-1390009>.
ISSN 2192-5682.

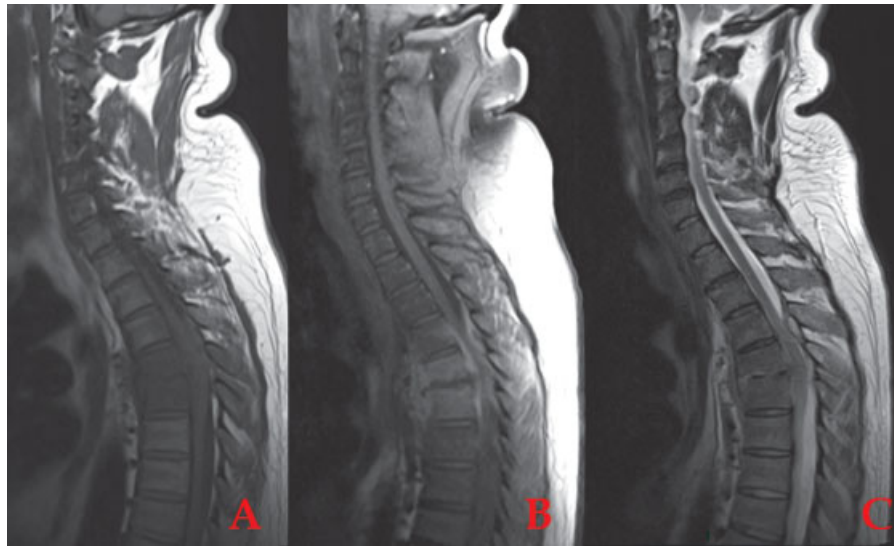


Fig. 1 Magnetic resonance imaging scan on admission. Lesion with a low T1-weighted (A) and high T2-weighted (C) signal in the T5–T6 vertebral body with high postcontrast enhancement (B), involving the T5–T6 disk and the left anterior prevertebral soft tissues; an epidural abscess is also evident, resulting in slight spinal cord compression.

Case Report

A 41-year-old man presented to the emergency room with dorsal back pain unresponsive to nonsteroidal anti-inflammatory drugs. His symptoms included persistent cough, which started 6 months earlier, but he did not have a subjective history of fevers. Neurologic examination was normal. He was 175 cm in height and weighed 130 kg (body mass index = 42 kg/m²). Full blood count and biochemistry showed white blood cell count (WBC) 14,269/L (neutrophils 71.3%; lymphocytes 21.8%; monocytes 2.2%; WBC 4.4 to 11.3/L); functional fibrinogen 907 mg/dL (1.5 to 4 g/dL); C-reactive protein 13.86 mg/dL (0.1 to 6 mg/dL); D-dimer 2,058 µg/L (0 to 500 µg/L); pH 7.74; pO₂ 59 mm Hg; pCO₂ 39 mm Hg; sat O₂ 95.4%. His body temperature was 36.7°C.

A thoracic magnetic resonance imaging (MRI) scan was obtained (► **Fig. 1**), which revealed a lesion with a low T1- and

high T2-weighted signal in the T5–T6 vertebral body with high postcontrast enhancement involving the T5–T6 disk and the left anterior prevertebral soft tissues. An epidural abscess was also evident, resulting in slightly spinal cord compression.

Further workup included blood cultures and computed tomography (CT)-guided needle biopsy of the T5 vertebral body. The blood and biopsy cultures both grew MRSA. Treatment started with rifampin 600 mg, teicoplanin 400 mg, levofloxacin 750 mg, and mobilization in an MZ brace.

Seven days later, the patient developed a high-grade lower-extremity weakness. An urgent MRI scan (► **Fig. 2**) showed an increase in the size of the lesion, fracture of the inferior T5 and superior T6 end plates, and local kyphosis resulting in greater spinal cord compression. The patient underwent surgery of posterior decompression and T3–T9 pedicle screw fixation. Postoperative CT scan (► **Fig. 3**)

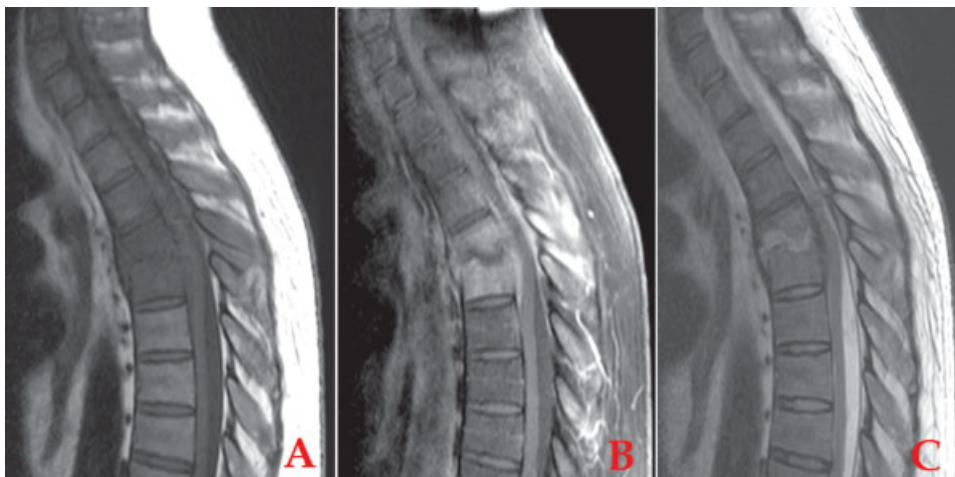


Fig. 2 Magnetic resonance imaging scan after symptoms worsened showing an increase in the size of the lesion, inferior T5 and superior T6 end plate fractures, and local kyphosis resulting in greater spinal cord compression.

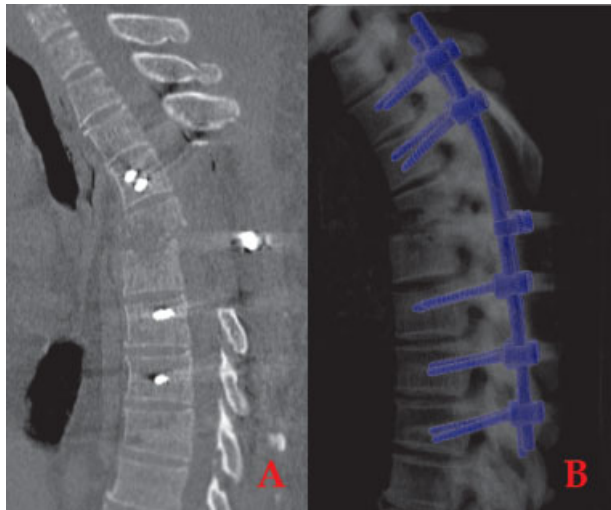


Fig. 3 Postsurgical computed tomography scan: good decompression but not complete realignment of the vertebral bodies.

showed good decompression but not complete realignment of the vertebral bodies.

Seven days later, an anterior approach was used to reconstruct the anterior column and to remove the paravertebral abscess. A T5–T6 corpectomy with implant of an expandable mesh and lateral plating was performed (► **Fig. 4**). A left-side thoracotomy was performed. After lung collapse, a discolored area was identified on the surface of the lower lobe of the left lung, involving the pleura and the paravertebral tissues, and appeared contiguous with the area of the spinal abscess. Atypical resection of the left lower lobe was performed. The material underwent histologic examination and aerobic, anaerobic, fungal, mycobacterial cultures. A tuberculous granuloma was detected on histology. Ziehl-Neelsen stain confirmed the diagnosis. Cultures also detected MRSA.

Treatment was started with rifampin (600 mg), linezolid (600 mg), ethambutol (25 mg/kg), pyrazinamide (25 mg/kg), and isoniazid (300 mg). The patient was referred to rehabilitation. One year later, X-ray (► **Fig. 5**) showed good realignment of the spinal column and no other complications.

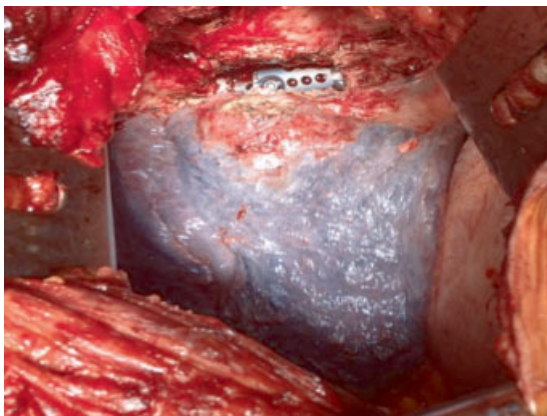


Fig. 4 Left-side thoracotomy, intraoperative view: T5–T6 expandable mesh implant. Irregular area on the surface of the lung corresponding to the pyogenic abscess developed on tuberculous granuloma.

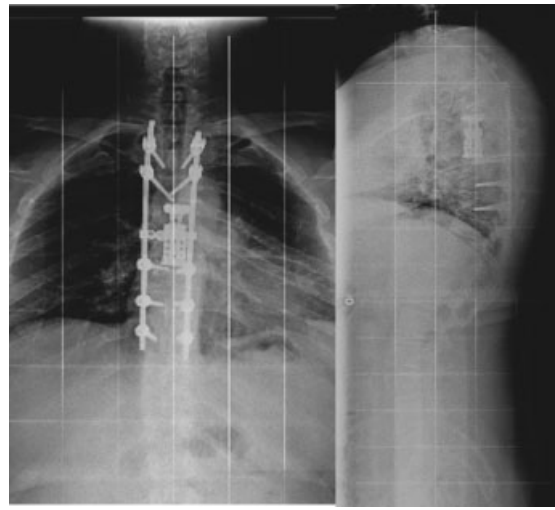


Fig. 5 One-year follow-up X-ray scan: good realignment of the spinal column and no other complications.

The patient is able to walk independently and the back pain is gone.

Discussion

Spondylodiscitis can be etiologically classified as pyogenic, granulomatous (tuberculosis, brucellosis, or fungal infection), or parasitic. Pyogenic spondylodiscitis commonly affects the lumbar column and more rarely affects the thoracic and the cervical column.³ *S. aureus* is the predominant pathogen in pyogenic spondylodiscitis, followed in older people by enterobacteria, mainly *Escherichia coli*, *Proteus*, *Klebsiella*, and *Enterobacter* spp.^{4–6} *Mycobacterium tuberculosis* is the most common cause of spondylodiscitis worldwide. Tuberculosis affects mostly the thoracic spine and involves two or more vertebral segments. The main contamination routes are hematogenous spread, external inoculation, or involvement from adjacent tissue.³

Early medical management is the first choice for eradicating the infection and alleviating pain.³ Immobilization of the affected spine segments can protect the patient from vertebral collapse and from the appearance of neurologic deficits. Chemotherapy should be determined after microorganisms are detected.⁷ Microbiologic diagnosis is essential to enable targeted antibiotic treatment. Agent-sensitive intravenous antibiotics should be begun preferably only after the pathogen has been identified and a table of resistance/sensitivity has been formulated.⁸ Material taken from biopsy should undergo aerobic, anaerobic, fungal, and mycobacterial cultures. Less invasive percutaneous biopsy is a safe procedure and can be taken either by CT-guided scan or by endoscopy.⁹ Nevertheless, biopsy and blood cultures allow microorganism identification in half of patients. When the pathogen is not detected, empirical therapy with a broad-spectrum antibiotic regimen is appropriate.⁸

Surgery is recommended if there is spinal cord compression, spinal epidural abscess, vertebral collapse, or deformity.¹⁰ The anterior approach is the standard for anterior

vertebral body debridement and stabilization. The posterior approach is mainly indicated to decompress the spinal cord or the nerve root due to an epidural abscess.¹¹ However, better stability is achieved with a circumferential fusion.

In our case, the pyogenic spondylodiscitis developed as a superinfection of a pulmonary tuberculous granuloma due to a contiguous invasion of the intervertebral disk. The best treatment for a tuberculous granuloma is surgical removal if the capsule does not allow an effective concentration of drugs in the infection's site.¹² In our case, posterior decompression was performed in an emergency setting because of the symptoms. We decided to use an anterior approach to remove the abscess and to restore the anterior column. Moreover, in this case an anterior approach allowed us to identify the etiology of the lesion and to set the correct chemotherapy. The patient was positioned in right lateral decubitus, and the thoracotomy was achieved via the left side to allow a good exposure and removal of the abscess that had a left extension inside the chest.

The anterior approach with manubriotomy was not considered because the lesion was below the cervicothoracic angle.¹³ Transthoracic thoracotomy is safe and rarely associated with neurologic deterioration.¹⁴

Disclosures

Pasquale Donnarumma, none

Roberto Tarantino, none

Valeria Palmarini, none

Tiziano De Giacomo, none

Roberto Delfini, none

References

- 1 Fantoni M, Trecarichi EM, Rossi B, et al. Epidemiological and clinical features of pyogenic spondylodiscitis. *Eur Rev Med Pharmacol Sci* 2012;16(Suppl 2):2–7
- 2 Trecarichi EM, Di Meco E, Mazzotta V, Fantoni M. Tuberculous spondylodiscitis: epidemiology, clinical features, treatment, and outcome. *Eur Rev Med Pharmacol Sci* 2012;16 (Suppl 2):58–72
- 3 Guerado E, Cerván AM. Surgical treatment of spondylodiscitis. An update. *Int Orthop* 2012;36(2):413–420
- 4 Mann S, Schütze M, Sola S, Piek J. Nonspecific pyogenic spondylodiscitis: clinical manifestations, surgical treatment, and outcome in 24 patients. *Neurosurg Focus* 2004;17(6):E3
- 5 McHenry MC, Easley KA, Locker GA. Vertebral osteomyelitis: long-term outcome for 253 patients from 7 Cleveland-area hospitals. *Clin Infect Dis* 2002;34(10):1342–1350
- 6 Turunc T, Demiroglu YZ, Uncu H, Colakoglu S, Arslan H. A comparative analysis of tuberculous, brucellar and pyogenic spontaneous spondylodiscitis patients. *J Infect* 2007;55(2):158–163
- 7 Aagaard T, Roed C, Dragsted C, Skinhøj P. Microbiological and therapeutic challenges in infectious spondylodiscitis: a cohort study of 100 cases, 2006–2011. *Scand J Infect Dis* 2013;45(6): 417–424
- 8 Zarghooni K, Röllinghoff M, Sobottke R, Eysel P. Treatment of spondylodiscitis. *Int Orthop* 2012;36(2):405–411 [Review]
- 9 Enoch DA, Cargill JS, Laing R, Herbert S, Corrah TW, Brown NM. Value of CT-guided biopsy in the diagnosis of septic discitis. *J Clin Pathol* 2008;61(6):750–753
- 10 Roßbach BP, Niethammer TR, Paulus AC, et al. Surgical treatment of patients with spondylodiscitis and neurological deficits caused by spinal epidural abscess (SEA) is a predictor of clinical outcome. *J Spinal Disord Tech* 2013; October 16 (Epub ahead of print)
- 11 Huang PY, Chen SF, Chang WN, et al. Spinal epidural abscess in adults caused by *Staphylococcus aureus*: clinical characteristics and prognostic factors. *Clin Neurol Neurosurg* 2012;114(6): 572–576
- 12 Tarantino R, Donnarumma P, Fazzolari B, Marruzzo D, Delfini R. Pott's disease: medical and surgical treatment. *Clin Ter* 2013; 164(2):97–100
- 13 Tarantino R, Donnarumma P, Marruzzo D, Landi A, De Giacomo T, Delfini R. Anterior surgical approaches to the cervicothoracic junction: when to use the manubriotomy? *Spine J* 2013;13(9): 1064–1068
- 14 Lubelski D, Abdullah KG, Steinmetz MP, et al. Lateral extracavitary, costotransversectomy, and transthoracic thoracotomy approaches to the thoracic spine: review of techniques and complications. *J Spinal Disord Tech* 2013;26(4):222–232 [Review]