



Case report

Rectal foreign body, an impacted plastic ball: A case report and review of literature

Mohammad N. Athamnah^{*}, Nimah A. Rabai, Hussein S.O. Al Azzam

Department of General Surgery, Princess Basma Teaching Hospital, Irbid, Jordan

ARTICLE INFO

Keywords:

Case report

Rectum

Impacted foreign body

Extraction

Laparotomy

1. Introduction

Foreign body insertion in rectum is not uncommon, predominantly presenting in males [1]. Potential reasons are self-treatment for anorectal conditions, criminal assaults and most commonly for sexual purposes. Almost any object one can think of has been found in rectum [2]. Rectal foreign bodies have different presentations, depending on foreign body shape, size, sharpness and duration of time from insertion to hospital presentation. Local anorectal injury, intestinal obstruction, bowel perforation and peritonitis are all complications [3]. Attempts of removal of foreign bodies at home are almost always present, but can be hazardous, especially if sharp or pointed instruments are used. Manual extraction at the emergency department should be tried first, if it fails, more sophisticated interventions should be used, such as proctosigmoidoscopy, laparoscopy or open surgical interventions. Here we present a case of impacted plastic ball in the rectum that could not be extracted using the above-mentioned techniques. As the ball was wedged in the pelvis and downward pressure during laparotomy failed to move it into the rectum, and transanal upward pressure failed to deliver it into the abdomen. This case is reported in line with the Updating Consensus Surgical CAse REport (SCARE) 2020 criteria [4].

2. Case presentation

One hour after midnight, a previously healthy, 51-year old male presented to Emergency Room (ER) complaining of foreign body in rectum. Patient reported insertion of a plastic ball into the anus two days

earlier. According to patient and his wife, the ball was pushed in to treat hemorrhoids. To facilitate insertion and due to the large size of the ball, an oily material was used for lubrication. Originally, the plastic ball is a part a vacuum carpet cleaning machine. Before hospital presentation, patient tried to extract the foreign body using a screw driver and spoon. The patient had no personal or family history of any specific disease, has a surgical history of open appendectomy 20 years before. He's not on any medications and has no known allergies. At hospital presentation, patient reported anal pain with no abdominal pain, no fever, no abdominal distention, no hematuria, no dysuria, no rectal bleeding. On physical exam, patient was looking well and cooperative with stable normal vital signs. Abdominal exam was unremarkable other than a pelvic mass felt with deep abdominal palpation. Upon inspection of anus, superficial external scratches were seen around anus, on Digital Rectal Exam (DRE) the plastic ball was palpated inside the rectum and anal sphincter tone was preserved. No hemorrhoid disease was seen. An attempt to extract the ball in ER failed, so imaging was done to further evaluate the situation and to plan a suitable extraction method. Simple pelvic x-ray showed a round-shaped foreign body situated in lower abdomen above the anal canal (Fig. 1). Abdominal CT scan identified the exact location, shape and orientation of the ball in the pelvis (Fig. 2).

Patient was admitted to surgical ward and preoperative workup was initiated, operative extraction was scheduled in the next morning. Under general anesthesia, in lithotomy position and using sufficient lubrication, several trials to extract the ball manually through anal canal failed, as the impacted foreign body appeared to be wider than the pelvic outlet. A decision was made to proceed to laparotomy. A 10 cm midline

^{*} Corresponding author at: Department of General Surgery, Princess Basma Teaching Hospital, Irbid 21110, Jordan.

E-mail address: mathamneh85@gmail.com (M.N. Athamnah).

<https://doi.org/10.1016/j.ijscr.2021.106404>

Received 18 August 2021; Received in revised form 8 September 2021; Accepted 10 September 2021

Available online 16 September 2021

2210-2612/© 2021 Published by Elsevier Ltd on behalf of IJS Publishing Group Ltd. This is an open access article under the CC BY-NC-ND license

(<http://creativecommons.org/licenses/by-nc-nd/4.0/>).

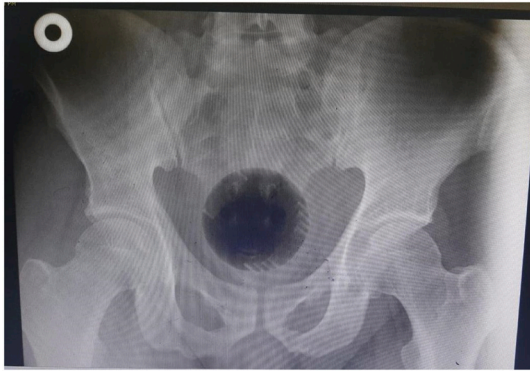

Fig. 1. X-ray showing a round-shaped foreign body in rectum.

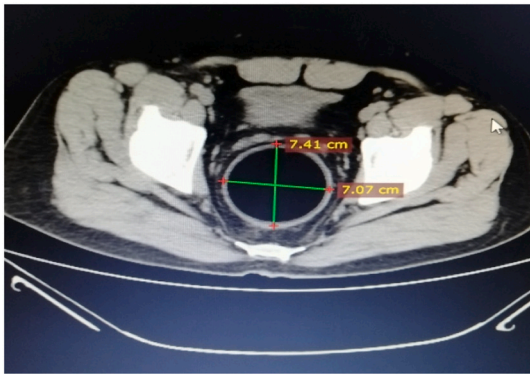


Fig. 2. Abdominal CT scan showing a 7 × 7 cm ball impacted in rectum.

skin incision was made, abdominal wall layers were opened layer by layer. Adhesiolysis was necessary to reach the sigmoid and properly identify the rectum. The foreign body was then felt deep in the pelvis, impacted in the rectum. An attempt to push the impacted ball downwards through the rectum and facilitate transanal extraction was fruitless. Unfortunately, the foreign body was tightly wedged in the pelvis, thus moving the impacted ball upwards was also unsuccessful. After several hours of unproductive efforts to move the ball or change its position, colorectal and orthopedic surgeons were consulted but no solution was provided. At this point, was decided to carefully cut the foreign body into smaller pieces to be extracted. This was done by puncturing the ball with an electric drill used in orthopedic operations, after inserting it through the dilated anus, and connecting the holes together with great caution using a bone cutter. After several hours of working very carefully to avoid rectal injury, the foreign body was broken into 3 main parts which relieved the impaction and made it easy

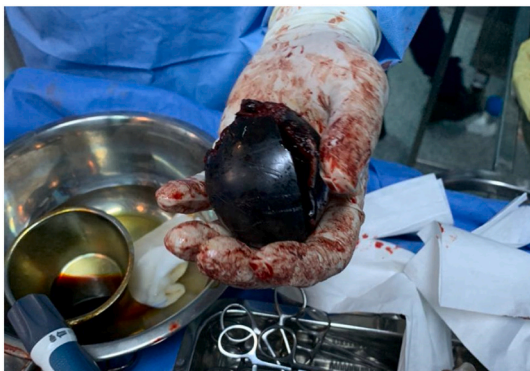

Fig. 3. The extracted foreign body (plastic ball).

to grasp and be extracted through the anus with minimal damage (Fig. 3). Diversion of the fecal stream was necessary after this long traumatic extraction to prevent contamination so a loop colostomy was performed. The operation was performed by HA a general surgery consultant, MA a general surgery specialist and TJ a colorectal surgery consultant who was consulted on phone. The total operative time was 7 h. Postoperative course was smooth and uneventful and the patient was discharged home with colostomy and scheduled for a follow-up proctosigmoidoscopy, which was done almost 2 months after. The scope was inserted up to 30 cm from anal verge (up to the distal colostomy opening), and showed normal rectal and colonic mucosa with no signs of diversion colitis. A small longitudinal mucosal bridging was seen in the anal canal, it has two openings, the distal is in the anal canal and the proximal is in the lower rectum, mostly representing healed mucosal injury (Fig. 4). Revision of colostomy is scheduled later and the patient referred to psychiatric counseling. The patient was compliant with the treatment plan and adherent to the follow-up visits and investigations and was satisfied with care provided by the surgical team and with the uneventful course of treatment.

3. Discussion

The presentation of rectal foreign body (RFB) although relatively uncommon [5–7] is no longer a medical oddity as it's encountered more frequently recently [7–10] with increasing incidence especially in urban areas [11,12]. Yet the diagnosis and management can be challenging [12] due to multiple reasons, including reasons related to the patient's feeling of embarrassment which makes him reluctant to provide details of the incident and to seek medical help only after trying several times to self-extract the object, which could complicate the situation even more and delay timely management [8,12,13], it's reported that only 33.3% of the cases of RFB present a history of anal introduction [8]. Other reasons are related to the shape of the foreign body which can make the extraction process challenging. If the RFB is sharp or large it could get impacted and difficult to remove and have a risk of causing perforation and tissue injury.

In general, RFB can be seen in all age groups, but its predominant in 30–40 years [12,14], with higher proportion of male patients 17:37:1 [15].

Most commonly encountered rectal foreign bodies are household objects like bottles and glasses (42.2%) [15,16], sexual toys, vegetables and fruits, lightbulbs [8,18], candles, and balls [18] as found in the patient we present here. Some ingested foreign bodies can also be found in rectum such as fish bone [14]. It can be iatrogenic as in migration of colonic stents [6] or in extremely rare cases, the migration of Intra-Uterine Contraceptive Device (IUCD) with penetration of rectal wall into rectal lumen, as reported by Ye et al. [17].

Regarding the reasons for insertion, RFB is either inserted

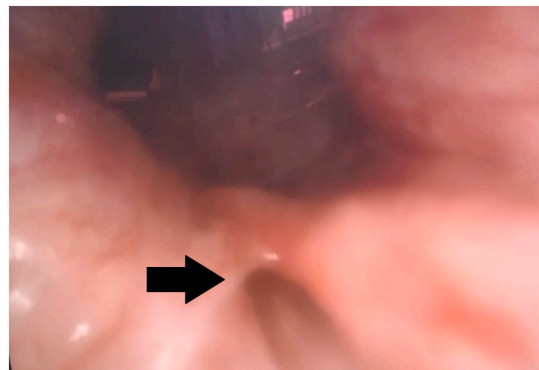


Fig. 4. Proctosigmoidoscopy revealed a mucosal bridging in the anal canal (black arrow).

voluntarily; most commonly for sexual gratification 75% [5,17] whether autoeroticism or as a consensual sexual act [19], or for treating anorectal conditions, for example to relieve fecal impaction, or for prostate massage, especially in the elderly [20], in drug traffickers as body packs [17], in prisoners hiding objects especially to harm others [21], and in the psychiatric patients including those with factitious disorders such as Munchausen's syndrome as the case reported by Khan et al. [19]. In others, RFBs are involuntarily inserted as in sexual assaults and rape, accounting for 12.5% of cases [21], in which cases legal authorities should be notified [18]. Other involuntary cases are attributed to accidental trauma [7].

Patients with RFB mostly present with anal pain and bleeding 66.7% [8,11], other symptoms include abdominal pain, constipation, obstipation or incontinence, depending on the location of RFB, presence of complications such as intestinal obstruction or perforation, and the duration of time from insertion to presentation to medical services.

Historically, the first report describing management of retained RFB dates back to the 16th century. In the modern era, the first reports were published in 1919 [15]. In general, patients with RFB should be dealt with in a supportive environment with confidentiality and professionalism, without being judgmental or comical [5,15,22]. Evaluation starts in the emergency room, with general and vital signs examination, which in case of abnormality may indicate the presence of perforation. Abdominal exam to evaluate for tenderness and determine the presence and location of foreign body if palpable, as in our case, in which the ball was felt in the lower abdomen. And most importantly to look for signs of peritonitis [5,11] which mandates an immediate surgical exploration. DRE is the constant part and the most informative of the physical exam [9,15] to assess the location, shape and size of the RFB, the presence of any associated local injury and to assess the tone of the anal sphincter [5].

Laboratory workup is not helpful in the diagnosis, it's necessary to perform in complicated cases when perforation is suspected, which can occur in 25% of cases [21]. It will show as leukocytosis and elevated acute inflammatory markers like C-Reactive Protein (CRP) [18], and lactic acidosis [5]. It's also requested as part of preoperative preparation if surgery is planned [15,17].

Imaging can aid in identifying RFB, its shape, number, size, direction and exact location. Plain abdomen and pelvic X-ray should be obtained to look for signs of perforation (pneumoperitoneum) or signs of obstruction [11]. If surgery is planned or if X-ray imaging doesn't reveal the foreign body, computed tomography can be helpful and decisive in further management [6,11], and it's also recommended if more than 24 h passed with RFB inside [23].

A wide spectrum of injury patterns can be associated with RFB. Ranging from minimal mucosal injury, to more serious complications like intraperitoneal perforation, sepsis, or even death [10]. Rectum Injury Scale of the American Association for the Surgery of Trauma can be used to classify the foreign body-induced rectal injury to define proper management (Table 1) [15,21].

Majority of patients are managed conservatively, with occasional need for surgical intervention [12]. In general, extraction of RFB should

Table 1
Rectum Injury Scale of the American Association for the Surgery of Trauma.

Grade	Lesion	Description
I	Hematoma or	Contusion or hematoma without devascularization.
	Laceration	Partial thickness laceration of wall
II	Laceration	Full-thickness laceration of wall that compromises < 50% of circumference
III	Laceration	Full- thickness laceration of wall compromises >50% of circumference
IV	Laceration	Full- thickness laceration that extends into the perineum
V	Vascular	Devascularized segment of rectum

Source: Adapted from Kyle G Cologne, Glenn T Ault [15].

start with the least invasive method, with gentle manual transanal extraction if possible, moving to endoscopic approach, or more invasive approaches like laparoscopy or laparotomy in difficult-to-extract objects [15]. Due to the wide spectrum of foreign bodies that patients present with, the process of extraction can be tedious requiring considerable skill which makes ingenuity on the part of the surgeon [6] who occasionally needs to come up with creative approaches to perform the extraction while ensuring successful extraction with least possible injury. In our patient, after all conventional methods have failed, we used orthopedic instruments like a drill and bone cutter to fragment the ball and retrieve it in pieces, cautiously, without causing any significant injury.

3.1. Transanal approach

According to Kingsley et al., RFB that are located in low or mid rectum up to 10 cm level can be safely removed with transanal approach, while laparotomy would be required for objects located above 10 cm [11]. This classification based on RFB location of entrapment helps to stratify the likelihood of transanal extraction [7].

This method is successful in managing 60-75% of cases [7], performed under local, spinal or general anesthesia to help relax the sphincter muscles to allow better visualization and increase the chance of successful extraction [12,15]. Suprapubic or sigmoid pressure can be applied, or the patient can perform Valsalva maneuver to prevent cephalad migration of the object and help moving it caudally down the rectum [15]. After sufficient lubrication, RFB can be simply removed by finger extraction [24] with careful insertion of the finger since some objects may be pointed or sharp [21], or it can be extracted using various instruments including ring forceps, obstetric forceps, suction devices, tonsil snares [24], Foley catheters, plaster of Paris or super glue to hold the objects, or by drilling holes in the object, with caution taken in extracting glass objects [7] and manipulating fragile foreign bodies [12].

3.2. Endoscopic approach

This method is used if transanal extraction fails. Usually for objects high in the rectum or even the colon [12]. Polypectomy snare, biopsy forceps, balloon techniques and guide wires, can be utilized for extraction [7]. It's contraindicated to use enemas to propel objects distally, as tit would cause further damage to the rectal wall [15].

3.3. Surgical approach

Surgery is the treatment of choice for patients with evidence of peritonitis, based on the medical history, physical examination, imaging and laboratory workup [16]. For clinically stable patients laparoscopy or laparotomy can be used if transanal and endoscopic approaches fail. They are usually for objects larger than 10 cm, hard or sharp, or located in proximal rectum or distal sigmoid [12]. RFB can be removed transanally with laparoscopic assistance using one 10 mm and two 5 mm ports [22].

Pubic symphysiotomy can be used if laparotomy fails to extract objects impacted in the pelvis. It expands the volume of the pelvis thus facilitates the extraction process as described by Kasotakis et al. [12].

Post-extraction of RFB, patients with mucosal injury like erosions, edema or lacerations should be observed as inpatients [21]. Abdominal radiography should be performed to rule out perforation that could have occurred during extraction [7]. Colonoscopy is also advised to confirm any rectal injury and degree of damage if present and to perform endoscopic hemostasis if needed [17]. Sphincter dysfunction can present after extraction, and usually improves with observation. If incontinence persists, then delayed sphincteroplasty can be performed [7]. It's crucial to provide supportive care and refer patients for psychiatric evaluation and counseling, especially in recurrent cases or cases involving assaults [5] to enable the patients to lead a normal social and

sexual life [6] and to prevent recurrence in the future [8]. Our patient had an uneventful postoperative course, a reassuring follow-up proctosigmoidoscopy and a proper referral to psychiatric clinic, he is also scheduled for colostomy revision surgery in the near future.

4. Conclusion

The case we present herein emphasizes how RFB can be challenging in both diagnosis and management, and how important it is for surgeons to be creative and prepared to use various techniques and instruments to safely remove RFB as conventional methods may occasionally fail.

Consent

Written informed consent was obtained from the patient for publication of this case report and accompanying images. A copy of the written consent is available for review by the Editor-in-Chief of this journal on request.

Provenance and peer review

Not commissioned, externally peer-reviewed.

Ethical approval

I certify that this kind of manuscript does not require ethical approval.

Funding

This work was independent and was not supported by any funding.

Guarantor

Mohammad N Athamneh
Nimah A Rabai.

Research registration number

N/A.

CRediT authorship contribution statement

Mohammad N Athamnah presented the study concept, collected data, wrote the case presentation, reviewed the paper, and had a final decision to publish.

Nimah A Rabai collected data, wrote the abstract and discussion, reviewed the paper, and had a final decision to publish.

Hussein SO Al Azzam reviewed the paper and had a final decision to publish.

Declaration of competing interest

Authors have no potential competing interests or conflicts to report.

Acknowledgements

None.

References

- [1] D.L. Clarke, I. Buccimazza, F.A. Anderson, S.R. Thomson, Colorectal foreign bodies, *Color. Dis.* 7 (1) (2005 Jan) 98–103.
- [2] A.A. Ayantunde, Approach to the diagnosis and management of retained rectal foreign bodies: clinical update, *Tech. Coloproctology* 17 (1) (2013 Feb) 13–20.
- [3] J.P. Lake, R. Essani, P. Petrone, A.M. Kaiser, et al., Management of retained colorectal foreign bodies: predictors of operative intervention, *Dis. Colon Rectum* 47 (10) (2004 Oct 1) 1694–1698.
- [4] for the SCARE Group, R.A. Agha, T. Franchi, C. Sohrabi, G. Mathew, The SCARE 2020 guideline: updating consensus Surgical Case Report (SCARE) guidelines, *Int. J. Surg.* 84 (2020) 226–230.
- [5] Daniel R. Principe, Jonathan Rubin, Matt Narbutis, et al., Repeat presentation of large rectal foreign body requiring surgical intervention, *J. Surg. Case Rep.* 4 (2019) 1–3.
- [6] Gaurav Aggarwal, Bhaskar Satsangi, Ramsharan Raikwar, et al., Unusual rectal foreign body presenting as intestinal obstruction: a case report, *Ulus Travma Acil Cerrahi Derg.* 17 (4) (2011) 374–376.
- [7] Hariharasudan Mani, Ronald Waits, Retained colorectal foreign body: a case report, *Int. J. Clin. Med. Imaging* 5 (2018) 614.
- [8] Robin G. Cheereth, George A. Ninan, Rectal foreign body: a case report, *Int. Surg. J.* 4 (3) (2017 Mar) 1119–1122.
- [9] Eyup M. Yilmaz, Erdem B. Catı, Rectal foreign bodies: five case reports, *Turk. J. Colorectal Dis.* 26 (2016) 98–100.
- [10] Armando Peixoto, Fernando Azevedo, Guilherme Macedo, Unusual retained rectal foreign body, *GE Port J. Gastroenterol.* 22 (6) (2015) 280–282.
- [11] Mahim Koshariya, Abhishk Shitole, Anshul Siroliya, Foreign body in rectum: case management and review of literature, *J. Clin. Diagn. Res.* (12) (2018 Dec), PD01-PD02.
- [12] G. Kasotakis, L. Roediger, S. Mittal, Rectal foreign bodies: a case report and review of literature, *Int. J. Surg. Case Rep.* 3 (2012) 111–115.
- [13] Adrian C.H. Fung, Bess S.Y. Tsui, Sammi Y.S. Wong, Y.H. Tam, Self-inserted foreign bodies during COVID-19: two case reports, *Hong Kong Med. J.* 27 (2021) 142–144.
- [14] Gun Kim, Nam-Hee Kim, Ri Na Yoo, et al., Rectal foreign body-case report, *Trauma Emerg. Care* 2 (4) (2017) 1–2.
- [15] Kyle G. Cologne, Glenn T. Ault, Rectal foreign bodies: what is the current standard? *Clin. Colon Rectal. Surg.* 25 (2012) 214–218.
- [16] Hiroo Sei, Toshihiko Tomita, Keisuke Naki, et al., Rectal foreign body of eggplant treated successfully by endoscopic transanal removal, *Case Rep. Gastroenterol.* 12 (2018) 189–193.
- [17] Hui Ye, Shujuan Huang, Qichang Zhou, et al., Migration of a foreign body to the rectum: a case report and literature review, *Medicine* 97 (28) (2018), e11512.
- [18] Norichika Yoshie, Atsunori Nakao, Eizaburo Ishimaru, et al., Unusual rectal foreign bodies: a case report and review of published works, *Acute Med. Surg.* 1 (2018) 61.
- [19] Shakeeb A. Khan, Christine A. Davey, Shamsul A. Khan, et al., Munchausen's syndrome presenting as rectal foreign body insertion: a case report, *Cases J.* 1 (243) (2008).
- [20] J.G. Ondieki, D. Kiptoon, Unusual case of rectal foreign body: case report, *East Afr. Med. J.* 91 (11) (2014 Nov).
- [21] Carlos E. Martinez, Lina Mateus, Heinz Ibanez, et al., literature review of management of colorectal foreign bodies, *Rev. Colomb. Gastroenterol.* 33 (1) (2018).
- [22] Arjun Singh Sandhu, Pruthwiraj Rao, Severe intraperitoneal injuries due to self introduced rectal foreign body, *Indian J. Surg.* 70 (April 2008) 86–88.
- [23] Tzu-Yi Chuang, Paul Tingey, Hassan Malik, Havish Srinath, Novel approach to rectal foreign body retrieval: a case report, *Int. J. Case Rep. Images* 9 (2018), 100926Z01TC2018.
- [24] J.L. Morgan, H.N. Khan, A case presentation of retained rectal foreign body, *EuroRad* (2007) 1563–4086, <https://doi.org/10.1594/EURORAD/CASE.5711>.