



Since January 2020 Elsevier has created a COVID-19 resource centre with free information in English and Mandarin on the novel coronavirus COVID-19. The COVID-19 resource centre is hosted on Elsevier Connect, the company's public news and information website.

Elsevier hereby grants permission to make all its COVID-19-related research that is available on the COVID-19 resource centre - including this research content - immediately available in PubMed Central and other publicly funded repositories, such as the WHO COVID database with rights for unrestricted research re-use and analyses in any form or by any means with acknowledgement of the original source. These permissions are granted for free by Elsevier for as long as the COVID-19 resource centre remains active.



Case Report

Prolonged viral shedding in a lymphoma patient with COVID-19 infection receiving convalescent plasma



Ayşe Karataş^a, Ahmet Çağkan İnkaya^b, Haluk Demiroğlu^a, Salih Aksu^a, Tahmaz Haziye^a, Olgun Erkin Çınar^a, Alpaslan Alp^c, Ömrüm Uzun^b, Nilgün Sayinalp^a, Hakan Göker^{a,*}

^a Hacettepe University Faculty of Medicine, Department of Internal Medicine, Hematology Unit, Ankara, Turkey

^b Hacettepe University Faculty of Medicine, Department of Infectious Diseases, Ankara, Turkey

^c Hacettepe University Faculty of Medicine, Department of Medical Microbiology, Ankara, Turkey

ARTICLE INFO

Keywords:

COVID-19

SARS-CoV-2

Lymphoma

Autologous stem cell transplantation (ASCT)

Convalescent plasma

ABSTRACT

Acute respiratory syndrome coronavirus 2 (SARS-CoV-2) first identified in Wuhan, China; and spread all over the world. Reverse-transcription polymerase chain reaction (RT-PCR) test for SARS-CoV-2 usually returns to negative in 20 days post-infection, but prolonged positivity has been reported up to 63 days. A case whose viral shedding lasted 60 days is reported from China. Herein we report a patient with a history of autologous stem cell transplantation (ASCT) for lymphoma whose RT-PCR test remained positive for SARS-CoV-2 for 74 days. The prolonged RT-PCR positivity, despite convalescent plasma infusion, may suggest that the given antibodies may be ineffective in terms of viral clearance. In patients with hematological malignancies or immunosuppression, such as ASCT, may lead to prolonged viral shedding, and strict isolation is warranted for long-term SARS-CoV-2 infection control.

1. Introduction

Acute respiratory syndrome coronavirus 2 (SARS-CoV-2) was first identified in Wuhan, China; and spread all over the world. Disease, caused by the SARS-CoV-2 virus named coronavirus disease 2019 (COVID-19). The clinical course ranges from asymptomatic infection to severe pneumonia, cytokine release syndrome, and fatal acute respiratory distress syndrome [1]. The mortality of COVID-19 deemed to be correlated with hyper-inflammation. Immunosuppression can suppress the destructive effect of the immune system, slow down virus clearance, and in turn may change the expected course of the disease. Also, immunosuppression may have detrimental effects during viral infection [2].

Innate and adaptive immune responses are fundamental to fight back viral assaults. Clinical features and prognosis of COVID-19 in immunosuppressed patients may be detrimental at this time [3]. Chemotherapeutic agents and corticosteroids used in the treatment of malignant diseases make the patients more vulnerable to COVID-19 disease by making their immune system even worse [4].

There is currently no evidence-based specific treatment for COVID-19. Given that the benefit of the current medications is limited, it might be somewhat useful to consider using the convalescent plasma (CP)

transfusion as a treatment strategy for critically ill patients [5].

2. Case presentation

A 61-year-old man with a history of mixed cellularity classical Hodgkin lymphoma (MCCHL, 4 years ago), peripheral T-cell lymphoma (17 months ago), autologous stem cell transplantation (ASCT, 6 months ago), hypogammaglobulinemia, invasive pulmonary aspergillosis (5 months) admitted with dyspnea and pleural effusion. The patient was in remission for MCCHL for 4 years. Later, he developed T-Cell lymphoma which was treated with ICE (ifosfamide, carboplatin and etoposide). Eventually, he underwent ASCT with BEAM (carmustine, etoposide, cytarabine, melphalan) conditioning regimen. Liposomal amphotericin B was given as secondary prophylaxis.

He was readmitted with dyspnea after 100 days of ASCT, while his lymphoma was in partial remission. The reverse-transcription polymerase chain reaction (RT-PCR) test obtained from the upper respiratory tract was negative of SARS-CoV-2. As computed tomography (CT) imaging revealed pleural effusion and progression of fungal infection liposomal amphotericin B was started once again. Besides, bacterial pneumonia was also covered with broad spectrum antimicrobials.

* Corresponding author.

E-mail address: hgoker1@yahoo.com (H. Göker).

<https://doi.org/10.1016/j.transci.2020.102871>

Received 15 June 2020; Accepted 18 June 2020

Available online 03 July 2020

1473-0502/ © 2020 Elsevier Ltd. All rights reserved.

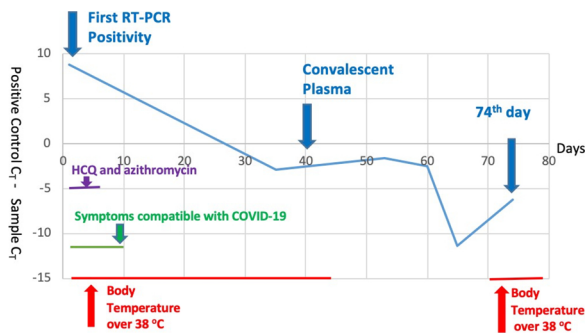


Fig. 1. Temporal Changes in (C_T) (positive control) - (C_T) (patient). (C_T) of the consequent samples were as follows 26.75, 28.13, 28.13, 29.45, 37.8 and 34.7 at respective time points.

(*) C_T → Cycle Threshold

(**) HCQ → Hydroxychloroquine

On the 25th day of the hospitalization the patient was tested positive with RT-PCR test for SARS-CoV-2 during work-up for prolonged fever and increased oxygen requirement. Chest CT also supported the diagnosis of COVID-19 pneumonia which was treated with hydroxychloroquine and azithromycin. After treatment for COVID-19 his oxygen requirement improved and imaging findings were improved in the follow-up CT.

He did not defervesce without any apparent origin of infection and the bacterial cultures remained sterile. Since the patient's swabs were still positive for SARS-CoV-2 RT-PCR on the 40th day of the infection, and he had persistent fever; we administered COVID-19 CP transfusion after obtaining a written consent.

We use Trima Accel® Automated Blood Collection System to obtain CP product from a donor satisfying universal donation criteria and recovered from COVID-19 disease. The EUROIMMUN ELISA kit was used to study the anti-SARS-CoV-2 IgG semi-quantitative titer of the donor's plasma and it was found positive (Titer 13.3; < 0.8 negative, ≥ 0.8 to < 1.1 borderline, ≥ 1.1 positive) before collection. 72 h after the CP transfusion, anti-SARS-CoV-2 IgG titer of the patient's plasma was 2.53 (≥ 1.1 positive).

After the CP transfusion, his fever resolved after 3 days. He was discharged from the hospital on the 78th day of hospitalization.

A week later, his fever relapsed and follow-up RT-PCR test was found to be positive. The last RT-PCR test, performed 74 days after the onset of COVID-19 was still positive. His viral shedding remained positive as demonstrated by RT-PCR, though his clinical features improved.

In Fig. 1, we show RT-PCR findings and summarize clinical symptoms.

3. Discussion

The case described herein presents a patient recovered from COVID-19 pneumonia with prolonged viral shedding.

COVID-19 claimed lives of thousands globally and yet, there is still no proven treatment. Consequently, both researchers and medical professionals try different possible treatments to cure patients. Given that the benefit of the current medications is limited, it is useful to consider the CP transfusion as a treatment strategy for critically ill patients. It is a well-known and safe procedure used in infectious diseases for years, and especially during the outbreaks (Ebola, SARS, H1N1, etc.). During the ongoing COVID-19 pandemic, the researchers have shown the positive effects of CP in critically ill patients with a limited amount of cases [6].

We administered CP transfusion to help viral clearance. However, the RT-PCR test for SARS-CoV-2 was still positive on the 74th day of the infection. The persistence of PCR positivity despite CP infusion may suggest that the given antibodies are not highly effective in terms of

viral clearance.

A multicenter clinical trial investigated the clinical effects of CP treatment in critically ill patients. All patients were given "standard" COVID-19 treatment. CP group was given additional CP. They could not find a statistically significant difference in the time to clinical improvement and the mortality rate in 28 days between the groups. Also, they established delayed viral clearance at 72 h in the CP group [7].

Normally, upper respiratory specimens return to negative in 20 days post-infection but prolonged positivity may last to 63 days, and it is mostly reported in severe patients [8,9]. A case whose viral shedding lasted 60 days is reported from China [10].

Zhu et al. investigates the clinical features of COVID-19 pneumonia in renal transplantation recipients who are immunosuppressed. In this study, longer viral shedding is observed in renal transplant recipients compared to the immunocompetent control group [3].

Our patient had also undergone bone ASCT thus, underlying immunosuppression might lead to prolonged shedding. Unfortunately, we could not perform whole genome sequencing, viral culturing to confirm the detected genome belonged to a viable virus. Furthermore, we can not exclude the possibility of reinfection. Despite, the patient was remained positive in RT-PCR he did not develop any symptoms compatible with COVID-19 after the initial disease course.

4. Conclusion

In conclusion, to the best of our knowledge this is the longest recorded COVID-19 patient with lymphoma who underwent ASCT with persistent SARS-CoV-2 viral shedding for 74 days, even with the administration of CP. In patients with hematological malignancies or immunosuppression such as ASCT may lead to prolonged viral shedding and strict medical precautions and isolation rules should be followed for SARS-CoV-2.

CRedit authorship contribution statement

Ayşe Karataş: Writing - original draft, Conceptualization, Visualization. **Ahmet Çağkan İnkaya:** Writing - review & editing. **Haluk Demiroğlu:** Supervision. **Salih Aksu:** Supervision. **Tahmaz Haziye:** Investigation. **Olgu Erkin Çınar:** Investigation. **Alpaslan Alp:** Resources. **Ömrüm Uzun:** Supervision. **Nilgün Sayınalp:** Supervision. **Hakan Göker:** Writing - review & editing, Conceptualization, Methodology, Supervision.

References

- [1] Neurath MF. Covid-19 and immunomodulation in IBD. *Gut* 2020;69(7):1335–42. <https://doi.org/10.1136/gutjnl-2020-321269>.
- [2] Ritchie AI, Singanayagam A. Immunosuppression for hyperinflammation in COVID-19: a double-edged sword? *Lancet* 2020;395(10230):1111. [https://doi.org/10.1016/S0140-6736\(20\)30691-7](https://doi.org/10.1016/S0140-6736(20)30691-7).
- [3] Zhu L, et al. Coronavirus disease 2019 pneumonia in immunosuppressed renal transplant recipients: A summary of 10 confirmed cases in wuhan, china. *Eur Urol* 2020;77(6):748–54. <https://doi.org/10.1016/j.eururo.2020.03.039>.
- [4] Kuderer NM, et al. Clinical impact of COVID-19 on patients with cancer (CCC19): a cohort study. *Lancet* 2020. [https://doi.org/10.1016/S0140-6736\(20\)31187-9](https://doi.org/10.1016/S0140-6736(20)31187-9).
- [5] Chen L, Xiong J, Bao L, Shi Y. Convalescent plasma as a potential therapy for COVID-19. *Lancet Infect Dis* 2020;20(4):398–400. [https://doi.org/10.1016/S1473-3099\(20\)30141-9](https://doi.org/10.1016/S1473-3099(20)30141-9).
- [6] Salazar E, et al. Treatment of COVID-19 patients with convalescent plasma. *Am J Pathol* 2020. <https://doi.org/10.1016/j.ajpath.2020.05.014>.
- [7] Li L, et al. Effect of convalescent plasma therapy on time to clinical improvement in patients with severe and life-threatening covid-19: a randomized clinical trial. *JAMA* 2020.
- [8] Widders A, Broom A, Broom J. SARS-CoV-2: The viral shedding vs infectivity dilemma. *Infection, Disease and Health* 2020. <https://doi.org/10.1016/j.idh.2020.05.002>.
- [9] Liu W-D, et al. Prolonged virus shedding even after seroconversion in a patient with covid-19. *J Infect* 2020. <https://doi.org/10.1016/j.jinf.2020.03.063>.
- [10] Li J, Zhang L, Liu B, Song D. Case report: viral shedding for 60 days in a woman with covid-19. *Am J Trop Med Hyg* 2020;102(6):1210–3. <https://doi.org/10.4269/ajtmh.20-0275>.