

Circulating levels of reactive oxygen species in patients with nonproliferative diabetic retinopathy and the influence of antioxidant supplementation: 6-month follow-up

Daniela Domanico, Serena Fragiotta¹, Alessandro Cutini¹, Carmela Carnevale², Luigi Zompatori³, Enzo Maria Vingolo¹

Aims: The aim was to evaluate circulating levels of reactive oxygen species (ROS) and changes in central macular thickness (CMT) in patients with nonproliferative diabetic retinopathy (NPDR) after antioxidant supplementation. **Materials and Methods:** A total of 68 patients (68 eyes) with NPDR were enrolled. Patients were randomly divided into two groups: Treated with antioxidant supplement (Group A) and untreated control group (Group B). Each tablet, for oral administration, containing pycnogenol 50 mg, Vitamin E 30 mg and coenzyme Q10 20 mg. CMT and free oxygen radical test (FORT) were analyzed at baseline (T0), 3 (T1) and 6 (T2) months in both groups. **Results:** In Group A, FORT levels and CMT were significantly reduced over time ($P < 0.001$ for both). In Group B, FORT levels were increased ($P < 0.001$) and CMT did not vary significantly ($P = 0.81$) over 3 time points. **Conclusions:** This is the first study showing the reduction of ROS levels in patients with NPDR thanks to antioxidant therapy. Moreover, our findings have suggested also an influence on retinal thickness.

Key words: Antioxidant supplementation, diabetes mellitus, free oxygen radicals test, nonproliferative diabetic retinopathy, reactive oxygen species

Diabetes is associated with microvascular complications involving the retina, glomerulus and vasa nervorum. Hyperglycemia causes abnormalities in the blood flow and vascular permeability, due to imbalance between vasodilators (nitric oxide) and vasoconstrictors (angiotensin II and endothelin-1) and permeability factors such as vascular endothelial growth factor (VEGF).^[1]

During diabetes, very low-density lipoprotein, low-density lipoprotein and high-density lipoprotein undergo oxidation by free radicals. In addition, proteins are also nonenzymatically glycosylated forming advanced glycation end products (AGEs). The formation of AGEs increases the production of reactive oxygen species (ROS).^[2-4] Other pathways contributing in ROS production are increased flux of glucose through the polyol pathway, activation of protein kinase C isoforms and hyperactivity of hexosamine pathway. Oxidative stress mediated by ROS overproduction is involved in the development and progression of endothelial cells and pericytes damage in diabetic retinopathy.^[5] Thus, the inhibition or reduction of oxidative stress may become an important strategy for therapy and prevention of diabetic complications.^[6-9]

Department of Ophthalmology, S. M. Goretti Hospital, Via G. Reni, 04100 Latina, ¹Department of Ophthalmology, A. Fiorini Hospital, Via Firenze, 04019 Terracina, Sapienza University of Rome, Rome, ²Department of Sense Organs UOC B, Policlinico Umberto I Hospital, Sapienza University of Rome, Viale del Policlinico 155, 00161 Rome, ³Department of Ophthalmology, San Giovanni Evangelista Hospital, Via Parrozzani 3, 00019 Tivoli, Italy

Correspondence to: Dr. Carmela Carnevale, Via Benadir 12, 00199 Rome, Italy. E-mail: carmelacarnevale@hotmail.it

Manuscript received: 24.07.14; **Revision accepted:** 23.01.15

The aim of this study was to assess the efficacy of antioxidant dietary supplementation composed by pycnogenol, Vitamin E and coenzyme Q10 (CoQ) in reducing the ROS levels in patients with nonproliferative diabetic retinopathy (NPDR), after 6-month of treatment. Furthermore, we also evaluated the possible structural changes of central macular thickness (CMT) over time, using spectral domain optical coherence tomography (SD-OCT).

Materials and Methods

A total of 68 patients with type 2 diabetes (range: 40–79 years) suffering from mild or moderate NPDR were enrolled. These patients were randomly assigned to two age-matched groups: Group A receiving antioxidant dietary supplementation and untreated control group (Group B). The patients were progressively numbered as they presented to our observation, we used the online randomization program (<http://www.graphpad.com/quickcalcs/index.cfm>) selecting random numbers and then randomly assign subjects to groups.

Each participant gave written consent before enrolment into the study. Institutional board approval was obtained from ethics committee of our institution. All procedures adhered to the tenets of the declaration of Helsinki.

Eligibility criteria included: Glycosylated hemoglobin levels in the normal range (HbA1C level $\leq 6.0\%$), normal lifestyle based on Mediterranean diet, mild-moderate physical exercise, abstinence of alcohol and tobacco products, no systemic hypertension or dyslipidemia, and no excessive exposure to the ultraviolet rays. All the patients had mild or moderate NPDR without clinically significant macular edema (CSME), according to the Early Treatment Diabetic Retinopathy Study protocol.^[10,11]

Access this article online

Website:
www.ijo.in

DOI:
10.4103/0301-4738.151455

Quick Response Code:



The patients have received metformin as monotherapy at a dose of 1000 mg twice daily. They were treated with the same oral hypoglycemic medication for at least 6-month prior to study enrollment.

Exclusion criteria were: Presence of coronary artery disease (CAD) or family history of CAD, prior treatment with Vitamin C or any other antioxidant dietary supplements, steroid or nonsteroid anti-inflammatory drugs, history of acute or chronic infections, fever, cancer or organ failure, peripheral vascular disease, thrombotic events, urinary microalbumin > 300 mg/day. We have also excluded subjects with other ocular pathologies, dioptric media opacities, patients who had a history of intravitreal injection therapies and previous laser treatment, and those with a history of intraocular or vitreoretinal surgery within 6-month.

Each tablet (Diabeter[®], Visufarma, Rome, Italy) contained 50 mg of pycnogenol, 30 mg of Vitamin E and 20 mg of CoQ. The oral dosage consisted of 1 tablet/day for 6-month.

All patients underwent a complete ophthalmologic examination and SD-OCT at baseline (T0), 3 (T1) and 6 (T2) months after the antioxidant dietary supplementation. Fluorescein angiography (FA) was performed at baseline, to exclude the presence of proliferative diabetic retinopathy (PDR). A capillary sample was collected for free oxygen radical test (FORT) examination at baseline and at months 3 and 6.

Spectral domain optical coherence tomography scans were performed with the Spectralis[®] HRA+OCT (software version 5.4.7.0, Heidelberg Engineering, Heidelberg, Germany), in a pattern of 20° × 15° (5.8 mm × 4.3 mm) raster scans consisting of 19 high-resolution line scans, each composed of 50 averaged frame. CMT was measured automatically using standard protocols of Heidelberg software. In addition, whenever both eyes of a patient were eligible, the right eye was selected as the study eye.

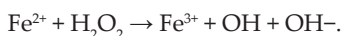Patients were divided into two subgroups according to the SD-OCT features: NPDR with diffuse retinal thickening (DRT) and without (wDRT). DRT is defined as increased retinal thickness (>200 μm) with reduced intraretinal reflectivity, especially in the outer retinal layers.^[12]

SD-OCT examination was performed by the same investigator at each follow-up time.

Oxidative stress analysis

The blood levels of ROS were determined using FORT with free oxygen radicals monitor and kit (FORM[®], CR 2000, Callegari, Italy). We used the FORM system to determine the concentration of ROS by a specific photometric kit of reagents called FORT. This is a colorimetric test based on the ability of the transition metals, such as Fe²⁺ or Fe³⁺, to catalyze the formation of free radicals in the presence of hydroperoxides (ROOH) (Fenton reaction). Radicals are then chemically trapped in an amine derivative.

Fenton reaction



This chemical reaction leads to the formation of a more stable radical colored cation, measured photometrically at 505 nm using the FORM analyzer. Different degrees of colors

are directly related to the quantity of radical compounds and the oxidative status of the blood sample.

The ROS concentration is expressed using the free oxygen radical test (FORT) units (UF), one UF is approximately equal to 0.26 mg/L.^[13]

A volume of 20 μl of whole blood was drawn at the morning, after an overnight fasting and before the assumption of any other medications. The blood samples were allowed to clot for 30 min, and then centrifuged at room temperature for 10 min. Finally, the samples were stored at -20°C until the time of assay. The results obtained were expressed in FORT unit.^[14]

The patients did not modify their diabetic therapy and dietary habits, during the course of the study. HbA1c was periodically monitored as an index of glycemic control.

Statistical analysis

Data are expressed as means ± standard deviation. The normality of distribution for each variable was analyzed using Shapiro-Wilk test. Repeated-measures analysis of variance (ANOVA) over the 3 times points (baseline, 3 and 6 months) and Bonferroni correction for multiple outcomes were used to determine whether any differences appeared in best-corrected visual acuity (BCVA) expressed as logMAR unit. The differences between groups were calculated using a 1-tailed unpaired *t*-test or Mann-Whitney U-test (nonnormal distribution, Shapiro-Wilk test *P* < 0.05). The Wilcoxon signed-rank and the Friedman tests were used to assess the changes over time when data were not normally distributed. Spearman's rank correlation was calculated for comparisons. Intraclass correlation (ICCs) were computed to estimate the consistency when the same eye is evaluated multiple times with SD-OCT. Statistical significance was set at *P* < 0.05. All calculations were carried out with the use of SPSS statistical software (version 19; SPSS, Inc., Chicago, IL, USA).

Results

The baseline characteristics of the subjects are summarized in Table 1.

None of the patients were lost to follow-up or discontinued intervention.

Table 1: Comparison of baseline characteristics between patients with (Group A) and without (Group B) antioxidant supplementation therapy

Characteristics	34 patients		<i>P</i>
	Group A	Group B	
Age (years)			
Mean±SD	58.29±12.37	62.29±11.54	0.08 ^a
Gender, <i>n</i> (%)			
Male	15	18	0.47 ^b
Female	19	16	
Duration of diabetes (years)			
Mean±SD	9.2±2.3	8.9±2.5	0.38 ^c
HbA1C (%)			
Mean±SD	5.8±1.21	5.6±1.13	0.42 ^c

^aUnpaired Student's *t*-test, ^bChi-square test, ^cMann-Whitney test. SD: Standard deviation

In Group A, 3 patients at first follow-up time (8.82%, mean time: 7.33 ± 2.51 days) and 5 patients at second follow-up (14.70%, mean time: 6.8 ± 2.77 days) have delayed their visit. Instead, four patients at first follow-up time (11.76%, mean time: 5 ± 4.08 days) and four patients at second follow-up time (11.76%, mean time: 5.25 ± 1.70 days) have delayed the visit in the Group B.

Mean BCVA was 0.026 ± 0.032 logMAR at baseline, 0.030 ± 0.032 logMAR at T1 and 0.034 ± 0.033 logMAR at T2 in the Group A (ANOVA, $F=0.50$, $P=0.60$). Moreover, mean BCVA was 0.030 ± 0.036 logMAR at baseline, 0.033 ± 0.035 logMAR at T1 and 0.037 ± 0.036 logMAR at T2 in the Group B (ANOVA, $P=0.29$, $P=0.74$).

Free oxygen radical test levels were significantly decreased over 3 times points in patients under antioxidant therapy, whereas significantly increased in the control group. In Group A between baseline and T1 there was the greatest reduction of free oxygen radical levels (60.11 UF, 95% IC [31.51, 88.71], $P < 0.001$ and 0.44 mmol/L H_2O_2 , 95% IC [0.22, 0.66], $P < 0.001$). Instead in Group B the levels of free oxygen radicals tended to increase between T1 and T2 (31.47 UF, 95% confidence intervals [CI] [-64.09, 1.15], $P < 0.001$ and 0.91 mmol/L H_2O_2 , 95% IC [-4.67, 6.49], $P < 0.001$) [Table 2 and Fig. 1].

In Group A, CMT was significantly reduced over 3 times points, whereas no significant changes were found in Group B. The improvement of CMT was greater at T1–T2 time interval (-15.44 μ m, [95% CI: 3.26, 27.61], $P=0.01$), than baseline/T1 (-8.02 μ m, [95% CI: -0.29 , 16.35], $P=0.05$) [Table 2 and Fig. 1]. CMT measurements using SD-OCT, showed an almost perfect level of consistency of the ICC coefficient (Group A, ICC: 0.96, 95% CI: 0.91 – 0.98, $P < 0.01$; Group B, ICC: 0.97, 95% CI: 0.95, 0.98, $P < 0.01$) for each group over time.

No significant correlations were found between the levels of FORT and the mean CMT (T0: $R=0.03$, $P=0.82$; T1: $R=0.04$, $P=0.78$; T2: $R=0.01$, $P=0.93$).

The DRT subgroups included 8 patients (8 eyes) of Group A (54 ± 9.68 years) and 7 patients (7 eyes) of Group B (64.28 ± 8.07 years). In the DRT patients under antioxidant therapy, the FORT levels were significantly reduced over time, but not between T1 and T2 ($z=-0.95$, $P=0.34$), whereas CMT was also reduced over time but not between T0 and T1 ($z=-0.41$, $P=0.68$). In the control group, FORT levels have increased, and CMT has not significantly change over time [Table 3].

The wDRT subgroups consisted of 26 patients (26 eyes) (54.24 ± 14.72 years) of the Group A and 27 eyes of 27 patients (61.77 ± 12.36 years) of the Group B. In the wDRT

Table 2: Outcome variables for the study groups over 3 times points

Variables	n=34 eyes					
	Group A			Group B		
	Baseline	3 months	6 months	Baseline	3 months	6 months
FORT-UF	349.88	289.76	259.05	330.41	345.64	377.11
SD	131.72	99.61	47.33	119.44	133.75	119.14
P^a		<0.001			<0.001	
FORT mmol/L H_2O_2	2.64	2.20	1.96	2.50	2.61	2.81
SD	0.99	0.75	0.35	0.91	1.02	0.92
P^a		<0.001			<0.001	
CMTs- μ m	223.97	215.94	200.50	209.35	210.35	209.44
SD	73.95	76.91	56.73	56.97	60.49	56.47
P^a		<0.001			0.81	

All the values are: Means \pm SD. ^aFriedman test. UF: FORT units, CMTs: Central macular thickness, SD: Standard deviation, FORT: Free oxygen radical test

Table 3: DRT subgroup analysis, both in antioxidant supplementation (Group A) and control group (Group B) over time

DRT variables	n=34 eyes					
	Group A			Group B		
	Baseline	3 months	6 months	Baseline	3 months	6 months
FORT-UF	336.11	292	259	295.71	349.42	326.28
SD	112.97	128.83	54.70	139.28	173.07	123.42
P^a		0.001			0.01	
FORT mmol/L H_2O_2	2.55	2.23	1.96	2.24	2.64	2.47
SD	0.85	0.97	0.41	1.05	1.32	0.94
P^a		0.001			0.01	
CMTs- μ m	323.33	320.55	273	301.57	300.71	293.71
SD	75.52	81.61	67.42	63.32	82.14	68.85
P^a		0.003			0.65	

UF: FORT units, CMTs: Central macular thickness, SD: Standard deviation, FORT: Free oxygen radical test, DRT: Diffuse retinal thickening, ^aFriedman test

patients receiving antioxidant therapy both levels of free oxygen radicals and CMT were significantly improved over time, whereas in the control subgroup the levels of free oxygen radicals significantly increased and the CMT did not change over time [Table 4, Figs. 2 and 3].

Discussion

In the present study, we have evaluated the efficacy of antioxidant dietary supplementation composed by pycnogenol, Vitamin E and CoQ in reducing the levels of ROS and the effect on retinal thickness.

The efficacy of oral antioxidant supplements is still unclear. Several studies have shown that antioxidant treatment could ameliorate endothelial cell dysfunction in diabetic patients.^[7,15]

Experimental studies suggest that Vitamin E seems to be effective in prevents the development and progression of diabetic complications. Its action consists in lowering ROS concentration, by decreasing lipid peroxidation with less effect on protein and DNA oxidation.^[16,17] The concentration of Vitamin E is below standard limits in patients with type 2 diabetes. Vitamin E supplementation was found to reduce glycated hemoglobin both in type 1 and 2 diabetes, especially

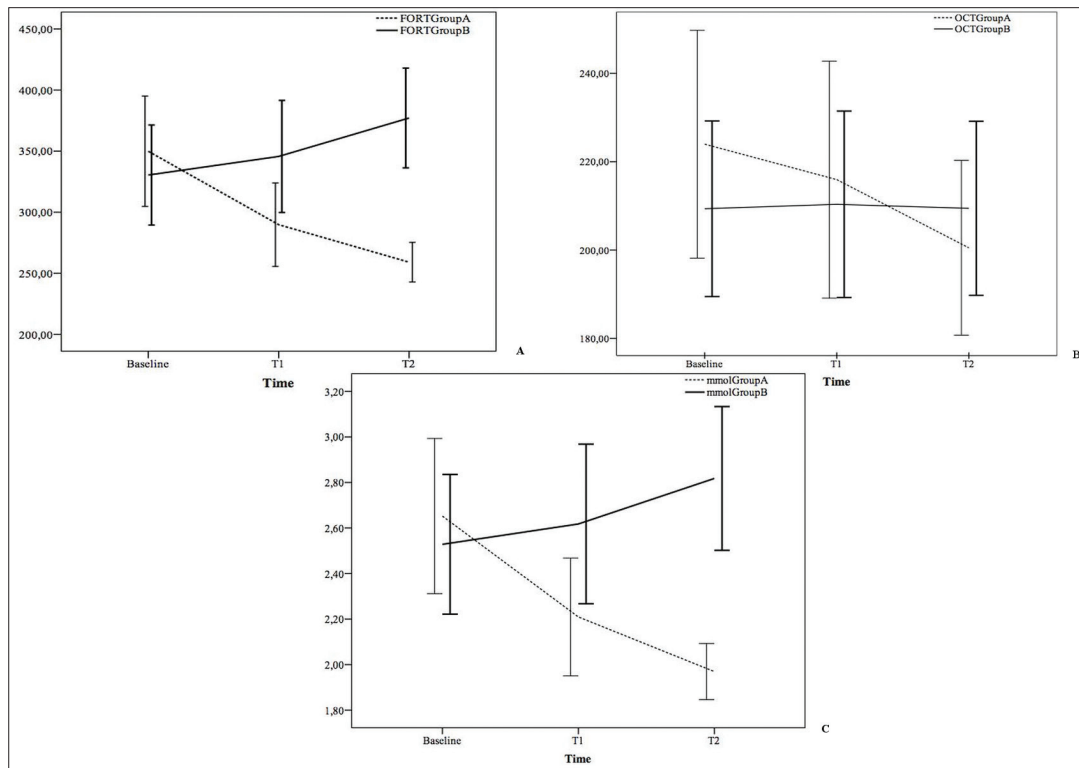


Figure 1: Linear graphs. Graph A shows free oxygen radical test (FORT) levels in the Group A (dashed line) and Group B (continuous line) at baseline (T0) 3 months (T1) and 6-month (T2); Graph B shows the changes in central macular thickness (m) in the Group A (dashed line) and in the Group B (continuous line) at 3 times points (T0, T1, T2). Graph C shows FORT levels reported as mmol/L in the Group A (dashed line) and Group B (continuous line) at 3 times points

Table 4: wDRT subgroups analysis over 3 times points in both study groups

wDRT variables	n=34 eyes					
	Group A			Group B		
	Baseline	3 months	6 months	Baseline	3 months	6 months
FORT-UF	354.84	288.96	259.08	339.40	344.66	390.29
SD	139.66	90.05	45.63	114.99	125.66	116.72
P ^a		0.009			0.009	
FORT mmol/L H ₂ O ₂	2.68	2.20	1.97	2.57	2.61	2.90
SD	1.05	0.68	0.34	0.87	0.95	0.91
P ^a		0.004			<0.001	
CMTs- μ m	188	178	174	185.44	186.92	187.59
SD	24.14	18.22	15.16	17.66	17.85	23.35
P ^a		<0.001			0.61	

All the values are: Means \pm SD. ^aFriedman test. wDRT: Without diffuse retinal thickening, UF: FORT units, CMTs: Central macular thickness, SD: Standard deviation, FORT: Free oxygen radical test

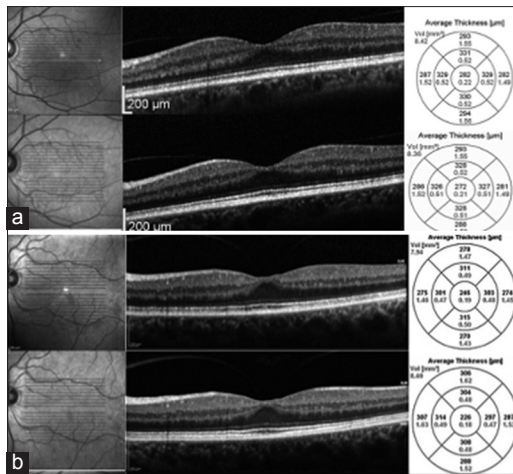


Figure 2: Spectral domain optical coherence tomography cross-sectional scan and average thickness map of Group A patients: (a) Without diffuse retinal thickening (DRT) before (upper side) and 6-month (lower side) after the assumption of antioxidant supplement; (b) patient with DRT before and after the assumption of antioxidant supplement

in patients with poor glycated hemoglobin control and low levels of Vitamin E.^[18-20]

Pycnogenol is a natural pine bark extract with strong antioxidant and hypoglycemic properties.^[21] Therefore, it is also shown to have positive effects on diabetic microangiopathy and diabetic neuropathy.^[22,23]

Coenzyme Q10 is a lipid-soluble molecule derived mainly from endogenous synthesis. It plays an essential role as an electron carrier in mitochondrial oxidative phosphorylation.^[24,25] Recent studies have demonstrated that CoQ10 improves endothelial function in patients with cardiovascular disease, diabetes type 2 and in the experimental model of diabetic nephropathy. CoQ might reduce oxidative stress via effects on the mitochondrial respiratory chain or via recoupling endothelial nitric oxide synthase.^[26-28]

Our results show that, in the group receiving antioxidant therapy the levels of free oxygen radicals and retinal thickness were significantly reduced over 3 times points. Conversely, in the control group were observed a significant increase of oxidative stress parameters and retinal thickness remained essentially unchanged over time.

Our findings suggest that antioxidant supplement may improve morphological damage (CMT). Indeed, as reported in the literature, ROS promotes breakdown of blood-retinal barrier and alters retinal blood flow by modulating the production of vasoactive factors, and also upregulates the retinal expression of VEGF and adhesion molecules as ICAM-1. This cascade of molecular events causes leakage of fluids into the surrounding tissue, which initially accumulate within Müller cells. These morphological alterations precede the CSME, and they are quantifiable by CMT measurement and define the DRT pattern.^[6-8,12,29]

In our opinion, the reduction of the ROS levels lead downregulation of the growth factors, adhesion molecules, and vasoactive substances and consequently, reduction of vascular leakage. This is morphologically expressed by the CMT reduction that in our study was highly significant in patients who had taken antioxidant supplement.

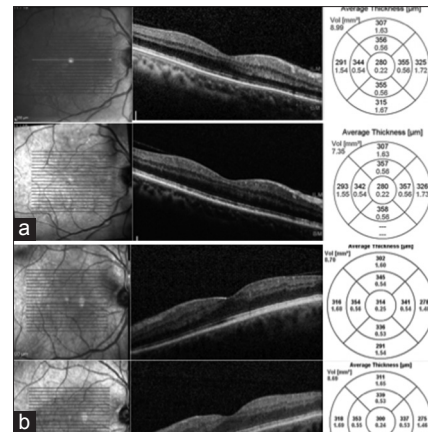


Figure 3: Spectral domain optical coherence tomography cross-sectional scan and average thickness map of Group B patients: (a) Without diffuse retinal thickening (DRT) at baseline (upper side) and 6-month (lower side) of follow-up (b) patient with DRT at baseline (upper side) and 6-month (lower side) of follow-up

In the subgroup analysis (Group A), the wDRT patients also showed FORT levels and CMT significantly reduced over 3 times points.

However, in the DRT subgroup, FORT levels were significantly reduced in the first 3 months and remained stable over the next months. Instead, the CMT reduction needed over 3 months to be significant. Probably, in patients with more advanced morphological damage (DRT) 3–6 months is the range time necessary to produce a morphological improvement (CMT lowering). This occurs only after the normalization of ROS levels and the other factors.

This result is confirmed by previous experimental study showing that antioxidant supplementation significantly decreases the severity of morphological changes in the RD damage after 5 months of administration.^[15]

Finally, in our opinion, the measurement of ROS by FORT technique is simple, fast and affordable as reported in previous studies, which assesses oxidative stress in patients with type 2 diabetes, cardiovascular diseases such as myocardial infarction, cancer, and other diseases.^[13,14,30-32]

Conversely, the indirect measure of ROS was considered studying the effects of substances involved in the production or elimination of these species using direct chemiluminescence and either direct or spin-trap electron paramagnetic resonance spectroscopy. A number of reviews have described these methods, their logistical constraints, and their use in the measurement of ROS.^[33,34]

There are some limitations in this study as the small number of the sample and the lack of data about the levels of ROS in the vitreous.

To our knowledge, this is the first study that reports the reduction of ROS in NPDR patients and its influence on retinal thickness.

In our opinion, antioxidant supplements can be used as a complementary therapy alongside traditional medical care, to prevent microvascular diabetic complications.

Further studies are needed to evaluate the efficacy of antioxidant supplements in larger groups of patients, and

also in patients with PDR. Moreover, a long-term follow-up is necessary to assess the optimal duration of treatment.

References

- Brownlee M. Biochemistry and molecular cell biology of diabetic complications. *Nature* 2001;414:813-20.
- Goldin A, Beckman JA, Schmidt AM, Creager MA. Advanced glycation end products: Sparking the development of diabetic vascular injury. *Circulation* 2006;114:597-605.
- Modak M, Dixit P, Londhe J, Ghaskadbi S, Devasagayam TP. Indian herbs and herbal drugs used for the treatment of diabetes. *J Clin Biochem Nutr* 2007;40:163-73.
- Khan V, Najmi AK, Akhtar M, Aqil M, Mujeeb M, Pillai KK. A pharmacological appraisal of medicinal plants with antidiabetic potential. *J Pharm Bioallied Sci* 2012;4:27-42.
- Yang Y, Hayden MR, Sowers S, Bagree SV, Sowers JR. Retinal redox stress and remodeling in cardiometabolic syndrome and diabetes. *Oxid Med Cell Longev* 2010;3:392-403.
- Sun J, Xu Y, Sun S, Sun Y, Wang X. Intermittent high glucose enhances cell proliferation and VEGF expression in retinal endothelial cells: The role of mitochondrial reactive oxygen species. *Mol Cell Biochem* 2010;343:27-35.
- Mancino R, Di Pierro D, Varesi C, Cerulli A, Feraco A, Cedrone C, *et al.* Lipid peroxidation and total antioxidant capacity in vitreous, aqueous humor, and blood samples from patients with diabetic retinopathy. *Mol Vis* 2011;17:1298-304.
- Pan HZ, Zhang H, Chang D, Li H, Sui H. The change of oxidative stress products in diabetes mellitus and diabetic retinopathy. *Br J Ophthalmol* 2008;92:548-51.
- Yamagishi S, Maeda S, Matsui T, Ueda S, Fukami K, Okuda S. Role of advanced glycation end products (AGEs) and oxidative stress in vascular complications in diabetes. *Biochim Biophys Acta* 2012;1820:663-71.
- Hee MR, Puliafito CA, Duker JS, Reichel E, Coker JG, Wilkins JR, *et al.* Topography of diabetic macular edema with optical coherence tomography. *Ophthalmology* 1998;105:360-70.
- Early Treatment Diabetic Retinopathy Study design and baseline patient characteristics. ETDRS report number 7. *Ophthalmology* 1991;98:741-56.
- Kim BY, Smith SD, Kaiser PK. Optical coherence tomographic patterns of diabetic macular edema. *Am J Ophthalmol* 2006;142:405-12.
- Pavlatou MG, Papastamataki M, Apostolou F, Papassotiriou I, Tentolouris N. FORT and FORD: Two simple and rapid assays in the evaluation of oxidative stress in patients with type 2 diabetes mellitus. *Metabolism* 2009;58:1657-62.
- Lorgis L, Zeller M, Dentan G, Sicard P, Richard C, Buffet P, *et al.* The free oxygen radicals test (FORT) to assess circulating oxidative stress in patients with acute myocardial infarction. *Atherosclerosis* 2010;213:616-21.
- Zhu Y, Zhang XL, Zhu BF, Ding YN. Effect of antioxidant N-acetylcysteine on diabetic retinopathy and expression of VEGF and ICAM-1 from retinal blood vessels of diabetic rats. *Mol Biol Rep* 2012;39:3727-35.
- Pazdro R, Burgess JR. The role of vitamin E and oxidative stress in diabetes complications. *Mech Ageing Dev* 2010;131:276-86.
- Baburao Jain A, Anand Jain V. Vitamin E, its beneficial role in diabetes mellitus (DM) and its complications. *J Clin Diagn Res* 2012;6:1624-8.
- Ceriello A, Giugliano D, Quatraro A, Donzella C, Dipalo G, Lefebvre PJ. Vitamin E reduction of protein glycosylation in diabetes. New prospect for prevention of diabetic complications? *Diabetes Care* 1991;14:68-72.
- Gökkusu C, Palanduz S, Ademoglu E, Tamer S. Oxidant and antioxidant systems in niddm patients: Influence of vitamin E supplementation. *Endocr Res* 2001;27:377-86.
- Suksomboon N, Poolsup N, Sinprasert S. Effects of vitamin E supplementation on glycaemic control in type 2 diabetes: Systematic review of randomized controlled trials. *J Clin Pharm Ther* 2011;36:53-63.
- Packer L, Rimbach G, Virgili F. Antioxidant activity and biologic properties of a procyanidin-rich extract from pine (*Pinus maritima*) bark, pycnogenol. *Free Radic Biol Med* 1999;27:704-24.
- Cesarone MR, Belcaro G, Rohdewald P, Pellegrini L, Ledda A, Vinciguerra G, *et al.* Improvement of diabetic microangiopathy with pycnogenol: A prospective, controlled study. *Angiology* 2006;57:431-6.
- Jankyova S, Kucera P, Goldenberg Z, Yaghi D, Navarova J, Kyselova Z, *et al.* Pycnogenol efficiency on glycaemia, motor nerve conduction velocity and markers of oxidative stress in mild type diabetes in rats. *Phytother Res* 2009;23:1169-74.
- Overvad K, Diamant B, Holm L, Holmer G, Mortensen SA, Stender S. Coenzyme Q10 in health and disease. *Eur J Clin Nutr* 1999;53:764-70.
- Littarru GP, Langsjoen P. Coenzyme Q10 and statins: Biochemical and clinical implications. *Mitochondrion* 2007;7 Suppl: S168-74.
- Hamilton SJ, Chew GT, Watts GF. Coenzyme Q10 improves endothelial dysfunction in statin-treated type 2 diabetic patients. *Diabetes Care* 2009;32:810-2.
- Gao L, Mao Q, Cao J, Wang Y, Zhou X, Fan L. Effects of coenzyme Q10 on vascular endothelial function in humans: A meta-analysis of randomized controlled trials. *Atherosclerosis* 2012;221:311-6.
- Sourris KC, Harcourt BE, Tang PH, Morley AL, Huynh K, Penfold SA, *et al.* Ubiquinone (coenzyme Q10) prevents renal mitochondrial dysfunction in an experimental model of type 2 diabetes. *Free Radic Biol Med* 2012;52:716-23.
- Choudhuri S, Dutta D, Sen A, Chowdhury IH, Mitra B, Mondal LK, *et al.* Role of N^e-carboxy methyl lysine, advanced glycation end products and reactive oxygen species for the development of nonproliferative and proliferative retinopathy in type 2 diabetes mellitus. *Mol Vis* 2013;19:100-13.
- Abramson JL, Hooper WC, Jones DP, Ashfaq S, Rhodes SD, Weintraub WS, *et al.* Association between novel oxidative stress markers and C-reactive protein among adults without clinical coronary heart disease. *Atherosclerosis* 2005;178:115-21.
- Mantovani G, Madeddu C, Macciò A, Gramignano G, Lusso MR, Massa E, *et al.* Cancer-related anorexia/cachexia syndrome and oxidative stress: An innovative approach beyond current treatment. *Cancer Epidemiol Biomarkers Prev* 2004;13:1651-9.
- Gizi A, Papassotiriou I, Apostolou F, Lazaropoulou C, Papastamataki M, Kanavaki I, *et al.* Assessment of oxidative stress in patients with sickle cell disease: The glutathione system and the oxidant-antioxidant status. *Blood Cells Mol Dis* 2011;46:220-5.
- Vergely C, Maupoil V, Clermont G, Bril A, Rochette L. Identification and quantification of free radicals during myocardial ischemia and reperfusion using electron paramagnetic resonance spectroscopy. *Arch Biochem Biophys* 2003;420:209-16.
- Tarpey MM, Wink DA, Grisham MB. Methods for detection of reactive metabolites of oxygen and nitrogen: *In vitro* and *in vivo* considerations. *Am J Physiol Regul Integr Comp Physiol* 2004;286:R431-44.

Cite this article as: Domanico D, Fragiotta S, Cutini A, Carnevale C, Zompatori L, Vingolo EM. Circulating levels of reactive oxygen species in patients with nonproliferative diabetic retinopathy and the influence of antioxidant supplementation: 6-month follow-up. *Indian J Ophthalmol* 2015;63:9-14.

Source of Support: Nil. **Conflict of Interest:** None declared.