

Review Article



Clinical Pearls of Venoarterial Extracorporeal Membrane Oxygenation for Cardiogenic Shock

Min Suk Choi , MD¹, Kiick Sung , MD, PhD², and Yang Hyun Cho , MD, PhD²

¹Department of Thoracic and Cardiovascular Surgery, Dongguk University Ilsan Hospital, Dongguk University School of Medicine, Goyang, Korea

²Department of Thoracic and Cardiovascular Surgery, Samsung Medical Center, Sungkyunkwan University School of Medicine, Seoul, Korea



Received: Jun 20, 2019

Accepted: Jun 24, 2019

Correspondence to

Yang Hyun Cho, MD, PhD

Department of Thoracic and Cardiovascular Surgery, Samsung Medical Center, Sungkyunkwan University School of Medicine, 81, Irwon-ro, Gangnam-gu, Seoul 06351, Korea.
E-mail: yanghyun.cho@samsung.com

Copyright © 2019. The Korean Society of Cardiology

This is an Open Access article distributed under the terms of the Creative Commons Attribution Non-Commercial License (<https://creativecommons.org/licenses/by-nc/4.0>) which permits unrestricted noncommercial use, distribution, and reproduction in any medium, provided the original work is properly cited.

ORCID iDs

Min Suk Choi

<https://orcid.org/0000-0002-5482-1272>

Kiick Sung

<https://orcid.org/0000-0003-0768-9587>

Yang Hyun Cho

<https://orcid.org/0000-0003-1685-3641>

Conflict of Interest

The authors have no financial conflicts of interest.

Author Contributions

Conceptualization: Sung K; Methodology: Cho YH; Project administration: Cho YH; Supervision: Sung K, Cho YH; Writing - original draft: Choi MS; Writing - review & editing: Cho YH.

ABSTRACT

Extracorporeal membrane oxygenation (ECMO) is a technique that uses a pump to drain blood from a body, circulate blood through a membrane lung, and return the oxygenated blood back into the body. Venoarterial (VA) ECMO is a simplified version of the heart-lung machine that assists native pulmonary and/or cardiac function. VA ECMO is composed of a drainage cannula in the venous system and a return cannula in the arterial system. Because VA ECMO can increase tissue perfusion by increasing the arterial blood flow, it is used to treat medically refractory cardiogenic shock or cardiac arrest. VA ECMO has a distinct physiology that is referred to as differential flows. It can cause several complications such as left ventricular distension with pulmonary edema, distal limb ischemia, bleeding, and thromboembolism. Physicians who are using this technology should be knowledgeable on the prevention and management of these complications. We review the basic physiology of VA ECMO, the mechanism of complications, and the simple management of VA ECMO.

Keywords: Extracorporeal membrane oxygenation; Physiology; Shock; Postoperative complications

INTRODUCTION

The first human use of cardiopulmonary bypass in the operating room was in 1953 to assist in the repair of an atrial septal defect, and it was performed by John Gibbon, MD. In 1954, C. Walton Lillehei, MD performed cardiac surgery using a bubble oxygenator. In 1957, Kammermeyer found that silicone rubber was strong enough to withstand hydrostatic pressure, yet it was permeable to gas transfer. With the development of a silicone membrane oxygenator, a device used for long-term bypass support that allowed recovery outside the operating room was created. Hence, the use of the silicone membrane oxygenator led to the use of the term extracorporeal membrane oxygenation (ECMO).¹⁾

The basic ECMO circuit includes cannulae for drainage and return, tubing, a pump, and a membrane lung. Venoarterial (VA) ECMO withdraws deoxygenated blood from the venous system through a drainage cannula, pumps the blood through a membrane lung, and returns

the blood to the arterial circulation through a return cannula. The blood flow through VA ECMO always bypasses the native cardiopulmonary system (**Figure 1**).

A membrane lung, also called as an oxygenator, is composed of hollow fiber bundles. An exchange of gas inside the hollow fibers and blood circulating outside the fibers occurs through the membrane of the hollow fibers. A membrane lung has been developed to maximize the blood-gas contact surface.²⁾ Microporous polypropylene membrane has limitation in terms of longevity.³⁾ Compressed surface polymers such as polymethylpentene (PMP) have been available since the early 2000s. It is also microporous, but its outer surface is compressed to form a solid-like membrane. Gas can still be entrained across the PMP material into the blood based on the principle of diffusion, but the plasma has difficulty in passing through the membrane because the micropores are covered with a solid-like membrane.⁴⁾ These compressed surface PMP hollow fibers still exchange gas as efficiently as the microporous polypropylenes and have longer longevity.

Pumps are divided into the following 2 basic subgroups: a roller pump and a centrifugal pump. The earliest circuits used a roller pump, which had the risk of line rupture. Therefore, it was dangerous when used outside the operating room. Because a centrifugal pump rarely causes such a catastrophe, most centers use it as a standard pump for ECMO. Centrifugal pumps generate flow by a spinning rotor that produces centrifugal force. The pump has been developed to decrease heat generation, sheer stress, hemolysis, or thrombosis. Recently, 3 kinds of pump according to the types of bearing are used. The first-generation centrifugal pumps have fixed strut and metal bearing. Because it frequently causes thrombosis around the bearing within a few days, it is not widely used for ECMO. Favored centrifugal pumps for ECMO have either pivot-bearing or a bearing-free magnetic levitation designs.²⁾

PHYSIOLOGY OF VENOARTERIAL EXTRACORPOREAL MEMBRANE OXYGENATION

The ratio of oxygen delivery to consumption

Bartlett and Conrad⁵⁾ SA explained the ratio logically. Oxygen delivery (DO_2) is the amount of oxygen delivered to the peripheral tissues per minute, or the product of arterial oxygen content (CO_2) times the cardiac output. Oxygen is present in the blood as oxygen dissolved in the plasma and bound to hemoglobin present in the red blood cells. The following are the mathematical formulas to calculate DO_2 in a patient on ECMO.

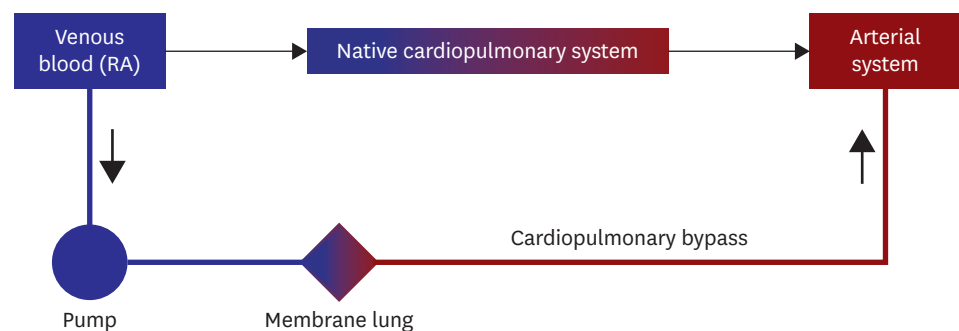


Figure 1. Schematic configuration of VA ECMO. The principal physiology of VA extracorporeal oxygenation of cardiopulmonary bypass.

ECMO = extracorporeal membrane oxygenation; RA = right atrium; VA = venoarterial.

$$\text{DO}_2 \text{ (cc/min)}$$

$$= \text{Cardiac output (L/min)} \times \text{arterial CO}_2 \text{ (cc/dL)} \times 10$$

$$\text{CO}_2 \text{ (cc/dL)}$$

$$= \text{Hemoglobin bound O}_2 + \text{dissolved O}_2$$

$$= (\text{Hemoglobin [g/dL]} \times \text{saturation [\%]} \times 1.36 \text{ cc/g}) + (\text{pO}_2 \text{ [mmHg]} \times 0.0031 \text{ cc/mmHg/dL})$$

$$\text{DO}_2 \text{ during VA ECMO}$$

$$= \text{Native cardiac output} \times \text{arterial CO}_2 + \text{ECMO flow} \times \text{perfusate CO}_2$$

If we take a closer look at the formula, DO_2 is controlled by cardiac output, hemoglobin concentration, hemoglobin saturation, and dissolved oxygen, in that order. Therefore, if DO_2 is insufficient, it is necessary to calibrate it in the above order to efficiently increase DO_2 .

Oxygen consumption (VO_2) is controlled by tissue metabolism. The normal $\text{DO}_2:\text{VO}_2$ ratio is 5:1. Mixed venous oxygen saturation (SvO_2) results from this ratio. If systemic DO_2 is moderately decreased and there is no change in VO_2 , the amount of oxygen extracted from each deciliter of arterial blood is greater. This results in decreased SvO_2 . If DO_2 is severely decreased, there is insufficient oxygen to meet metabolic demands, anaerobic metabolism occurs, and, finally, lactic acidosis and shock occur. In practice, this situation occurs when the $\text{DO}_2:\text{VO}_2$ ratio is less than 2:1. Therefore, the overall goal of management is to keep DO_2 at least twice the VO_2 , and preferably 5 times the VO_2 . Since SvO_2 reflects this ratio accurately, it is one of the most important considerations when monitoring and managing critically ill patients.

ECMO is indicated when other treatment modalities cannot sustain the $\text{DO}_2:\text{VO}_2$ ratio. If $\text{DO}_2:\text{VO}_2$ ratio decreases due to decreased DO_2 in cardiogenic shock, ECMO can increase systemic blood flow to replace the reduced cardiac output. Cardiogenic and obstructive shock reduces not only the cardiac output but also CO_2 in the blood due to ventilation-perfusion mismatch. ECMO can correct both the decreased cardiac output and CO_2 . In septic shock, $\text{DO}_2:\text{VO}_2$ ratio decreases due to the increase in VO_2 . Moreover, if the septic shock is combined with decreased cardiac contractility, DO_2 is decreased, further reducing $\text{DO}_2:\text{VO}_2$ ratio, hence, ECMO may be considered.

To summarize, VA ECMO can be an option for the treatment of various types of shock because it can increase CO_2 and systemic blood flow and eventually increase DO_2 . Hence, the goal of VA ECMO is as follows: to restore organ blood flow and adequate tissue oxygenation while awaiting recovery, without damaging to the lungs or circulation.⁶⁾

Interaction between the native cardiovascular system and venoarterial extracorporeal membrane oxygenation

The important basic pressure-volume loop of left ventricle (LV) are shown in **Figure 2A**. The loop changes as cardiogenic shock occurs (**Figure 2B**). In the beginning, the stroke volume and the left ventricular end-systolic pressure (LVESP) decrease. Left ventricular end-diastolic pressure (LVEDP) or left ventricular end-diastolic volume (LVEDV) can be increased secondarily but not greatly in a short time. As the cardiogenic shock develops some more, LVEDP and LVEDV begin to increase, maintaining some linear correlation. If the cardiac shock persists, LVEDV increases, but LVEDP increases furthermore. Subtle increases in LVEDV can be associated with substantial increases in LVEDP due to the nonlinear end-diastolic pressure-volume relationship.⁷⁾

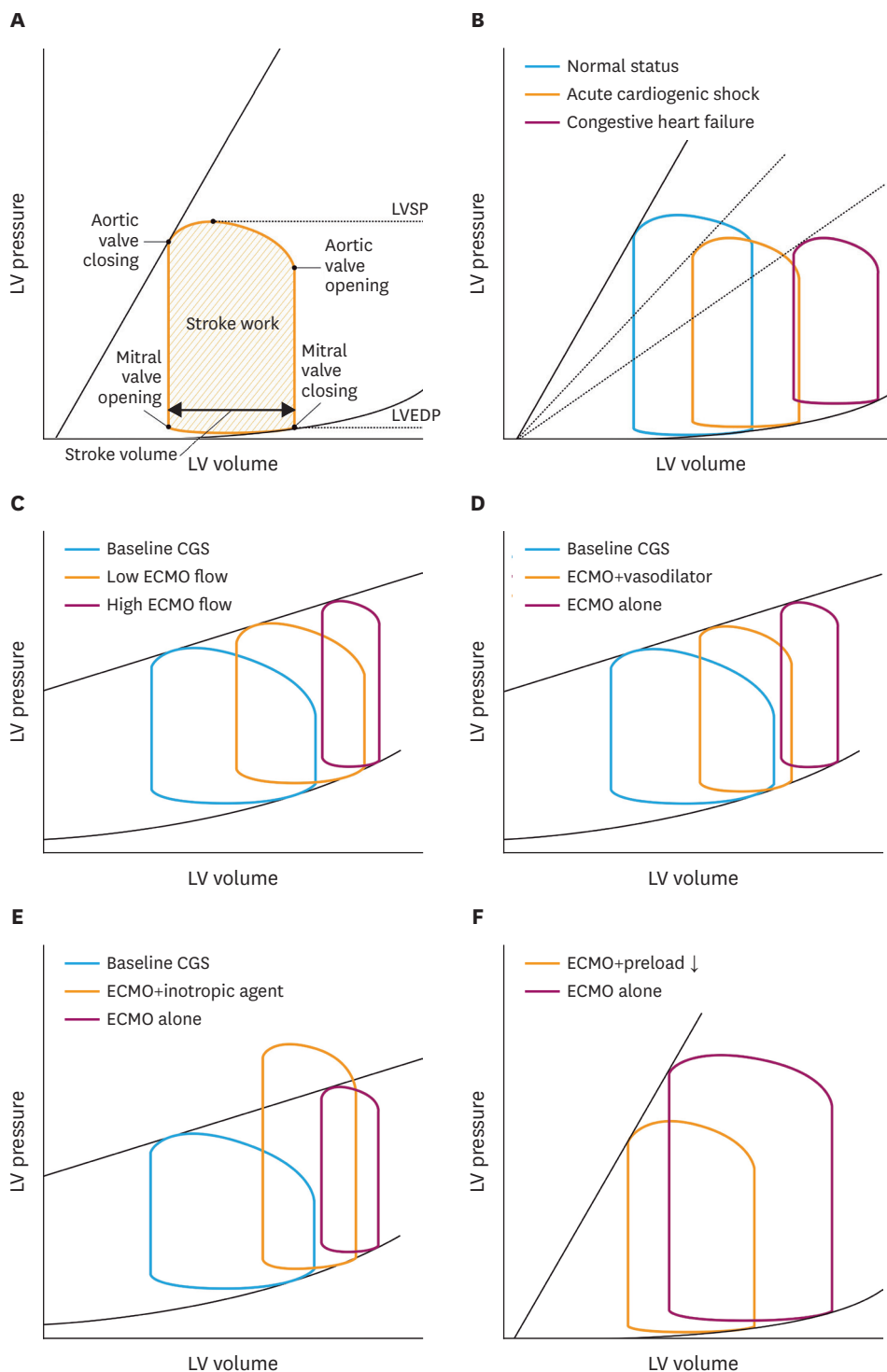


Figure 2. Pressure-volume loops before and after VA ECMO. (A) Normal pressure-volume loop. (B) Representative pressure-volume loop as heart failure persists and deteriorates. (C) Impact of ECMO flow during VA ECMO. (D) Impact of decreasing PVR during VA ECMO. (E) Impact of inotropic agent during VA ECMO. (F) Impact of decreasing preload during VA ECMO. Modified from Burkhoff et al.⁷⁾

CGS = cardiogenic shock; ECMO = extracorporeal membrane oxygenation; LV = left ventricle; LVEDP = left ventricular end-diastolic pressure; LVSP = left ventricular systolic pressure; PVR = peripheral vascular resistance; VA = venoarterial.

If VA ECMO is started in this state, the pulse pressure is decreased and the mean arterial pressure (MAP) is increased. The stroke volume decreased because the amount of native cardiopulmonary circulation decreases due to the physiology of ECMO called cardiopulmonary bypass.^{7,8)} Increasing the ECMO flow further reduces the stroke volume, increases the LV afterload, and increases the LVEDV and especially LVEDP as shown in the **Figure 2C**.⁷⁾

The increased LV end-diastolic, left atrial (LA), and pulmonary capillary wedge pressures during VA ECMO can be mitigated by decreases in systemic vascular resistance or improvement in ventricular contractility. First, the peripheral vascular resistance (PVR) can be decreased as shown in **Figure 2D**. PVR can be reduced naturally by the baroreceptors, pharmacologically (e.g., nitroprusside) or mechanically (e.g., by intra-aortic balloon pumping).⁷⁾ This increases stroke volume as well. Pharmacological enhancement of contractility is also possible, but may not be beneficial in cardiogenic shock due to their independent effects in increasing myocardial VO_2 and potential effects on heart rate and arrhythmias (**Figure 2E**).⁷⁾ Reducing the cardiac preload through volume restriction can also reduce LVEDP or LVEDV to some extent (**Figure 2F**).⁷⁾ Therefore, monitoring for an increase in LVEDP is important by performing serial physical examinations, chest radiographies, and echocardiographies and monitoring the pressures from Swan-Ganz catheter.⁹⁾

If the heart recovers, the pulse pressure and MAP increase. However, if it does not recover and it gets worse, the LVEDP and pulmonary capillary wedge pressure increase furthermore. These increases are detrimental to blood oxygen saturation coming from the lungs and markedly increase myocardial oxygen demand, which can worsen LV function, especially in acute myocardial ischemia or infarction.⁷⁾ In such cases, the left heart venting should be considered, which will be discussed later. The typical changes of ventricular loads or coronary perfusion during VA ECMO are summarized in **Table 1**. Based on these physiologic interactions between the native cardiovascular system and VA ECMO, we suggest minimizing dose of vasopressors (afterload reduction), fluid removal (preload reduction), and keeping a good amount of ECMO flow (adequate tissue oxygenation). This principle will let the native heart rest while balancing tissue oxygen supply and demand.

Table 1. The changes of ventricular loads and coronary perfusion during VA ECMO

	VA ECMO	Mechanism	Special situation
RV preload	Decreased	Cardiopulmonary bypass Direct drainage from RA	Mobilization of physiologically reserved venous blood volume may happen by increasing overall cardiac output.
RV afterload	Unpredictable	Multiple factors influence RV afterload such as pulmonary vasoconstriction, preload and afterload of LV, vasopressors, ventilator settings, and total volume status.	Increased LV afterload by VA ECMO may increase RV afterload. However, improved myocardial perfusion by ECMO can also reduce RV afterload by improved LV contraction.
LV preload	Decreased	Cardiopulmonary bypass Reduced pulmonary blood flow	Aortic regurgitation even in mild degree can dramatically increase LV afterload. Collateral circulation to pulmonary system varies.
LV afterload	Increased	Continuous flow Increased MAP	Reduction of MAP by the administration of vasodilators may reduce afterload while keeping high overall cardiac output.
Coronary perfusion	Generally increased	Increased MAP Reduced catecholamines	If LV diastolic pressure is too high by increased afterload, coronary perfusion may decrease.

ECMO = extracorporeal membrane oxygenation; LV = left ventricle; MAP = mean arterial pressure; RA = right atrium; RV = right ventricle; VA = venoarterial.

Harlequin syndrome

During VA ECMO, perfusate blood from ECMO mixes in the aorta with the LV blood, which has traversed the lungs. Hence, the content of oxygen and carbon dioxide in the patient's arterial blood represents a combination of blood from these 2 sources, and the total systemic blood flow is the sum of the extracorporeal flow plus the amount of blood passing through the heart and lungs.⁵⁾ Fully saturated blood from the ECMO circuit will meet the blood ejected from the native ventricle. The location of this mixing point, so called the watershed point, depends upon the amount of ECMO support provided and the degree of LV ejection. If there is extremely severe myocardial dysfunction, the mixing point will typically be in the proximal ascending aorta or aortic root. As myocardial function improves, the mixing point may migrate more distally into the descending thoracic aorta. The CO₂ of blood ejected by the LV depends on the gas exchange ability of the native lungs. If significant pulmonary edema is present, hypoxic blood may perfuse the proximal aortic branches, including the coronaries and the innominate artery. The patient's upper body will appear blue, while the lower body will appear pink.¹⁰⁾ This is the reason we call it Harlequin syndrome. The watershed point has been shown in computed tomography or fluoroscopic images in several reports.¹¹⁻¹⁴⁾ Therefore, measuring saturations in the right hand or analyzing arterial blood gases from the right arm is important (Figure 3).¹⁰⁾

INDICATIONS OF VENOARTERIAL EXTRACORPOREAL MEMBRANE OXYGENATION

Cardiogenic shock and cardiac arrest

The best indication of VA ECMO is a cardiogenic shock. Common causes of cardiogenic shock are acute myocardial infarction, acute myocarditis, progression of cardiomyopathy, acute allograft rejection after heart transplantation, overdose of cardiotoxic drugs, refractory

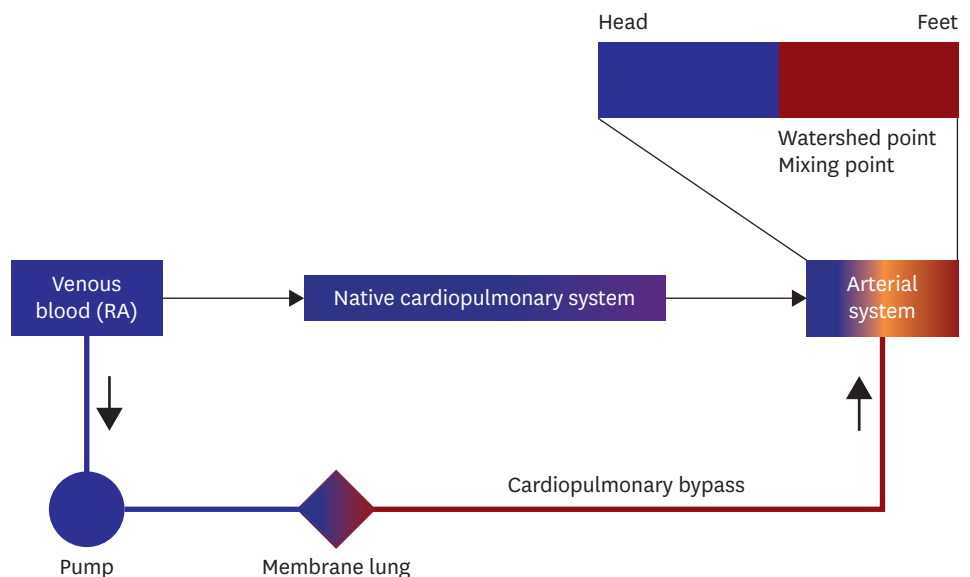


Figure 3. A simplified diagram showing the physiology of VA ECMO. Harlequin syndrome is common during VA ECMO. Patients on VA ECMO often have lung failure caused by pulmonary edema with preexisting cardiogenic shock, combined pneumonia, ventilation-perfusion mismatch, and pulmonary edema by left ventricular distension. If mixing point is distal to the aortic arch, patients are at risk of cerebral ischemia. ECMO = extracorporeal membrane oxygenation; RA = right atrium; VA = venoarterial.

ventricular tachycardia, failure to wean off cardiopulmonary bypass, or cardiac failure coexistent with severe respiratory dysfunction. Although the most important step for successful VA ECMO is correct diagnosis, the timing of application is also important. Medical refractoriness is practically difficult to define. Persistent hypotension (systolic blood pressure less than 80 mmHg), increase of lactate level, worsening metabolic acidosis, frequent non-sustained ventricular tachycardia or fibrillation, and requirement of other organ support devices such as dialysis or intra-aortic balloon pump (IABP) under high-dose inotrope or vasopressor infusion suggest the timing of VA ECMO.¹⁵⁾ It is very important to start VA ECMO before cardiac arrest. The outcome of VA ECMO before cardiac arrest is much better than that of extracorporeal cardiopulmonary resuscitation (ECPR). A common mistake in the intensive care unit is the reliance on blood pressure only in deciding the initiation of VA ECMO. The cause of cardiogenic shock, responsiveness of medical therapy, signs of organ hypoperfusion (drowsy mentality, agitation, dyspnea, cold skin, and poor urine output), and laboratory findings should be taken into consideration when making a decision to initiate VA ECMO.

ECPR is the application of rapid deployment of ECMO to provide circulatory support in patients under cardiac arrest who fail to achieve a sustained return of spontaneous circulation (ROSC).⁹⁾ Two studies of propensity score matching demonstrated the neurological or survival benefits of ECPR over conventional cardiopulmonary resuscitation (CPR).¹⁶⁾¹⁷⁾ Most practitioners would agree that the goal is to minimize the duration of cardiac arrest and advocate shorter periods of CPR as being optimal. The previous reports usually suggest that the duration of CPR before ECMO should be less than 30 minutes, not greater than 60 minutes.¹⁸⁻²⁰⁾ Commonly used inclusion criteria for ECPR are as follows⁹⁾: witnessed arrest,²¹⁾ bystander CPR initiation within 5 minutes, high-quality and uninterrupted CPR including end-tidal CO₂ more than 10 mmHg,²²⁾ failure to achieve ROSC within 15 minutes of CPR, initial rhythm of ventricular fibrillation or ventricular tachycardia, and age less than 70 years. Nevertheless, age greater than 70 years is not an exclusion criterion.²³⁾ The 2015 American Heart Association guidelines recommended that in settings where it can be rapidly implemented, ECPR may be considered for selected patients with cardiac arrest for whom the suspected etiology of the cardiac arrest is potentially reversible during a limited period of mechanical cardiorespiratory support.²²⁾

Pulmonary thromboembolism

Treatment of acute pulmonary thromboembolism (PTE) varies considerably depending on the amount of thrombus and vital signs. VA ECMO is useful in rapidly deteriorating vital signs such as cardiac arrest or refractory shock because of acute PTE, that is, massive PTE.²⁴⁻²⁸⁾ Moreover, if we consider the ECMO's physiology of partial cardiopulmonary bypass, VA ECMO is the most suitable device for the pathophysiology of right heart failure from PTE. After the patient becomes stable, the treatment for the thrombus should be selected among the following options: anticoagulation,²⁵⁾²⁹⁾ systemic thrombolysis,³⁰⁾ catheter-directed thrombectomy or thrombolysis,³¹⁾ or surgical embolectomy.²⁴⁾²⁶⁾ The European Society of Cardiology 2014 acute PTE guidelines briefly mention that ECMO can be used to treat massive PTE as a method for hemodynamic support and as an adjunct to surgical thrombectomy.³²⁾ Because VA ECMO itself requires systemic anticoagulation, VA ECMO with or without catheter-directed thrombectomy may cure acute PTE.³¹⁾ Thrombolysis, especially systemic thrombolysis, would be dangerous under VA ECMO. Authors have experienced severe uncontrollable cannulation site bleeding after thrombolysis.

Septic shock

Sepsis was historically regarded as a contraindication to ECMO.¹⁾ A number of studies demonstrated that it could be lifesaving in neonatal and pediatric septic shock.³³⁾ Therefore in neonates and children, ECMO has been established as a valid salvage therapy. However, the evidence of its benefits in adult patients is weak, particularly in cases of refractory septic shock.³⁴⁾ Controversies surrounding the benefits of ECMO in septic shock with a predominantly vasoplegic phenotype persist.³⁵⁾ Favorable outcomes of VA ECMO in patients with septic shock combined with heart failures have been reported for recent years.³⁶⁻³⁹⁾

When applying VA ECMO for septic shock, the central ECMO is often performed because vasoplegia requires a significant amount of ECMO flow. Central ECMO can insert the largest available cannulae directly into the right atrium and ascending aorta. MacLaren et al.³³⁾ reported that the central ECMO has been used in adult patients to achieve flows of up to 10 L/min with good outcomes. If the central ECMO is hesitant due to the bleeding risk, bilateral femoral cannulation can be considered.⁴⁰⁾ However, high-flow VA ECMO for septic shock does not seem to produce consistently favorable outcomes. We suggest using ECMO only when there are significant signs of combined cardiogenic shock such as high central venous pressure or pulmonary artery occlusion pressure.⁹⁾ A sepsis patient with low LV ejection fraction and multi-organ failure already in progress is inadequate to perform VA ECMO because cardiac failure may be a sign of imminent death.

CANNULATION, MANAGEMENT, AND COMPLICATIONS

Cannulation strategies

There are 2 principles in VA ECMO configurations. One is central and another is peripheral. Although there is no clear definition of central ECMO, it generally means that at least one of the venous or arterial cannulation sites is in the central vessels (vena cava, pulmonary artery, or aorta) or cardiac chambers. Peripheral ECMO is inserted only through the peripheral vessels. Most of the VA ECMO is cannulated peripherally. The Seldinger technique is usually used for cannulation. Cannulae can be inserted blindly. However, the vast majority of patients who require VA ECMO for cardiovascular reasons have weak pulsatility.⁴¹⁾ Therefore, ultrasound-guided cannulation or surgical exposure of the vessels is useful. Fluoroscopic-guided cannulation is also helpful in advancing the guidewire or cannula without vascular complications.²¹⁾

Peripheral cannulation entails drainage of the venous blood from the right atrium through a cannula that exits the femoral vein. Multistage cannula is usually inserted with its tip in the inferior vena cava, right atrium or superior vena cava. Less commonly, the right internal jugular vein may also be used. Typically, the arterial cannula is a short cannula inserted in the femoral artery with the tip in the common iliac artery. Alternatively, arterial blood can also be returned into the axillary or subclavian artery through a side graft or directly.⁴²⁾⁴³⁾

The main advantage of peripheral cannulation is its ease of cannulation. The cannulation is often performed bedside and can even be performed in patients undergoing CPR. Disadvantages include the occurrence of Harlequin syndrome, aortic root thrombus formation, LV distension, and lower extremity ischemia. Furthermore, femoral cannulation may not be feasible in patients with significant peripheral vascular disease.⁴⁴⁾

In some peripheral VA ECMO cases, an additional cannula can be inserted to make two kinds of triple cannulations. One is venovenous-arterial ECMO which refers to the insertion of an additional venous drainage cannula typically into the right internal jugular vein. This intends to improve drainage and unloading.⁴⁴⁾⁴⁵⁾ Another is veno-venoarterial or veno-arteriovenous ECMO which provides respiratory and circulatory support simultaneously. Part of the outflow is directed toward the right atrium. The relative flows of the 2 outflow limbs (arterial and oxygenated venous) are modulated using the adjustable clamps and flow sensors and must be carefully regulated as each change will impact preload, afterload, oxygenation, and location of the watershed.⁴⁵⁾

The configuration of the central ECMO was originated from the classical cannulation during cardiac surgery. However, recently, it is performed when obtaining higher ECMO flow is necessary or peripheral cannulation is impossible. The short, large-bore venous cannulae are used for greater cardiac decompression than in peripheral cannulation. Additionally, as oxygenated blood is returned to the ascending aorta, there is less concern for retrograde flow and Harlequin syndrome.⁴⁴⁾ In most ECMO centers, chest is kept closed after central VA ECMO. After recovery from the surgery, the patient may be able to move more liberally than peripheral cannulation. This can be a significant benefit to the patients who have to wait for recovery or transplantation for longer period such as several weeks. A key disadvantage of central cannulation is that it requires entering the chest for cannulation and decannulation. As such, central cannulation results in the increased risk of bleeding, surgical reexploration, and mediastinitis.⁴⁴⁾

Monitoring of adequate oxygen delivery

Flow of extracorporeal membrane oxygenation

In general, target flow rate for adults is 60 cc/kg/min.²⁾ However, it never means “full flow.” The real target flow should be whatever flow that is needed to promptly reverse shock and restore tissue oxygenation. Circuit flows should be goal-directed, targeting rapid normalization of lactate, improvement in SvO₂ >65%, and restoration of appropriate MAPs which is explained in the next paragraphs.⁶⁾

If the ECMO flow is insufficient, a correct cause should be differentiated from various ones such as ineffective circulating volume due to hypovolemia, pulmonary congestion or sepsis, problems in the drainage or return, or resistance in the ECMO circuit.

Blood pressure and pulsatility

ECMO provides continuous blood flow. Any pulsatility, if present, is created by the residual LV function. In severe cases of cardiogenic shock, only mean blood pressure, which is created by ECMO, can be measured, necessitating the use of an arterial line.¹⁰⁾ The target MAP is usually more than 50 to 60 mmHg. We prefer the lower side of MAP to reduce LV afterload. As cardiac function improves, pulse pressure increases as a sign of recovery.⁹⁾ Although keeping pulse pressure more than 10 mmHg has been a general recommendation in VA ECMO management, there is no evidence that “making pulse pressure more than 10 mmHg” improves outcomes. There are many studies insisting that high pulsatility and high MAP after ECMO is a good prognostic factor. However, augmenting pulsatility using low ECMO flow and high vasopressors may cause low cardiac output state and increase afterload of the heart. We prefer a cardiac resting (preload and afterload reduction) with no or low dose inotropes rather than artificially augmented pulsatility.

Oxygen balance

Adequate systemic perfusion is best measured with a SvO₂ and serum lactate level. Ideally, SvO₂ greater than 70% and serum lactate level less than 2.2 mmol/L or 19.8 mg/dL ensure optimal balance between DO₂ and VO₂. SvO₂ is generally increased immediately after ECMO initiation. However, increase in lactate level takes for a while depending on the pre-ECMO lactate level. Rather than the absolute value of lactate, the level should be decreased over time toward normal value. If SvO₂ and lactate levels are not recovered with satisfaction, there are 2 typical scenarios. One is a wrong ECMO indication such as severe septic shock without cardiac compromise (high VO₂). Another is insufficient oxygen supply (low DO₂). This can be tried to manage by increasing ECMO flow with volume infusion or transfusion. Rarely, localized ischemia such as bowel infarction will present as a low SvO₂ and reduced lactate clearance during VA ECMO.

Complications

Limb ischemia

Vascular complications include bleeding or hematoma in the cannulation site, lower limb ischemia, femoral artery embolism, and retroperitoneal bleeding,⁴⁶⁾⁴⁷⁾ with lower limb ischemia being the major complication. If the femoral arterial cannula takes up most of the internal diameter of the artery, perfusion to the distal limb is impeded and limb ischemia occurs. If the distal limb ischemia is detected late or if the reperfusion procedure is performed late, it may be fatal due to rhabdomyolysis, acute kidney injury, or compartment syndrome requiring fasciotomy. Sometimes, amputation is inevitable.⁴⁸⁾⁴⁹⁾ Risk factors for distal limb ischemia include the use of larger bore cannulae, presence of peripheral vascular disease, cannulation in the superficial femoral artery, presence of small iliofemoral arteries (in younger or female patients), and vasospasm (in profound shock, cardiac arrest, or high dose of vasopressors).

One of the best ways to increase distal perfusion is to perform an ultrasound- or fluoroscopy-guided percutaneous catheterization into the superficial femoral artery.⁵⁰⁾⁵¹⁾ Catheterization after surgical exposure of the artery is another option.⁵²⁾ Surgical side graft perfusion is sometimes performed. After cannulation, the limb perfusion should be frequently checked because the catheter may be occluded by a thrombus or kink.

The timing of distal limb perfusion such as early preemptive perfusion or late selective perfusion is not yet established. Early perfusion is preferable over late perfusion when considering the fatal risk of limb ischemia.⁵¹⁾⁵³⁾ Several methods are known in determining the limb perfusion state. Measuring capillary refilling time of the toes is simple but less accurate. Distal limb perfusion is often nonpulsatile during ECMO. Thus, performing pulse oximetry is not useful. A Duplex ultrasound is more accurate than the pulse oximetry because it can detect continuous and nonpulsatile flow. However, performing Duplex ultrasound requires skills, and this procedure cannot be monitored continuously. Recently, near-infrared spectroscopy has been widely used because it is less invasive and continuous monitoring is possible.⁵⁴⁾⁵⁵⁾ There is also a method of measuring the distal limb flow using a flowmeter.⁵²⁾

Left ventricle distension and pulmonary edema

ECMO does not directly decompress the LV. Some venous blood continues to enter the right ventricle and thus is delivered through the pulmonary circulation into the LV. Additionally, bronchial circulation and Thebesian veins will also deliver blood into the LV. This blood must be ejected through the aortic valve and into the arterial circulation.¹⁰⁾ Without satisfactory

ejection, blood will accumulate under pressure, until it eventually equalizes with systemic arterial pressure. The LV will not eject if its systolic function is too poor to overcome the afterload. Without urgent correction, severe pulmonary edema will occur, followed by fatal pulmonary hemorrhage. The LV must be encouraged to eject, by maintaining inotropes and decreasing afterload or blood pressure. Liberal use of echocardiography can be helpful in demonstrating routine opening of the aortic valve and in allowing the measurement of LV dimensions.¹⁰⁾ A pulmonary artery catheter can also be helpful by noting a progressive increase in left-sided filling pressures. Dyspnea, low SaO₂ of the right hand, increased tracheal secretion, and bloody and watery sputum are classic signs of LV distension. Aggravation of bilateral pulmonary congestion after VA ECMO also suggests pulmonary edema by VA ECMO. Generally, pulmonary artery occlusion pressure or pulmonary capillary wedge pressure, diastolic pulmonary artery pressure, and mean right atrial pressure reflect directly or indirectly LVEDP. High LVEDP will affect the pulmonary artery pressure and right atrial pressure. If there is no pulmonary artery catheter, monitoring the right atrial pressure may be helpful to detect LV distension. In echocardiography, decreased LV ejection fraction with increased LV end-diastolic dimension may suggest LV distension. Echocardiography will reveal many signs of increased LVEDP. Increased amount of valve regurgitation after VA ECMO is also helpful in diagnosing LV distension. There is no single diagnostic finding of LV distension. There should be a combination of symptoms or signs and available data from invasive lines or echocardiography. If the LV is distended despite the infusion of inotropes or vasodilators, left heart must be physically decompressed.¹⁰⁾ Kapur and Esposito⁵⁶⁾ summarized the relationship between pressure and volume of the LV during VA ECMO with or without LV venting. VA ECMO reduces biventricular volumes with a concomitant increase in MAP and both LV systolic and diastolic pressures as we explained earlier in **Figure 2B**. This increase in LV afterload or wall stress occurs because there is no direct venting of the left heart with VA ECMO. Venting of the left heart with an IABP, Impella device, transaortic catheter, or transseptal LA cannula during VA ECMO support reduces LVESP and LVEDV. Left heart venting not only improves left heart distension but also improves Harlequin syndrome.⁵⁷⁾ ECMO with left heart decompression is known to improve survival in severe cardiogenic shock.⁵⁸⁾

A number of methods have been suggested for left heart venting. Venting with other mechanical circulatory support such as IABP and Impella will be discussed in detail later.

1) Percutaneous transseptal LA venting

Percutaneous transseptal LA venting is performed with transseptal cannula insertion over the wire after transseptal atrial puncture.⁵⁹⁻⁶²⁾ If multistage venous cannula is available, we prefer inserting a single multistage venous cannula over the interatrial septum. This approach is referred to as LA-VA ECMO. LA-VA ECMO generally offers a sufficient biventricular decompression (**Figure 4**).⁶³⁾

2) Balloon atrial septostomy

Balloon atrial septostomy or atrial septal stenting, which induces left-to-right shunt during LV dysfunction, has been introduced as a less invasive technique than LA drainage through the transseptal puncture.⁶¹⁾⁶⁴⁻⁶⁷⁾ However, if the hole of septostomy is not large enough, left-to-right shunt may be ineffective.⁶²⁾

3) Surgical left heart venting

Left heart vent cannula can be inserted through the right upper pulmonary vein.⁶⁸⁾ The cannulation can be performed with the right mini-thoracotomy as a less invasive technique.

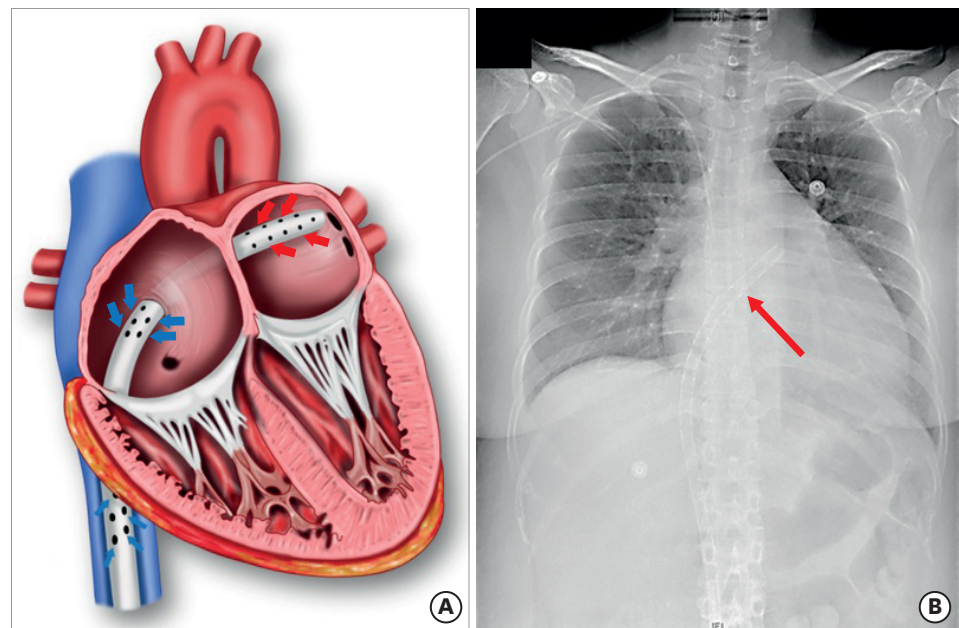


Figure 4. LAVA ECMO. (A) In LAVA ECMO, the multistage cannula drains both in the left atrium (via end hole) and right atrium (via side holes). (B) A chest radiograph in which the cannula tip (red arrow) is placed in the left atrium through the atrial septum.

ECMO = extracorporeal membrane oxygenation; LAVA = left atrial venoarterial.

It can later be used as a drainage cannula for paracorporeal LV assist device if necessary.⁽⁶⁹⁾⁽⁷⁰⁾ Transapical LV cannulation through full sternotomy, lower median sternotomy,⁽⁷¹⁾ or left mini-thoracotomy⁽⁷²⁾ is also known to be useful, which has the advantage of subsequent bridging the LV assist device later.⁽⁷²⁾

4) Transaortic catheter left ventricle venting

In LV venting catheterization, the catheter is inserted retrogradely through the aortic valve.⁽⁷³⁾ Moreover, this technique is considered to be less invasive technique, but as of today, the amount of drainage collected in this technique seems to be insufficient.⁽⁷⁴⁾⁽⁷⁵⁾

5) Percutaneous pulmonary artery venting

Percutaneous pulmonary artery venting with a 15-Fr drainage cannula via the jugular vein is considered a less invasive technique, which is inserted under fluoroscopy.⁽⁷⁶⁾⁽⁷⁷⁾

Venting with other mechanical circulatory support such as IABP and Impella will be discussed in detail later.

Anticoagulation-related complications: thromboembolism and bleeding

The primary purpose of systemic anticoagulation is to protect the major organs from thromboembolism. The secondary reason of anticoagulation is to keep ECMO circuit patent. There may be 2 sources of thrombi including native cardiopulmonary system and extracorporeal circuit. The more dangerous site of thrombi is the native cardiopulmonary system, since it is close to the coronary arteries and cerebral vessels. Currently available ECMO circuits are generally resistant to thrombus formation and sudden malfunction. It is highly important that good anticoagulation status is maintained during high-flow VA ECMO because native cardiopulmonary blood flow is slow or static (**Figure 5**). In adult patients,

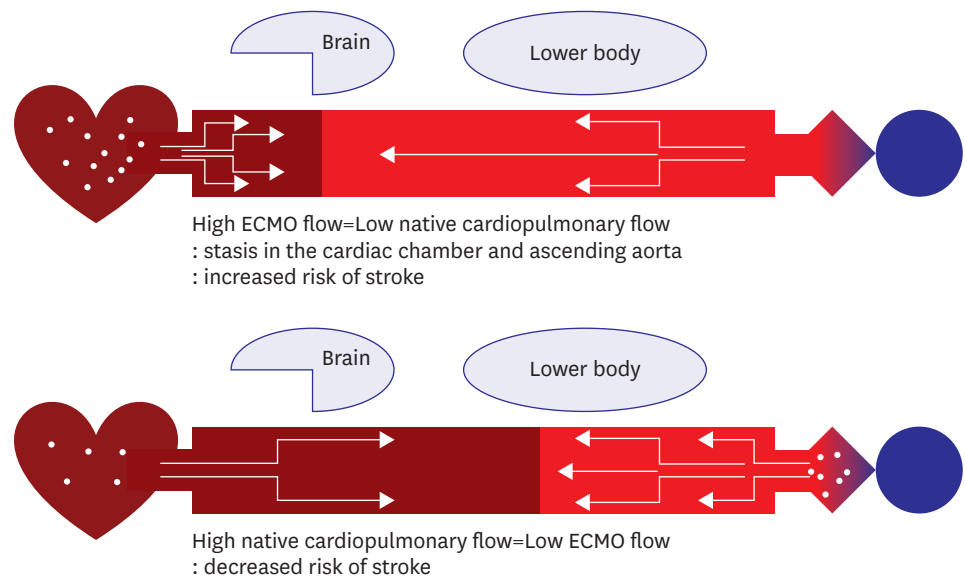


Figure 5. Simplified diagrams are showing interaction between a patient's native cardiovascular system and VA ECMO flow. Embolic stroke is usually caused by thrombi in the native cardiac chambers rather than extracorporeal circuit. Anticoagulation is more crucial at high-flow than low-flow ECMO. ECMO = extracorporeal membrane oxygenation; VA = venoarterial.

ECMO blood flow 1 L/min is enough to keep the circuit patent. At this low flow, it is almost impossible for the thrombi from ECMO to reach to the cerebral vessels.

Hemolysis is also an important complication of ECMO. There are many potential causes of hemolysis including pump thrombosis, increased resistance of the membrane lung, and kinking of tube or cannulae and so on. The most common cause of hemolysis is pump thrombosis. If a thrombus is formed in the centrifugal pump, there will be excessive friction that will damage the blood cells. Massive intravascular hemolysis results in multiorgan failure and anemia.⁷⁸⁾ Plasma lactate dehydrogenase is a useful maker of hemolysis. Although it is nonspecific for hemolysis, it rapidly increases during hemolysis and normalizes after the resolution of hemolysis. Dark red-colored urine and acute renal failure are also signs of hemolysis. Significant increase of plasma-free hemoglobin (>50 mg/dL) confirms massive intravascular hemolysis.

Heparin-induced thrombocytopenia (HIT) is a rare complication reported in up to 5% of patients, and screening tests have an unacceptably high false-positive rate, while confirmation tests, that is, HIT antibody assay and serotonin release assay, are very costly.⁷⁹⁾ As the latter tests are not available in most centers including our own, we take action on a positive HIT screening test only if there is clinical evidence of HIT.⁸⁰⁾ Management of HIT includes prompt cessation of heparin and transition to a direct thrombin inhibitor, for example, argatroban. This novel drug selectively binds to circulating and clot-bound thrombin. This direct mechanism of action renders antithrombin levels irrelevant, resulting in more predictable pharmacokinetics and better efficacy. Argatroban may have a more significant platelet-preserving effect than unfractionated heparin, regardless of whether HIT is present.⁸¹⁾ Argatroban administered during ECMO is reported to be administered significantly less (0.1–0.2 mcg/kg/min) than the recommended dose for HIT (2 mcg/kg/min).⁸¹⁾⁸²⁾

EXTRACORPOREAL MEMBRANE OXYGENATION WEANING

Myocardial recovery should be suspected when there is increased pulsatility in the arterial circulation, increased mixed venous saturation, decreased serum lactate level, and improvement in the echocardiographic appearance of systolic function. Flow can be gradually decreased, and hemodynamics are assessed. If blood pressure and cardiac output can be maintained on reasonable doses of inotropes, decannulation should be considered.⁵⁾¹⁰⁾

Echocardiography plays a key role in the ECMO, including patient selection, adequate placement of cannulae, and monitoring, weaning, and follow-up after decannulation.⁸³⁾ In our institution, we perform echocardiography at 3 L/min and 1 L/min of ECMO flow. Improved LV ejection fraction and cardiac output assessed by echocardiography are favorable signs of a successful weaning. If echocardiographic findings indicate that it is fine to proceed with weaning, we perform ECMO at 1 L/min for 12–24 hours. After 12–24 hours, we check the urine output, vasopressor or inotrope requirement, and SvO₂ and lactate levels. We strongly discourage decannulation under high-dose inotropes or vasopressors with signs of organ hypoperfusion.

Femoral cannulae are removed by direct surgical exposure and repair, by removal and manual compression, or by removal with Perclose ProGlide suture-mediated closure system (Abbott Vascular, Clonmel, Ireland).¹⁰⁾⁸⁴⁾ Manual compression has the following disadvantages: performance of the procedure for 1–2 hours and performance of additive bed rest and the presence of risk of pseudoaneurysm or thrombotic occlusion. Surgical arterial repair requires surgical skills, although the risk of pseudoaneurysm is rather low.

COMBINED USE OF OTHER MECHANICAL CIRCULATORY SUPPORT

The use of other mechanical circulatory support during VA ECMO is performed because VA ECMO has no direct effect of venting the LV and the LVEDP increases as the cardiac function deteriorates.⁵⁶⁾

Intraaortic balloon pump

An IABP can be instrumental in reducing afterload¹⁰⁾. There are still some conflicts over the effect of IABP under VA ECMO.⁸⁵⁾⁸⁶⁾ However, neither report had any disclosures about the LV function or LA pressure before or after IABP. Tay et al.⁸⁷⁾ presented a hypothesis that the LV afterload may paradoxically increase during systole due to balloon deflation or “de-clamping” effect of the descending thoracic aorta. In diastole, balloon occlusion of the aorta may reduce ECMO-driven blood flow to the aortic root and arch and attenuate myocardial and cerebral perfusion (**Figure 6**). We believe IABP may be useful in a patient who only needs low-flow of VA ECMO than high-flow of ECMO. It also may facilitate weaning from VA ECMO. Further research on the degree of left heart decompression via IABP is deemed necessary.

Impella

The Impella devices (Abiomed Inc., Danvers, MA, USA) are microaxial flow blood pumps designed to be positioned across the aortic valve, actively pumping blood from the LV into the ascending aorta. The Impella pumps are approved by the US Food and Drug Administration for only 6 hours of support but are often used for longer duration of support.¹⁰⁾ Impella

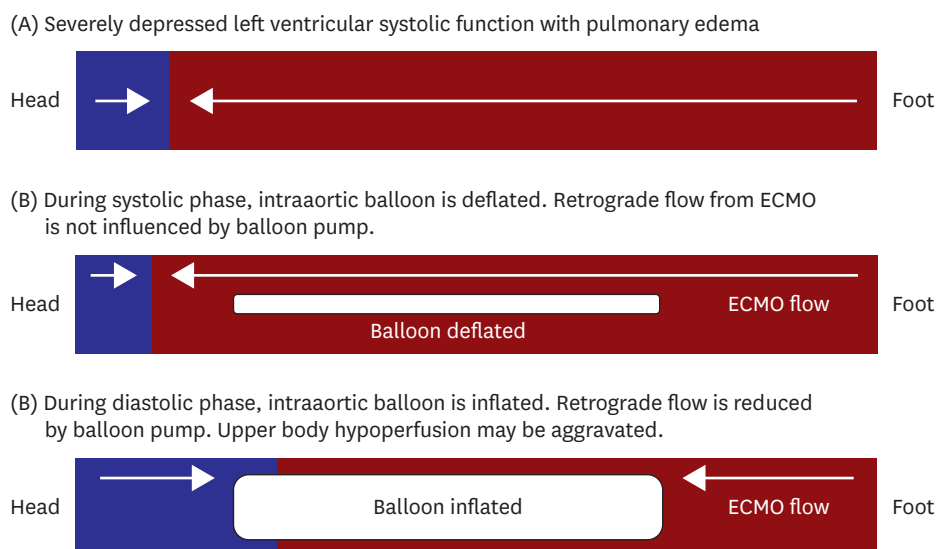


Figure 6. The blood flow in a patient with pulmonary edema on VA ECMO is shown. If a patient has extremely poor left ventricular systolic function, IABP may increase cardiac afterload by systolic deflation and decrease cerebral perfusion by diastolic inflation.
ECMO = extracorporeal membrane oxygenation; IABP = intra-aortic balloon pump.

during VA ECMO has been demonstrated to be feasible and effective.⁸⁸⁻⁹⁰⁾ Three devices for the left sided support and one for the right sided support are available.

CONCLUSION

We suggest a simplified flowchart for the initial management of VA ECMO (**Figure 7**). VA ECMO should be deployed before cardiac arrest or profound shock occurs. The ability of establishing quick and precise diagnosis of medically refractory cardiogenic shock is the most important step for a successful outcome. Proper cannulation is also important to prevent cannulation-related problems. After cannulation, blood flow of ECMO should be optimized. There are 3 values to easily monitor good ECMO flow including MAP, SvO₂, and lactate level. MAP should not be too low or too high. To ensure enough tissue perfusion, SvO₂ should be higher than 65%. If the flow of VA ECMO is adequate, the lactate level will be gradually decreased and finally normalized (<2.2 mmol/L). Inotropes and vasopressors are generally tapered out or maintained at a minimal dose. Systemic anticoagulation should be initiated as soon as hemostasis in the cannulation site is achieved. Distal limb perfusion should be checked frequently. If there are significant signs of hypoperfusion, selective perfusion catheter is inserted within 6–8 hours after VA ECMO initiation. Pulmonary edema by LV distension occurs after several hours or a few days after VA ECMO initiation. The classic signs are watery and pinkish tracheal secretion, bilateral pulmonary haziness, and low pulse pressure. If MAP is high, aggressive fluid removal and vasodilatation may help. However, LV decompression is frequently necessary.

We should examine the causes of cardiac failure and correct it as much as we can. For prolonged support, central ECMO conversion may be performed or an implantable LV assist device may be used. ECMO is not a procedure or treatment. It is a process including establishing a diagnosis, selecting a good candidate, performing a risky procedure, preventing and managing of complications, weaning, decannulation, and providing

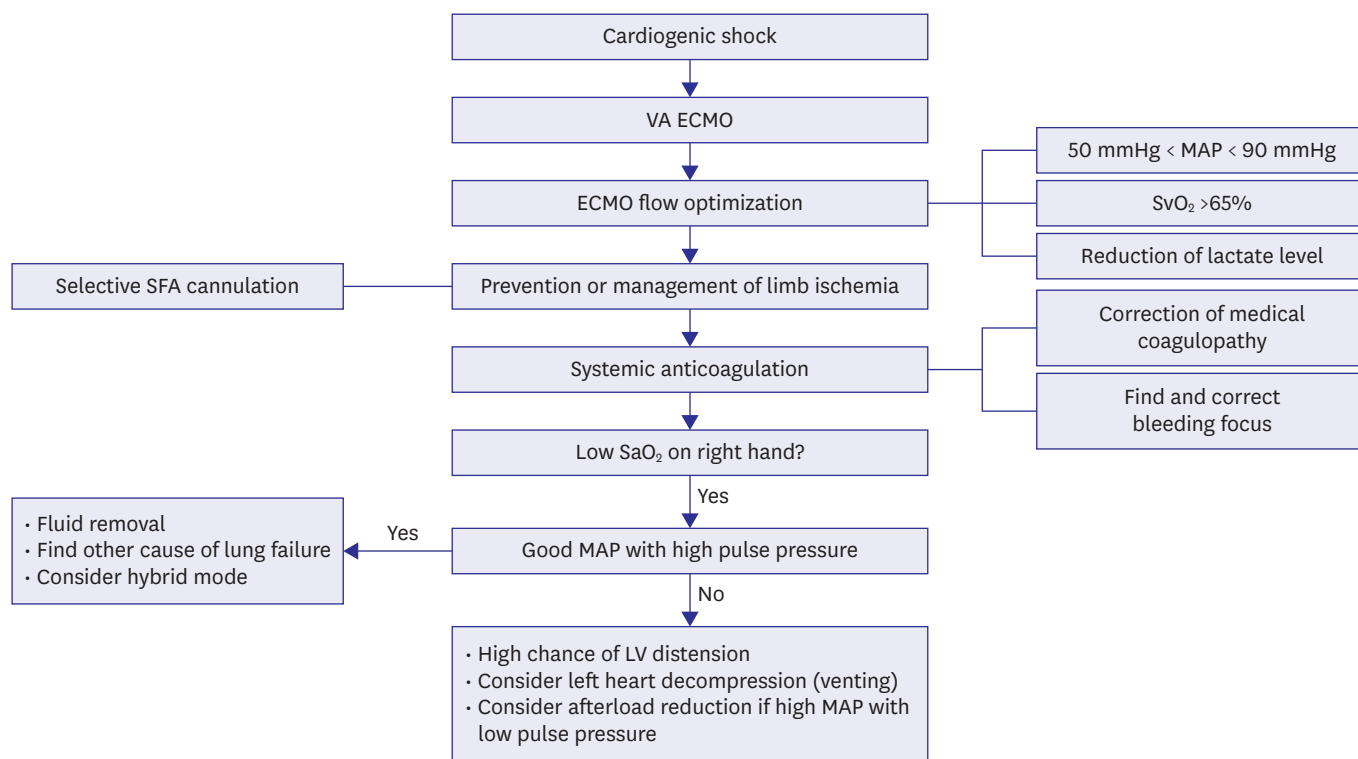


Figure 7. A simplified flow chart for the initial management of VA ECMO.

ECMO = extracorporeal membrane oxygenation; LV = left ventricle; MAP = mean arterial pressure; SaO₂ = arterial oxygen saturation; SFA = superficial femoral artery; SvO₂ = mixed venous oxygen saturation; VA = venoarterial.

general critical care. Therefore, a multidisciplinary approach is crucial for a good outcome. Cardiologists, intensivists, cardiovascular surgeons, perfusionists, and intensive care unit nurses should continuously discuss and collaborate to save such a sick patient. Although not previously mentioned, meticulous general critical care is extremely important. Intensive care unit physicians, ECMO specialists, and nurses are the people standing right beside these patients. They should know how to monitor a patient on ECMO and how to respond to complications. Teamwork and 3-dimensional care are keys in the success of ECMO. Yoko Ono, wife of John Lennon, said: “A dream you dream alone is only a dream. A dream you dream together is reality.”

REFERENCES

- Fortenberry JD, Lorusso R. *The history and development of extracorporeal support*. In: Brogan TV, Lequier L, Lorusso R, MacLaren G, Peek G, editors. *Extracorporeal Life Support: The ELSO Red Book*. 5th ed. Ann Arbor (MI): Extracorporeal Life Support Organization; 2017. p.1-15.
- Toomasian JM, Vercaemst L, Bottrell S, Horton SB. *The circuit*. In: Brogan TV, Lequier L, Lorusso R, MacLaren G, Peek G, editors. *Extracorporeal Life Support: The ELSO Red Book*. 5th ed. Ann Arbor (MI): Extracorporeal Life Support Organization; 2017. p.49-80.
- Montoya JP, Shanley CJ, Merz SI, Bartlett RH. Plasma leakage through microporous membranes. Role of phospholipids. *ASAIO J* 1992;38:M399-405.
[PUBMED](#) | [CROSSREF](#)
- Thiara AP, Hoel TN, Kristiansen F, Karlsen HM, Fiane AE, Svennevig JL. Evaluation of oxygenators and centrifugal pumps for long-term pediatric extracorporeal membrane oxygenation. *Perfusion* 2007;22:323-6.
[PUBMED](#) | [CROSSREF](#)

5. Bartlett RH, Conrad SA. *The physiology of extracorporeal life support*. In: Brogan TV, Lequier L, Lorusso R, MacLaren G, Peek G, editors. *Extracorporeal Life Support: The ELSO Red Book*. 5th ed. Ann Arbor (MI): Extracorporeal Life Support Organization; 2017. p.31-47.
6. MacLaren G, Butt W. *ECMO for septic shock*. In: Brogan TV, Lequier L, Lorusso R, MacLaren G, Peek G, editors. *Extracorporeal Life Support: The ELSO Red Book*. 5th ed. Ann Arbor (MI): Extracorporeal Life Support Organization; 2017. p.613-26.
7. Burkhoff D, Sayer G, Doshi D, Uriel N. Hemodynamics of mechanical circulatory support. *J Am Coll Cardiol* 2015;66:2663-74.
[PUBMED](#) | [CROSSREF](#)
8. Rihal CS, Naidu SS, Givertz MM, et al. 2015 SCAI/ACC/HFSA/STS clinical expert consensus statement on the use of percutaneous mechanical circulatory support devices in cardiovascular care: endorsed by the American Heart Association, the Cardiological Society of India, and Sociedad Latino Americana de Cardiologia Intervencion; affirmation of value by the Canadian Association of Interventional Cardiology-Association Canadienne de Cardiologie d' intervention. *J Am Coll Cardiol* 2015;65:e7-26.
[PUBMED](#) | [CROSSREF](#)
9. Guglin M, Zucker MJ, Bazan VM, et al. Venoarterial ECMO for adults: JACC scientific expert panel. *J Am Coll Cardiol* 2019;73:698-716.
[PUBMED](#) | [CROSSREF](#)
10. Haft JW, Firmin R. *Adult cardiac support*. In: Annich GM, Lynch WR, MacLaren G, Wilson JM, Bartlett RH, editors. *ECMO Extracorporeal Cardiopulmonary Support in Critical Care*. 4th ed. Ann Arbor (MI): Extracorporeal Life Support Organization; 2012. p.323-30.
11. Batista PM, Cavarocchi NC, Hirose H. Extracorporeal membranous oxygenation mimics aortic dissection on CAT scan. *Ann Thorac Surg* 2013;95:357.
[PUBMED](#) | [CROSSREF](#)
12. Goslar T, Stankovic M, Ksela J. Contrast layering artefact mimicking aortic dissection in a patient on veno-arterial extracorporeal membrane oxygenation undergoing computed tomography scan. *Interact Cardiovasc Thorac Surg* 2016;22:507-9.
[PUBMED](#) | [CROSSREF](#)
13. Sirol M, Sideris G, Deye N, Henry P, Baud F, Soyser P. A bizarre aortic dissection. *Ann Thorac Surg* 2012;93:2070.
[PUBMED](#) | [CROSSREF](#)
14. Auzinger G, Best T, Vercueil A, Willars C, Wendon JA, Desai SR. Computed tomographic imaging in peripheral VA-ECMO: where has all the contrast gone? *J Cardiothorac Vasc Anesth* 2014;28:1307-9.
[PUBMED](#) | [CROSSREF](#)
15. Na SJ, Chung CR, Cho YH, et al. Vasoactive inotropic score as a predictor of mortality in adult patients with cardiogenic shock: medical therapy versus ECMO. *Rev Esp Cardiol (Engl Ed)* 2019;72:40-7.
[PUBMED](#) | [CROSSREF](#)
16. Chen YS, Lin JW, Yu HY, et al. Cardiopulmonary resuscitation with assisted extracorporeal life-support versus conventional cardiopulmonary resuscitation in adults with in-hospital cardiac arrest: an observational study and propensity analysis. *Lancet* 2008;372:554-61.
[PUBMED](#) | [CROSSREF](#)
17. Shin TG, Choi JH, Jo IJ, et al. Extracorporeal cardiopulmonary resuscitation in patients with inhospital cardiac arrest: A comparison with conventional cardiopulmonary resuscitation. *Crit Care Med* 2011;39:1-7.
[PUBMED](#) | [CROSSREF](#)
18. Huang SC, Wu ET, Chen YS, et al. Extracorporeal membrane oxygenation rescue for cardiopulmonary resuscitation in pediatric patients. *Crit Care Med* 2008;36:1607-13.
[PUBMED](#) | [CROSSREF](#)
19. Prodhon P, Fiser RT, Dyamenahalli U, et al. Outcomes after extracorporeal cardiopulmonary resuscitation (ECPR) following refractory pediatric cardiac arrest in the intensive care unit. *Resuscitation* 2009;80:1124-9.
[PUBMED](#) | [CROSSREF](#)
20. Sivarajan VB, Best D, Brizard CP, Shekerdemian LS, d'Udekem Y, Butt W. Duration of resuscitation prior to rescue extracorporeal membrane oxygenation impacts outcome in children with heart disease. *Intensive Care Med* 2011;37:853-60.
[PUBMED](#) | [CROSSREF](#)
21. Jaski BE, Ortiz B, Alla KR, et al. A 20-year experience with urgent percutaneous cardiopulmonary bypass for salvage of potential survivors of refractory cardiovascular collapse. *J Thorac Cardiovasc Surg* 2010;139:753-757.e1-2.
[PUBMED](#) | [CROSSREF](#)

22. Link MS, Berkow LC, Kudenchuk PJ, et al. Part 7: adult advanced cardiovascular life support: 2015 American Heart Association guidelines update for cardiopulmonary resuscitation and emergency cardiovascular care. *Circulation* 2015;132:S444-64.
[PUBMED](#) | [CROSSREF](#)
23. Lorusso R, Gelsomino S, Parise O, et al. Venoarterial extracorporeal membrane oxygenation for refractory cardiogenic shock in elderly patients: trends in application and outcome from the extracorporeal life support organization (ELSO) registry. *Ann Thorac Surg* 2017;104:62-9.
[PUBMED](#) | [CROSSREF](#)
24. Šimek M, Hutyra M, Gwozdziwicz M, Fluger I, Steriovský A, Konečný J. The role of surgical embolectomy and extracorporeal membrane oxygen therapy in the treatment of massive pulmonary embolism - a review. *Rozhl Chir* 2015;94:103-10.
[PUBMED](#)
25. Watanabe Y, Sakakura K, Akashi N, et al. Veno-arterial extracorporeal membrane oxygenation with conventional anticoagulation can be a best solution for shock due to massive PE. *Int Heart J* 2017;58:831-4.
[PUBMED](#) | [CROSSREF](#)
26. Cho YH, Kim WS, Sung K, et al. Management of cardiac arrest caused by acute massive pulmonary thromboembolism: importance of percutaneous cardiopulmonary support. *ASAIO J* 2014;60:280-3.
[PUBMED](#) | [CROSSREF](#)
27. Swol J, Buchwald D, Ewers A, Schildhauer TA. Venoarterielle extrakorporale Membranoxygenierung (ECMO). *Med Klin Intensivmed NotfMed* 2013;108:63-8.
[CROSSREF](#)
28. Yusuff HO, Zochios V, Vuylsteke A. Extracorporeal membrane oxygenation in acute massive pulmonary embolism: a systematic review. *Perfusion* 2015;30:611-6.
[PUBMED](#) | [CROSSREF](#)
29. Moon D, Lee SN, Yoo KD, Jo MS. Extracorporeal membrane oxygenation improved survival in patients with massive pulmonary embolism. *Ann Saudi Med* 2018;38:174-80.
[PUBMED](#) | [CROSSREF](#)
30. Kafi A, Friedman O, Kim I. Use of low-dose thrombolytics for treatment of intracardiac thrombus and massive pulmonary embolus after aborted liver transplant leads to recovery of right ventricular function and redo liver transplantation. *BMJ Case Rep* 2017;2017:bcr-2017-219837.
[PUBMED](#) | [CROSSREF](#)
31. Lauren Lindsey J, Jain R, Vachharajani V. Catheter directed thrombolysis combined with ECMO for massive pulmonary emboli. *Respir Med Case Rep* 2018;25:6-8.
[PUBMED](#) | [CROSSREF](#)
32. Konstantinides SV. 2014 ESC guidelines on the diagnosis and management of acute pulmonary embolism. *Eur Heart J* 2014;35:3145-6.
[PUBMED](#)
33. MacLaren G, Butt W, Best D, Donath S. Central extracorporeal membrane oxygenation for refractory pediatric septic shock. *Pediatr Crit Care Med* 2011;12:133-6.
[PUBMED](#) | [CROSSREF](#)
34. Riera J, Argudo E, Ruiz-Rodríguez JC, Ferrer R. Extracorporeal membrane oxygenation for adults with refractory septic shock. *ASAIO J*. 2018 [Epub ahead of print].
[PUBMED](#) | [CROSSREF](#)
35. Chvojka J, Martinkova V, Benes J, et al. Mechanical circulatory support in refractory vasodilatory septic shock: a randomized controlled porcine study. *Shock*. 2019 [Epub ahead of print].
[PUBMED](#) | [CROSSREF](#)
36. Perdue SM, Poore BJ, Babu AN, Stribling WK. Successful use of extracorporeal membrane oxygenation support in severe septic shock with associated acute cardiomyopathy. *J Card Surg* 2018;33:50-2.
[PUBMED](#) | [CROSSREF](#)
37. Asaki M, Masuda T, Miki Y. Veno-arterial extracorporeal membrane oxygenation for septic cardiomyopathy due to *Legionella* pneumonia after influenza virus infection. *Case Rep Crit Care* 2018;2018:6973197.
[PUBMED](#) | [CROSSREF](#)
38. Liu C, Zhu R, Zhou Z, et al. Sepsis-induced cardiomyopathy complicated with cardiogenic shock patients supported with extracorporeal membrane oxygenation. *Zhonghua Wei Zhong Bing Ji Jiu Yi Xue* 2017;29:1140-3.
[PUBMED](#)
39. Lees NJ, Rosenberg A, Hurtado-Doce AI, et al. Combination of ECMO and cytokine adsorption therapy for severe sepsis with cardiogenic shock and ARDS due to Pantone-Valentine leukocidin-positive *Staphylococcus aureus* pneumonia and H1N1. *J Artif Organs* 2016;19:399-402.
[PUBMED](#) | [CROSSREF](#)

40. Kredel M, Kunzmann S, Schlegel PG, et al. Double peripheral venous and arterial cannulation for extracorporeal membrane oxygenation in combined septic and cardiogenic shock. *Am J Case Rep* 2017;18:723-7.
[PUBMED](#) | [CROSSREF](#)
41. Prankoff T, Hines MH. *Vascular access for extracorporeal support*. In: Annich GM, Lynch WR, MacLaren G, Wilson JM, Bartlett RH, editors. *ECMO Extracorporeal Cardiopulmonary Support in Critical Care*. 4th ed. Ann Arbor (MI): Extracorporeal Life Support Organization; 2012. p.133-47.
42. Hysi I, Fabre O, Renaut C, Guesnier L. Extracorporeal membrane oxygenation with direct axillary artery perfusion. *J Card Surg* 2014;29:268-9.
[PUBMED](#) | [CROSSREF](#)
43. Javidfar J, Brodie D, Costa J, et al. Subclavian artery cannulation for venoarterial extracorporeal membrane oxygenation. *ASAIO J* 2012;58:494-8.
[PUBMED](#) | [CROSSREF](#)
44. Jayaraman AL, Cormican D, Shah P, Ramakrishna H. Cannulation strategies in adult veno-arterial and veno-venous extracorporeal membrane oxygenation: techniques, limitations, and special considerations. *Ann Card Anaesth* 2017;20:S11-8.
[PUBMED](#) | [CROSSREF](#)
45. Napp LC, Kühn C, Hoepfer MM, et al. Cannulation strategies for percutaneous extracorporeal membrane oxygenation in adults. *Clin Res Cardiol* 2016;105:283-96.
[PUBMED](#) | [CROSSREF](#)
46. Yang F, Hou D, Wang J, et al. Vascular complications in adult postcardiotomy cardiogenic shock patients receiving venoarterial extracorporeal membrane oxygenation. *Ann Intensive Care* 2018;8:72.
[PUBMED](#) | [CROSSREF](#)
47. Aziz F, Brehm CE, El-Banyosy A, Han DC, Atnip RG, Reed AB. Arterial complications in patients undergoing extracorporeal membrane oxygenation via femoral cannulation. *Ann Vasc Surg* 2014;28:178-83.
[PUBMED](#) | [CROSSREF](#)
48. Pozzi M, Koffel C, Djaref C, et al. High rate of arterial complications in patients supported with extracorporeal life support for drug intoxication-induced refractory cardiogenic shock or cardiac arrest. *J Thorac Dis* 2017;9:1988-96.
[PUBMED](#) | [CROSSREF](#)
49. Avalli L, Sangalli F, Migliari M, et al. Early vascular complications after percutaneous cannulation for extracorporeal membrane oxygenation for cardiac assist. *Minerva Anestesiol* 2016;82:36-43.
[PUBMED](#)
50. Rao AS, Pellegrini RV, Speziali G, Marone LK. A novel percutaneous solution to limb ischemia due to arterial occlusion from a femoral artery ECMO cannula. *J Endovasc Ther* 2010;17:51-4.
[PUBMED](#) | [CROSSREF](#)
51. Jang WJ, Cho YH, Park TK, et al. Fluoroscopy-guided simultaneous distal perfusion as a preventive strategy of limb ischemia in patients undergoing extracorporeal membrane oxygenation. *Ann Intensive Care* 2018;8:101.
[PUBMED](#) | [CROSSREF](#)
52. Madershahian N, Nagib R, Wippermann J, Strauch J, Wahlers T. A simple technique of distal limb perfusion during prolonged femoro-femoral cannulation. *J Card Surg* 2006;21:168-9.
[PUBMED](#) | [CROSSREF](#)
53. Yeo HJ, Yoon SH, Jeon D, et al. The utility of preemptive distal perfusion cannulation during peripheral venoarterial extracorporeal membrane oxygenation support. *J Interv Cardiol* 2016;29:431-6.
[PUBMED](#) | [CROSSREF](#)
54. Lamb KM, Hirose H, Cavarocchi NC. Preparation and technical considerations for percutaneous cannulation for veno-arterial extracorporeal membrane oxygenation. *J Card Surg* 2013;28:190-2.
[PUBMED](#) | [CROSSREF](#)
55. Keshavamurthy S, Shafii AE, Soltesz E. Spectroscopic limb monitoring in peripheral extracorporeal membrane oxygenation. *Asian Cardiovasc Thorac Ann* 2015;23:347-8.
[PUBMED](#) | [CROSSREF](#)
56. Kapur NK, Esposito M. Hemodynamic support with percutaneous devices in patients with heart failure. *Heart Fail Clin* 2015;11:215-30.
[PUBMED](#) | [CROSSREF](#)
57. Prasad A, Ghodsizad A, Brehm C, et al. Refractory pulmonary edema and upper body hypoxemia during veno-arterial extracorporeal membrane oxygenation—a case for atrial septostomy. *Artif Organs* 2018;42:664-9.
[PUBMED](#) | [CROSSREF](#)

58. Schmack B, Seppelt P, Weymann A, et al. Extracorporeal life support with left ventricular decompression-improved survival in severe cardiogenic shock: results from a retrospective study. *PeerJ* 2017;5:e3813.
[PUBMED](#) | [CROSSREF](#)
59. Alkhouli M, Narins CR, Lehoux J, Knight PA, Waits B, Ling FS. Percutaneous decompression of the left ventricle in cardiogenic shock patients on venoarterial extracorporeal membrane oxygenation. *J Card Surg* 2016;31:177-82.
[PUBMED](#) | [CROSSREF](#)
60. Lee SI, Lee SY, Choi CH, Park KY, Park CH. Left heart decompression in acute complicated myocardial infarction during extracorporeal membrane oxygenation. *J Intensive Care Med* 2017;32:405-8.
[PUBMED](#) | [CROSSREF](#)
61. Eastaugh LJ, Thiagarajan RR, Darst JR, McElhinney DB, Lock JE, Marshall AC. Percutaneous left atrial decompression in patients supported with extracorporeal membrane oxygenation for cardiac disease. *Pediatr Crit Care Med* 2015;16:59-65.
[PUBMED](#) | [CROSSREF](#)
62. Cheung MM, Goldman AP, Shekerdemian LS, Brown KL, Cohen GA, Redington AN. Percutaneous left ventricular "vent" insertion for left heart decompression during extracorporeal membrane oxygenation. *Pediatr Crit Care Med* 2003;4:447-9.
[PUBMED](#) | [CROSSREF](#)
63. Dulnuan K, Guglin M, Zwischenberger J, Gurley J. Left atrial veno-arterial extracorporeal membrane oxygenation: percutaneous bi-atrial drainage to avoid pulmonary edema in patients with left ventricular systolic dysfunction. *J Am Coll Cardiol* 2018;71:A1358.
[CROSSREF](#)
64. Baruteau AE, Barnette T, Morin L, et al. Percutaneous balloon atrial septostomy on top of venoarterial extracorporeal membrane oxygenation results in safe and effective left heart decompression. *Eur Heart J Acute Cardiovasc Care* 2018;7:70-9.
[PUBMED](#) | [CROSSREF](#)
65. Lin YN, Chen YH, Wang HJ, Hung JS, Chang KC, Lo PH. Atrial septostomy for left atrial decompression during extracorporeal membrane oxygenation by inoue balloon catheter. *Circ J* 2017;81:1419-23.
[PUBMED](#) | [CROSSREF](#)
66. Alhussein M, Osten M, Horlick E, et al. Percutaneous left atrial decompression in adults with refractory cardiogenic shock supported with veno-arterial extracorporeal membrane oxygenation. *J Card Surg* 2017;32:396-401.
[PUBMED](#) | [CROSSREF](#)
67. Johnston TA, Jagers J, McGovern JJ, O'Laughlin MP. Bedside transseptal balloon dilation atrial septostomy for decompression of the left heart during extracorporeal membrane oxygenation. *Catheter Cardiovasc Interv* 1999;46:197-9.
[PUBMED](#) | [CROSSREF](#)
68. Weymann A, Schmack B, Sabashnikov A, et al. Central extracorporeal life support with left ventricular decompression for the treatment of refractory cardiogenic shock and lung failure. *J Cardiothorac Surg* 2014;9:60.
[PUBMED](#) | [CROSSREF](#)
69. Keenan JE, Schechter MA, Bonadonna DK, et al. Early experience with a novel cannulation strategy for left ventricular decompression during nonpostcardiotomy venoarterial ECMO. *ASAIO J* 2016;62:e30-4.
[PUBMED](#) | [CROSSREF](#)
70. Kim C, Cho YH, Sung K, Yang JH. Transformation of percutaneous extracorporeal life support to paracorporeal ventricular assist device: a case report. *Korean J Thorac Cardiovasc Surg* 2014;47:409-12.
[PUBMED](#) | [CROSSREF](#)
71. Guirgis M, Kumar K, Menkis AH, Freed DH. Minimally invasive left-heart decompression during venoarterial extracorporeal membrane oxygenation: an alternative to a percutaneous approach. *Interact Cardiovasc Thorac Surg* 2010;10:672-4.
[PUBMED](#) | [CROSSREF](#)
72. Centofanti P, Attisani M, La Torre M, et al. Left ventricular unloading during peripheral extracorporeal membrane oxygenator support: a bridge to life in profound cardiogenic shock. *J Extra Corpor Technol* 2017;49:201-5.
[PUBMED](#)
73. Fumagalli R, Bombino M, Borelli M, et al. Percutaneous bridge to heart transplantation by venoarterial ECMO and transaortic left ventricular venting. *Int J Artif Organs* 2004;27:410-3.
[PUBMED](#) | [CROSSREF](#)
74. Kim WH, Hong TH, Byun JH, et al. Flow rate through pigtail catheter used for left heart decompression in an artificial model of extracorporeal membrane oxygenation circuit. *ASAIO J* 2017;63:346-50.
[PUBMED](#) | [CROSSREF](#)

75. Barbone A, Malvindi PG, Ferrara P, Tarelli G. Left ventricle unloading by percutaneous pigtail during extracorporeal membrane oxygenation. *Interact Cardiovasc Thorac Surg* 2011;13:293-5.
[PUBMED](#) | [CROSSREF](#)
76. Loforte A, Baiocchi M, Gliozzi G, Coppola G, Di Bartolomeo R, Lorusso R. Percutaneous pulmonary artery venting via jugular vein while on peripheral extracorporeal membrane oxygenation running: a less invasive approach to provide full biventricular unloading. *Ann Cardiothorac Surg* 2019;8:163-6.
[PUBMED](#) | [CROSSREF](#)
77. Avalli L, Maggioni E, Sangalli F, Favini G, Formica F, Fumagalli R. Percutaneous left-heart decompression during extracorporeal membrane oxygenation: an alternative to surgical and transeptal venting in adult patients. *ASAIO J* 2011;57:38-40.
[PUBMED](#) | [CROSSREF](#)
78. Rother RP, Bell L, Hillmen P, Gladwin MT. The clinical sequelae of intravascular hemolysis and extracellular plasma hemoglobin: a novel mechanism of human disease. *JAMA* 2005;293:1653-62.
[PUBMED](#) | [CROSSREF](#)
79. Coughlin MA, Bartlett RH. Anticoagulation for extracorporeal life support: direct thrombin inhibitors and heparin. *ASAIO J* 2015;61:652-5.
[PUBMED](#) | [CROSSREF](#)
80. Tay CK, Sung K, Cho YH. Clinical pearls in venovenous extracorporeal life support for adult respiratory failure. *ASAIO J* 2018;64:1-9.
[PUBMED](#) | [CROSSREF](#)
81. Kim YS, Lee H, Yang JH, et al. Use of argatroban for extracorporeal life support in patients with nonheparin-induced thrombocytopenia: analysis of 10 consecutive patients. *Medicine (Baltimore)* 2018;97:e13235.
[PUBMED](#) | [CROSSREF](#)
82. Beiderlinden M, Treschan T, Görlinger K, Peters J. Argatroban in extracorporeal membrane oxygenation. *Artif Organs* 2007;31:461-5.
[PUBMED](#) | [CROSSREF](#)
83. Donker DW, Meuwese CL, Braithwaite SA, et al. Echocardiography in extracorporeal life support: a key player in procedural guidance, tailoring and monitoring. *Perfusion* 2018;33:31-41.
[PUBMED](#) | [CROSSREF](#)
84. Hwang JW, Yang JH, Sung K, et al. Percutaneous removal using Perclose ProGlide closure devices versus surgical removal for weaning after percutaneous cannulation for venoarterial extracorporeal membrane oxygenation. *J Vasc Surg* 2016;63:998-1003.e1.
[PUBMED](#) | [CROSSREF](#)
85. Aso S, Matsui H, Fushimi K, Yasunaga H. The effect of intraaortic balloon pumping under venoarterial extracorporeal membrane oxygenation on mortality of cardiogenic patients: an analysis using a nationwide inpatient database. *Crit Care Med* 2016;44:1974-9.
[PUBMED](#) | [CROSSREF](#)
86. Park TK, Yang JH, Choi SH, et al. Clinical impact of intra-aortic balloon pump during extracorporeal life support in patients with acute myocardial infarction complicated by cardiogenic shock. *BMC Anesthesiol* 2014;14:27.
[PUBMED](#) | [CROSSREF](#)
87. Tay CK, Yoo KH, Cho YH. Intraaortic balloon pulsation in peripheral venoarterial extracorporeal membrane oxygenation: more is not always better. *Crit Care Med* 2016;44:e1251.
[PUBMED](#) | [CROSSREF](#)
88. Karatolios K, Chatzis G, Markus B, Luesebrink U, Richter A, Schieffer B. Biventricular unloading in patients with refractory cardiogenic shock. *Int J Cardiol* 2016;222:247-52.
[PUBMED](#) | [CROSSREF](#)
89. Cheng A, Swartz ME, Massey HT. Impella to unload the left ventricle during peripheral extracorporeal membrane oxygenation. *ASAIO J* 2013;59:533-6.
[PUBMED](#) | [CROSSREF](#)
90. Narain S, Papacuri G, Fuhrman TM, Silverman RB, Peruzzi WT. Novel combination of impella and extracorporeal membrane oxygenation as a bridge to full recovery in fulminant myocarditis. *Case Rep Crit Care* 2012;2012:459296.
[PUBMED](#) | [CROSSREF](#)