

REVIEW ARTICLE

Total Hip Arthroplasty for Crowe Type IV Hip Dysplasia: Surgical Techniques and Postoperative Complications

Xiao-tong Shi, MD, Chao-feng Li, MD, Yu Han, MD, PhD, Ya Song, MD, Shu-xuan Li, MD, Jian-guo Liu, MD, PhD 

Department of Orthopaedics Jilin University First Hospital, Jilin University First Hospital, Changchun, Jilin Province, China

Total hip arthroplasty (THA) of Crowe type IV developmental dysplasia of the hip (DDH) is challenging. Although traditional (lateral, posterolateral, and posterior) THA approaches have been used with great anatomic success, they damage peri-articular muscles, which are already quite weak in type IV DDH. The recently developed direct anterior approach (DAA) can provide an inter-nerve and inter-muscle approach for THA of type IV dysplasia hips. However, femur exposure with the DAA could be difficult during surgery and it is hard to apply femoral shortening osteotomy. THA techniques used for type IV DDH include anatomic hip center techniques (true acetabular reconstruction) and high hip center techniques, wherein an acetabulum is reconstructed above the original one. Although anatomic construction of the hip center is considered “the gold standard” treatment, it is impossible if the anatomical acetabulum is too small and shallow. Procedures used to support type IV DDH reduction with anatomic hip center techniques include greater trochanter osteotomy, lesser trochanter osteotomy, and subtrochanteric osteotomy. However, these techniques have yet to be standardized, and it is unclear which is best for type IV DDH. One-state and two-state non-osteotomy reduction techniques have also been introduced to treat type IV DDH. Potential complications of THA performed in patients with type IV DDH include leg length discrepancy (LLD), peri-operative femur fracture, nonunion of the osteotomy site, and nerve injury. It is worth noting that nowadays an increasing number of Crowe type IV DDH patients are more sensitive to postoperative LLD.

Key words: Acetabular reconstruction; Hip dislocation; Osteotomy; Postoperative complications; Total hip replacement

Introduction

Developmental dysplasia of the hip (DDH) is a condition characterized by morphological abnormalities of the acetabulum and femur. During its diagnosis, DDH is classified according to dislocation severity, most commonly based on the Crowe rubric, wherein type IV is the most severe of four types¹. Due to the pathological anatomical changes that accompany this condition, primary total hip arthroplasty (THA) is complicated and difficult in patients with Crowe type IV (type IV from here forward for simplicity) DDH, especially the hip reduction component of the operation.

In the 1970s, John Charnley introduced the trochanteric osteotomy for complicated primary hip replacement,

including in patients with type IV DDH². Subsequently, additional operation techniques, with and without osteotomy, have been developed to facilitate reduction during THA. Although several such surgical protocols have been reported to yield excellent results, each has drawbacks. Poor bone stock, massive soft tissue release, lengthened legs after surgery, and anatomical abnormalities can put type IV DDH patients at risk of postoperative complications, such as leg length discrepancy (LLD), peri-operative femur fracture, nonunion of the osteotomy site, and nerve injury^{1,3,4}.

The primary aim of this paper was to review THA procedures, including introducing a direct anterior approach (DAA) THA procedure, for use in patients with type IV DDH.

Address for correspondence Jian-guo Liu, MD, PhD, Jilin University First Hospital, No. 71, Xinmin Street, Chaoyang District, Changchun, Jilin, China 130000 Tel: +86-013756661600; Email: liujg6@126.com

Disclosure: The authors declare that the research was conducted in the absence of any commercial or financial relationships that could be construed as a potential conflict of interest.

All authors are in agreement with the content of the manuscript. The content has not been published or submitted for publication elsewhere except as a brief abstract in the proceedings of a scientific meeting or symposium.

Received 28 June 2019; accepted 20 October 2019

Potential reasons for postoperative complications in type IV DDH patients and options for their management are discussed. We conducted a search of the PubMed database with the key-word “dysplasia hip” and a date range of 1 January 2012 to 31 December 2019, which yielded approximately 2400 potentially relevant studies. From the retrieved literature, we excluded studies involving pediatric patients, pelvic osteotomy, and/or low-grade (i.e. dislocation type) DDH. Ultimately, we included 64 papers related to THA for type IV DDH in this study.

Direct Anterior Approach Total Hip Arthroplasty

Traditional THA approaches, including lateral, posterolateral, and posterior approaches, have been reported to yield excellent results in patients with DDH^{3–6}. However, these traditional approaches are associated with some degree of muscle injury, with postoperative dislocation rates of up to 16.6%⁷. Type IV DDH is associated with hip muscle weakness that may put these patients at particular risk of postoperative dislocation⁸.

In THA, a DAA enables the hip muscles to be accessed through inter-nerve and inter-muscle pathways, and has been gaining favor. Compared with other approaches, a DAA has advantages of faster recovery, less pain, and a lower postoperative dislocation rate^{9,10}. Hence, at least theoretically, a DAA seems to be the most appropriate approach for THA. Oinuma and colleagues described a case series of 12 totally dislocated hips treated by DAA THA with subtrochanteric osteotomy¹¹. For the operations, they placed each patient in a supine position with the operating table adjusted to 15°–20° to put the patient’s body in hyperextension. To expose the distal femur, which can be difficult in type IV dysplasia if a subtrochanteric osteotomy is needed, they released the posterior hip capsule, piriformis tendon, obturator internus, and the superior and inferior gemelli. The proximal femur was then moved out of the wound and femoral canal reaming was completed. Blunt dissection of the vastus intermedius was completed to enable subtrochanteric osteotomy to be completed. Over a mean follow-up period of 3.7 years, Oinuma *et al.* did not observe any occurrences of motor nerve palsy or infection and no revision operations were needed¹¹. This non-occurrence of postoperative complications was attributed to abductor muscle preservation, which also enabled full weight-bearing by 1 week postoperatively, compared with 3–16 weeks with traditional approaches. In a study of 50 dysplastic hips subjected to DAA THA and follow-up MRI 1 year later, Kawasaki and colleagues noted damage to the gluteus minimus, obturator internus, and tensor fasciae latae without damage to the gluteus medius and piriformis¹².

Potential drawbacks of DAA THA include risk of nerve dysfunction, intraoperative femoral fracture, wound complications, early femoral failure, and dislocation. Such complications may be avoided by experienced DAA operators; however, the DAA learning curve is steep^{13–16}.

Traditional Approaches for Total Hip Arthroplasty

Reconstruction of the acetabulum at its original position is now the generally accepted optimal choice. The main anatomic hip center techniques share common elements. On the acetabular side, a femoral head resection is performed, followed by identification of the true acetabulum, which can be found by following the inferior joint capsule¹⁷ or by identification relative to the transverse and round ligaments¹⁸. After the true acetabulum has been exposed by removal of scar tissue and osteophytes, it can be reamed to the appropriate size and placed in an appropriate cup and liner. Original acetabular reaming commences with a small reamer, taking care to avoid overreaming of the anterior or posterior acetabular column. According to Zhu and Li¹⁹, after preoperative mapping, reamers can be held with a 30°–50° abduction and 5°–25° anteversion position and the acetabulum should be reamed postero-superiorly to maximize cup coverage. Finally, a cup inclination angle of –40° with a 20°–25° anteversion is generally appropriate. After cup insertion, dome screws are inserted to improve cup stability. According to Tikhilov *et al.*, dome screws provide reliable cup stability when there is >65% cup coverage. Additional cup support techniques can be performed if there is <65%–70% cup coverage. The resected femoral head is used for bone autografting^{7,19–22}.

On the femur side, the first step is to expose the proximal femur, followed by intramedullary reaming with modular or custom implants (special reaming tools are provided by the manufacturer). If the femoral anteversion is <25°, a monoblock stem can be selected; if a non-modular stem is recommended, femoral stem anteversion should be adjusted to 15°–20°. Then, a trial stem is inserted into the medullary cavity and reduced as needed. If sufficient stem reduction cannot be achieved after releasing the soft tissues, then osteotomy should be considered. Osteotomy should be planned for preoperatively if the leg will be lengthened by ≥3–4 cm to reduce the risk of sciatic nerve complications. Prior to completing the hip reduction, to facilitate reduction, extensive soft tissue releasing should be completed, including (potentially as needed) release of the adductor, iliotibial tract, gluteus maximus, iliopsoas, rectus femoris, sartorius, piriformis, gracilis, and biceps femoris. All aspects of soft tissue release should be done in accordance with the specific operative conditions and case characteristics. During post-hip-reduction leg-length lengthening, which may be quite extensive in these patients, the hip and knee are kept in flexion to protect the sciatic nerve. Postoperatively, the flexion angles of the joints should be decreased gradually according to the patients’ neurological signs^{8,18,20,21,23}.

In general, the question of whether the acetabular or femoral side procedures should be completed first is dependent on operator preference. In some cases, the sciatic nerve is separated at the beginning of the operation and then palpated later to confirm preservation of moderate tension. Because type IV dysplasia hips have substantial anteversion of the acetabulum and femur, combined anteversion of the limb under 55° (20°–25° and 15°–20° for the cup and stem,

respectively) is used to avoid postoperative dislocation. Following this principle, in a series of 16 type IV dysplasia hip cases, Zhu and colleagues²⁴ set the cup anteversion according to the native acetabular anteversion to enable preferable cup coverage. Following subtrochanteric osteotomy, they rotated the proximal femur backward to maintain appropriate combined anteversion. Preoperatively, the mean (\pm standard deviation) femur, acetabular, and combined anteversion extents were $57.5^\circ \pm 9.6^\circ$, $31.0^\circ \pm 2.4^\circ$, and $88.6^\circ \pm 9.4^\circ$, respectively. After THA, the mean femur, acetabular, and combined anteversion extents were $17.9^\circ \pm 2.9^\circ$, $31.2^\circ \pm 2.5^\circ$, and $49.2^\circ \pm 2.6^\circ$. No dislocations occurred during 12 months of follow up^{20,21,24,25}. The main complications that occur following application of an anatomic hip center technique are summarized in Table 1.

Because it is difficult to reconstruct the hip center at its original position in type IV DDH cases involving a small, shallow true acetabulum, the high hip technique, wherein the acetabulum is reconstructed superior to the anatomic one, may be employed²⁶. Using a high hip center technique in a cohort of 84 patients, Montalti and colleagues obtained mean vertical and horizontal distances from the rotational center of 33 ± 8 mm and 30 ± 5 mm in type III DDH cases and IV DDH cases, respectively²⁷. After 15 years, revision was performed in only 2 of those cases due to aseptic loosening (one cup and one stem)²⁷. Galea *et al.* obtained mean hip center heights of 21.2 mm and 28.4 mm superior to the inter-teardrop line (ITL) in a THA study involving 74 nondysplastic/Crowe type I hips and 49 type II–IV dysplastic hips, respectively²⁸. After a mean follow-up period of 13.8 years, the patients treated for type II–IV DDH had a mean Harris hip score of 89.9; none of the patients suffered dislocation, and hip center height was not associated with Harris hip scores or polyethylene wear rate. However, patients with type IV DDH are at increased risk of postoperative dislocation and of needing revision surgery following hip center reconstruction. In a 30-year follow-up study of 49 patients with type II DDH, Watts *et al.* found cup and stem loosening rates of 68% and 29%, respectively, in cases with a reconstructed hip center that was ≥ 35 mm superior to the ITL, versus 35% and 18%, respectively, in cases with a hip center that was < 35 mm superior to ITL²⁹. In a retrospective review of 1079 THA-treated patients with DDH with a mean follow-up of 74.3 months, Komiyama *et al.* found that mean hip center height was significantly greater in dislocation cases (29.7 mm superior to the ITL) than in non-dislocation cases (24.1 mm superior to the ITL)³⁰.

Osteotomy Techniques

When an acetabular prosthesis is placed in a type IV dysplastic hip, osteotomy is always needed to facilitate reduction while avoiding nerve complications⁷. Specifically, osteotomy helps to prevent soft tissue contracture and to protect the sciatic nerve by lessening leg lengthening^{7,31}. Osteotomy techniques used for this purpose include greater trochanter, lesser trochanter, and subtrochanteric osteotomy. Subtrochanteric

osteotomy can be performed several ways, including transverse, oblique, double chevron (V-shaped), step-cut (Z-shaped), and sigmoid methods (Fig. 1).

Transverse osteotomy is the simplest osteotomy technique. It requires only two transverse cuts to the femur below the lesser trochanter and does not require the use of any specialized instruments. Before the first cut, an upright line should be made along the long axis of the femur with an electric knife to serve as a rotational alignment marker. The first transverse cut is 1 cm distal to the lesser trochanter (~ 10 cm below the tip of greater trochanter). After a trial stem and head have been applied, the proximal femur can be reduced into the acetabulum. The distal femur should be tracked distally with appropriate force, and then the overlapping portion of the femur should be removed by the second transverse cut. After preparation of the distal femur, a femoral component is inserted. With a non-modular stem, the original excess anteversion of the femur can be restored to a normal range by rotating the two femur fragments. If the reduction is not satisfactory due to insufficient femur removal, a repeat osteotomy can be performed (Fig. 2)^{17,18,32–34}.

In oblique osteotomy, the first osteotomy line is made approximately 1 cm below the lesser trochanter, like in transverse osteotomy except that the line is made at an angle (upward or downward lateral). Although some authors have suggested a 45° oblique osteotomy line, to our knowledge, a significant association between line angle and operation outcome has not been established (Fig. 3)^{35,36}.

Double chevron osteotomy can also be performed as a combined double chevron osteotomy, wherein a transverse osteotomy is first completed to shorten the femur and then the proximal and distal fragments are adjusted to an appropriate anteversion. The transverse osteotomy geometry is then remodeled into a double chevron. After a transverse cut of the femur has been made and the length of femur to be removed has been determined, the double chevron osteotomy site can be marked with ink and then proximal and distal chevron osteotomies can be completed with a reciprocating saw. Double chevron osteotomy can be completed with specialized devices as well, such as multi-holed broaches, femoral cutting slot guides, and guide pins^{37–39}.

A step-cut osteotomy can be done alone or in conjunction with a transverse osteotomy. In the latter case, the transverse osteotomy is completed first to shorten the femur, then the step-cut osteotomy is completed to enhance rotational stability. For the step-cut osteotomy, the femur is first cut in the transverse axis 2–5 cm below the lesser trochanter. Then, the reduction is completed after a stem is placed in the proximal part of the femur. After traction of the distal femur part, the length of overlap is taken as the overall femur length that should be eliminated, with half of the bone volume to be eliminated being taken from the proximal femoral fragment and half being taken from the distal femoral fragment. If the femoral anteversion needs to be adjusted by osteotomy, the

TABLE 1. Outcomes and complications of anatomic hip center techniques

Study	Osteotomy form	Patients (hips)	Mean age (years, range)	Mean follow-up (years, range)	Preoperative function score	Postoperative function score	Osteotomy Site malunion	Nerve syndrome (temporary/permanent)	Post-surgery dislocation	Intraoperative fracture	Preoperative LLD (cm, range)	Postoperative LLD (cm, range)	Revision hips
Kose et al. ²⁷	Transverse	15(21)	41.0 (24-56)	5.0 (3-8)	HHS: 36.2 ± 9.8	HHS: 90.8 ± 2.5	0	1/1	2	5	*	*	2
Ozan et al. ²⁸	Transverse	25(25)	51.4 (35-70)	5.1 (2-7)	HHS: 49.5 (25-72)	HHS: 87.1 (74-94)	1	0/0	3	*	3.6 (1.0-5.5)	0.5 (0-1.5)	0
Imarisio et al. ²⁹	Transverse	17 (18)	50.0 (33-71)	4.2 (1-10)	HHS: 89.0 (78-97)	HHS: 89.0 (78-97)	0	1/0	2	1	4.8 (0-7.5)	0.8 (0-4)	0
Zhou et al. ¹⁴	Transverse	62 (76)	46.5 (19-73)	10.0 (6.6-13.2)	HHS: 38.8 (21-59)	HHS: 86.1 (76-98)	1	2/0	3	4	4.3 (2.1-6.5)	1.0 (0.6-1.7)	2
Zarei et al. ³¹	Transverse	48 (52)	41.0 (19-55)	*(1-3)	HHS: 41.70 (32-46)	HHS: 88.1 (74-94)	0	2/0	0	0	5.0 (2-7)	1.0 (0-2)	1
Liu et al. ³²	Transverse	45(52)	40.6 (18-62)	9.8 (8.9-11.8)	HHS: 33.7 ± 4.7	HHS: 89.8 ± 7.1	0	2/0	2	0	4.38 ± 0.75	0.71 ± 0.37	0
Kilicoglu et al. ³³	Oblique	16 (20)	43.4 (27-60)	6.8 (3.7-10.3)	HHS: 50.0 (32-69)	HHS: 83 (75-93)	1	0/0	3	3	*	1.0 (0-3)	2
Bianchi et al. ³⁴	Oblique	12 (16)	53.2 (34-70)	8.7 (4-13)	HHS: 37.2 (24-58)	HHS: 83.7 (65-97)	1	0/0	3	2	*	*	0
Vicenti et al. ³⁵	8 cases Z-shaped and 9 cases transverse	15 (17)	38.6 (28-68)	7.3 (5.3-11.1)	HHS: 38.3 (32-52)	HHS: 85.6 (69-90)	0	2/0	0	1	4.5 (3.8-7.0)	1.2 (0.9-1.6)	0
Neumann et al. ³⁶	Z-shaped	12 (16)	58 (20-67)	5.0 (3-8)	HHS: 35.9 (20-65)	HHS: 94.3 (82-100)	0	0/0	0	0	3.0 (0-7.0)	8 cases < 1, 1 ≤ 4	0
Hasegawa et al. ³⁷	Z-shaped	18 (20)	58.5 (48-72)	10.2 (5-20)	HHS: 56.1 (54-65)	HHS: 84.5 (77-93)	0	2/0	3	0	3.8 (0.5-7.3)	1.4 (-1-5.5)	4
Sonohata et al. ³⁸	Double chevron	28 (36)	58.0 (39-77)	7.3 (5-13)	JOA: 48.1 ± 18.1	JOA: 83.1 ± 13.7	1	1/0	4	3	*	*	2
Koulouvaris et al. ⁴¹	Distal transverse	24(24)	45.8(22-69)	4.6(2.3-6.0)	MMP: 9.96 (6-12)	MMP: 17.2 (15-18)	1	*	*	*	2.0 (0-4.5)	0.16 (0-0.28)	0
Hartofilakidis et al. ⁴⁵	Greater trochanteric	140 (192)	50.0 (23-77)	*(10-34)	*	*	32	5/3	6	*	*	*	71
Zhao et al. ⁴⁷	Lesser trochanteric	28 (30)	35.3 (17-67)	4.6 (2-11)	MAP: 9.3 (6.1-11.5)	MAP: 15.9 (12.1-17.2)	†	2/0	0	3	4.7 (0.7-6.2)	0.8 (0.3-1.5)	0
Wu et al. ⁵²	None	46(50)	*(38-77)	6.4 (2.2-11.5)	HHS: 40.2 (*)	HHS: 86.5 (*)	†	0/0	1	0	*	1.3 (0-1.6)	0
Yan et al. ⁵⁰	None	25 (28)	33 (19-58)	*(1-4.2)	*	HHS: 87.3 ± 10.6	†	4/0	0	0	4.6 (3.0-6.5)	0.5 (0-1.6)	0
Zhu et al. ⁵¹	None	74 (82)	55.8 (20-80)	5.1 (2-8)	HHS: 42.1 (24-71)	HHS: 89.9 (76-100)	†	0/0	1	1	*	0.4 ± 0.5	1
Imbuldeniya et al. ⁴⁹	None	21 (25)	47.0 (23-89)	18.7(15.8-21.8)	HHS: 46 (29-63)	HHS: 90 (73-98)	†	0/0	1	2	*	1.1 (0-1.6)	17

*Never mentioned in original paper. †impossible for this condition to occur. LLD, leg length discrepancy.

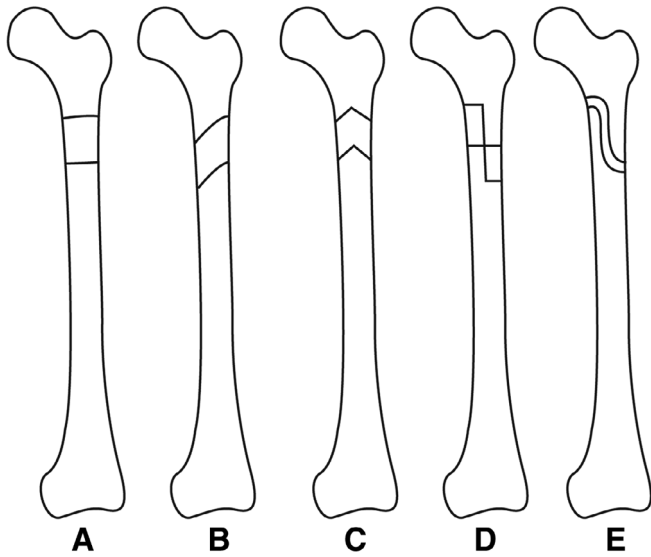


Fig. 1 Types of subtrochanteric osteotomy: (A) transverse, (B) oblique, (C) double chevron, (D) step-cut, and (E) sigmoid.

half-bone-volume of the distal femoral part is removed while the proximal part is held at the appropriate position (Fig. 4)⁴⁰⁻⁴².

For a subtrochanteric osteotomy, the location of cuts may be proximal or distal. With a distal osteotomy, valgus knee deformity can be corrected in the process of femur shortening. However, a distal osteotomy requires a long incision⁴³.

Among the subtrochanteric osteotomy types, transverse osteotomy has generally been favored due to its procedural simplicity, satisfactory clinical outcomes, and relatively high error-tolerance. Step-cut and sigmoid osteotomies have been shown to provide greater rotational stability and more

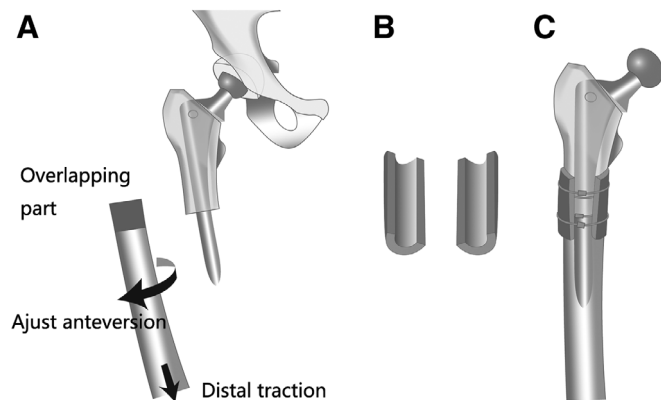


Fig. 2 Transverse osteotomy procedure: (A) after distal traction, overlapping femur is resected and the femoral anteversion can be adjusted; (B) the removed overlapping femur bone piece is split vertically into two hemi-cylinder-shaped halves; and (C) after final insertion of the femoral prosthesis, the two hemi-cylinder-shaped halves of the resected overlapping femur piece can be used to support fixation of the osteotomy site.

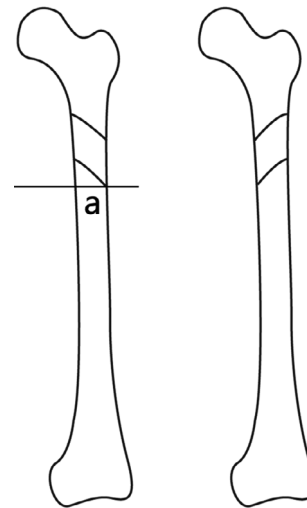


Fig. 3 Oblique osteotomy procedure. Upward lateral and downward lateral osteotomy lines are introduced with angle "a" between them. It has been recommended that angle "a" should be 45°, although an optimal angle has not been demonstrated empirically.

bony surface contact to support early bone tissue union than transverse osteotomies³¹. However, to our knowledge, they have not been shown to lead to superior clinical results. Meanwhile, the corners of a step-cut osteotomy may be at increased risk of fracture³¹. In contrast, transverse, oblique, step-cut, and double chevron osteotomies were found to have statistically similar levels of stability in a biomechanical experiment⁴⁴. In a meta-analysis of 37 studies (795 hips), Li and colleagues found that modified osteotomy (oblique, step-cut, and double-chevron) techniques were associated with

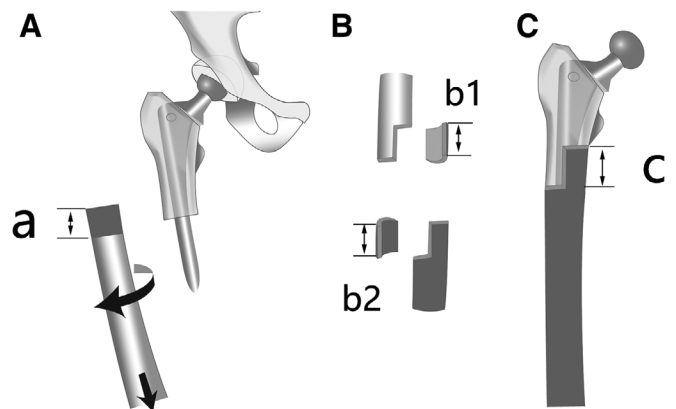


Fig. 4 Step-cut osteotomy procedure: (A) after distal femur traction, the length of overlap (a) is determined and femoral anteversion is adjusted; (B) mirrored proximal (b1) and distal (b2) femoral fragments are removed, such that $a = b1 = b2$; and (C) final insertion of femoral prosthesis is performed ($c = a = b1 = b2$).

bone union, nerve palsy, dislocation, and revision rates and clinical Harris hip scores that were similar to those obtained with classic transverse osteotomy⁴⁵.

Trochanteric osteotomy, originally developed from low-friction arthroplasty², presents advantages for THA of dysplastic hips, including favorable exposure of the acetabulum and proximal femur and a substantial abductor lever arm after reattachment of the greater trochanter. However, trochanteric osteotomy has been reported to have a relatively low bony union rate (82%) and, thus, conversely, a high non-union rate (1%–32%)^{2,46,47}. Lesser trochanter osteotomy has been used to treat high dislocated dysplasia hips. Although it can result in better bony union than subtrochanter and trochanter osteotomies, it limits the femur length reduction extent that is possible and has been associated with abductor weakness⁴⁸.

No Osteotomy Total Hip Arthroplasty

Total hip arthroplasty of dislocated dysplasia hips can be completed without osteotomy in a one-stage or two-stage protocol. Obviation of the osteotomy has several potential benefits: (i) avoidance of the risk of osteotomy site non-union; (ii) no femur shortening, which may lead to truly equal-length legs; and (iii) no need for internal femur fixation.

In two-stage THA, the first stage involves femoral head resection, soft tissue release, and prosthesis insertion. At the conclusion of the first stage, an external fixator system is constructed with pins and distraction tubes around the hip to pull the femur gradually into a more distal location until the femoral neck is at the level of the anatomic acetabulum. Approximately 2 weeks later, in the second stage, the external fixator system is removed and THA of the affected hip is completed. Two-stage THA reduces neurovascular damage risk, but the use of pins in the first stage may lead to infection risk and patients need to spend more days in the hospital than with other methods⁴⁹.

One-stage THA without osteotomy has been reported to produce excellent long-term functional results but has been associated with three notable drawbacks: (i) challenging hip reduction; (ii) high sciatic nerve complication risk; and (iii) difficulty achieving appropriate soft tissue release^{8,23,50,51}. Methods that have been used to facilitate hip reduction in single-stage THA without osteotomy include use of a low femoral-neck osteotomy line (as low as the lesser trochanter)⁵⁰, powerful pharmacological muscle relaxation combined with a special reduction position²³, and artful usage of a Hohmann retractor⁵¹. To our knowledge, the evidence regarding sciatic nerve complication risk in single-stage THA without osteotomy is inconclusive. Notwithstanding, insufficient soft tissue release during single-stage THA can lead to unsuccessful reduction, whereas excessive soft tissue release may lead to a high dislocation risk and hip dysfunction postoperatively. To address this soft tissue release challenge, Wu and colleagues recommend releasing of the following muscles, in this order, until sufficient release is

achieved: (i) adductor, iliotibial tract, and gluteus maximus; (ii) iliopsoas, rectus femoris, and sartorius; and, finally, (iii) piriformis and hamstrings⁸. If reduction remains difficult after release of all of these muscles, Wu and colleagues recommend osteotomy⁸.

Postoperative Complications

Following THA, LLD is a common complication, especially among patients who present with a severe unilateral dislocation. Postoperative functional LLD in patients treated for type IV DDH is affected by many factors, including bony LLD, pelvic tilt, pelvic imbalance development, spinal lateral curve, spinal deformity, and postoperative prosthesis position. Li *et al.* found an average bony LLD of 3.5 ± 3.0 mm (bony leg length measured from greater trochanter tip to ankle center) in a sample of 78 type IV DDH patients (70 unilateral and 8 bilateral)⁵². Zhang *et al.* measured skeletal limb length (from the femoral head tip to the midpoint of the tibial plafond) of 67 unilateral DDH patients (32 Hartofilakidis type II and 35 Hartofilakidis type III) and found that skeletal limb length on the affected side was >5 mm longer than that on the contralateral side in one-third of the patients⁵³. Meanwhile, Bilgen *et al.* reported that the acetabular area on the affected side was 11 mm more distal than that of the contralateral side in Crowe type IV DDH patients⁵⁴. To protect the sciatic nerve, leg length is often sacrificed by osteotomy in cases of a severely dislocated femoral head and extensive soft tissue contracture. Although any single factor alone may not disrupt postoperative functional LLD, they may have a clinically significant combined influence on LLD.

Leg length discrepancy is a common post-THA complication and concerns related to LLD can cause anxiety and depression in DDH patients⁵⁵. Fujimaki *et al.* found that patient outcomes are compromised when LLD is ≥ 5 mm after THA⁵⁶, and Chen *et al.* noted that a postoperative LLD of ≥ 10 mm leads to gait asymmetry⁵⁷. When clinically significant LLD does occur after THA, additional physical therapy should be applied for 6 months. If physical therapy does not correct the problem satisfactorily, then a shoe lift should be considered. In severe cases, a second surgery can be performed. If the contralateral hip is also in need of THA, then the LLD can be solved with the contralateral operation⁵⁸. Thakral *et al.* introduced a surgical technique for contralateral leg lengthening to correct LLD⁵⁹. If contralateral leg lengthening is contraindicated, shortening of the THA leg may be considered⁶⁰.

Due to the narrow femoral canal, intra-operative femur fractures can occur in 5.2%–26.8% of THA cases²⁰. These fractures can be treated with wire-plate internal fixation. If the femoral canal is too narrow to allow insertion of the smallest available stem, then the femur can be split anteriorly and posteriorly for 4–10 cm⁶.

A challenging reduction process during THA can put patients at increased risk of osteotomy site nonunion (rate range, 2.8%–7.1%)²⁰. Nonunion risk can be mitigated with

plate and screw fixation^{27,31}, an eagle claw hook and cable system,³ or the application of cerclage wires to two longitudinally split halves of resected femur³⁵.

The main causes of nerve injury complications in DDH patients continue to be debated. Eggli *et al.* have suggested that nerve injury is caused mainly by direct damage during the operation, rather than leg lengthening⁶¹. However, excessive limb lengthening is considered by many surgeons to be the main cause of post-THA nerve injury. If so, limiting the extent of lengthening to no more than 3–4 cm may reduce nerve injury risk. When osteotomy is applied during THA, reported nerve injury rates range from 5% to 11.3%²⁰. However, in most cases, nerve injury symptoms resolve within 6 months. Even among patients who suffered nerve injury following hip reconstruction at the anatomic acetabulum with extensive leg lengthening (>4 cm), with a nerve injury rate of 14.3%, patients' nerve symptoms recovered quickly⁵¹. Methods used to prevent nerve injury include separating the sciatic nerve and applying palpitation to control its tension²¹, nerve stimulation⁶², and femur traction with delayed postoperative reduction⁶³.

Conclusion

Despite the characteristic complications associated with the approach, THA by a DAA can produce satisfactory

treatment outcomes for type IV DDH. High hip center reconstruction produces satisfactory clinical results in the short term but has been associated with higher long-term revision and dislocation rates than reported for reconstruction at the anatomical acetabulum. Reconstruction of type IV DDH at the original acetabulum requires femur osteotomy to enable appropriate hip reduction and prevent nerve injury. Greater trochanter osteotomy, the first procedure applied to treat type IV DDH, produces poor union conditions at the osteotomy site. Meanwhile, lesser trochanter osteotomy treatment of type IV DDH has the drawbacks of limited femur length shortening and a high risk of femur head dislocation. A variety of subtrochanteric osteotomy techniques have been applied to THA for type IV DDH, including transverse, oblique, double chevron, step-cut, and sigmoid methods. All of these subtrochanteric osteotomy techniques can produce excellent clinical results, with transverse osteotomy being appreciated for its simplicity and the other more complicated techniques being appreciated for their ability to provide greater rotational stability than transverse osteotomy. No-osteotomy THA methods can also provide satisfactory outcomes for type IV DDH but are associated with elevated risk of complications, such as LLD, intra-operative femur fracture, osteotomy site nonunion, and nerve injury.

References

1. Crowe JF, Mani VJ, Ranawat CS. Total hip replacement in congenital dislocation and dysplasia of the hip. *J Bone Joint Surg Am*, 1979, 61: 15–23.
2. Charnley J. Total hip replacement by low-friction arthroplasty. *Clin Orthop Relat Res*, 1970, 72: 7–21.
3. Sofu H, Kockara N, Gursu S, Issin A, Oner A, Sahin V. Transverse subtrochanteric shortening osteotomy during cementless total hip arthroplasty in Crowe type-III or IV developmental dysplasia. *J Arthroplasty*, 2015, 30: 1019–1023.
4. Mu W, Yang D, Xu B, Mamtimin A, Guo W, Cao L. Midterm outcome of cementless total hip arthroplasty in Crowe IV-Hartofilakidis type III developmental dysplasia of the hip. *J Arthroplasty*, 2016, 31: 668–675.
5. Ahmed E, Ibrahim e-G, Ayman B. Total hip arthroplasty with subtrochanteric osteotomy in neglected dysplastic hip. *Int Orthop*, 2015, 39: 27–33.
6. Li X, Lu Y, Sun J, Lin X, Tang T. Treatment of Crowe type-IV hip dysplasia using cementless total hip arthroplasty and double chevron subtrochanteric shortening osteotomy: a 5- to 10-year follow-up study. *J Arthroplasty*, 2017, 32: 475–479.
7. Greber EM, Pelt CE, Gililand JM, Anderson MB, Erickson JA, Peters CL. Challenges in total hip arthroplasty in the setting of developmental dysplasia of the hip. *J Arthroplasty*, 2017, 32: S38–S44.
8. Wu X, Li SH, Lou LM, Cai ZD. The techniques of soft tissue release and true socket reconstruction in total hip arthroplasty for patients with severe developmental dysplasia of the hip. *Int Orthop*, 2012, 36: 1795–1801.
9. Nogler MM, Thaler MR. The direct anterior approach for hip revision: accessing the entire femoral diaphysis without endangering the nerve supply. *J Arthroplasty*, 2017, 32: 510–514.
10. Taunton MJ, Trousdale RT, Sierra RJ, Kaufman K, Pagnano MW. John Charnley Award: randomized clinical trial of direct anterior and minimiposterior approach THA: which provides better functional recovery?. *Clin Orthop Relat Res*, 2018, 476: 216–229.
11. Oinuma K, Tamaki T, Miura Y, Kaneyama R, Shiratsuchi H. Total hip arthroplasty with subtrochanteric shortening osteotomy for Crowe grade 4 dysplasia using the direct anterior approach. *J Arthroplasty*, 2014, 29: 626–629.
12. Kawasaki M, Hasegawa Y, Okura T, Ochiai S, Fujibayashi T. Muscle damage after total hip arthroplasty through the direct anterior approach for developmental dysplasia of the hip. *J Arthroplasty*, 2017, 32: 2466–2473.
13. Lee GC, Marconi D. Complications following direct anterior hip procedures: costs to both patients and surgeons. *J Arthroplasty*, 2015, 30: 98–101.
14. Meneghini RM, Elston AS, Chen AF, Kheir MM, Fehring TK, Springer BD. Direct anterior approach: risk factor for early femoral failure of cementless total hip arthroplasty: a multicenter study. *J Bone Joint Surg Am*, 2017, 99: 99–105.
15. Eto S, Hwang K, Huddleston JI, Amanatullah DF, Maloney WJ, Goodman SB. The direct anterior approach is associated with early revision total hip arthroplasty. *J Arthroplasty*, 2017, 32: 1001–1005.
16. Meermans G, Konan S, Das R, Volpin A, Haddad FS. The direct anterior approach in total hip arthroplasty: a systematic review of the literature. *Bone Joint J*, 2017, 99: 732–740.
17. Baz AB, Senol V, Akalin S, Kose O, Guler F, Turan A. Treatment of high hip dislocation with a cementless stem combined with a shortening osteotomy. *Arch Orthop Trauma Surg*, 2012, 132: 1481–1486.
18. Wang D, Li DH, Li Q, *et al.* Subtrochanteric shortening osteotomy during cementless total hip arthroplasty in young patients with severe developmental dysplasia of the hip. *BMC Musculoskelet Disord*, 2017, 18: 491.
19. Xu J, Xu C, Mao Y, Zhang J, Li H, Zhu Z. Posterosuperior placement of a standard-sized cup at the true acetabulum in acetabular reconstruction of developmental dysplasia of the hip with high dislocation. *J Arthroplasty*, 2016, 31: 1233–1239.
20. Wang D, Li LL, Wang HY, Pei FX, Zhou ZK. Long-term results of cementless total hip arthroplasty with subtrochanteric shortening osteotomy in Crowe type IV developmental dysplasia. *J Arthroplasty*, 2017, 32: 1211–1219.
21. Krych AJ, Howard JL, Trousdale RT, Cabanela ME, Berry DJ. Total hip arthroplasty with shortening subtrochanteric osteotomy in Crowe type-IV developmental dysplasia. *J Bone Joint Surg Am*, 2009, 91: 2213–2221.
22. Tikhilov R, Shubnyakov I, Burns S, *et al.* Experimental study of the installation acetabular component with uncoverage in arthroplasty patients with severe developmental hip dysplasia. *Int Orthop*, 2016, 40: 1595–1599.
23. Yan F, Chen G, Yang L, He R, Gu L, Wang F. A reduction technique of arthroplasty without subtrochanteric femoral shortening osteotomy for the treatment of developmental high dislocation of hip: a case series of 28 hips. *J Arthroplasty*, 2014, 29: 2289–2293.
24. Zhu B, Su C, He Y, *et al.* Combined anteversion technique in total hip arthroplasty for Crowe IV developmental dysplasia of the hip. *Hip Int*, 2017, 27: 589–594.
25. Shi XT, Li CF, Cheng CM, Feng CY, Li SX, Liu JG. Preoperative planning for total hip arthroplasty for neglected developmental dysplasia of the hip. *Orthop Surg*, 2019, 11: 348–355.
26. Dapuzzo MR, Sierra RJ. Acetabular considerations during total hip arthroplasty for hip dysplasia. *Orthop Clin North Am*, 2012, 43: 369–375.

27. Montalti M, Castagnini F, Giardina F, Tassinari E, Biondi F, Toni A. Cementless total hip arthroplasty in Crowe III and IV dysplasia: high hip center and modular necks. *J Arthroplasty*, 2018, 33: 1813–1819.
28. Galea VP, Laaksonen I, Donahue GS, *et al*. Developmental dysplasia treated with cementless total hip arthroplasty utilizing high hip center reconstruction: a minimum 13-year follow-up study. *J Arthroplasty*, 2018, 33: 2899–2905.
29. Watts CD, Abdel MP, Hanssen AD, Pagnano MW. Anatomic hip center decreases aseptic loosening rates after total hip arthroplasty with cement in patients with Crowe type-II dysplasia: a concise follow-up report at a mean of thirty-six years. *J Bone Joint Surg Am*, 2016, 98: 910–915.
30. Komiya K, Fukushi JJ, Motomura G, *et al*. Does high hip centre affect dislocation after total hip arthroplasty for developmental dysplasia of the hip?. *Int Orthop*, 2019, 43: 2057–2063.
31. Cascio BM, Thomas KA, Wilson SC. A mechanical comparison and review of transverse, step-cut, and sigmoid osteotomies. *Clin Orthop Relat Res*, 2003, 411: 296–304.
32. Imarisio D, Trecci A, Sabatini L, Uslenghi M, Leone C, Scagnelli R. Cementless total hip replacement for severe developmental dysplasia of the hip: our experience in Crowe's group IV. *Musculoskelet Surg*, 2013, 97: 25–30.
33. Rasi AM, Kazemian G, Khak M, Zarei R. Shortening subtrochanteric osteotomy and cup placement at true acetabulum in total hip arthroplasty of Crowe III-IV developmental dysplasia: results of midterm follow-up. *Eur J Orthop Surg Traumatol*, 2018, 28: 923–930.
34. Zeng WN, Liu JL, Wang FY, *et al*. Total hip arthroplasty for patients with Crowe type IV developmental dysplasia of the hip: ten years results. *Int J Surg*, 2017, 42: 17–21.
35. Kiliçoğlu Öi, Türker M, Akgül T, Yazicioğlu O. Cementless total hip arthroplasty with modified oblique femoral shortening osteotomy in Crowe type IV congenital hip dislocation. *J Arthroplasty*, 2013, 28: 117–125.
36. Zagra L, Bianchi L, Mondini A, Ceroni RG. Oblique femoral shortening osteotomy in total hip arthroplasty for high dislocation in patients with hip dysplasia. *Int Orthop*, 2015, 39: 1797–1802.
37. Sonohata M, Kitajima M, Kawano S, Tanaka R, Mawatari M. Total hip arthroplasty with femoral subtrochanteric osteotomy after Schanz osteotomy. *J Orthop Sci*, 2016, 21: 469–474.
38. Hotokebuchi T, Sonohata M, Shigematsu M, Mawatari M. A new device for a V-shaped subtrochanteric osteotomy combined with total hip arthroplasty. *J Arthroplasty*, 2006, 21: 135–137.
39. Sonohata M, Tajima T, Kitajima M, *et al*. Total hip arthroplasty combined with double-chevron subtrochanteric osteotomy. *J Orthop Sci*, 2012, 17: 382–389.
40. Rollo G, Solarino G, Vicenti G, Picca G, Carozzo M, Moretti B. Subtrochanteric femoral shortening osteotomy combined with cementless total hip replacement for Crowe type IV developmental dysplasia: a retrospective study. *J Orthop Traumatol*, 2017, 18: 407–413.
41. Neumann D, Thaler C, Dorn U. Femoral shortening and cementless arthroplasty in Crowe type 4 congenital dislocation of the hip. *Int Orthop*, 2012, 36: 499–503.
42. Hasegawa Y, Iwase T, Kanoh T, Seki T, Matsuoka A. Total hip arthroplasty for Crowe type IV developmental dysplasia. *J Arthroplasty*, 2012, 27: 1629–1635.
43. Koulouvaris P, Stafylas K, Sculco T, Xenakis T. Distal femoral shortening in total hip arthroplasty for complex primary hip reconstruction. A new surgical technique. *J Arthroplasty*, 2008, 23: 992–998.
44. Muratli KS, Karatosun V, Uzun B, Celik S. Subtrochanteric shortening in total hip arthroplasty: biomechanical comparison of four techniques. *J Arthroplasty*, 2014, 29: 836–842.
45. Li C, Zhang C, Zhang M, Ding Y. Comparison of transverse and modified subtrochanteric femoral shortening osteotomy in total hip arthroplasty for developmental dysplasia of hip: a meta-analysis. *BMC Musculoskelet Disord*, 2014, 15: 331.
46. Necessian OA, Newton PM, Joshi RP, Sheikh B, Eftekhar NS. Trochanteric osteotomy and wire fixation: a comparison of 2 techniques. *Clin Orthop Relat Res*, 1996, 333: 208–216.
47. Hartofilakidis G, Babis GC, Georgiades G, Kourlaba G. Trochanteric osteotomy in total hip replacement for congenital hip disease. *J Bone Joint Surg Br*, 2011, 93: 601–607.
48. Bao N, Meng J, Zhou L, Guo T, Zeng X, Zhao J. Lesser trochanteric osteotomy in total hip arthroplasty for treating CROWE type IV developmental dysplasia of the hip. *J Arthroplasty*, 2013, 37: 385–390.
49. Binazzi R. Two-stage progressive femoral lowering followed by cementless total hip arthroplasty for treating Crowe IV-Hartofilakidis type 3 developmental dysplasia of the hip. *J Arthroplasty*, 2015, 30: 790–796.
50. Imbuldeniya AM, Walter WL, Zicat BA, Walter WK. Cementless total hip replacement without femoral osteotomy in patients with severe developmental dysplasia of the hip: minimum 15-year clinical and radiological results. *Bone Joint J*, 2014, 96: 1449–1454.
51. Li H, Yuan Y, Xu J, Chang Y, Dai K, Zhu Z. Direct leverage for reducing the femoral head in total hip arthroplasty without femoral shortening osteotomy for Crowe type 3 to 4 dysplasia of the hip. *J Arthroplasty*, 2018, 33: 794–799.
52. Li Y, Zhang X, Wang Q, *et al*. Equalisation of leg lengths in total hip arthroplasty for patients with Crowe type-IV developmental dysplasia of the hip: classification and management. *Bone Joint J*, 2017, 99: 872–879.
53. Zhang Z, Luo D, Cheng H, Xiao K, Zhang H. Unexpected long lower limb in patients with unilateral hip dislocation. *J Bone Joint Surg Am*, 2018, 100: 388–395.
54. Bilgen ÖF, Salar N, Bilgen MS, Mutlu M, Kara GK, Gürsel E. The effect of dislocation type (Crowe types I–IV) on pelvic development in developmental dysplasia of the hip: a radiologic study of anatomy. *J Arthroplasty*, 2015, 30: 875–878.
55. Liu R, Li Y, Fan L, Mu M, Wang K, Song W. Depression and anxiety before and after limb length discrepancy correction in patients with unilateral developmental dysplasia of the hip. *J Psychosom Res*, 2015, 79: 574–579.
56. Fujimaki H, Inaba Y, Kobayashi N, Tezuka T, Hirata Y, Saito T. Leg length discrepancy and lower limb alignment after total hip arthroplasty in unilateral hip osteoarthritis patients. *J Orthop Sci*, 2013, 18: 969–976.
57. Chen G, Nie Y, Xie J, Cao G, Huang Q, Pei F. Gait analysis of leg length discrepancy-differentiated hip replacement patients with developmental dysplasia: a midterm follow-up. *J Arthroplasty*, 2018, 33: 1437–1441.
58. Ng VY, Kean JR, Glassman AH. Limb-length discrepancy after hip arthroplasty. *J Bone Joint Surg Am*, 2013, 95: 1426–1436.
59. Thakral R, Johnson AJ, Specht SC, *et al*. Limb-length discrepancy after total hip arthroplasty: novel treatment and proposed algorithm for care. *Orthopedics*, 2014, 37: 101–106.
60. Kasis AG, Stockley I, Saleh M. External fixator-assisted acute shortening with internal fixation for leg length discrepancy after total hip replacement. *Strategies Trauma Limb Reconstr*, 2008, 3: 3–8.
61. Eggl S, Hankemayer S, Müller ME. Nerve palsy after leg lengthening in total replacement arthroplasty for developmental dysplasia of the hip. *J Bone Joint Surg Br*, 1999, 81: 843–845.
62. Shemesh SS, Robinson J, Overley S, Bronson MJ, Moucha CS, Chen D. Novel technique for intraoperative sciatic nerve assessment in complex primary total hip arthroplasty: a pilot study. *Hip Int*, 2018, 28: 210–217.
63. Flanagan BA, Dushey CH, Rubin LE, Keggi KJ. Total hip arthroplasty followed by traction and delayed reduction for Crowe IV developmental dysplasia of the hip. *J Arthroplasty*, 2013, 28: 1052–1054.