

# Robotic-Assisted Laparoscopic Management of Ureteral Endometriosis

Anna C. Frick, MD, MPH, Ehab E. Barakat, MD, Robert J. Stein, MD,  
Michelle Mora, MD, Tommaso Falcone, MD

## ABSTRACT

Endometriosis is the leading cause of female pelvic pain and infertility and affects approximately 10% of women. Lesions involve the urinary tract in up to 6% of cases with ureteral involvement in a smaller subset of .08% to 1%. Multiple authors describe open and laparoscopic approaches to management of ureteral endometriosis; however, this report describes 2 cases of ureteral obstruction secondary to endometriosis managed with robotic-assisted laparoscopic partial ureterectomy and ureteroneocystostomy.

**Key Words:** Robotic, Endometriosis, Ureteral reimplantation.

## INTRODUCTION

Endometriosis is the leading cause of female pelvic pain and infertility and affects approximately 10% of women.<sup>1</sup> Lesions involve the urinary tract in up to 6% of cases<sup>2-4</sup> with ureteral involvement in a smaller subset of .08% to 1%.<sup>4,5</sup> Extrinsic endometriosis lesions invade the ureteral adventitia, while intrinsic lesions invade the ureteral muscularis. Both types can severely compromise urinary tract function and lead to renal failure.<sup>6</sup> Presentation is often asymptomatic (50%), though it may be associated with abdominal pain (17% to 26%), flank pain (17% to 26%), and hematuria (13% to 18%).<sup>7</sup>

Ureteral endometriosis can be managed either medically or surgically, though medical management is generally considered palliative. Surgical management of extrinsic lesions involves ureterolysis and excision of endometriosis, while intrinsic disease causing ureteral obstruction due to invasion of the ureteral muscularis or severe fibrosis necessitates resection of the affected ureteral segment. In cases of severe renal compromise, a nephrectomy should be considered.

Historically, ureteral resection and repair for infiltrating endometriosis have been performed via laparotomy, though laparoscopic approaches have been reported.<sup>8-10</sup> However, ureteral reimplantation involves precise movements and suturing with fine caliber suture, and as such, requires advanced laparoscopic skills to be performed successfully. Given that advocates of robotic-assisted surgery revere the system's wristed instrumentation, ergonomic positioning, and 3-dimensional high-definition vision system as significant improvements over the laparoscopic approach, ureteral resection and reimplantation for gynecologic surgery may provide a good application for robotic-assistance in gynecologic surgery. Thus, this report presents 2 cases of ureteral obstruction secondary to endometriosis managed with robotic-assisted laparoscopic partial ureterectomy and ureteroneocystostomy. The technical aspects of this procedure and its potential benefits over open and laparoscopic approaches are discussed.

## CASE REPORT ONE

Patient 1 is a 26-year-old referred for management of stage IV endometriosis. She had a history of 3 laparoscopic

Obstetrics, Gynecology and Women's Health Institute, Cleveland Clinic, Cleveland, Ohio, USA (Drs Frick, Barakat, Falcone), Glickman Urologic and Kidney Institute, Cleveland Clinic, Cleveland, Ohio, USA (Dr. Stein), Department of Anatomic Pathology, Cleveland Clinic, Cleveland, Ohio, USA (Dr Mora).

Address correspondence to: Anna C. Frick, 9500 Euclid Avenue, Desk A-81, Cleveland, Ohio 44195, USA. Telephone: (216) 445-6586, Fax: (216) 636-2620.

DOI: 10.4293/108680811X13125733356314

© 2011 by JSLs, *Journal of the Society of Laparoendoscopic Surgeons*. Published by the Society of Laparoendoscopic Surgeons, Inc.

procedures for excision of endometriosis, though previous surgeons were not able to remove all visible disease, and the patient suffered persistent dysmenorrhea, dyspareunia, and infertility. In November 2007, the patient underwent laparoscopic excision of endometriosis, bilateral ureterolysis, chromotubation, and an ovarian cystectomy for a left endometrioma. In July of 2009, she presented with flank pain to an outside hospital, where a CT scan revealed a right ureteral obstruction and multiple ovarian cysts. A ureteral stent was placed and removed 2 weeks later. She followed up at our institution where a diuretic radionuclide scan revealed mild right renal cortical thinning, and a right kidney function contribution of 44%. A retrograde pyelogram and ureteroscopy showed a focal stricture of the distal right ureter. A double-J stent was placed.

In August 2009, the patient underwent laparoscopic excision of endometriosis and robotic-assisted laparoscopic partial ureterectomy and ureteroneocystostomy. At the time of surgery, the patient was noted to have extensive fibrosis overlying the right pelvic sidewall, including the ureter. The proximal ureter was moderately dilated at the level of the iliac bifurcation. The cul-de-sac was obliterated, and there were severe adhesions of the bowel to both adnexa and a right endometrioma. We used a laparoscopic approach to perform right ureterolysis from the pelvic brim to the level of the uterine artery. Frozen section of a biopsy of periureteral tissue yielded endometriosis. Adhesiolysis was performed, and visible endometriosis implants were excised from the anterior abdominal wall.

The decision was made to proceed with resection of the affected ureteral segment due to the extensive peritoneal fibrosis and stricture of the right ureter. A Boari flap was planned given the location of the stricture just distal to the bifurcation of the iliac vessels. The partial ureterectomy and Boari flap were performed using a da Vinci Si surgical system to facilitate the reimplantation, which requires precise movements while handling delicate tissue and suturing with small-caliber material. This was achieved by resecting the affected 3-cm segment of ureter, then mobilizing and spatulating the remaining ureteral segments. The bladder was mobilized anteriorly and a wide-based Boari flap created. The flap was brought to the ureteral remnant off tension. The ureter was then anastomosed to the apex of the flap by using interrupted 4-0 braided absorbable sutures. A double-J stent was inserted, and the remainder of the bladder defect was closed using a 3-0 braided absorbable suture. Irrigation of the bladder confirmed a watertight closure. A JP drain was placed. The

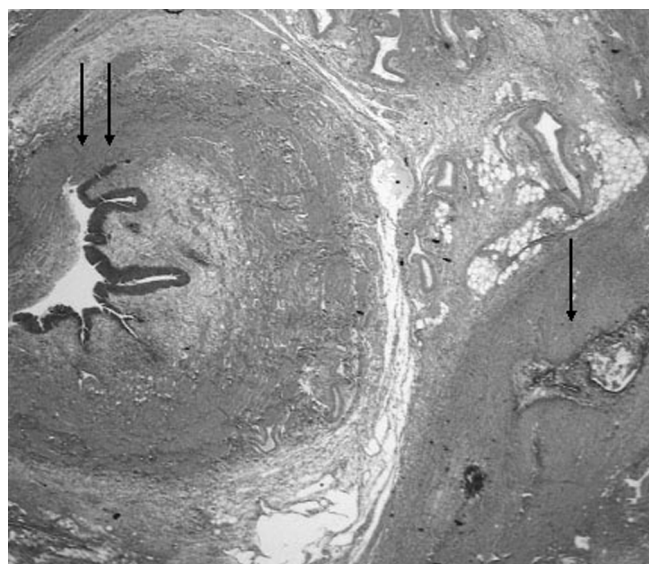
case was completed in 6 hours and 38 minutes. A JP creatinine on postoperative day 2 was 0.8mg/dL, suggesting integrity of the ureteroneocystostomy anastomosis site.

A cystogram was performed on postoperative day 11, demonstrating no extravasation at the anastomotic site. The JP drain and Foley catheter were removed. The stent was removed 1 month postoperatively. Two months postoperatively, a diuretic nucleotide scan demonstrated 50% contribution from each kidney and no obstruction. Pathology of both the excised ureteral segment and surrounding tissue revealed endometriosis (Figure 1). At 1 year, the patient was evaluated by her local physician and underwent a renal ultrasound that revealed no evidence of hydronephrosis. Her creatinine was within normal limits.

**CASE REPORT TWO**

Patient 2 is a 49-year-old perimenopausal woman with a history of 3 surgical procedures for excision of endometriosis. On initial presentation to our clinic in December 2007, a pelvic ultrasound obtained for a history of menometrorrhagia revealed moderate dilation of the left renal pelvis with a possible ureteropelvic junction obstruction. There was no atrophy of the renal parenchyma.

Upon urology follow-up, the patient reported mild flank pain and a history of 2 urinary tract infections in the



**Figure 1.** Endometriosis involving peri-ureteral soft tissue. Endometrial glandular epithelium with surrounding endometrial stromal cells (*single arrow*) adjacent to the ureter (*double arrow*).

previous 6 months. A CT urogram and MRI in January 2008 showed a distal ureteral obstruction at the site of an infiltrative soft tissue lesion. A diuretic radionuclide scan demonstrated that renal function was equivalent bilaterally. A repeat scan in May 2008 showed a persistent left-sided obstruction. This prompted evaluation with cystoscopy, ureteroscopy, and stenting. No intraluminal pathology was noted, though the patient had persistent moderate hydronephrosis proximal to the level of the iliac bifurcation. Leuprolide depot was administered and the stent removed. Nearly 1 year later, ultrasound images revealed persistent moderate left hydronephrosis. In August 2009, the patient underwent laparoscopic excision of endometriosis, ureterolysis, and partial ureterectomy with robotic-assisted laparoscopic left ureteroneocystostomy.

Intraoperatively, there was moderate ureteral dilation proximal to the pelvic brim, though no visible endometriosis was in the pelvis. Ureterolysis was performed laparoscopically, revealing dense fibrosis of the left pelvic sidewall from the level of the iliac bifurcation to the midpelvis. A stricture of the ureter was visualized just beyond the level of the midpelvis. Given the relatively distal level of the lesion, the decision was made to proceed with a ureteroneocystostomy. The da Vinci Si surgical system was used for the remainder of the procedure to facilitate visualization and suturing during the reimplantation.

The strictured segment of ureter was excised and the bladder mobilized. An incision was made in the bladder dome, and the ureter was anastomosed to the defect using interrupted sutures of 4-0 braided absorbable suture. A double-J stent was then placed during the anastomosis. The bladder was irrigated, and no extravasation was noted. The case was completed in 3 hours and 15 minutes. A JP drain placed intraoperatively was removed on postoperative day 1 after a JP creatinine level of 0.8mg/dL suggested integrity of the anastomosis site. Final pathology revealed endometriosis in the pelvic sidewall peritoneum overlying the ureter. The stent was removed 1 month postoperatively. Repeat diuretic radionuclide scans 3 and 10 months postoperatively revealed stable renal function and no evidence of obstruction. The patient was advised to return in 2 years for a repeat diuretic radionuclide scan and determination of creatinine level.

## DISCUSSION

To evaluate the extent of ureteral endometriosis, surgical management should begin with dissection of the perito-

neum off the ureter and ureterolysis. Resection of the surrounding endometriosis and fibrotic tissue may successfully relieve a ureteral obstruction in patients with superficial, extrinsic disease, though lesions invading the ureteral wall or inducing extensive fibrosis require resection of the involved ureteral segment. Lesions located at the level of the distal ureter should be resected and a ureteroneocystostomy performed. If the lesion is at the level of the midpelvis, a psoas hitch or Boari flap is generally recommended.<sup>11,12</sup> Segmental ureterectomy with ureteroureterostomy is acceptable in select cases, though some authors advocate ureteroneocystostomy in all cases of extensive pelvic endometriosis, given the high risk of disease development or recurrence in the distal aspect of the ureter.<sup>13</sup>

Excision of endometriosis and ureterolysis are rather straightforward laparoscopic procedures. However, ureteroureterostomy and ureteroneocystostomy require more advanced laparoscopic suturing skills with fine caliber suture and thus may not be feasible for surgeons with more limited laparoscopic experience. Robotic-assisted surgery offers 3-dimensional visualization, wristed instrumentation with 7 degrees of freedom, motion scaling, and tremor filtration, as well as ergonomic positioning. This is in contrast to laparoscopic equipment's 4 degrees of freedom and 2-dimensional scope that demands the surgeon stand for the entire procedure. These features may contribute to increased precision with robotic tasks compared to laparoscopy features, as was observed in one study<sup>14</sup> comparing speed and precision on multiple tasks using robotic assistance versus conventional laparoscopy. Multiple studies have also found that novices achieve suturing and knot tying competency faster with robotic assistance than with conventional laparoscopy.<sup>15,16</sup> Thus, learning this type of advanced laparoscopic procedure may be easier with robotic assistance than with conventional laparoscopy. However, multiple retrospective studies<sup>17-19</sup> have shown robotic assistance is more costly than a conventional laparoscopic approach.

## CONCLUSION

In the cases described here, robotic-assisted laparoscopy provided an alternative, potentially advantageous approach to ureteral resection and repair in these patients with endometriosis inducing ureteral obstruction. Both patients underwent successful minimally invasive robotic-assisted laparoscopic ureterectomy and ureteral reimplantation and were discharged from the hospital in under 48 hours. At 12-month follow-up, both were

asymptomatic and doing well. These cases suggest that robotic assistance is feasible and safe in women undergoing surgery for endometriosis involving the upper urinary tract. However, further investigation with larger comparative cohorts and longer follow-up that include cost analyses is needed to define the role of robotics for ureteral reconstruction.

## References:

1. Giudice LC, Kao LC. *Endometriosis Lancet*. 2004;364:1789-1799.
2. Chapron C, Dubuisson JB. Laparoscopic management of bladder endometriosis. *Acta Obstet Gynecol Scand*. 1999;78:887-890.
3. Chapron C, Fauconnier A, Vieira M, et al. Anatomical distribution of deeply infiltrating endometriosis: Surgical implications and proposition for a classification. *Hum Reprod*. 2003;18:157-161.
4. Nezhat C, Nezhat F, Nezhat CH, Nasserbakht F, Rosati M, Seidman DS. Urinary tract endometriosis treated by laparoscopy. *Fertil Steril*. 1996;66:920-924.
5. Stillwell TJ, Kramer SA, Lee RA. Endometriosis of ureter. *Urology*. 1986;28:81-85.
6. Jadoul P, Feyaerts A, Squifflet J, Donnez J. Combined laparoscopic and vaginal approach for nephrectomy, ureterectomy, and removal of a large rectovaginal endometriotic nodule causing loss of renal function. *J Minim Invasive Gynecol*. 2007;14:256-259.
7. Comiter CV. Endometriosis of the urinary tract. *Urol Clin North Am*. 2002;29:625-635.
8. Nezhat CH, Nezhat FR, Freiha F, Nezhat CR. Laparoscopic vesicopsoas hitch for infiltrative ureteral endometriosis. *Fertil Steril*. 1999;71:376-379.
9. Frenna V, Santos L, Ohana E, Bailey C, Wattiez A. Laparoscopic management of ureteral endometriosis: Our experience. *J Minim Invasive Gynecol*. 2007;14:169-171.
10. Bosev D, Nicoll LM, Bhagan L, et al. Laparoscopic management of ureteral endometriosis: The Stanford university hospital experience with 96 consecutive cases. *J Urol*. 2009;182:2748-2752.
11. Scioscia M, Molon A, Grosso G, Minelli L. Laparoscopic management of ureteral endometriosis. *Curr Opin Obstet Gynecol*. 2009;21:325-328.
12. Yohannes P. Ureteral endometriosis. *J Urol*. 2003;170:20-25.
13. Antonelli A, Simeone C, Frego E, Minini G, Bianchi U, Cunico SC. Surgical treatment of ureteral obstruction from endometriosis: Our experience with thirteen cases. *Int Urogynecol J Pelvic Floor Dysfunct*. 2004;15:407-412.
14. Dakin GF, Gagner M. Comparison of laparoscopic skills performance between standard instruments and two surgical robotic systems. *Surg Endosc*. 2003;17:574-579.
15. Yohannes P, Rotariu P, Pinto P, Smith AD, Lee BR. Comparison of robotic versus laparoscopic skills: Is there a difference in the learning curve? *Urology*. 2002;60:39-45.
16. Chandra V, Nehra D, Parent R, et al. A comparison of laparoscopic and robotic assisted suturing performance by experts and novices. *Surgery*. 2010;147:830-839.
17. Holtz DO, Miroshnichenko G, Finnegan MO, Chernick M, Dunton CJ. Endometrial cancer surgery costs: robot vs laparoscopy. *J Minim Invasive Gynecol*. 2010;17(4):500-503. Epub 2010 May 23.
18. Sarlos DKots L, Stevanovic N, Schaer G. Robotic hysterectomy versus conventional laparoscopic hysterectomy: outcome and cost analyses of a matched case-control study. *Eur J Obstet Gynecol Reprod Biol*. 2010;150(1):92-96. Epub 2010 Mar 5.
19. Patel M, O'Sullivan D, Tulikangas PK. A comparison of costs for abdominal, laparoscopic and robot-assisted sacral colpopexy. *Int Urogynecol J Pelvic Floor Dysfunct*. 2009;20(2):223-228. Epub 2008 Oct 16.