

Incidence of recurrent fungal keratitis after primary keratoplasty and visual outcome and prognosis after intervention for the recurrence

Yuerong Gong, MS^{a,b,*}, Meng Xin, MD^c

Abstract

There are no standardized protocols or guidelines for the treatment of recurrent fungal keratitis after therapeutic keratoplasty. This study aimed to investigate the incidence of recurrent fungal keratitis after the primary keratoplasty and the visual outcome and prognosis after intervention for the recurrence.

This was a retrospective study. Patients with recurrent fungal keratitis after lamellar keratoplasty (LK) or penetrating keratoplasty (PK) were treated with different antifungal regimens at Shandong Eye Hospital and Qingdao Eye Hospital between January 2004 and December 2015. The operative techniques included PK, focal excision, tectonic keratoplasty with a patch graft, lensectomy and vitrectomy, and combined operation. Patients were followed at 1, 2, and 3 months, and then every 6 months after surgery for 2 years. Best corrected visual acuity was assessed and recurrence was recorded. Good prognosis was defined as the presence of visual acuity.

Fungal keratitis recurred in 112 of 1448 patients (112/1448, 7.7%) treated initially with PK or LK. The good prognosis rates for different sites of recurrent fungal keratitis were: overall, 93 of 112 (83.0%); recipient bed, 64 of 69 (92.8%); anterior chamber, 14 of 14 (100%); posterior segment, 10 of 16 (62.5%); and atypical, 5 of 13 (38.5%). There was no significant difference in the timing of recurrence between the good and poor prognosis groups ($P = .518$). Recurrence rates were similar between patients with PK (8.6%) and those with LK (6.0%; $P > .05$), but the good prognosis rate in patients with post-LK recurrence (96.8%) was higher than that in patients with post-PK recurrence (77.8%, $P = .017$).

Individualized treatment according to recurrent sites of fungal keratitis can achieve a good prognosis in most patients.

Abbreviations: BCVA = best corrected visual acuity, LK = lamellar keratoplasty, PK = penetrating keratoplasty, SD = standard deviation.

Keywords: lamellar keratoplasty, penetrating keratoplasty, Recurrent Fungal Keratitis

1. Introduction

In China, fungal keratitis is the most common cause of blindness among patients with infectious corneal diseases.^[1–3] A variety of pharmacological agents are available for the treatment of fungal keratitis, which include polyenes (eg, amphotericin B)

and azoles (eg, ketoconazole and voriconazole),^[4–8] but not all cases of fungal keratitis respond to pharmacotherapy. Therefore, therapeutic keratoplasty retains an important role in the management of progressive fungal keratitis refractory to medical treatment.^[9–14] Nevertheless, keratitis can still recur in 10% to 15% of patients treated with therapeutic keratoplasty.^[9,10,15–17] A variety of therapeutic approaches have been used to manage the recurrence of fungal keratitis after therapeutic keratoplasty, which include antifungal medications (fluconazole or voriconazole) administered as eye drops or through intravenous, subconjunctival, or intracameral injections, repeat keratoplasty, and evisceration.^[9,10,15–18] Currently, there are no standardized protocols or guidelines for the treatment of recurrent corneal fungal infection after therapeutic keratoplasty. Failure to recognize recurrent fungal keratitis in its early stages or to take an effective treatment measure in a timely manner can result in suboptimal therapy and even eye loss. The selection of an appropriate intervention is further complicated by the possibility that different sites of recurrent keratitis may need different treatment approaches. Therefore, research is needed to identify reasonable and effective treatment strategies for the recurrence of fungal keratitis after therapeutic keratoplasty, as well as the factors associated with recurrence and prognosis after treatments.

Therefore, the aim of the present study was to investigate the incidence of recurrent fungal keratitis after the primary keratoplasty and the visual outcome and prognosis after intervention for the recurrence. This study retrospectively evaluated the effects of

Editor: Khaled Ahmed Abdelrahman.

Funding: This study was supported by the National Natural Science Foundation of China (no. 81530027, 81500702), the National Basic Research Program of China (no. 2013CB967004) and the Top Scholarship Program of Taishan (no. tspd20150215).

The authors report no conflicts of interest.

^a Shandong University, Jinan, ^b Department of Ophthalmology, Binzhou Medical University Hospital, Binzhou, ^c Yantai Affiliated Hospital of Binzhou Medical University, Yantai, Shandong, China.

* Correspondence: Yuerong Gong, Shandong University, No. 44 Wenhua Xi Road, Jinan 250012, Shandong, China, Department of Ophthalmology, Binzhou Medical University Hospital, Binzhou 256603, Shandong, China. (e-mail: gongyuerong2003@163.com)

Copyright © 2019 the Author(s). Published by Wolters Kluwer Health, Inc. This is an open access article distributed under the terms of the Creative Commons Attribution-Non Commercial-No Derivatives License 4.0 (CCBY-NC-ND), where it is permissible to download and share the work provided it is properly cited. The work cannot be changed in any way or used commercially without permission from the journal.

Medicine (2019) 98:24(e15910)

Received: 18 January 2019 / Received in final form: 25 April 2019 / Accepted: 10 May 2019

<http://dx.doi.org/10.1097/MD.00000000000015910>

individualized treatment regimens on the recurrence of fungal keratitis after therapeutic keratoplasty in patients at the Shandong Eye Hospital and Qingdao Eye Hospital (China).

2. Materials and methods

2.1. Patients

This was a retrospective study. Patients with recurrent fungal keratitis after initial lamellar keratoplasty (LK) or penetrating keratoplasty (PK) for fungal keratitis were treated at Shandong Eye Hospital and Qingdao Eye Hospital between January 2004 and December 2015, and included in this study. This study was approved by the Ethics Committee of the Shandong Eye Hospital and Qingdao Eye Hospital.

Recurrent fungal keratitis was diagnosed by clinical examination (eg, gray-white invasive lesion of the recipient bed, mushroom-shaped pus mass at the anterior chamber angle, pus mass at the pupillary zone, and/or hypopyon reappearance) or confocal microscopy that was used to confirm the presence of fungal hyphae deep in the cornea, as previously described.^[16] Etiologic diagnosis was based on fungal hyphae-positive smears or fungal culture from specimens obtained during secondary surgery.

The inclusion criteria were: initial keratoplasty for fungal keratitis; recurrent fungal keratitis confirmed by clinical examination, and/or confocal microscopy, and/or smears/cultures of corneal tissue, aqueous humor or vitreous body samples; 1 eye involvement. Those with the coexistence of other complications of keratoplasty were excluded.

2.2. Indications for the initial keratoplasty

The indication for LK was that the infection did not involve the descemet membrane. The indications for PK were that the infection invaded the entire cornea; the descemet membrane and endothelium layer; or there was corneal perforation.

2.3. Postoperative medical therapy after initial therapeutic keratoplasty

Postoperative management of patients after initial therapeutic keratoplasty (for the first presentation of fungal keratitis) was performed as previously described.^[16] Oral fluconazole was administered 1 day before keratoplasty and lasted for 21 days. Postoperatively, 0.5% fluconazole, 0.25% amphotericin B, or 5% natamycin were administered topically 4 times daily for 2 weeks, and subsequently tapered. Antibiotic drops and nonsteroidal anti-inflammatory drops were also administered 4 times daily. If there were no signs of recurrence 2 weeks after surgery, 0.02% fluorometholone was topically administered twice daily for 1 week, and then changed to 4 times daily.

2.4. Classification of recurrent fungal keratitis

Recurrent fungal keratitis after therapeutic keratoplasty was classified based on the clinical features: recipient bed recurrence, anterior chamber recurrence, posterior segment recurrence, and atypical recurrence (Table 1). Recurrence of fungal keratitis was also classified as early recurrence (occurring within 8 days after

Table 1
Manifestations and individualized treatment of different types of recurrent fungal keratitis.

Types	Manifestations under slit lamp	Association between manifestations and the recurrence site	Strategies for individualized treatment
RBC	Gray-white invasive lesion of the recipient bed, including the donor/host junction. Some patients may have purulent exudate at the donor/host junction, or additional hypopyon.	The gray-white invasive lesion of the recipient bed is the initial recurrence site.	A. PK with the same diameter of LK for deep RBC under the lamellar graft after initial LK. B. Corneal lesion resection + bulbar conjunctiva flap covering for superficial peripheral RBC after initial LK. C. PK with expanded diameter of LK for deep peripheral RBC after initial LK. D. Expanded diameter of PK for RBC involving the corneal graft after initial PK. E. Corneal lesion resection for RBC ≤ 2 mm and not involving the corneal graft after initial PK; expanded diameter of PK for uncontrolled recurrence after resection. F. Expanded diameter of PK for RBC > 2 mm and not involving the sclera after initial PK. G. PK with patch graft for RBC > 2 mm involving slightly the sclera after initial PK. H. Enucleation or evisceration for widespread infection of the sclera after initial PK.
ACR	Mushroom-shaped pus mass at the anterior chamber angle or the surface of the iris	The covered mushroom-shaped pus mass is the initial recurrence site	Removal of mushroom-shaped pus mass; anterior chamber injection of 0.1 mg fluconazole or voriconazole once daily; if these measures fail to control infection, then anterior chamber lavage and complete removal of recurrent lesions are conducted.
PSR	Pus mass at the pupillary zone.	The pus mass at the pupillary zone suggests that the initial recurrence site is at the posterior segment. The pus from the posterior segment crosses the pupil into the anterior chamber and forms a pus mass at the pupillary zone.	Removal of the pus mass at the pupillary zone; antifungal drugs for the anterior chamber lavage; extracapsular lens extraction for lens infection; intravitreal injection of 0.1 mg fluconazole or voriconazole, or 10 μ g amphotericin B, or vitrectomy for vitreous body infection; enucleation or evisceration for panophthalmitis.
AR	Hypopyon without invasive lesion of the recipient bed, mushroom-shaped pus mass, or pus mass at the pupillary zone.	Hypopyon is not the site of the initial recurrence. The initial recurrence site can only be determined after hypopyon lavage and exploration.	Anterior chamber lavage and exploration; resection of the recurrent site; corresponding treatments as described above for different sites and involved areas; enucleation or evisceration for widespread sclera and intraocular infection.

RBC=recipient bed recurrence, ACR=anterior chamber recurrence, PSR=posterior segment recurrence, AR=atypical recurrence, LK=lamellar keratoplasty, PK=penetrating keratoplasty.

therapeutic keratoplasty) or late recurrence (occurring from 2 weeks after therapeutic keratoplasty).

2.5. Individualized treatment for recurrent fungal keratitis

The general treatment for recurrent fungal infection was aggressive medical therapy. All patients received antifungal drugs both topically (0.5% fluconazole or voriconazole drops every 15 minutes combined with 0.25% amphotericin B or 5% natamycin drops once every hour) and subconjunctivally (injections of 3-mg fluconazole or voriconazole once or twice daily). For some patients with recipient bed recurrence, intrastromal injections of antifungal drugs (1-mg fluconazole or voriconazole once or twice daily) were initially conducted. Individualized treatment was conducted if the general treatment was ineffective after 3 to 5 days of treatment. The details of the individualized treatment for the different types of recurrence are shown in Table 1.

2.6. Follow-up

All patients were followed at 1, 2, and 3 months after discharge, and then every 6 months for 2 years. Best corrected visual acuity (BCVA) was assessed using comprehensive refractometry and vision chart. Recurrence was also recorded.

2.7. Treatment evaluation

For the analysis of treatment effect, good prognosis was defined as the presence of visual acuity. Poor prognosis was defined as failure in infection control with evisceration or enucleation of the eyeball or termination of treatment owing to ineffectiveness.

2.8. Statistical analysis

Statistical comparisons were conducted using SPSS 17.0 (IBM, Armonk, NY). Continuous variables are expressed as means \pm standard deviations (SD) and were compared between groups using the Student *t* test. Categorical variables are presented as frequency and percentage and were compared between groups

using the χ^2 test or Fisher exact test. Two-sided *P* values $<.05$ were considered statistically significant.

3. Results

3.1. General characteristics of the patients included in the analysis

During the study period, 1448 patients with fungal keratitis that could not be controlled medically underwent PK (937/1448, 64.7%) or LK (511/1448, 35.3%). As shown in Table 2, 1325 (91.5%) of the 1448 patients were positive for fungal culture.

Recurrent fungal keratitis occurred in 112 (7.7%) of the 1448 patients treated with therapeutic keratoplasty. Among the 112 patients with recurrence, 99 received etiologic diagnosis (by identifying fungal hyphae in the smears or fungal growth in culture; Table 2), 10 were diagnosed by confocal microscopy (the presence of fungal hyphae deep in the cornea), and 3 were diagnosed by clinical manifestations. These 112 patients (including 81 post-PK and 31 post-LK) were included in the final analysis. Patient age ranged from 12 to 80 years (mean of 49.1 years). There were 64 men and 48 women. Seven (6.3%) of the 112 patients had treatment terminated because of ineffectiveness and 12 (10.7%) of the 112 patients underwent evisceration or enucleation of the eyeball because of uncontrollable infection. The overall good prognosis rate for the treatment of recurrent fungal keratitis was 83.0% (93/112). As shown in Table 2, there was no significant difference in the microbiological results between the fungal keratitis group ($n=1448$) and the recurrence group ($n=112$). There was also no significant difference in the microbiological results between the good prognosis group ($n=93$) and the poor prognosis group ($n=19$).

3.2. Prognosis of the different clinical types of fungal keratitis

The good prognosis rates of the different sites of recurrent fungal keratitis were: recipient bed recurrence, 64 of 69 (92.8%); anterior chamber recurrence, 14 of 14 (100%); posterior segment recurrence, 10 of 16 (62.5%); and atypical recurrence, 5 of 13 (38.5%) (Table 3). There was no significant difference in the timing of recurrence between the good and poor prognosis groups ($P=.518$).

Table 2

Microbiological results.

Fungus, n (%) ^{*†}	Fungal keratitis (n=1448)	Recurrence (n=112)	Good prognosis (n=93)	Poor prognosis (n=19)
<i>Fusarium</i>	905 (62.5)	68 (60.7)	55 (59.1)	13 (68.4)
<i>Aspergillus</i>	183 (12.6)	19 (17.0)	16 (17.2)	3 (15.8)
<i>Alternaria</i>	61 (4.2)	4 (3.6)	4 (4.3)	0
<i>Candida</i>	25 (1.7)	1 (0.9)	1 (1.1)	0
<i>Penicillium</i>	28 (1.9)	2 (1.8)	2 (2.2)	0
<i>Acremonium</i>	22 (1.5)	2 (1.8)	2 (2.2)	0
<i>Dematiaceous hyphomycetes</i>	23 (1.6)	2 (1.8)	1 (1.1)	1 (5.3)
<i>Mycelia sterilia</i>	20 (1.4)	4 (3.6)	3 (3.2)	1 (5.3)
Other fungi	19 (1.3)	2 (1.8)	2 (2.2)	0
Unidentifiable fungi	39 (2.7)	3 (2.7)	3 (3.2)	0
Smears (+), culture (-)	123 (8.5)	5 (4.5)	4 (4.3)	1 (5.3)

* $P>.05$ for all fungi, fungal keratitis group vs recurrence group.

† $P>.05$ for all fungi, good prognosis group vs poor prognosis group.

Table 3
General characteristics.

Variable	Total (n = 112)	Good prognosis (n = 93)	Poor prognosis (n = 19)	P
Age, y	49.1 ± 12.2	48.4 ± 12.2	52.2 ± 12.4	.227
Male	64 (57.1)	52 (55.9)	12 (63.2)	.561
Immunosuppressor	0	0	0	—
High myopia	1 (0.9)	1 (1.1)	0	—
History of glaucoma surgery	2 (1.8)	2 (2.2)	0	—
History of LASIK	1 (0.9)	1 (1.1)	0	—
History of keratitis	2 (1.8)	1 (1.1)	1 (5.3)	.312
Hypertension	5 (4.5)	4 (4.3)	1 (5.3)	1.000
Diabetes	12 (10.7)	10 (10.8)	2 (10.5)	1.000
Type of keratoplasty				.017
LK	31 (27.7)	30 (32.3)	1 (5.3)	
PK	81 (72.3)	63 (67.7)	18 (94.7)	
Recurrence after keratoplasty				.518
Early (≤8 days)	92 (82.1)	75 (80.6)	17 (89.5)	
Late (≥14 days)	20 (17.9)	18 (19.4)	2 (10.5)	
Left eye infection	60 (53.6)	48 (51.6)	12 (63.2)	.358
Infection site				<.001
Recipient bed	69 (61.6)	64 (68.8)	5 (26.3)	
Anterior chamber	14 (12.5)	14 (15.1)	0	
Posterior segment	16 (14.3)	10 (10.8)	6 (31.6)	
Atypical	13 (11.6)	5 (5.3)	8 (42.1)	
Treatment				—
Drug treatment (nonintraocular)	13 (11.6)	13 (14.0)	0	
Drug treatment (intraocular)	17 (15.2)	17 (18.2)	0	
Lesion resection	18 (16.0)	18 (19.4)	0	
Replacing cornea graft in PK (fresh cornea)	29 (25.9)	29 (31.2)	0	
Replacing cornea graft in PK (conserved in glycerine)	3 (2.7)	3 (3.2)	0	
Using patch graft in PK (conserved in glycerine)	5 (4.5)	5 (5.3)	0	
Lensectomy and vitrectomy	4 (3.6)	4 (4.3)	0	
Lesion resection, lensectomy and vitrectomy	2 (1.8)	2 (2.2)	0	
Fresh cornea PK, lensectomy and vitrectomy	2 (1.8)	2 (2.2)	0	
Abandoned treatments	7 (6.2)	0	7 (36.8)	
Evisceration or enucleation of the eyeball	12 (10.7)	0	12 (63.2)	

Data were expressed as means ± standard deviations or n (%). LASIK=laser-assisted in situ keratomileusis, LK=lamellar keratoplasty, PK=penetrating keratoplasty.

3.3. Comparison of prognosis between patients with recurrent fungal keratitis after LK and PK

The recurrence rates did not differ significantly between initial PK (81/937, 8.6%) and LK groups (31/511, 6.1%; $P = .079$), but the good prognosis rate of post-LK recurrent patients (30/31, 96.8%) was significantly higher than that of post-PK recurrent patients (63/81, 77.8%; $P = .017$).

The only recurrent site of fungal keratitis after LK was the recipient bed. Post-LK recurrent fungal keratitis occurred in the deep central bed in 25 of 31 patients (80.6%). All patients with deep lamellar recurrence had different degrees of anterior chamber response and 68.0% of patients (17/25) had a hypopyon or severe fibrinous effusion. Of the 31 patients with post-LK recurrent fungal keratitis, 8 (25.8%) had a good prognosis with antifungal drug therapy (including intrastromal injections and intracameral injections), 21 (67.7%) were cured by PK, and 1 (3.2%) finally required enucleation of the eyeball because of precipitously deteriorating condition.

Post-PK recurrent fungal infection occurred at various sites: recipient bed (69/81, 85.2%), anterior chamber (14/81, 17.3%), posterior segment (16/81, 19.8%), and atypical recurrence (13/81, 16.0%). After aggressive individualized treatment, 63 patients (63/81, 77.8%) had good prognosis; 7 patients (8.6%) had treatments terminated, and 11 patients (13.5%) finally required enucleation

or evisceration of the eyeball. Representative cases of patients with recurrent fungal keratitis are shown in Figures 1 and 2.

3.4. BVCA after recurrent fungal infection and individualized treatment

In the good prognosis group, BVCA was well maintained during the 2 years of follow-up (Table 4).

4. Discussion

This study aimed to investigate the incidence of recurrent fungal infection after the primary surgery and the visual outcome and prognosis after intervention for the recurrence. Our findings suggest that recurrent fungal keratitis might require an individualized therapy tailored to the site of recurrent fungal keratitis, which can achieve good prognosis in the majority of patients.

In this study, the overall rate of recurrent fungal keratitis after initial therapeutic keratoplasty was 7.7% (112/1448), which is in agreement with previous reports.^[9,10,15–18] Because of the various manifestations of recurrent fungal keratitis and the lack of systematic treatment protocols or guidelines, it remains a challenge for ophthalmologists to appropriately manage this condition. This study included 112 cases of recurrent fungal

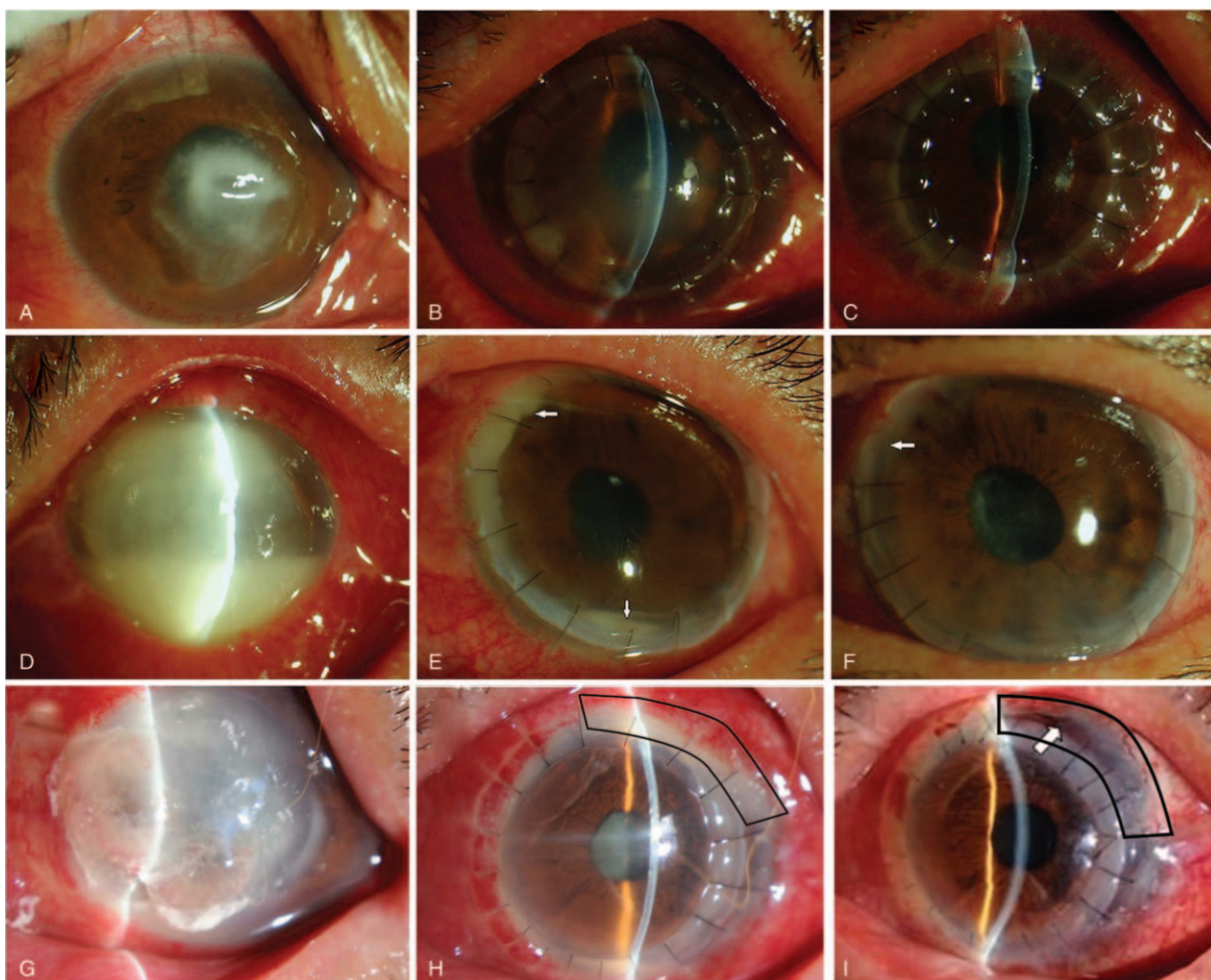


Figure 1. Three representative cases of recipient bed recurrence. (A–C) Case 1. Male, 68 years' old. (A) Central corneal infiltration; a little pus can be seen in the anterior chamber. (B) After lamellar keratoplasty (LK), the fungi recurred in the central recipient bed, showing as gray-white infiltration. (C) Medical therapy was not effective after recurrence. The graft was transparent after penetrating keratoplasty (PK). (D–F) Case 2. Female, 51 years' old. (D) She had extensive corneal infection and a large amount of pus in the anterior chamber. (E) The infection recurred in the recipient bed after PK, showing gray-white infiltration. Purulent adhesion was observed at the interface of the recipient bed and graft. A little pus was observed in the anterior chamber (white arrow). (F) After recipient bed lesion resection at the recurrence site, the infection was controlled, the graft was transparent (white arrow), and the aqueous humor in the anterior chamber was clear. (G–I) Case 3. Male, 61 years' old. (G) A large range of cornea was involved, and the corneoscleral limbus was affected at the nasal side. Local perforation was observed. (H) Local recipient bed recurrence after PK. Purulent adhesion was observed at the interface of recipient bed and graft (black frame), the aqueous humor was turbid, and pus was observed in the lower anterior chamber. (I) Medical therapy was not effective after recurrence. The central graft and patch (black frame) were transparent and the aqueous humor in the anterior chamber was clear after lesion resection and patch PK treatment.

infection and the treatments were tailored to the various sites of recurrence. Notably, the use of individualized treatments resulted in an overall good prognosis rate of 83.0%.

Among the 112 patients with recurrent fungal keratitis, 30 (26.8%) were successfully managed using topical, subconjunctival, intrastromal, intracameral, and/or vitreous administration of antifungal drugs, mainly voriconazole. Treatment of a small series of 25 patients with deep refractory fungal keratitis showed that intrastromal voriconazole could treat the infection in 76% of the patients.^[7] However, a study of 940 patients in India showed that voriconazole was not superior to natamycin.^[19] In the present study, the success rate of medical treatment was 26.8% in patients with recurrent fungal keratitis, which could be considered as low. It is possible that the fungus was resistant or was not sensitive to the drugs selected. Nevertheless, it would not be unreasonable to treat all patients initially with medical therapy and closely observe for any signs of improvement or

deterioration. Nonetheless, the majority of cases of recurrence ultimately required re-operation to control the fungal infection. Therefore, if no obvious improvement is achieved after 3 to 5 days of medical therapy, operation is then the choice of treatment.

In this study, all cases of recipient bed recurrence without graft infection were successfully treated, likely because of the early identification of the infection site and timely treatment. Based on the principle that minimal interventional damage be exerted, the first choice of operation, if any, for these cases was focal excision and re-seaming of the graft-host junction. Although several patients complained of temporary astigmatism, the original regular graft could be preserved and the operative damage was small, enabling patients to recover quickly with few complications.

However, treatment is more challenging when infiltration of the corneosclera or sclera occurs.^[20] In our hospital, a new

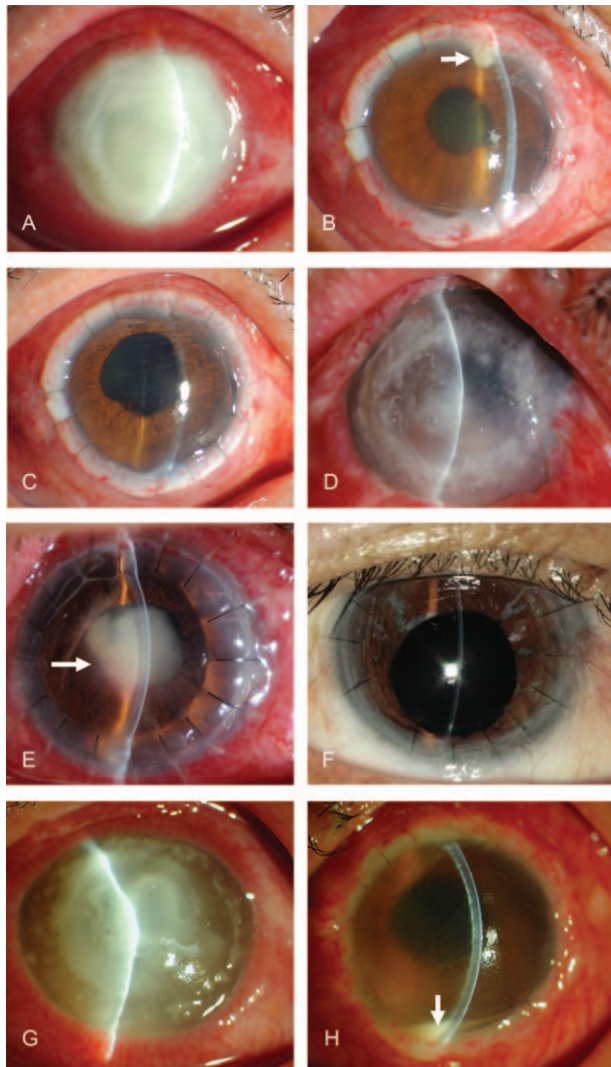


Figure 2. Three representative cases of anterior chamber, posterior segment, and atypical recurrence. (A–C) Case 1. Male, 50 years' old. (A) Full corneal fungal infection affecting the corneal limbus, with peripheral cornea autolysis and thinning. (B) After total corneal transplantation, mushroom-shaped purulent exudation was seen in the upper corner of the chamber (white arrow) and the aqueous humor was turbid. (C) After removal of the mushroom-shaped purulent exudation and anterior chamber injection of antifungal drugs, the corneal grafts were transparent and the aqueous humor in the anterior chamber was clear. (D–F) Case 2. Male, 56 years' old. (D) The preoperative corneal fungal infection involved total cornea and full corneal layers. The conditions of the anterior chamber could not be seen. (E) Fungal recurrence in the posterior segment after penetrating keratoplasty (PK). A mass-like purulent exudation was observed in the pupil area (white arrow). (F) Reexamination at 1 year after lensectomy + vitrectomy showed that the corneal graft was transparent, and aqueous humor was clear. (G–H) Case 3. Male, 33 years' old. (G) The cornea was widely infected, locally thinned, and there were a large number of satellite foci. The conditions of the anterior chamber could not be seen. (H) Atypical recurrence was observed after PK. The Hypopyon was observed in the anterior chamber (white arrow). The aqueous humor was obviously turbid. The corneal graft was transparent, and the exact recurrence lesions were not seen in the recipient bed and the graft. After recurrence, medical therapy was not effective. An exploratory operation was performed. During surgery, it was found that the upper and nasal sclera were eroded. Massive empyema was observed in the ciliary body; the vitreous body also showed empyema. There was intraocular infection, and the eyeballs could not be kept and were removed.

Table 4

BCVA in the good prognosis group.

Time point, n (%)	BCVA <0.1	0.1 ≤ BCVA <0.4	BCVA ≥0.4
1 mo (n=93)	18 (19.4)	45 (48.3)	30 (32.3)
3 mo (n=93)	17 (18.2)	47 (50.6)	29 (31.2)
6 mo (n=91)	15 (16.5)	49 (53.8)	27 (29.7)
12 mo (n=79)	3 (3.8)	54 (68.4)	22 (27.8)
18 mo (n=43)	1 (2.3)	30 (69.8)	12 (27.9)
24 mo (n=25)	1 (4.0)	20 (80.0)	4 (16.0)

BCVA = best corrected visual acuity.

method has been used to treat corneoscleral or scleral recurrent fungal infection. A tectonic keratoplasty with a patch graft from preserved corneoscleral ring in glycerin is attempted to connect the graft-host junction of the preexisting PK. This method offers a less invasive alternative to repeat PK and allows retention of the parent PK. Moreover, this approach avoids the use of large, oversized transplants that can result in serious complications such as peripheral anterior synechia and secondary glaucoma.^[9,21] All patients treated with this technique in the present study achieved good tectonic stability. Although some may question the adequacy of the endothelial function in these cases, those 5 patients who received tectonic keratoplasty with a patch graft in this study were found to have no endothelial function decompensation during follow-up (1–2 years). Therefore, this method appears to be a good choice for patients with recurrent fungal infection that exceeds the corneosclera. Nevertheless, the number of cases was small and studies with larger numbers of patients are necessary to verify the efficacy of this technique.

In cases of recipient bed recurrence that extended to the graft, resection of the lesions was often inefficient even if the recurrent lesions were small. In these patients, therapeutic PK with a large corneal graft was often necessary to control the recurrence. In this study, 7 of 8 of the cases with graft infection underwent lesion resection, and 5 of these failed. These 5 patients were ultimately successfully treated by therapeutic PK with a large corneal graft, indicating that this may be the therapy of choice when recipient bed recurrent fungal infection extends to the graft.

Anterior chamber recurrence is likely because of residual fungal foci in deep tissues at the juncture between the recipient bed and the graft. A small amount of mycelia propagates locally, forming a mushroom-shaped pus mass. Thus, a good therapeutic effect could be obtained if the recurrence was detected at an early phase and treated promptly with an effective method such as intracameral injection or lavage of antifungal drugs. In this study, about 80% cases of anterior chamber recurrences were resolved with intracameral injection or lavage with antifungal drugs after the removal of the mushroom-shaped pus mass. Fungal hyphae were detected by smear examination of the removed pus mass. The remaining anterior chamber recurrent cases were cured by anterior chamber lavage with antifungal drugs combined with recipient bed lesion excision. Intracameral injection or lavage with antifungal drugs after removing the mushroom-shaped pus mass may therefore be sufficient for most cases of anterior chamber recurrence.

When posterior segment recurrence has occurred and there is a purulent exudate covering the lens surface in the pupillary zone, the infection has already extended to the lens or anterior vitreous and sometimes even to the posterior vitreous. In these cases, treatments such as simple anterior chamber irrigation and

injection of antifungal drugs were not effective in most cases, and lens excision combined with vitrectomy were often needed to control the recurrence. Failure to initiate effective operative treatment in a timely manner will allow the infection to progress rapidly, potentially resulting in endophthalmitis and thus an inability to save the eye. In this study, 3 patients with posterior segment recurrence had a good prognosis with multiple anterior chamber irrigations and vitreous injections of antifungal drugs; 4 cases were successfully treated with lens excision and vitrectomy surgery; 4 lost their eye; and 1 refused further treatment.

Treatment of atypical recurrent fungal keratitis was the most challenging. Given the large range of preoperative infections, the sclera was often involved, and detecting surrounding recipient bed recurrence after surgery was difficult. This type of recurrence lacks targeted therapy and exhibits a poor prognosis. In this study, 5 patients underwent exploratory operations for recurrence in the recipient bed and were successfully treated. Five patients were found with widespread infections of the sclera during operation for atypical recurrent fungal keratitis and lost their eye. Therefore, we speculate that the starting point of this type of recurrence was the recipient bed. The remaining 3 patients discontinued treatment.

All cases of post-LK recurrent fungal infection occurred in the recipient bed, and most (80.6%) occurred in the deep recipient bed. All patients with deep lamellar recurrence had different degrees of anterior chamber response combined with a hypopyon or severe fibrinous effusion (17/25, 68%). PK was the optimal treatment choice, as focal excision combined with a conjunctival flap are not suitable for these cases.^[16] In this study, 67.7% (21/31) of patients with post-LK recurrence received PK that successfully treated the condition. The reasons for the good prognosis of the patients initially treated with LK could be that the infection did not break through the descemet membrane before the intervention (which was the indication for LK) started and there was no fungus in the intraocular area.

Maintaining a good vision after the infection event is important for the long-term quality of life of the patients. In the present study, among those who had good prognosis after the treatment of recurrent fungal keratitis, adequate BCVA was maintained in most patients, which is also shown by other studies.^[22-24] Additional studies are necessary to determine which approach could achieve the best BCVA after treatments.

This study has some limitations. First, this was a retrospective study; hence, it cannot be excluded that selection bias or reporting bias influenced the results. Second, the number of patients with recurrent fungal keratitis was relatively small, limiting the statistical analyses and the conclusions. Third, this was a single-center study, so the results may not be generalizable to the general patient population. Nonetheless, the results provide useful information for the treatment of patients with recurrent fungal keratitis after therapeutic keratoplasty.

In conclusion, different keratoplasty approaches and different infection sites are associated with different prognoses. Recurrent fungal keratitis might require an individualized therapy tailored to the site of recurrent fungal keratitis, such that good prognosis can be achieved in the majority of patients with adequate BCVA. Further research is needed to confirm and expand the findings of the present study, with the aim of developing a standardized protocol for the management of recurrent fungal keratitis after therapeutic keratoplasty.

Author contributions

Investigation: Yuerong Gong, Meng Xin.

Methodology: Yuerong Gong, Meng Xin.

Writing – original draft: Yuerong Gong.

References

- Whitcher JP, Srinivasan M, Upadhyay MP. Corneal blindness: a global perspective. *Bull World Health Organ* 2001;79:214–21.
- Song X, Xie L, Tan X, et al. A multi-center, cross-sectional study on the burden of infectious keratitis in China. *PLoS One* 2014;9:e113843.
- Cao J, Yang Y, Yang W, et al. Prevalence of infectious keratitis in Central China. *BMC Ophthalmol* 2014;14:43.
- Sauer A, Letscher-Bru V, Speeg-Schatz C, et al. In vitro efficacy of antifungal treatment using riboflavin/UV-A (365 nm) combination and amphotericin B. *Invest Ophthalmol Vis Sci* 2010;51:3950–3.
- Carrasco MA, Genesoni G. Treatment of severe fungal keratitis with subconjunctival amphotericin B. *Cornea* 2011;30:608–11.
- You X, Li J, Li S, et al. Effects of lamellar keratectomy and intrastromal injection of 0.2% fluconazole on fungal keratitis. *J Ophthalmol* 2015;2015:656027.
- Kalaiselvi G, Narayana S, Krishnan T, et al. Intrastromal voriconazole for deep recalcitrant fungal keratitis: a case series. *Br J Ophthalmol* 2015;99:195–8.
- Lekhanont K, Nonpassopon M, Nimvorapun N, et al. Treatment with intrastromal and intracameral voriconazole in 2 eyes with Lasiodiplodia theobromae keratitis: case reports. *Medicine (Baltimore)* 2015;94:e541.
- Ti SE, Scott JA, Janardhanan P, et al. Therapeutic keratoplasty for advanced suppurative keratitis. *Am J Ophthalmol* 2007;143:755–62.
- Anshu A, Parthasarathy A, Mehta JS, et al. Outcomes of therapeutic deep lamellar keratoplasty and penetrating keratoplasty for advanced infectious keratitis: a comparative study. *Ophthalmology* 2009;116:615–23.
- Sharma N, Jain M, Sehra SV, et al. Outcomes of therapeutic penetrating keratoplasty from a tertiary eye care centre in northern India. *Cornea* 2014;33:114–8.
- Sharma N, Sachdev R, Jhanji V, et al. Therapeutic keratoplasty for microbial keratitis. *Curr Opin Ophthalmol* 2010;21:293–300.
- Barut Selver O, Egrilmez S, Palamar M, et al. Therapeutic corneal transplant for fungal keratitis refractory to medical therapy. *Exp Clin Transplant* 2015;13:355–9.
- Liu Y, Jia H, Shi X, et al. Minimal trephination penetrating keratoplasty for severe fungal keratitis complicated with hypopyon. *Can J Ophthalmol* 2013;48:529–34.
- Rogers GM, Goins KM, Sutphin JE, et al. Outcomes of treatment of fungal keratitis at the University of Iowa Hospitals and Clinics: a 10-year retrospective analysis. *Cornea* 2013;32:1131–6.
- Shi W, Wang T, Xie L, et al. Risk factors, clinical features, and outcomes of recurrent fungal keratitis after corneal transplantation. *Ophthalmology* 2010;117:890–6.
- Deng SX, Kamal KM, Hollander DA. The use of voriconazole in the management of post-penetrating keratoplasty Paecilomyces keratitis. *J Ocul Pharmacol Ther* 2009;25:175–7.
- Bajracharya L, Gurung R. Outcome of therapeutic penetrating keratoplasty in a tertiary eye care center in Nepal. *Clin Ophthalmol* 2015;9:2299–304.
- Prajna NV, Krishnan T, Mascarenhas J, et al. The mycotic ulcer treatment trial: a randomized trial comparing natamycin vs voriconazole. *JAMA Ophthalmol* 2013;131:422–9.
- McLintock CA, Lee GA, Atkinson G. Management of recurrent Paecilomyces lilacinus keratitis. *Clin Exp Optom* 2013;96:343–5.
- Killingsworth DW, Stern GA, Driebe WT, et al. Results of therapeutic penetrating keratoplasty. *Ophthalmology* 1993;100:534–41.
- Ansari Z, Miller D, Galor A. Current thoughts in fungal keratitis: diagnosis and treatment. *Curr Fungal Infect Rep* 2013;7:209–18.
- Sun Y, Sun Z, Chen Y, et al. Corneal debridement combined with intrastromal voriconazole for recalcitrant fungal keratitis. *J Ophthalmol* 2018;2018:1875627.
- Zhang MC, Liu X, Jin Y, et al. Lamellar keratoplasty treatment of fungal corneal ulcers with acellular porcine corneal stroma. *Am J Transplant* 2015;15:1068–75.