

This is an Open Access article licensed under the terms of the Creative Commons Attribution-NonCommercial-NoDerivs 3.0 License ([www.karger.com/OA-license](http://www.karger.com/OA-license)), applicable to the online version of the article only. Distribution for non-commercial purposes only.

# Fibrocellular Contraction of a Lamellar Posterior Corneal Graft

Jesper Hjortdal<sup>a</sup> Anders Ivarsen<sup>a</sup> Steffen Heegaard<sup>b</sup>

<sup>a</sup>Department of Ophthalmology, Aarhus University Hospital, Aarhus, and

<sup>b</sup>Section of Eye Pathology, Department of Neuroscience and Pharmacology, University of Copenhagen, Copenhagen, Denmark

## Key Words

Anti-smooth muscle actin · Cornea · Endothelial keratoplasty · Transplantation

## Abstract

**Purpose:** To report a case of progressive fibrotic contraction of the posterior lamellar graft after initially successful Descemet's stripping automated endothelial keratoplasty (DSAEK).

**Methods:** Retrospective report of clinical data and histopathological analysis of excised corneal tissue.

**Results:** A 63-year-old woman underwent uncomplicated DSAEK in her left eye due to endothelial dystrophy. During the first months after surgery, her visual acuity was 0.3, and a semilunar contraction gradually appeared at the edge of the graft. Over the following months, the fibrotic changes progressed and visual acuity decreased, with no improvement after uncomplicated cataract surgery. A successful penetrating keratoplasty was performed, and the excised corneal button with an attached posterior lamellar graft was histologically examined. The affected part of the graft consisted of a thickened fibrocellular tissue positive for glycosaminoglycans and smooth muscle actin.

**Conclusions:** The present case demonstrates asymmetric fibrotic contraction of a DSAEK graft.

## Introduction

Posterior lamellar keratoplasty has become the preferred corneal transplant procedure for the treatment of Fuchs' endothelial dystrophy and secondary bullous keratopathy. To date, the posterior lamellar graft is most commonly created using a microkeratome, the so-called Descemet's stripping automated endothelial keratoplasty (DSAEK) [1, 2]. Posterior lamellar keratoplasty has been shown to have many advantages over

conventional penetrating keratoplasty: visual recovery is more rapid, corneal astigmatism is less, suture-related complications are avoided, and the procedure leaves the globe mechanically stable after surgery due to the small tunnel incision used [3]. Specific complications related to the DSAEK procedure include a possibly higher frequency of primary graft failure due to surgical complications, especially during the learning curve of the surgeon. The most common cause of posterior graft failure is a low endothelial cell count with a subsequent oedema [4], but epithelial implantation, remnants of Descemet's membrane, and fibrocellular tissue at the graft periphery have also been identified as causes of graft failure [5].

In this case report, we describe an occurrence of progressive asymmetric contraction of the posterior lamellar graft, eventually leading to re-transplantation.

### Case Report

A 63-year-old female patient presented with slowly progressive blurring of vision in both eyes. Slit-lamp examination revealed typical Fuchs' endothelial dystrophy with guttata and metal-beaten appearance of the endothelium. There was no significant cataract. Best-corrected visual acuity was 0.25 in the right and 0.2 in the left eye. The patient had DSAEK surgery in her worse, left eye.

An organ-cultured human donor cornea (male donor aged 40 years; endothelial cell count 2,300 cells/mm<sup>2</sup>) was acquired from The Danish Cornea Bank, Aarhus, Denmark. The donor cornea was mounted in the artificial chamber of a Moria ALTK microkeratome system (Moria, Antony, France), and a 350- $\mu$ m cutting head was used. Just before anterior keratectomy, the pressure in the anterior chamber was increased to 150 mm Hg. The cutting procedure was uneventful. An 8-mm Hessburg-Barron punch was used to cut the posterior lamellar graft to the desired diameter.

Conventional DSAEK surgery under peribulbar anaesthesia was performed using an anterior chamber maintainer, an inverse Sinsky hook, a Busin glide, and a dedicated pair of forceps (Moria) for pulling the graft into the anterior chamber via a 4-mm 12 o'clock incision. The graft was centred and the anterior chamber filled with a large air bubble. Two hours after surgery, the air bubble was reduced to approximately 30% of the chamber volume.

The immediate postoperative period was uneventful. One week after surgery, the patient's visual acuity was 0.2, and 1 month after surgery it was 0.3.

Three months after surgery, her visual acuity was still 0.3, and a white semilunar-shaped condensation could be observed in the nasal periphery of the graft that appeared to be well attached. Over the next months, the graft contracted and visual acuity worsened to 0.2. Pentacam HR visualisation of the graft illustrated a contraction of the rim of the graft (fig. 1a). A mild cataract developed, and the patient underwent uncomplicated phacoemulsification and intraocular lens implantation. Visual acuity did not improve, and therefore it was decided to perform a re-graft as an 8-mm penetrating keratoplasty (fig. 1b). The recipient cornea with the attached posterior lamellar graft was sent for histopathology. The postoperative course was uncomplicated, and the penetrating graft has been clear for more than 1 year. There are no visible remnants of the previous posterior lamellar graft. The patient's latest best corrected visual acuity with sutures was 0.25.

The fellow donor cornea to the cornea used for DSAEK surgery in this case was used for a penetrating keratoplasty in another patient. The post-operative follow-up of the recipient was uneventful.

### Histopathological Methods

The corneal button was fixed in 4% buffered formaldehyde and embedded in paraffin. Sections were cut at 4  $\mu$ m and mounted on glass slides; they were stained with haematoxylin-eosin, hematoxylin-phloxine-saffron, periodic acid-Schiff, colloidal iron and Alcian blue at 1.0 and 0.2 M MgCl<sub>2</sub>.

Immunohistochemical reactions were performed using the streptavidin-biotin method. The procedure included microwave processing. Antibodies against S-100, vimentin, smooth muscle actin, CD31, CD34, CD68, glial fibrillary acid protein, pancytokeratin and neuron-specific enolase were applied, and appropriate controls were performed.

#### *Histological Findings*

The patient's trephined cornea showed a normal epithelium and a normal Bowman's layer. The central thickness of the host corneal stroma was 432  $\mu\text{m}$ , and the central thickness of the failed DSAEK lenticule was 198  $\mu\text{m}$ . Retained host Descemet's membrane was observed peripheral to the lenticule. The endothelial cell count on the lenticule was 8 cells per high-power field. On one side, the donor Descemet's membrane, along with the innermost stromal collagen fibres, was retracted posteriorly, thereby exposing the thickened edge of the DSAEK lenticule (fig. 1c). In this area, the lenticule stroma consisted of a thickened fibrocellular tissue and stained strongly positive for acid and neutral mucopolysaccharides (glycosaminoglycans) using colloidal iron and Alcian blue at 0.2 M  $\text{MgCl}_2$ . The fibrocellular keratocytes in the lenticule were positive for antibodies against vimentin, smooth muscle actin and neuron-specific enolase but negative for antibodies against pancytokeratin, CD68, CD34, CD31, glial fibrillary acid protein and S-100.

#### **Discussion**

The present case illustrates that late and progressive complications also may arise after otherwise successful DSAEK surgery. It is well known that microkeratome cutting of posterior lamellar grafts results in a graft, which becomes gradually thicker towards the periphery. This is expected as the microkeratome ideally removes an anterior lamella of even thickness, whereas the cornea becomes thicker towards the periphery. Normally, this does not result in complications, although the lamellar lenticule changes the posterior curvature of the cornea, leading to a hyperopic shift of 0.5 to 1.0 dioptres.

A small decentration of the punch when cutting the posterior graft to the desired diameter may lead to asymmetric thickening towards the periphery. In the worst case scenario, the punch cut might reach beyond the edge of the anterior lamellar cut, which could lead to the inoculation of donor epithelial cells into the anterior chamber of the recipient's eye [4]. This did not appear to be the case in this patient, as no epithelial cells were found by histology and slit-lamp examination of the patient's re-grafted eye.

Histopathological examination revealed a thickened and loose fibrillar network corresponding to the area of contraction. Staining revealed the presence of activated keratocytes and abundant deposits of hyaluronic acid in the peripheral area of fibrocellular proliferation.

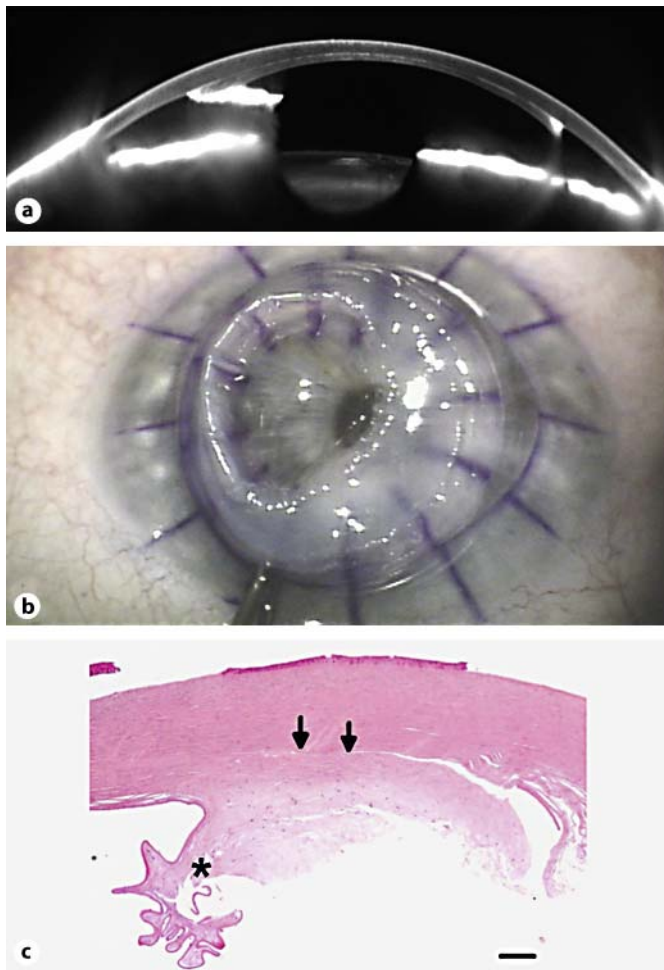
We postulate that the decentred punching of the posterior lamellar graft resulted in an asymmetric thickening of the graft's periphery. The thick, exposed stromal edge swelled, and the keratocytes produced glycosaminoglycans. With time, the keratocytes were activated and changed into fibroblasts, which were smooth muscle actin positive and capable of retracting the Descemet's membrane. Zhang et al. [4] described four different clinicopathological features in failed Descemet's stripping. One of the causes of failed DSAEK is a fibrocellular proliferation at the edge of the lenticule. Suh et al. [6] described fibrocellular tissue on the anterior stromal surface of the posterior lamellar graft. This was not observed in our case. In the present case, the scarring of the DSAEK at the periphery

caused a retraction of the donor Descemet's membrane. This scarring was considered secondary to a decentred thickened graft.

In order to avoid cases like the presented one in the future, further development of dedicated microkeratomes, which ensure a very large-diameter anterior lamellar cut, is needed. Alternatively, femtosecond lasers may be used to cut posterior lenticules from the endothelial side, although the visual quality after implantation of femtosecond laser-cut posterior lamellar grafts has been disappointing [7]. Finally, Descemet's membrane endothelial keratoplasty, in which the Descemet's membrane with endothelial cells is isolated exclusively, also would eliminate stromal tissue contraction, as described in this case report [8].

#### **Disclosure Statement**

The authors have no conflict of interest to declare.



**Fig. 1.** **a** Pentacam HR Scheimpflug images obtained 6 months after surgery. Note the excessive scar tissue at the nasal edge of the graft. **b** Image of the eye immediately after trephination. The excised cornea has been flipped around, and a phimosi of the posterior lamellar graft is clearly evident. **c** Micrograph of the excised recipient cornea with the posterior lamellar graft. The donor lenticule with the Descemet's membrane appears normal at the bottom (left). Towards the periphery of the lenticule, the Descemet's membrane takes a curly course over the contracted fibrocellular area of the DSAEK graft (asterisk). The two arrows indicate the interface between the patient's corneal stroma and the DSAEK graft. Bar = 200  $\mu$ m.

## References

- 1 Melles GR, Lander F, Rietveld FJ: Transplantation of Descemet's membrane carrying viable endothelium through a small scleral incision. *Cornea* 2002;21:415–418.
- 2 Gorovoy MS: Descemet-stripping automated endothelial keratoplasty. *Cornea* 2006;25:886–889.
- 3 Hjortdal J, Ehlers N: Descemet's stripping automated endothelial keratoplasty and penetrating keratoplasty for Fuchs' endothelial dystrophy. *Acta Ophthalmol* 2009;87:310–314.
- 4 Zhang Q, Randleman JB, Stulting RD, Lee WB, Stone DU, Kozarsky AM, Grossniklaus HE: Clinicopathologic findings in failed descemet stripping automated endothelial keratoplasty. *Arch Ophthalmol* 2010;128:973–980.
- 5 Lee JA, Djalilian AR, Riaz KM, Sugar J, Tu EY, Wadia H, Edward DP: Clinical and histopathologic features of failed descemet stripping automated endothelial keratoplasty grafts. *Cornea* 2009;28:530–535.
- 6 Suh LH, Dawson DG, Mutapcic L, Rosenfeld SI, Culbertson WW, Yoo SH, O'Brien TP, Dubovy SR: Histopathologic examination of failed grafts in descemet's stripping with automated endothelial keratoplasty. *Ophthalmology* 2009;116:603–608.
- 7 Cheng YY, Schouten JS, Tahzib NG, Wijdh RJ, Pels E, van Cleynenbreugel H, Eggink CA, Rijnveld WJ, Nuijts RM: Efficacy and safety of femtosecond laser-assisted corneal endothelial keratoplasty: a randomized multicenter clinical trial. *Transplantation* 2009;88:1294–1302.
- 8 Melles GR, Ong TS, Ververs B, van der Wees J: Descemet membrane endothelial keratoplasty (DMEK). *Cornea* 2006;25:987–990.