

## Penetrating ocular trauma by nail of a badminton feather shuttle cock: A rare case report

*Sudipta Das, Veer Singh, Kumar Saurabh*

Sports-related ocular traumas may be rare, but can have devastating and disabling consequences. The causes of eye-related injuries depend on the type of sports popular in a particular area or country. Badminton is a popular sport played by all age groups and socioeconomic segments and is popular in many parts of the world. It is most popular in South-East Asia, accounting for two-thirds of all ocular sports injury in Malaysia. In India, badminton has become quite popular in recent years. Shuttlecocks in badminton have been shown to be responsible for a high number of outpatient ocular sports-related, mostly blunt injuries. We report an unusual case of penetrating ocular injury due to a feather shuttlecock and its surgical management.

Access this article online	
Quick Response Code:	Website: www.ijo.in
	DOI: 10.4103/ijo.IJO_1681_19

Department of Vitreo Retina, Aditya Birla Sankara Nethralaya, Kolkata, West Bengal, India

**Correspondence to:** Dr. Sudipta Das, Aditya Birla Sankara Nethralaya, 147 Mukundapur, E.M. Bypass, Kolkata - 700 099, West Bengal, India. E-mail: drsudipta07@gmail.com

Received: 15-Sep-2019

Revision: 12-Dec-2019

Accepted: 29-Dec-2019

Published: 25-May-2020

**Key words:** Badminton, penetrating trauma, shuttlecock

### Case Report

An 11-year-old boy presented with a history of trauma to right eye from a projectile nail that came out of a feather shuttlecock while playing badminton. He complained of slight diminution of vision associated with pain and redness following the trauma. His uncorrected visual acuity was 6/18 and 6/6 in his right and left eyes, respectively. Anterior segment examination of the right eye revealed a scleral penetrating injury with a metal nail in the infero-temporal quadrant, the entry point of the nail being 3–4 mm from the limbus [Fig. 1a and d]. The cornea was clear, pupil reaction slightly sluggish, anterior chamber formed with 2+ cells and a clear lens. Left eye examination was unremarkable.

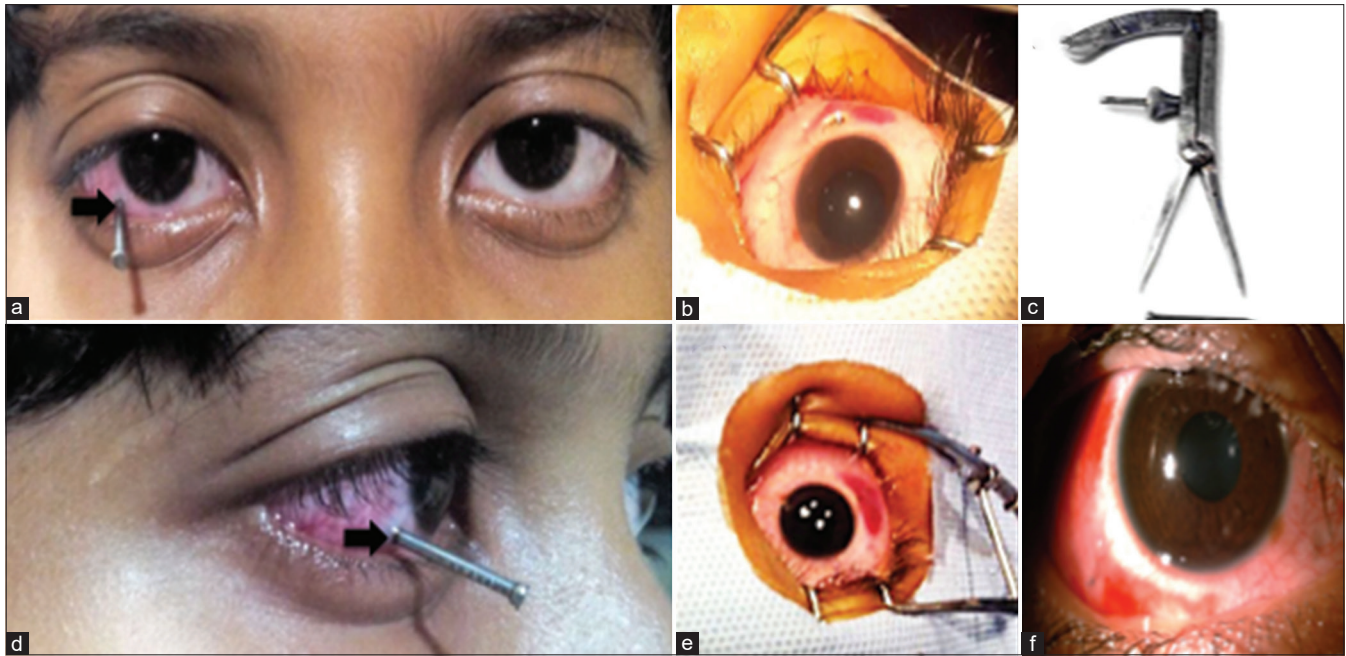
Dilated fundus examination of the right eye showed clear vitreous and attached retina with a normal disc and macula. Peripheral retina did not reveal any break or hemorrhage and the nail was not seen inside the vitreous. Scleral indentation was deferred. The left eye was normal.

Immediate surgery was planned and the child underwent foreign body removal, scleral tear repair, transscleral cryopexy at the site of injury, and intravitreal injection of vancomycin and ceftazidime under general anesthesia [Fig. 1a and e]. The site of injury was found to be 3 mm from the limbus and nail length 20 mm when measured intraoperatively [Fig. 1c]. The

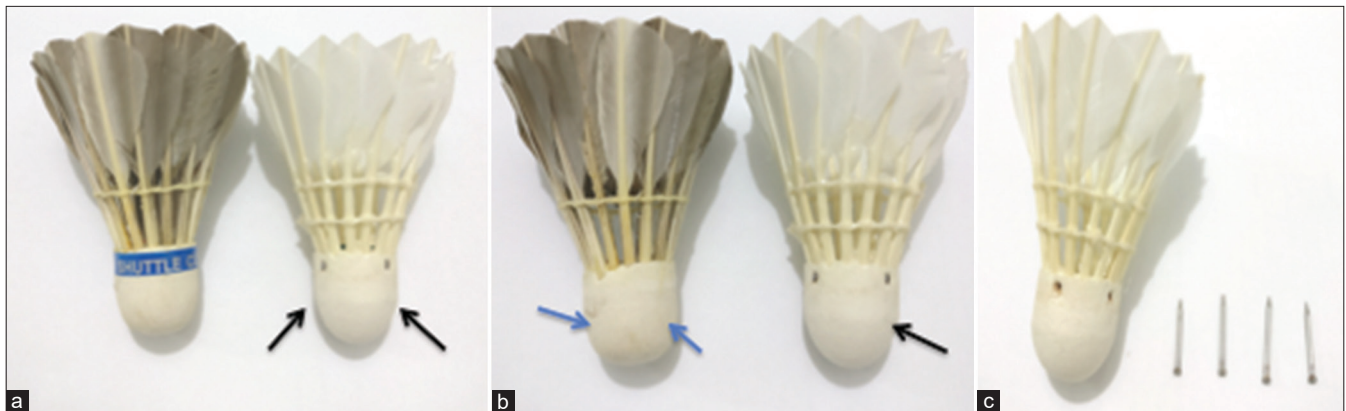
This is an open access journal, and articles are distributed under the terms of the Creative Commons Attribution-NonCommercial-ShareAlike 4.0 License, which allows others to remix, tweak, and build upon the work non-commercially, as long as appropriate credit is given and the new creations are licensed under the identical terms.

**For reprints contact:** reprints@medknow.com

**Cite this article as:** Das S, Singh V, Saurabh K. Penetrating ocular trauma by nail of a badminton feather shuttle cock: A rare case report. Indian J Ophthalmol 2020;68:1209-11.



**Figure 1:** (a and d) Anterior and lateral view of the metal nail entry point at pars plana of right eye at infero-temporal quadrant (Black solid arrow) (b and e) closed scleral entry point following surgical removal of nail, (c) 20 mm iron nail measured by calipers, (f) first postoperative day with sutured entry wound and localized conjunctival chemosis



**Figure 2:** (a and c) Conventional feather shuttlecock with radial nails (black arrows) to fix the cork unit with feathers, (b) absence of nails (blue arrows) in expensive shuttlecocks compared to conventional local brands

intraoperative wound after closure and its postoperative day one appearance is also mentioned [Fig. 1b and f].

Six weeks later, the patient had a best-corrected visual acuity of 6/6 in the right eye with a quiet anterior segment, clear vitreous, attached retina and no peripheral breaks. At 3 months and 6 months post surgery, both anterior and posterior segments remained stable.

To confirm the source of the nail, the patient was asked to bring the pack of feather shuttlecocks which was being used for the sport. A few different brands of shuttlecock were also bought from the local market for comparison. On dissection of shuttlecocks from each of the packs, the expensive varieties of feather shuttlecock did not show any nails in it. On the other hand, the one from the patient's pack revealed 4 radially directed nails present at the base of the shuttlecock, which were

the same as the one retrieved from the patient's eye [Fig. 2a-c]. This confirmed the source of the nail in the patient's eye.

## Discussion

Ocular injury with a shuttlecock can lead to significant damage. There are reports of 12.5% of ocular trauma from all causes to sports.<sup>[1,2]</sup> A total of 14.3% of sports-related injuries can be attributed to badminton.<sup>[3]</sup> Shuttlecock and racquet are responsible for 6% and 7% of badminton-related ocular injuries, respectively.<sup>[4]</sup> Shuttlecock can attain extreme velocities during its projectile trajectory with the current advances in racquet technology. To the best of our knowledge, the entire shuttlecock-related ocular injuries reported so far are blunt trauma except when a penetrating injury had occurred as a result of shattering of the glass of spectacles worn by a player while playing badminton.<sup>[5]</sup> The use of spectacles is associated

with increased frequency of injury related to glass shattering. Hence, glass spectacles are dangerous and should never be worn by sportsmen. If refractive correction must be worn, then it should ideally be incorporated into polycarbonate protective spectacles.<sup>[6]</sup> In a study by Chandran,<sup>[1]</sup> shuttlecock injuries have been shown to account for hyphaema in 53.3% of cases. A total of 27% of such patients develop an impaired vision of 6/60 or less due to macular edema, traumatic cataract, or glaucoma.<sup>[1]</sup>

In our case, the nail, which resulted in the penetrating ocular injury, allegedly came out of a feather shuttlecock while playing badminton. On further investigation, the source of the nail was confirmed to be from a locally purchased shuttlecock. It is important to beware of such locally available indigenous shuttlecocks and the extent of damage that they can cause. Multiple types of shuttle brands are available all over the country. We recommend readers to dissect a sample shuttlecock to check the presence of nail before continuing with any local shuttle brand if known international established brands are not in use. Regulatory authorities should be intimated in case of any manufacturing discrepancy. Our case was lucky to have the entry point in the pars plana and to have received timely and prompt management, but such nails can lead to devastating ocular trauma leading to significant visual impairment. This is a unique case report reporting an unusual badminton-related penetrating ocular trauma with the aim of creating awareness regarding this particular kind of ocular injury. Prospect for prevention of sports-related trauma can be addressed with vigorous education among the players, coaches, and parents. The Ontario Badminton Association (OBA) has made the use of special eye protectors (manufactured according to American Society for Testing and Materials F803 specifications) mandatory for all junior racquet players in OBA-sanctioned tournament. Taking cue from the OBA, eye protectors should be made compulsory for racquet sports players all over the world.<sup>[7]</sup>

The Protective Eyewear Promotion (PEP) model should be adopted for all badminton players. The model recommends appropriate education of the players with respect to protective eyewear, usage of synthetic shuttlecocks, tailoring the advice for each individual player, making the eyewear more available to them, and providing incentives for using protective eyewear to potentiate safe-behavior. This model has been shown to reduce the risk of eye injury in squash players.<sup>[8]</sup> Prevention is the best option for management and it has been suggested that more than 90% of sports-associated eye injuries can be avoided.<sup>[9]</sup> Even with advanced microsurgical treatment, the result of severe eye injuries is usually unsatisfactory. Prophylaxis is important and remains the only gold standard for preventing such devastating injuries. Protective polycarbonate spectacles are available for wear on the court and are designed to deflect blows onto the glabella and orbit margins. They can incorporate refractive correction and should be encouraged. Under no

circumstances should a player wear glass spectacles. It is the duty of his optometrist or ophthalmologist to dissuade him from so doing. The illusion that contact lenses offer partial protection in this situation should be dispelled. They merely complicate an injury.<sup>[10]</sup>

#### Declaration of patient consent

The authors certify that they have obtained all appropriate patient consent forms. In the form the patient has given his consent for his images and other clinical information to be reported in the journal. The patient understand that his name and initial will not be published and due efforts will be made to conceal their identity, but anonymity cannot be guaranteed.

#### Conclusion:

Shuttlecocks in badminton have been shown to be responsible for a high number of outpatient ocular sports-related, mostly blunt injuries. We report an unusual case of penetrating ocular injury due to a feather shuttlecock and its surgical management, and emphasize that the players should wear protective polycarbonate glasses.

#### Financial support and sponsorship

Nil.

#### Conflicts of interest

There are no conflicts of interest.

#### References

1. Chandran S. Ocular hazards of playing badminton. *Br J Ophthalmol* 1974;58:757-60.
2. Barr A, Baines PS, Desai P, MacEwen CJ. Ocular sports injuries: The current picture. *Br J Sports Med* 2000;34:456-8.
3. Jones NP. Eye Injuries in sport: An increasing problem. *Br J Sports Med* 1987;21:168-70.
4. Kelly SP. Serious eye injury in badminton players. *Br J Ophthalmol* 1987;71:746-7.
5. Barrell GV, Cooper PJ, Elkington AR, Macfadyen JM, Powell RG, Tormey P. Squash ball to eye ball: The likelihood of squash players incurring an eye injury. *BMJ (Clin Res Ed)* 1981;283:893-5.
6. Cass SP. Ocular injuries in sports. *Curr Sports Med Rep* 2010;11:11-5.
7. Ontario Badminton Association guidelines: OBA (Web site). Available from: <http://www.kwbadminton.com/club-guidelines/> [Last accessed on 2020 Jan 24].
8. Eime R, Owen N, Fench C. Protective eyewear promotion: Applying principles of behaviour change in the design of squash injury prevention programme. *Sports Med* 2004;34:629-38.
9. McLean CP, DiLillo D, Bornstein BH, Bevins RA. Predictors of goggle use among acquetball players. *Int J Inj Contr Saf Promot* 2008;15:167-70.
10. Jones NP. One year of severe eye injuries in sport. *Eye* 1988;2:484-7.