

Received: 2011.09.06
Accepted: 2012.05.02
Published: 2013.07.29

Hybrid approach for closure of muscular ventricular septal defects

Authors' Contribution:

Study Design A
Data Collection B
Statistical Analysis C
Data Interpretation D
Manuscript Preparation E
Literature Search F
Funds Collection G

ABCDE 1 **Ireneusz Haponiuk**
ABDEG 1 **Maciej Chojnicki**
ABCEF 1 **Radoslaw Jaworski**
ABEF 1 **Mariusz Steffek**
ABDF 1 **Jacek Juscinski**
ABCD 1 **Mariusz Sroka**
BCD 1 **Roland Fiszer**
BCF 1 **Aneta Sendrowska**
BEF 2 **Katarzyna Gierat-Haponiuk**
ADE 1 **Bohdan Maruszewski**

1 Department of Pediatric Cardiac Surgery, Mikolaj Kopernik Pomeranian Centre of Traumatology, Gdańsk, Poland
2 Department of Rehabilitation, Medical University of Gdańsk, Gdańsk, Poland

Corresponding Author: Ireneusz Haponiuk, e-mail: ireneusz_haponiuk@poczta.onet.pl
Source of support: Self financing

Background: The complexity of ventricular septal defects in early infancy led to development of new mini-invasive techniques based on collaboration of cardiac surgeons with interventional cardiologists, called hybrid procedures. Hybrid therapies aim to combine the advantages of surgical and interventional techniques in an effort to reduce the invasiveness. The aim of this study was to present our approach with mVSD patients and initial results in the development of a mini-invasive hybrid procedure in the Gdansk Hybrid Heartlink Programme (GHHP) at the Department of Pediatric Cardiac Surgery, Pomeranian Centre of Traumatology in Gdansk, Poland.





Material/Methods: The group of 11 children with mVSDs was enrolled in GHHP and 6 were finally qualified to hybrid trans-ventricular mVSD device closure. Mean age at time of hybrid procedure was 8.22 months (range: from 2.7 to 17.8 months, SD=5.1) and mean body weight was 6.3 kg (range: from 3.4 to 7.5 kg, SD=1.5).

Results: The implants of choice were Amplatzer VSD Occluder and Amplatzer Duct Occluder II (AGA Med. Corp, USA). The position of the implants was checked carefully before releasing the device with both transesophageal echocardiography and epicardial echocardiography. All patients survived and their general condition improved. No complications occurred. The closure of mVSD was complete in all children.

Conclusions: Hybrid procedures of periventricular muscular VSD closure appear feasible and effective for patients with septal defects with morphology unsuitable for classic surgical or interventional procedures. The modern strategy of joint cardiac surgical and interventional techniques provides the benefits of close cooperation between cardiac surgeon and interventional cardiologist for selected patients in difficult clinical settings.

Key words: **ventricular septal defect • device closure • mini-invasive hybrid procedures • congenital heart defects • cardiac surgery**

Full-text PDF: <http://www.medscimonit.com/download/index/idArt/883985>

 2664  1  3  18

Background

Muscular ventricular septal defects account for 20% of the total ventricular septal defects in the population [1]. Most muscular ventricular septal defects (mVSD) are single and isolated lesions that close spontaneously in their natural history. Sometimes there are many different muscular communications between the left and right ventricles, called 'swiss-cheese' type septal defects. Muscular VSDs may cause clinical signs and symptoms of pulmonary overflow with left-sided volume overload. This may result in heart failure, especially in infants with hemodynamically significant unrestricted communications [2].

Unsuitable localization for a classic surgical closure of mVSDs can be challenging in congenital heart surgery. In such situations it is not uncommon that residual shunts are still present despite several attempts to close multiple muscular defects [3]. This results in higher mortality and morbidity and increases the risk of reoperation and ventricular dysfunction due to right or left ventriculotomy [4]. Therefore, closure of small mVSDs with no hemodynamic compromise remains controversial, facing expected spontaneous closure of 80% of the defects in the first 2 years life [2]. Device closure of mVSDs can be successfully accomplished using transcatheter technique when the child reaches a body weight that allows intervention.

The complexity of ventricular septal defects in early infancy led to development of new mini-invasive techniques based on collaboration of cardiac surgeons with interventional cardiologists, called hybrid procedures [5]. Hybrid therapies aim to combine the advantages of surgical and interventional techniques in an effort to reduce the invasiveness (e.g., cardiopulmonary bypass, cardioplegic arrest, incision trauma, groin vessel injury, and risk of tricuspid insufficiency) of a cardiac procedure [6]. In selected babies, the trans-ventricular hybrid technique may be more feasible and advantageous, although closure of mVSDs is still one of the most challenging procedures in cardiac intervention and surgery [2].

The aim of this study was to present our approach with mVSD patients and initial results in the development of a mini-invasive hybrid procedure in the Gdansk Hybrid Heartlink Programme (GHHP) at the Department of Pediatric Cardiac Surgery, Pomeranian Centre of Traumatology in Gdansk, Poland. We present different approach strategies to patients referred for surgery with the diagnosis of mVSDs, individually modified with regard to morphology of muscular defects, or accompanying pathologies, requiring additional interventions.

Material and Methods

We present a group of 11 patients with the diagnosis of muscular ventricular septal defects, who consecutively entered GHHP

at the Department of Pediatric Cardiac Surgery, Pomeranian Centre of Traumatology in Gdansk, Poland (Table 1). Six groups of patients were identified: children with isolated mVSDs treated primarily with mini-invasive hybrid procedure (n=2); patients with multiple mVSDs and pulmonary artery banding (n=3); children with coarctation of the aorta (CoA) and muscular VSDs or other complex cardiac lesions, who after initial coarctation repair and pulmonary artery banding (PA) finally underwent hybrid mVSD procedure (n=2); an infant with large perimembranous VSD and accompanying mVSD that had to be closed periventricularly after routine extracorporeal circulation (ECC) (n=1); patients with mVSD who are listed for primary hybrid mVSD closure (n=2); and 1 patient with mVSD, whose parents refused permission for treatment (n=1).

This study is a part of GHHP, which was initiated in 2008 to introduce and develop mini-invasive hybrid techniques in our department. Inclusion criteria for patients with muscular septum defects were: infants with muscular VSD or multiple VSDs, either isolated defects, or accompanied by other cardiac lesions necessitating operative repair; as well as patients after initial palliative treatment, who underwent pulmonary artery banding because of pulmonary overflow in early infancy. Free consent was obtained from well informed parents of all involved or potentially recruited patients in the outpatient clinic. We present 4 different strategies of hybrid mVSD closure:

1. Single-stage hybrid mVSD closure with the use of the Amplatzer VSD Occluder (AGA Med. Corp., USA) device.
2. Two-stage approach in patients with a complex multi-mVSDs and neonatal critical aortic coarctation repair, when hybrid mVSD closure is the final procedure with surgical PA de-banding.
3. One-stage hybrid approach as combination of open heart surgical closure of perimembranous VSD with a novel use of the Amplatzer Duct Occluder II (AGA Med. Corp., USA) device.
4. Routine 2-stage approach with PA banding, inducing septum hypertrophy and after reevaluation, a hybrid or percutaneous mVSD closure.

The first group consisted of children with mVSDs observed from birth, with significant left-to-right shunts ($Q_p: Q_s > 1.6:1$) and signs of LV overload (LV enlargement, mitral insufficiency, left atrial enlargement, and poor contractility) on ECHO. In the second group were babies after critical coarctation repair supplemented with PA banding under direct PA pressure monitoring, systemic pressure, respiratory pCO₂ measurement, and peripheral saturation control. The definitive procedure with hybrid mVSD closure and PA de-banding was performed after meticulous evaluation of patients, including clinical status, peripheral desaturation, and echocardiographic symptoms of RV and septal hypertrophy. In the third group, perimembranous VSD was closed using ECC and muscular defects were closed

Table 1. Patients with muscular ventricular septal defect in Gdansk Hybrid Heartlink Programme.

No	Patient initials	Diagnosis	Largest mVSD diameter at diagnosis	Implantation mode	Two-step treatment	Age at mVSD closure (months)	Weight at mVSD closure (kg)	First operation (1 st step)	Device type and size (mm)	Second operation (2 nd step)	Follow-up after mVSD closure (months)	Status
Children with isolated muscular VSD treated primarily with miniinvasive hybrid procedure												
1	KA	mVSD	5	Perven-tricular	No	17.8	6.8	Hybrid mVSD closure	AVSDO 6	–	Success (27)	Alive
2	CW	mVSD	6	Percutaneous	No	18	10.5	Percutaneous mVSD closure	AVSDO 8	–	–	Alive
Children with isolated muscular VSD referred for two step procedure												
3	TT	mVSD	1,5	–	Yes	30.4	12	PA banding	–	PA debanding, VSD calibration	–	Alive
4	RB	mVSD	7	perven-tricular	Yes	8	7.5	PA banding	AVSDO 4	PA debanding, hybrid mVSD closure	Success (16)	Alive
5	KK	mVSD	10	Perven-tricular	Yes	7	6	PA banding	ADOII 12	PA debanding, hybrid mVSD closure	Success (5)	Alive
Children with coarctation of the aorta and muscular VSD treated with miniinvasive hybrid procedure as a second step procedure												
6	GA	mVSD, CoA	5,5	Perven-tricular	Yes	7	7	PA banding, CoA plasty	AVSDO 8	PA debanding, hybrid mVSD closure	Success (32)	Alive
7	UOW	mVSD, HAA, CoA	10	Perven-tricular	Yes	6.8	7	PA banding, HAA and CoA plasty	AVSDO 10	PA debanding, hybrid mVSD closure	Success (20)	Alive
Child with muscular VSD and perimembraneous VSD treated with miniinvasive hybrid procedure and VSD closure in ECC												
8	WR	mVSD, perimem-braneous VSD	4	Perven-tricular	No	2.7	3,4	pVSD closure in ECC, hybrid mVSD closure	ADOII 5	–	Success (26)	Alive
Children with muscular VSD waiting for primary hybrid procedure												
9	SP	mVSD	4	–	No	–	–	Awaiting	–	–	–	Alive, moderate HF
10	NC	mVSD	3	–	No	–	–	Awaiting	–	–	–	Alive, mild HF
Child with muscular VSD, who's parents disagreed for treatment												
11	RZ	mVSD	6	–	No	–	–	Treatment disagreement	–	–	–	Alive, mild HF

mVSD – muscular ventricular sep tal defect; pVSD – perimembraneous ventricular defect; CoA – coarctation of the aorta; HAA – hypoplastic aortic arch; PA – pulmonary artery; AVSDO – Amplatzer VSD Occluder; ADOII – Amplatzer Duct Occluder II; ECC – extracorporeal circulation; HF – heart failure.

periventricularly with devices during the same open heart procedure. The fourth group was babies with initial diagnosis of mVSD who underwent elective primary PA banding to prepare the patient for the final operation and PA de-banding when the defects will close after induced RV hypertrophy. Of the 11 involved patients, 2 were in generally good condition, and were

regularly examined and observed as candidates for hybrid approach when the left-to-right shunt definitely appears hemodynamically significant. Criteria by which patients were excluded from periventricular device closure were the same as for standard ECC procedure (infections, contraindications for heparin administration, instable metabolic status, and renal and

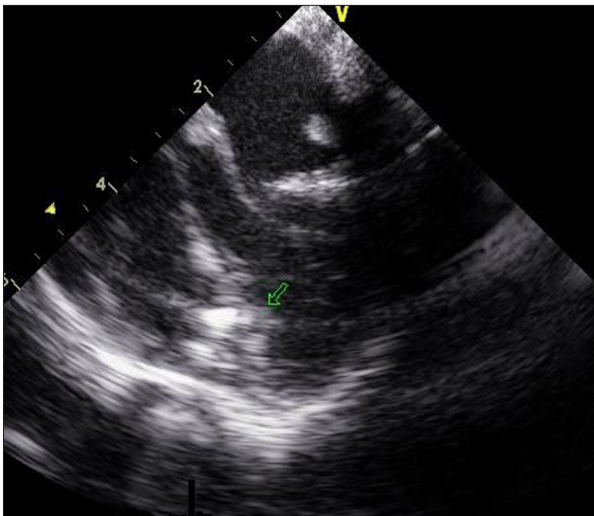


Figure 1. The guiding wire is passed through the muscular ventricular septal defect – intraoperative transoesophageal echocardiography (TEE) image.

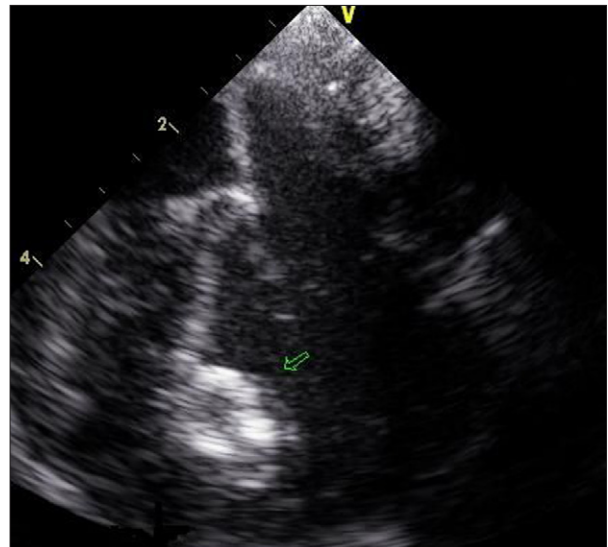


Figure 2. Muscular ventricular septal defect closure with one disc expanded – transoesophageal echocardiography (TEE) image.

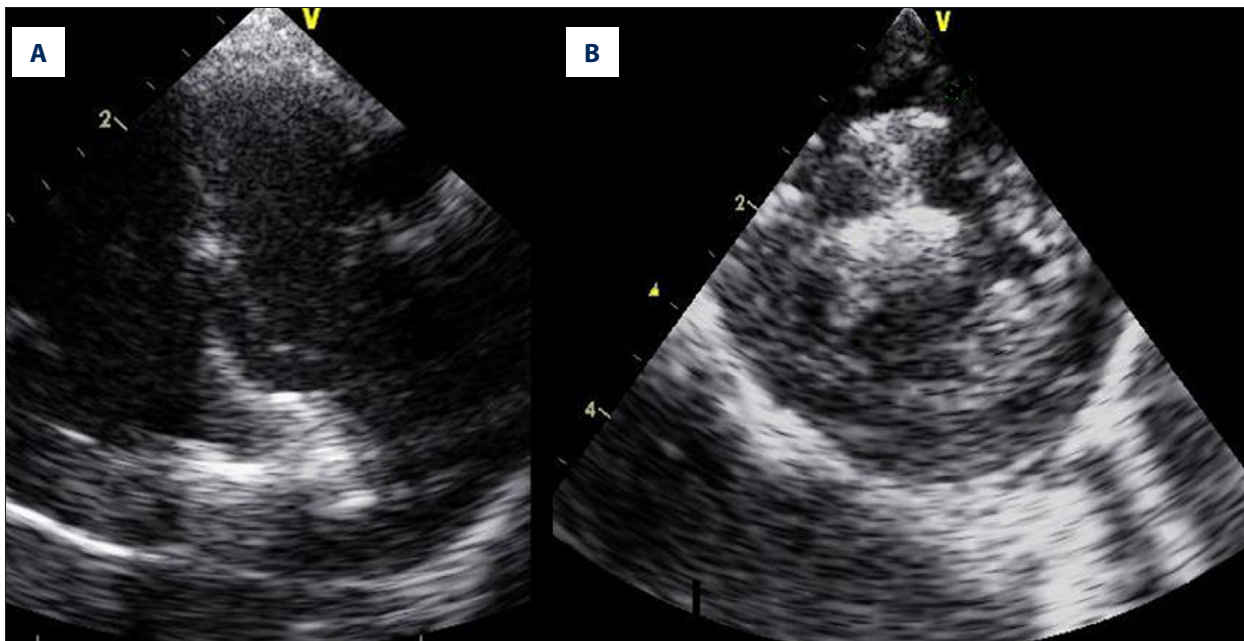


Figure 3. The muscular ventricular septal defect occluding device implanted into the septum – transoesophageal echocardiography image (TEE) (A) and epicardial echocardiography (EE) image (B).

liver failure), as well as parental refusal to allow blood products transfusion or any cardiac procedures.

Hybrid approach for mVSD procedure: the technique

The child referred for hybrid procedure is prepared for a classic cardiac procedure under general anesthesia in a routine fashion, with extracorporeal circulation ready to be commenced in case of any complications. After a classic median sternotomy,

the heparin is administered in a half-dose as for cardiopulmonary bypass (1.5 mg/kg body weight) and a purse string suture is placed on the free wall of the right ventricle facing the location of the mVSD. The purse string site is precisely localized with simultaneous transoesophageal echocardiography (TEE) and epicardial echocardiography (EE), to find an optimal puncture point just opposite the largest muscular VSD. A gentle palpation on the right ventricle (RV) free wall is helpful in identifying the optimal location. A 6F gauge needle is inserted through

the purse string suture on the RV free wall into the RV cavity, followed by a guiding “wire” inserted before removing the needle. The guiding wire is manoeuvred towards the mVSD to pass the septum to the LV, while the needle is removed (Figure 1). A sheath dilator is used to pass the RV free wall easily. It is crucial to localize the tip of the dilator to prevent any injury to the LV structures. Under TEE on beating heart, the left disc is expanded and attached to the septum with a guiding wire. The right disc is expanded in the right ventricle to commence closing the VSD (Figure 2). The position of the implant is checked carefully before releasing the device with both TEE and EE. The wires are removed and finally the purse string is tied (Figure 3). After the operation, standard pediatric cardiac surgical perioperative monitoring is used routinely. The heparin infusion (under activated partial thromboplastin time control) is continued until an oral acetylsalicylic acid (10 mg/kg body weight/day) is administered for 3–6 months. In the larger implants or an apical localization, the acetylsalicylic acid is continued longer than 6 months. The follow-up outcome after periventricular mVSD closure was analyzed in terms of success of the procedure, which is defined as adequate placement of the device, the lack of or trivial (<1 mm color jet width) residual shunt, with regard to any procedure-related late complications, patient status and psychosocial condition during the standard controls in the outpatient clinic.

Results

In the total group of 11 patients with mVSD involved in GHHP, 6 children were qualified to hybrid trans-ventricular mVSD device closure. Mean age at time of hybrid procedure was 8.22 months (range: from 2.7 to 17.8 months, SD=5.1), mean body weight was 6.3 kg (range: from 3.4 to 7.5 kg, SD=1.5). There were 4 girls and 2 boys. An isolated mVSD appeared in only 2 children in this group, in every other case of muscular defects there were accompanying pathologies: perimembranous VSD with separate mVSD in 1 child and critical aortic coarctation (CoA) in another 2 babies. In all but 1 patient, preoperative LV function was in the borderline normal range (LVEF >50%, SF >40%), with clear evidence of pulmonary congestion in a routine chest X-ray in all infants.

The size of mVSDs ranged from 4 to 10 mm, with a median of 7 mm (SD=2.6). A single occluder (Amplatzer VSD Occluder or Amplatzer Duct Occluder II, AGA Med. Corp., USA) was successfully implanted in all 6 patients. Mean postoperative hospital stay was 9 days. All patients survived. Four patients, after hybrid mVSD closure, were extubated within the first 10 hours after the procedure, and 2 others required prolonged ventilation for up to 6 days due to preoperative heart failure. Six patients, after hybrid procedures, were discharged home in general good condition, no atrioventricular blocks, heart insufficiency, or pericardial effusions were observed. One patient

(KK) required prolonged pleural drainage postoperatively (to postoperative day 4) due to pleural effusions. Mean follow-up is now 21 months (range: from 5 to 32 months, SD=9.6) after hybrid mVSD closure. Regular physical and echocardiographic examinations are performed in our outpatient clinic. All patients are free of any cardiac events and medication, with no neurocognition deficits or circulatory insufficiency. There were no complications observed during follow-up. Residual shunts that were measured in outpatient echocardiography controls showed Qp: Qs<1.5:1, with the tendency to gradually decrease.

In 1 girl (TT) (Table 1) referred for surgical PA-debanding, who initially underwent coarctation repair and PA-banding, the left-to-right shunt appeared hemodynamically insignificant. Thus, after removing the PA banding, a hybrid procedure was abandoned. The patient is under careful follow-up.

One patient (CW) (Table 1) with isolated, hemodynamically significant mVSD, who was initially included into GHHP, at the age of 18 months underwent successful percutaneous mVSD closure with an Amplatzer VSD Occluder (AGA Med. Corp., USA) without any complications.

Two children are still awaiting hybrid mVSD closure procedure, and 1 of them has been referred for PA banding. Both children are regularly controlled in the outpatient clinic. Parents of another girl, who received complete information about natural history and pathophysiology of mVSD, potentially adverse effects of hybrid operation, as well as of cessation of treatment, finally refused consent for any medical intervention. The child remains under observation in a different institution.

Discussion

This report summarizes our single-centre experience in hybrid operations with periventricular muscular VSD closure. Our intention was to offer an alternative option for small, “borderline” babies, who are usually failing to thrive, with low body weight, and in individuals that have concomitant abnormalities that may require several staged interventions. After initial training and detailed preparation of therapeutic plans, we decided to undertake the challenge.

The first successful case of intraoperative periventricular device closure on the beating heart in an infant was reported in 1998 [7]. After that, a few authors have presented their initial experience in hybrid approach with promising results, and techniques are still evolving [8–13]. Following the literature on hybrid therapies, it appears that the advantages of surgical and interventional techniques, which are beneficial in borderline babies who do not meet criteria for surgery or cardiac intervention. Hybrid procedures have the advantage of avoiding

cardiopulmonary bypass and complications of vascular access in small and hemodynamically unstable babies [4].

Hybrid strategy is a reasonable alternative to transcatheter closure of mVSDs, mainly because of high risk of significant complications and residual shunt when performed in small children. Also, prolonged exposure to radiation associated with this procedure carries long-term undesirable and potentially detrimental side-effects [2,6].

The advantages of hybrid approach are closure of the defect under direct control, smaller risk of hemodynamic compromise and reduced device closure falls, as well as simultaneous possibility of other defects correction. In our group of patients, we performed other cardiac procedures simultaneously with the hybrid approach: surgical closure of perimembranous VSD or PA de-banding, with use of classical surgical approach via midline sternotomy.

With regard to periventricular technique used for mVSD closure, the aid of an experienced echocardiographer is crucial to provide perfect imaging during procedure of implant placement, as well as for safe catheter manipulation, device delivery and deployment, and post-release position in the septum [14]. All hybrid procedures were performed under TEE guidance, but we also used an epicardial probe that was helpful in precise assessment of mVSD position and shape (Figure 3). All steps of the procedure must be accomplished gently, with minimal manipulation and invasiveness, and the imaging must be perfect.

There is no doubt that mVSDs are frequently hidden within the RV trabeculations and therefore are difficult to localize through the standard surgical approach via the right atrium and tricuspid valve. Therefore, in 1 of the presented patients we closed perimembranous VSD using cardioplegic ECC, and after the failure to localize mVSD, we "restored" heart function and periventricularly closed mVSD on the beating heart with a VSD occluder. Although the device of choice in our experience is the Amplatzer VSD Occluder (AGA Med. Corp., USA) with self-expandable double-discs made from nitinol wire mesh, the more suitable implant in this case (premature baby aged 2 months, body weight 3.4 kg) was the Amplatzer Duct Occluder II because its small discs, which does not interfere with intracardiac structures in a small heart. This could be an argument for the industry to provide more delicate ventricular occluding implants dedicated to very small patients. To the best of our knowledge there is still a lack of such devices available commercially.

The patients with multiple mVSDs usually need special consideration. In our opinion, there is no need to place many devices

to close several defects separately. We follow the experience of Gan et al, who suggest that in children with many small nearby mVSDs, after the largest and most central defect device closure, the nearby smaller defect might become even smaller, making it difficult to pass the guidewire to the LV cavity [15]. This might be due to the local compression of inserted device on the muscular bridges between smaller defects, and narrowing the diameter of unclosed defects. The flanges of in-site devices may partially cover the nearby defects.

The body weight of hybrid patients less than 5.2 kg is thought to be associated with increased risk of complications [11]. The smallest of our patients was 3.4 kg, a premature neonate who had successful hybrid mVSD closure without any complications. The most common complications reported in the literature on mVSD device closure are device embolization, cardiac perforation, and even intraoperative deaths. Other complications are transient loss of arterial pulse after the procedure, blood loss requiring blood transfusion, hematoma, complete heart block, ventricular tachyarrhythmia, hypotension, injury of the aortic valve, stroke, and device-related hemolysis [2,6,16–18]. We believe that heart blocks can be avoided by careful patient selection and avoiding inlet type of defects.

The limitations of our preliminary report are the small number of patients and short follow-up. Our promising results suggest the value of offering hybrid treatment to other patients, and encourage us to continue our GHHP.

Conclusions

Our initial results demonstrate that hybrid procedures of periventricular muscular VSD closure appear feasible and effective for patients with unfavorable morphology, and who are unsuitable for classic surgical or interventional closure. A modern strategy combining cardiac surgery with interventional techniques provides patients with difficult clinical factors with the benefits of cooperation between cardiac surgeon and interventional cardiologist.

Acknowledgments

We strongly acknowledge Dr Mark Galantowicz and Dr John Cheatham from Nationwide Children's Hospital in Columbus, Ohio, USA, who strongly supported our initial attempts to create Gdansk Hybrid Heartlink Programme in the Department of Pediatric Cardiac Surgery, Pomeranian Centre of Traumatology in Gdansk, Poland.

References:

1. Rudolph A: Ventricular septal defect. *Congenital Diseases of the Heart: Clinical-Physiological Considerations*. NY: Futura Publishing Company, 2001: 197-244
2. Amin Z, Cao QL, Hijazi ZM: Closure of muscular ventricular septal defects: Transcatheter and hybrid techniques. *Catheter Cardiovasc Interv*, 2008; 72: 102-11
3. Haponiuk I, Chojnicki M, Jaworski R et al: Delayed closure of multiple muscular ventricular septal defects in an infant after coarctation repair and a hybrid procedure – a case report. *Heart Surg Forum*, 2011; 14: E67-69
4. Abadir S, Sarquella-Brugada G, Mivelaz Y et al: Advances in paediatric interventional cardiology since 2000. *Arch Cardiovasc Dis*, 2009; 102: 569-82
5. Bacha EA, Cao QL, Galantowicz ME et al: Multicenter experience with per-ventricular device closure of muscular ventricular septal defects. *Pediatr Cardiol*, 2005; 26: 169-75
6. Bacha EA, Hijazi ZM: Hybrid procedures in pediatric cardiac surgery. *Semin Thorac Cardiovasc Surg Pediatr Card Surg Annu*, 2005; 78-85
7. Amin Z, Berry JM, Foker JE et al: Intraoperative closure of muscular ventricular septal defect in a canine model and application of the technique in a baby. *J Thorac Cardiovasc Surg*, 1998; 115: 1374-76
8. Lang N, Kozlik-Feldmann R, Meyer-Gold A et al: Modification of a hybrid technique for closure of muscular ventricular septal defects in a pig model. *Heart Surg Forum*, 2010; 13: E299-304
9. Crossland DS, Wilkinson JL, Cochrane AD et al: Initial results of primary device closure of large muscular ventricular septal defects in early infancy using perventricular access. *Catheter Cardiovasc Interv*, 2008; 72: 386-91
10. Haponiuk I, Chojnicki M, Jaworski R et al: Miniinvasive hybrid closure of multiple muscular ventricular septal defects in a premature infant with novel use of Amplatzer Duct Occluder II – a case report. *Wideochir Inne Tech Malo Inwazyjne*, 2011; 6: 33-36
11. Holzer R, Balzer D, Cao QL et al: Device closure of muscular ventricular septal defects using the Amplatzer muscular ventricular septal defect occluder: immediate and mid-term results of a U.S. registry. *J Am Coll Cardiol*, 2004; 43: 1257-63
12. Waight DJ, Bacha EA, Kahana M et al: Catheter therapy of Swiss cheese ventricular septal defects using the Amplatzer muscular VSD occluder. *Catheter Cardiovasc Interv*, 2002; 55: 355-61
13. Wollenek G, Wyse R, Sullivan I et al: Closure of muscular ventricular septal defects through a left ventriculotomy. *Eur J Cardiothorac Surg*, 1996; 10: 595-98
14. Pedra CA, Pedra SR, Chacur P et al: Perventricular device closure of congenital muscular ventricular septal defects. *Expert Rev Cardiovasc Ther*, 2010; 8: 663-74
15. Gan C, An Q, Tao K et al: How to choose an occluder for two nearby muscular ventricular septal defects? *Ann Thorac Surg*, 2009; 87: 1307-8
16. Holzer R, Marshall A, Kreutzer J et al: Hybrid procedures: adverse events and procedural characteristics—results of a multi-institutional registry. *Congenit Heart Dis*, 2010; 5: 233-42
17. Quansheng X, Qin W, Silin P et al: Transthoracic device closure of ventricular septal defects without cardiopulmonary bypass: experience in infants weighting less than 8 kg. *Eur J Cardiothorac Surg*, 2011; 40: 591-97
18. Michel-Behnke I, Ewert P, Koch A et al: Device closure of ventricular septal defects by hybrid procedures: a multicenter retrospective study. *Catheter Cardiovasc Interv*, 2011; 77: 242-51