

TABLE 2: Exacerbation of urticaria and angioedema following omalizumab therapy

Patient	Age	Gender	Diagnosis	Disease duration	Omalizumab dosage	Reaction
1*	68y	Male	CSU+ angioedema	4 years	5th	
6th	Angioedema	29	25	24	30	
Urticaria+ angioedema	18	20	21	18	22	
2*	49y	Female	CSU+ angioedema	25 years	2nd	Angioedema
3*	33y	Female	CSU+ angioedema	7 years	1st	
2nd	Hypotension and weakness					
Anaphylaxis						
4*	38y	Male	CSU	5 years	1st	Urticaria
Our patient	55y	Male	CSU	16 years	5th	Urticaria+ angioedema

\* Cases in the report of Ertaş *et al.*, 2016.<sup>4</sup>; CSU: Chronic spontaneous urticaria

development of angioedema after the administration of the drug made us think that it was a paradoxical adverse reaction.

Even though we were not able to make the diagnostic tests, exacerbation of the pre-existing urticaria, and development of angioedema in our patient may be related with the excipients in omalizumab such as polysorbate and histidine rather than the active ingredient. Especially polysorbate is one of the well-established sensitizers that may be involved in the development of severe non-immunological reactions. Anaphylactoid reactions with cutaneous symptoms have also previously been described in asthmatic patients being treated with omalizumab.<sup>5</sup> As most commercial preparations include different excipients which are necessary to preserve and stabilize the product, it should be taken into consideration that these excipients may play a role in the development of such adverse reactions and in unsatisfactory responses to the omalizumab therapy. □

## REFERENCES

1. Kaplan AP, Giménez-Arnau AM, Saini SS. Mechanisms of action that contribute to efficacy of omalizumab in chronic spontaneous urticaria. *Allergy*. 2017;72:519-533.
2. Termeer C, Staubach P, Kurzen H, Strömer K, Ostendorf R, Maurer M. Chronic spontaneous urticaria - a management pathway for patients with chronic spontaneous urticaria. *J Dtsch Dermatol Ges*. 2015;13:419-28.
3. Sabroe RA. Failure of omalizumab in cholinergic urticaria. *Clin Exp Dermatol*. 2010;35:e127-9.
4. Ertaş R, Özyurt K, Yıldız S, Ulaş Y, Turasan A, Avcı A. Adverse reaction to omalizumab in patients with chronic urticaria: flare up or ineffectiveness? *Iran J Allergy Asthma Immunol*. 2016;15:82-6.
5. Price KS, Hamilton RG. Anaphylactoid reactions in two patients after omalizumab administration after successful long-term therapy. *Allergy Asthma Proc*. 2007;28:313-9.

**How to cite this article:** Ozbacivan O, Akarsu S, Ilknur T, Fetil E. Urticaria and angioedema as possible reactions of omalizumab. *An Bras Dermatol*. 2018;93(2):304-5.

## Diphencyprone as a therapeutic alternative to exuberant periungual warts\*

Bruno de Castro e Souza<sup>1</sup>  
 Caroline Paías Ribeiro<sup>1</sup>  
 Bethânia Cabral Cavalli Swiczar<sup>1</sup>  
 Mário Cezar Pires<sup>1</sup>

DOI: <http://dx.doi.org/10.1590/abd1806-4841.20187200>

Dear editor,

One of the most frequent diagnoses in a dermatologist's daily practice is viral warts. In many cases, the lesion is self-limiting and frequently resolves without therapeutic intervention – especially in recent cases – with little hyperkeratosis.<sup>1</sup> However, periungual warts, in particular, are frequently associated with high recurrence rates, which poses a therapeutic challenge. Several therapeutic modalities are described in the literature. Some of them include surgical techniques that are sometimes painful and can lead to nail dystrophy. In such cases, physicians can resort to drugs used for immunotherapy with good resolution rates and aesthetic results. In this context, diphencyprone has been studied for some time, with

Received on 13.04.2017.

Approved by the Advisory Board and accepted for publication on 07.08.2017.

\* Work performed at Hospital do Servidor Público Estadual de São Paulo (HSPE - IAMSPE) – São Paulo (SP), Brazil.  
 Financial support: None.  
 Conflict of interests: None.

<sup>1</sup> Dermatology Service at Hospital do Servidor Público Estadual de São Paulo (HSPE - IAMSPE) – São Paulo (SP), Brazil.

MAILING ADDRESS:  
 Bruno de Castro e Souza  
 E-mail: brunocastro1990@hotmail.com

©2018 by Anais Brasileiros de Dermatologia

controversial results.<sup>2</sup> We describe the case of a female patient with difficult-to-treat periungual wart who showed considerable clinical signs of improvement after the use of diphencyprone.

A 13-year-old female patient presented with multiple periungual warts on nine fingers with one year of evolution (Figure 1). She had undergone previous treatment with lactic acid associated with salicylic acid without improvement. Due to the exuberance of the clinical picture, we decided to perform immunotherapy with a 2% solution of diphencyprone on the back skin. The patient returned after two weeks reporting application site reaction (blisters) and a slight improvement of the periungual lesions. After that, we initiated a therapy with a 0.1% solution of diphencyprone applied to the warts, always followed by occlusion for eight hours. The patient evolved with significant improvement of the lesions after three applications in biweekly intervals (Figure 2).

Immunotherapy consists of modulating the immune system, either to activate or to suppress immune responses. Its activation is especially important in the treatment of viral infections. For

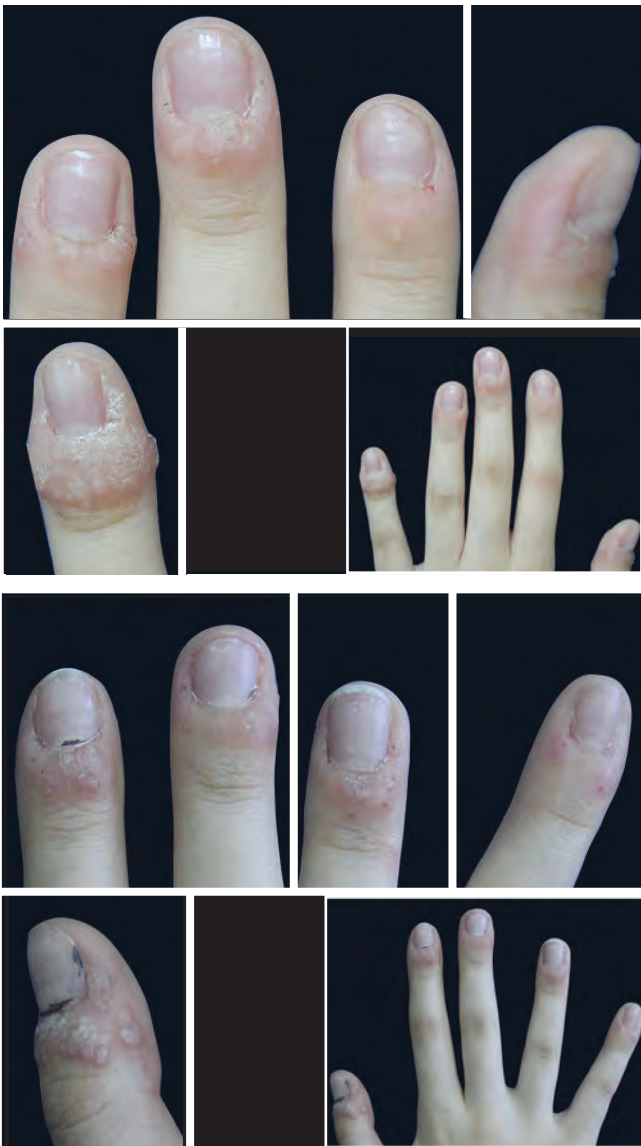


FIGURE 1: Initial presentation with involvement of nine fingers

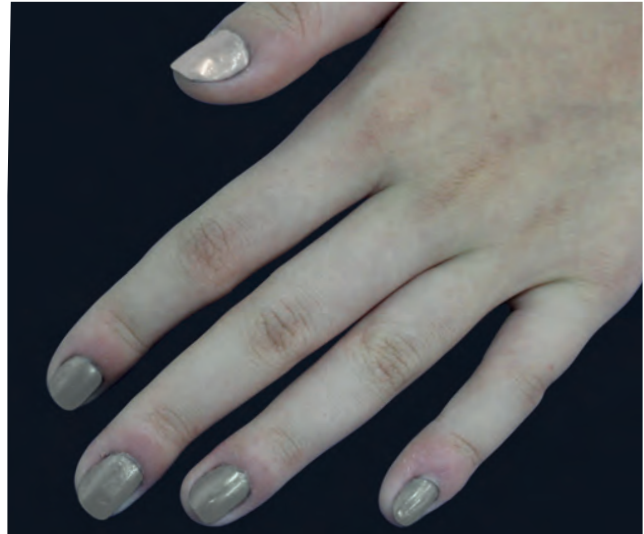

FIGURE 2: Left hand with significant improvement after treatment

some time, immunotherapy has been studied in dermatology, especially in the treatment of recalcitrant viral warts, which includes topical, intralesional, or systemic treatments. It is theorized that the application of topical immunomodulators induces delayed-type or type IV hypersensitivity reactions. As a consequence, Th1 cells release cytokines that cause the recruitment of macrophages and natural killer cells that induce the death of infected keratinocytes.<sup>2</sup> This reaction would justify the reduction of warts after sensitization on the back skin, even without direct application in the periungual region.

Among the topical immunomodulators, diphencyprone is one of the most studied with varying efficacy results revealed by the studies. Cure rates of treatment with diphencyprone vary from 44-88%. In a controlled open study of 170 patients with multiple viral warts (511 lesions), complete resolution of the lesions was seen in 141 patients (82.9%) and in 434 warts (84.8%). Younger patients (<20 years) and localized warts on the hands showed better results.<sup>3</sup> To date, there are no randomized clinical trials comparing diphencyprone with other therapeutic modalities. Choi MH *et al.*, in a non-randomized study of 147 patients, showed a statistical superiority of diphencyprone (93%) after 12 months of follow-up compared to cryotherapy (76%) ( $p > 0.05$ ). These results strengthen the hypothesis that diphencyprone stimulates direct immunity response against HPV.<sup>4</sup> A series of cases specifically made with patients with periungual warts was conducted with 27 patients (66 lesions). Of them, 85% of patients (91% of the warts) achieved complete clearance. Warts located in the proximal nail fold showed a 95% higher success rate, compared to 87% and 86% for lateral fold and hyponychium, respectively.<sup>5</sup>

Although diphencyprone finds a theoretical basis in the international literature for the treatment of periungual and recalcitrant viral warts, we found no reports or discussions in the Brazilian literature. Our patient experienced previous therapeutic failure, showing excellent clinical results with diphencyprone. We call attention to this effective and safe drug that is rarely considered as an alternative in the therapeutic arsenal of the dermatologist. □

## REFERENCES

1. Ockenfels HM. Therapeutic management of cutaneous and genital warts. *J Dtsch Dermatol Ges.* 2016;14:892-9.
2. Word AP, Nezafati KA, Cruz PD Jr. Treatment of Warts With Contact Allergens. *Dermatitis.* 2015;26:32-7.
3. Suh DW, Lew BL, Sim WY. Investigations of the efficacy of diphenylcyclopropenone immunotherapy for the treatment of warts. *Int J Dermatol.* 2014;53:e567-71.
4. Choi MH, Seo SH, Kim IH, Son SW. Comparative study on the sustained efficacy of diphenylcyclopropenone immunotherapy versus cryotherapy in viral warts. *Pediatr Dermatol.* 2008;25:398-9.
5. Choi Y, Kim DH, Jin SY, Lee AY, Lee SH. Topical immunotherapy with diphenylcyclopropenone is effective and preferred in the treatment of periungual warts. *Ann Dermatol.* 2013;25:434-9.

**How to cite this article:** Souza BC, Ribeiro CP, Swiczar BCC, Pires MC. Diphencyprone as a therapeutic alternative to exuberant periungual warts. *An Bras Dermatol.* 2018;93(2):305-7.



## Metastatic pleomorphic dermal sarcoma: an uncommon skin tumour\*

Georgios Kravvas<sup>1</sup>  
David Veitch<sup>1</sup>  
Ian Thomas Logan<sup>1</sup>  
Conal Martin Perrett<sup>1</sup>

DOI: <http://dx.doi.org/10.1590/abd1806-4841.20187228>

A 69-year-old Caucasian male was referred to our department with a 3-month history of an enlarging, asymptomatic nodule on his forehead. Examination revealed a 15mm, shiny, erythematous nodule with no associated lymphadenopathy. Further examination was unremarkable. Excision biopsy with a 4mm peripheral surgical margin revealed a dermal-based atypical spindle cell tumour extending from the dermo-epidermal junction to the deep subcutaneous adipose tissue. There was no evidence of tumour necrosis, lymphovascular invasion or perineural infiltration. No expression of cytokeratins, S100, desmin, or CD34 immunohistochemical markers was found, but there was positive expression of CD10. The his-

tological margins were clear by 2mm peripherally and 1.2mm deep. Histopathological and immunohistochemical findings were consistent with the diagnosis of pleomorphic dermal sarcoma (Figure 1). The patient was followed up 3-monthly in a dedicated cutaneous sarcoma clinic. Six months after excision of the primary lesion, a new 5mm papule appeared on the excision scar (Figure 2). Repeat excision revealed recurrent pleomorphic dermal sarcoma with clear margins. The multidisciplinary team consensus was to treat this further with local adjuvant radiotherapy following a staging CT scan. At 7 months, staging CT revealed a new discrete nodule in the left lower lobe of the lung. CT-guided biopsy confirmed a CD10 positive spindle cell tumour consistent with metastatic pleomorphic dermal sarcoma. The patient subsequently died from pneumonia at 11 months following diagnosis, having been too unwell for palliative chemotherapy.

Pleomorphic dermal sarcoma (PDS), previously known as superficial malignant fibrous histiocytoma, or undifferentiated pleomorphic sarcoma of skin, is a rare dermal-based spindle cell tu-

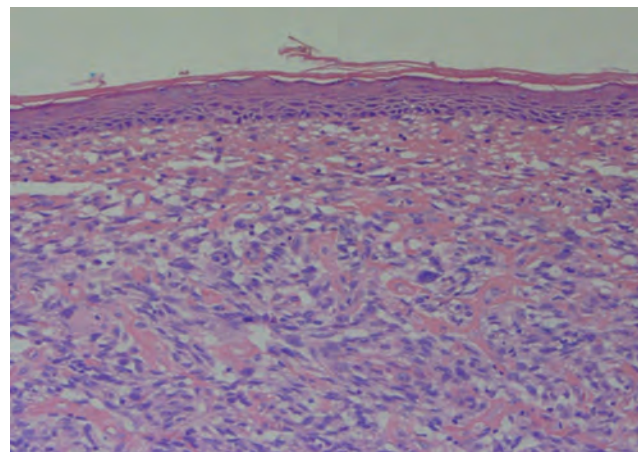


FIGURE 1: A dermal-based tumour comprised of intersecting fascicles of spindle cells with clear cytoplasm and moderate nuclear atypia (Hematoxylin & eosin, X100)

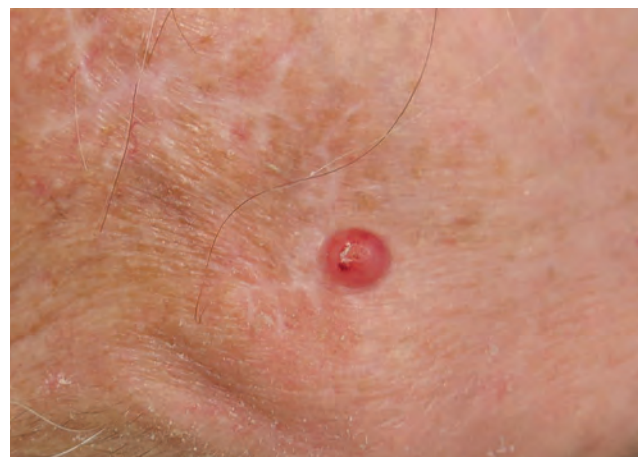

FIGURE 2: Shiny, erythematous papule with a central depression on the patient's forehead

Received on 01.05.2017.

Approved by the Advisory Board and accepted for publication on 01.10.2017.

\* Work performed at the Department of Dermatology, University College London Hospitals NHS Foundation Trust - London, United Kingdom.

Financial support: None.

Conflict of interest: None.

<sup>1</sup> Department of Dermatology, University College London Hospitals - London, United Kingdom.

MAILING ADDRESS:

Georgios Kravvas  
E-mail: [kravvas@hotmail.com](mailto:kravvas@hotmail.com)

©2018 by Anais Brasileiros de Dermatologia

