

MECHANICAL SUTURE IN RECTAL CANCER

CORNEL DRAGOS CHEREGI¹, IOAN SIMON¹, OVIDIU FABIAN¹,
ADRIAN MAGHIAR²

¹Department of Surgery, Railway Company University, Cluj-Napoca, Romania

²Department of Surgery, Pelican Hospital, Oradea, Romania

Abstract

Background and aims. Colorectal cancer is one of the most frequent digestive malignancies, being the third cause of death by cancer, despite early diagnosis and therapeutic progress made over the past years. Standard treatment in these patients is to preserve the anal sphincter with restoration of intestinal function by mechanical colorectal anastomosis or coloanal anastomosis, and to maintain genitourinary function by preservation of hypogastric nerves.

Methods. In order to emphasize the importance of this surgical technique in the Fourth Surgical Clinic of the CF Clinical Hospital Cluj-Napoca, we conducted a prospective observational interventional study over a 3-year period (2013-2016) in 165 patients hospitalized for rectal and rectosigmoid adenocarcinoma in various disease stages, who underwent Dixon surgery using the two techniques of manual and mechanical end-to-end anastomosis. For mechanical anastomosis, we used Covidien and Panther circular staplers. The patients were assigned to two groups, group A in which Dixon surgery with manual end-to-end anastomosis was performed (116 patients), and group B in which Dixon surgery with mechanical end-to-end anastomosis was carried out (49 patients).

Results. Mechanical anastomosis allowed to restore intestinal continuity following low anterior resection in 21 patients with lower rectal adenocarcinoma compared to 2 patients in whom intestinal continuity was restored by manual anastomosis, with a statistically significant difference ($p < 0.000001$). The double-row mechanical suture technique is associated with a reduced duration of surgery (121.67 minutes for Dixon surgery with mechanical anastomosis, compared to 165.931 minutes for Dixon surgery with manual anastomosis, $p < 0.0001$).

Conclusion. The use of circular transanal staplers facilitates end-to-end anastomosis by double-row mechanical suture, allowing to perform low anterior resection in situations when the restoration of intestinal continuity by manual anastomosis is technically not possible, with the aim to preserve the anal sphincter, to restore intestinal function and maintain genitourinary function through preservation of hypogastric nerves.

Keywords: rectal cancer, low anterior resection, circular stapler, mechanical anastomosis

Background and aim

Rectal cancer is a disease in which cancer cells develop in rectal tissues. Regarding histopathological types, adenocarcinoma occurs in 98% of colon and rectal cancer cases. Other types of rectal cancer are more rarely

found: lymphoma (1.3%), carcinoma (0.4%) and sarcoma (0.3%). When squamous carcinomatous cells develop in the transition area between the rectum and the anus, anal carcinoma occurs. Very rare cases of squamous cell carcinoma of the rectum have been reported [1,2].

The incidence of colorectal cancer has dramatically increased as a result of economic and industrial development. Colorectal cancer is currently the third cause

Manuscript received: 01.03.2017

Received in revised form: 19.06.2017

Accepted: 26.06.2017

Address for correspondence: cornel.cheregi@yahoo.com

of death by cancer, both in men and women in the United States [1,3].

About 20% of colon cancer cases develop in the cecum, 20% in the rectum and 10% at the rectosigmoid junction. Approximately 25% of colon cancer cases develop in the sigmoid colon [1].

The incidence and mortality rates of colon and rectal cancer have decreased over the past decades, from 66.3 per 100,000 inhabitants in 1985 to 45.5 in 2006 [3]. The accelerated decrease rate in the period 1998-2006 (up to 3% per year in men and 2.2% per year in women) is partly due to increased screening, allowing the detection and removal of colorectal polyps before their progression to cancer. The risk to develop a colorectal malignancy is about 6% in the general population in the USA.

In Romania, the incidence of colorectal cancer is continuously increasing, from 8.78/10,000 inhabitants in 1998 to 23.79/10,000 inhabitants in 2008 [4].

When colorectal cancer cases are detected at an early stage and localized, the 5-year survival rate is 90% [3]. The mortality rate of colorectal cancer was higher in men (18.6 per 100,000) than in women (13.1 per 100,000) in the period 2008-2012 [5]. The incidence of colorectal cancer starts to increase after the age of 35 and rises at an accelerated rate after the age of 50, up to the seventh decade of life. More than 90% of colon cancer cases occur after 50 years of age. However, cases in young children and adolescents have also been reported [1]. The incidence rate of colorectal cancer in adults aged less than 50 years increased by 1.8% per year from 2007 to 2011 [3].

The surgical definition of the rectum differs from its anatomical definition; surgeons consider the rectum to begin at the level of the sacral promontory, while anatomists consider it to begin at the level of the third sacral vertebra. Consequently, the measured length of the rectum varies between 12 cm and 15 cm. The rectum is different from the colon in that its outer layer is formed by longitudinal muscles. The rectum contains three folds, known as Houston's valves: the superior valve (at 10-12 cm) and the inferior valve (at 4-7 cm), situated on the left side, and the middle valve (at 8-10 cm), on the right side.

"National Comprehensive Cancer Network" guidelines define the location of rectal cancer at 12 cm from the anal margin by rigid proctoscopy. However, surgery indicates its location at 10.1-15 cm from the anal margin [6].

The standard approach of patients with rectal cancer is to preserve the anal sphincter with restoration of intestinal function by mechanical colorectal anastomosis or coloanal anastomosis, and to maintain genitourinary function by preservation of hypogastric nerves [7,8]. The solutions for restoring digestive continuity after resection of the middle rectum are dictated by the length of the remaining stump. In case of a sufficient stump, low anterior resection (Dixon surgery) is performed. In case of a short stump, there are

two options, either low anterior resection, which is more difficult and risky in this situation (particularly in obese patients or patients with a narrow pelvis), or coloanal anastomosis – the two procedures being alternatives to rectal amputation [9]. The development of transanal circular staplers has considerably facilitated this type of anastomosis, allowing to perform anterior resection of the rectum in 15-20% of the cases where rectal amputation would have been applied. Very low colorectal anastomosis, close to the anal orifice, is associated in 40% of cases with intermittent loss of feces, incontinence and urgent stools in up to 50% of cases [10], due to loss of the reservoir function of the rectum. The most widely accepted solution is to create a new J-shaped reservoir for the improvement of functional results [8,11,12].

Methods

Low anterior resection (Dixon surgery) is generally performed for lesions situated in the middle and upper third of the rectum and, occasionally, for lower third lesions. Given that this is a major surgery, patients should be in good health, without pre-existing sphincter problems or evidence of local disease extended to the pelvis.

Patients will not have a permanent colostomy, but they should be informed that a temporary colostomy or ileostomy may be required. After such an operation, patients should be aware that mild sphincter dysfunction may occur. Other disorders include transient urinary dysfunction secondary to detrusor muscle weakness, which occurs in 3-15% of all patients, and sexual dysfunction, including retrograde ejaculation and impotence. In the past, this occurred in 5-70% of men, but recent reports indicate a lower incidence [13].

Surgery involves complete mobilization of the rectum, sigmoid colon and splenic flexure, and consists of total *mesorectal excision* [13,14,15]. This is accompanied by a lower local recurrence rate (4%) compared to transanal excision (20%), but is associated with a higher anastomotic fistula rate (11%). For this reason, total mesorectal excision may not be required for lesions in the upper third of the rectum.

According to a study conducted by Maurer et al., the introduction of total mesorectal excision has resulted in an impressive reduction of the local recurrence rate and an improvement of the survival rate in patients without systemic diseases [16].

Rectal excision should follow 4 steps: removal of the mesorectum, separation of the layers of Denonvilliers' fascia, dissection of lateral ligaments and middle rectal arteries when these are present, and preservation of pelvic nerve plexuses.

The distal resection margin varies depending on the site of the lesion. A distal margin 2 cm from the lesion should be obtained. For distal rectal tumors, less than 5 cm from the anal margin, the minimum acceptable distal

resection limit is 1 cm. Distal intramural spread beyond 1 cm is associated with aggressive behavior or advanced stages of the tumor (Table I) [14,17].

Table I. Minimum acceptable proximal and distal resection margins.

Resection margins	Proximal resection margin (cm)	Distal resection margin (cm)
Ideal margins	5 or > 5	2 or > 2
Minimum acceptable margins	2 or >2	1 or > 1

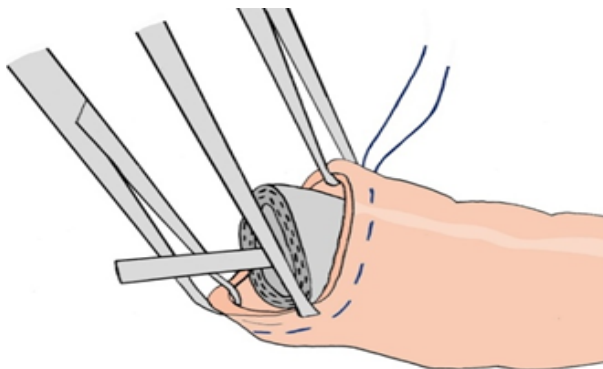
The procedure is performed with the patient in a modified lithotomy position, with the buttocks slightly over the edge of the operating table to allow easy access to the rectum [16]. A circular stapler is used to perform end-to-end anastomosis. This consists of a head – a mushroom-shaped “anvil” (cap and stem), and a shaft. The stem serves for contact with the stapler shaft and allows to maintain correct contact between the two digestive tract segments to be anastomosed. The circular stapler acts by physical apposition, synchronous compression, double-row mechanical suture and at the same time, removal of excess material of the intestinal ends to be anastomosed. The final result of using this type of mechanical stapler can be checked by examining the intestinal rings that are

left in the stapler following anastomosis. If these rings are continuous, anastomosis has been correctly performed.

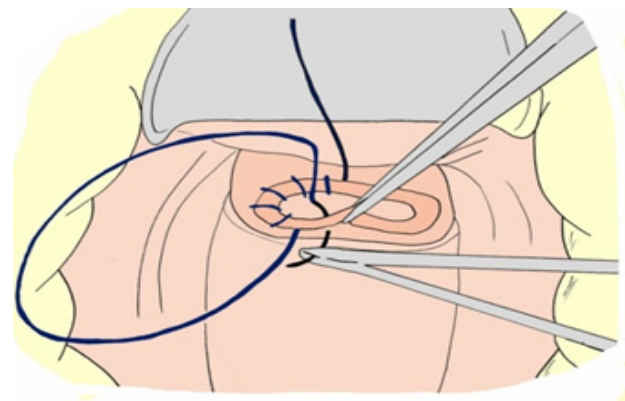
The rectum is dissected distally to the tumor. The cap of the anvil is introduced into the lumen of the proximal intestinal segment to be anastomosed, which is closed with a purse-string suture around the anvil stem (Figure 1).

The distal intestinal segment must be closed in the form of a glove finger by enterorrhaphy. The shaft of the circular stapler is inserted into the lumen of the distal intestinal segment to be anastomosed through the rectum. The two parts of the stapler are joined by extension of the trocar (usually by rotating a knob on the handle), which is connected to the stem of the anvil. At this point, the shaft of the stapler fires two rows of staples, which join the two intestinal segments. At the same stage, excess tissue is cut off by extension of a circular knife from the stapler shaft, which thus ensures communication between the lumens of the two segments to be anastomosed (Figure 2).

After firing the stapler, this can be extracted, and the excess tissue rings that are left between the anvil and the stapler shaft can be examined for mucosal continuity, to make sure that the anastomosis has been correctly performed [18] (Figures 3-4).

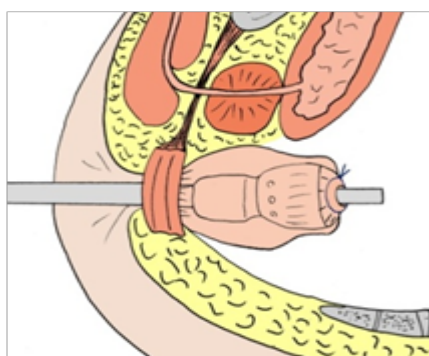


a

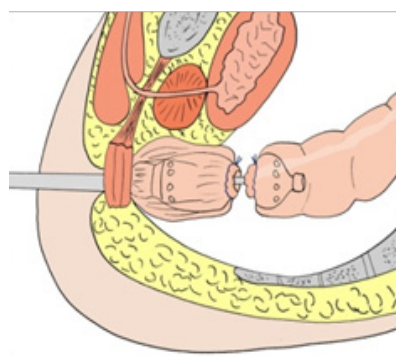


b

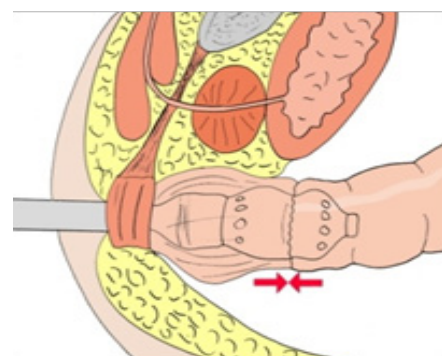
Figure 1. a) Insertion of the anvil cap into the lumen of one of the ends to be anastomosed; b) View after purse-string closure of the intestinal end around the anvil stem.



a



b



c

Figure 2. a) Insertion of the circular stapler shaft into the distal segment to be anastomosed, previously closed in the form of a glove finger by enterorrhaphy; b) Extension of the trocar that serves for connection of the anvil; c) Connection of the two parts of the circular stapler.

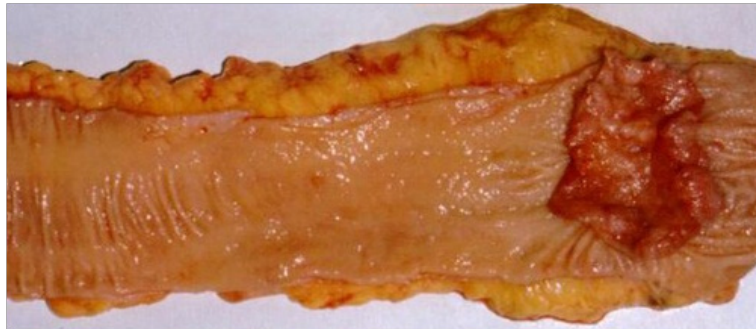


Figure 3. Ulcerated rectal cancer – resection specimen.

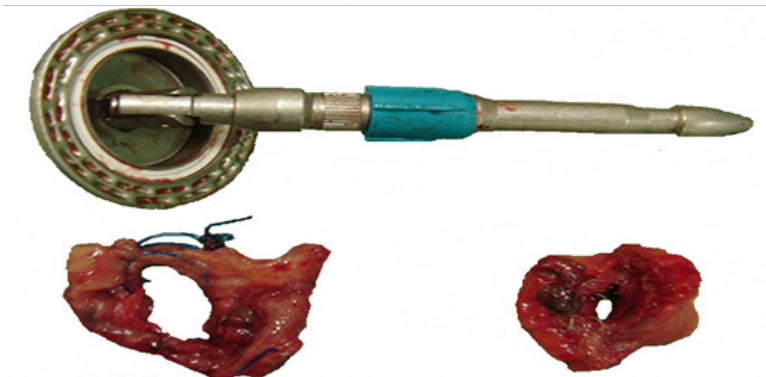


Figure 4. The anvil used for mechanical anastomosis and the tissue fragments removed by stapling.

In order to emphasize the importance of this surgical technique in the Fourth Surgical Clinic of the CF Clinical Hospital Cluj-Napoca, we conducted a prospective observational interventional study over a 3-year period (2013-2016) in 165 patients hospitalized for rectal and rectosigmoid adenocarcinoma in various disease stages, who underwent Dixon surgery using the two techniques of manual and mechanical end-to-end anastomosis. For mechanical anastomosis, we used Covidien and Panther circular staplers. The patients were assigned to two groups, group A in which Dixon surgery with manual end-to-end anastomosis was performed (116 patients), and group B in which Dixon surgery with mechanical end-to-end anastomosis was carried out (49 patients). A number of parameters were monitored in the studied group: demographic data (age, sex), type of suture - manual versus mechanical - of the anastomosis, distance of rectal resection from the anal orifice, performance of temporary ileostomy

or cecostomy, development of early and late postoperative complications, operative time, mortality, duration of hospitalization, cost-efficiency ratio.

All information was stored and processed using the Microsoft® Excel® 2010 software (Microsoft® Corporation, SUA), representing the database of the statistical study.

The statistical analysis methods used were Fisher's exact test, Chi-square test, Comparison of means test (t-test) and Comparison of proportions test, using the MedCalc® medical statistics software version 12.2.1.0 (MedCalc® Software, Mariakerke, Belgium). A p value <0.05 proved a statistically significant difference between the studied groups.

The study was approved by the Ethics Committee, and all patients were asked to complete and sign an informed consent form.

Results

The analysis of demographic data evidences a significantly increased incidence of the disease in male patients (105 male patients/60 female patients, $p=0.000001$). Our study shows a significantly increased incidence of rectal and rectosigmoid adenocarcinoma between the fourth and eighth decades of life both in the total group and comparatively between the two groups ($p<0.0001$) (Table II).

Regarding the distance at which tumor resection was performed in relation to the anal orifice in the entire group

of patients, there was a significant difference between the resection of the upper rectum and mesorectum compared to the resection of the lower rectum ($p<0.000001$), which shows that tumor location was significantly higher in 142 patients compared to 23 patients, in whom the tumor invaded the lower rectum (Table III).

In our study, tumor resection in the lower 1/3 of the rectum was performed in 43% of cases by mechanical anastomosis (21 patients), compared to 1.72% of cases by manual anastomosis (2 patients), with a statistically significant difference ($p<0.000001$) (Table III).

Table II. Demographic and therapeutic data of study patients.

	Group A (n = 116)	Group B (n = 49)	p†
Sex M/F	105/60	p = 0.000001*	
Men	70	35	p = 0.216058*
Women	46	14	
Age (years)			
20-40	1	2	p < 0.0001**
41-60	35	17	
61-80	78	30	
81-85	2	0	
Operative time	138-198 (165.931)	88-148 (121.67)	p < 0.0001*
Ileostomy	3	19	p < 0.000001*
No ileostomy	113	30	p < 0.000001*
Postoperative complications			
Low-flow fistula	15 (1 in the lower 1/3, 3 in the middle 1/3, and 11 in the upper 1/3 of the rectum)	2 (lower 1/3 of the rectum)	p = 0.100292*
High-flow fistula	1 (upper 1/3 of the rectum)	2 (middle 1/3 of the rectum)	p = 0.210629*
Fistula	16 (13.8%)	4 (8.16%)	p = 0.4514***
Parietal wound hematoma	4	1	p = 1.000000
Abdominal wound seroma	5	1	p = 0.670624
Wound suppuration	7	1	p = 0.436762
Other complications			
Death from pulmonary embolism	0	1	p = 0.296970*
Adhesive intestinal obstruction	0	1	p = 0.296970*
UDH	1	0	p = 1.000000*
Bladder injury - cystorrhaphy	1	0	p = 1.000000*
Superficial thrombophlebitis	1	0	p = 1.000000*
No other complications	97	44	p = 0.345690*

*Fisher's exact test ** Chi-square test ***Comparison of proportions test

†p < 0.05 proves a statistically significant difference between the studied groups

Table III. The distance at which tumor resection was performed in relation to the anal orifice in the entire group of patients.

Location of tumor resection	Group A (n = 116)	Group B (n = 49)	Total group (n = 165)	p†	p†
Lower 1/3 (4-7 cm from the AO)	2	21	23	p < 0.000001*	p < 0.000001*
Middle 1/3 (8-10 cm from the AO)	24	14	142		p = 0.313101*
Upper 1/3 (11-20 cm from the AO)	90	14			p < 0.000001*

*Fisher's exact test

**Chi-square test

***Comparison of proportions test

†p < 0.05 proves a statistically significant difference between the studied groups

To protect anastomosis in the lower third of the rectum, temporary ileostomy was performed in 19 patients with mechanical anastomosis and 3 patients with manual anastomosis, adenocarcinoma being situated in the lower third of the rectum, with a significant difference between the groups ($p < 0.000001$). Of the 19 patients with mechanical anastomosis, 7 were previously treated with radiochemotherapy, 3 in stage I, 1 in stage II A, 1 in stage III A, and 2 in stage III B of the disease.

In the current study, the fistulization rate of mechanical anastomosis was 8.16% (4 cases, of which 2 with low-flow fistulas and 2 with high-flow fistulas), compared to manual anastomosis, 13.8% (15 low-flow cases and 1 high-flow case), without statistical significance between the groups ($p = 0.435525$). The 2 low-flow fistulas occurred as early postoperative complications after mechanical anastomosis of the lower third of the rectum, and the 2 high-flow fistulas developed following mechanical anastomosis of the middle third of the rectum. In the case of Dixon surgery with manual anastomosis, 1 low-flow fistula appeared as an early postoperative complication after manual anastomosis of the lower third of the rectum, 3 low-flow fistulas after manual anastomosis of the middle third of the rectum, and 11 low-flow fistulas and 1 high-flow fistula after manual anastomosis of the upper third of the rectum (Table II).

Other postoperative complications that developed in both groups of patients were parietal wound hematoma, abdominal wound seroma, wound suppuration, but without statistical significance between the groups. Systemic complications included pulmonary embolism in a patient with mechanical anastomosis, resulting in the patient's death, while among patients with manual anastomosis, one had upper digestive hemorrhage, one had bladder injury solved by cystorrhaphy, and one patient developed superficial thrombophlebitis (Table II). There was no anastomotic stenosis or disease recurrence in the studied cases.

Regarding the operative time, the data provided by this study show a statistically significant difference between the two groups, 88-148 (121.67) minutes for

Dixon surgery with mechanical anastomosis, compared to 138-198 (165.931) minutes for Dixon surgery with manual anastomosis ($p < 0.0001$) (Table II).

However, the high cost of staplers required for mechanical anastomosis is a disadvantage that limits the use of this method. The cost of a Covidien circular stapler is 550 euro, and that of a Panther circular stapler is 350 euro.

Discussion

Literature data confirm the increase in the incidence of colorectal cancer after the age of 35, and its rapid increase after 50 years of age, until the seventh decade of life. More than 90% of colon cancer cases occur after the age of 50 [19,20]. This finding is also present in our study.

The solution for the restoration of digestive continuity is dictated by the length of the residual stump. The development of circular transanal staplers has considerably facilitated this type of anastomosis, allowing for anterior rectal resection in 15-20% of cases where rectal amputation would have been performed [10]. In other words, the smaller the distance from the anus, the more difficult to perform is manual anastomosis, particularly in the case of adenocarcinomas located in the lower third of the rectum.

Studies show that the rate of mechanical anastomotic dehiscence varies between 3-11% for anastomosis in the middle and upper third of the rectum, and can reach 20% for anastomosis in the lower third. For this reason, some surgeons choose to protect anastomoses of the lower third of the rectum by creating a temporary deviation stoma. This is particularly important when patients have received preoperative radiotherapy [13].

The main disadvantage is the high cost of staplers. Compared to end-to-end anastomoses performed by manual suture, studies have shown that there are no differences regarding postoperative complications (anastomotic fistulas, strictures) or the recurrence rate. A relatively recent option of using mechanic suture devices with a goal in digestive continuity reestablishment after removal of the intestine segment that carries the tumor is offering an

increased degree of safety as well as a faster postoperative recovery [21,22,23,24,25,26,27].

Conclusions

Rectal cancer continues to create problems regarding the increased proportion of advanced cases, being, along with colon cancer, the third cause of death, as well as regarding the technical surgical solutions required by each individual case. A significantly increased incidence of the disease is found in male patients, particularly between the fourth and eighth decades of life ($p < 0.0001$), with a predominant location in the upper and middle third of the rectum ($p < 0.000001$).

Mechanical anastomosis allowed to restore intestinal continuity following low anterior resection in 21 patients with lower rectal adenocarcinoma compared to 2 patients in whom intestinal continuity was restored by manual anastomosis, with a statistically significant difference ($p < 0.000001$).

The double-row mechanical suture technique is associated with a reduced duration of surgery (121.67 minutes for Dixon surgery with mechanical anastomosis compared to 165.931 minutes for Dixon surgery with manual anastomosis, $p < 0.0001$).

An important role in preventing anastomotic dehiscence is played by temporary ileostomy. All patients with tumors located in the lower third of the rectum who did not undergo temporary ileostomy subsequently developed anastomotic dehiscence, without a significant difference between the groups.

The rates of postoperative complications (anastomotic dehiscence, parietal wound hematoma, wound seroma, wound suppuration) are not significantly different between the two surgical anastomosis techniques, mechanical and manual, for reconstruction of intestinal continuity.

The high cost of staplers continues to be the main disadvantage of using mechanical anastomosis.

References

- Giovannucci E, Wu K. Cancers of the colon and rectum. Schottenfeld D, Fraumeni J, eds. *Cancer. Epidemiology and Prevention*. 3rd ed. Oxford University Press; 2006. Chapter IV: p. 42.
- Anagnostopoulos G, Sakorafas GH, Kostopoulos P, Grigoriadis K, Pavlakis G, Margantinis G, et al. Squamous cell carcinoma of the rectum: a case report and review of the literature. *Eur J Cancer Care (Engl)*. 2005;14(1):70-74.
- American Cancer Society. *Cancer Facts & Figures 2016*. American Cancer Society. 2016; p. 8 Available from: <https://www.cancer.org/content/dam/cancer-org/research/cancer-facts-and-statistics/annual-cancer-facts-and-figures/2016/estimated-number-of-new-cancer-cases-and-deaths-by-sex-us-2016.pdf>
- Jinescu G, Murgu C, Voicu C, Andrei S, Rădoi M, Chidiosan C et al. Tumori colonice perforate – atitudine în urgență [Perforated colic tumors – management in emergency]. *Chirurgia*. 2009;104(suppl. 1):134-135.
- Surveillance, Epidemiology, and End Results Program. SEER Stat Fact Sheets: Colon and Rectum Cancer. National Cancer Institute. 2015. Available from: URL: <http://seer.cancer.gov/statfacts/html/colorect.html>.
- Kapiteijn E, Marijnen CA, Nagtegaal ID, Putter H, Steup WH, Wiggers T, et al. Preoperative radiotherapy combined with total mesorectal excision for resectable rectal cancer. *N Engl J Med*. 2001;345(9):638-646.
- Baxter NN, Garcia-Aguilar J. Organ preservation for rectal cancer. *J Clin Oncol*. 2007;25(8):1014-1020.
- McNamara DA, Parc R. Methods and results of sphincter-preserving surgery for rectal cancer. *Cancer Control*. 2003;10:212-218.
- Parks AG, Percy JP. Resection and sutured colo-anal anastomosis for rectal carcinoma. *Br J Surg*. 1982;69:301-304.
- Nicholls RJ, Lubowski DZ, Donaldson DR. Comparison of colonic reservoir and straight colo-anal reconstruction after rectal excision. *Br J Surg*. 1988;75:318-320.
- Parc R, Tiret E, Frileux P, Maszkowski E, Loygue J. Resection and colo-anal anastomosis with colonic reservoir for rectal carcinoma. *Br J Surg*. 1986;73:139-141.
- Lazorthes F, Fages P, Chiotasso P, Lemozy J, Bloom E. Resection of the rectum with construction of a colonic reservoir and colo-anal anastomosis for carcinoma of the rectum. *Br J Surg*. 1986;73:136-138.
- van Helmond J, Beart RW. *Cancer of the rectum: Operative management and adjuvant therapy. Current Therapy in Colon and Rectal Surgery*. 2nd ed. Philadelphia, Pa: Mosby; 2005.
- Nelson H, Petrelli N, Carlin A, Couture J, Fleshman J, Guillem J, et al. Guidelines 2000 for colon and rectal cancer surgery. *J Natl Cancer Inst*. 2001;93(8):583-596.
- Bullard KM, Rothenberger DA. Colon, rectum, and anus. Schwartz SE, ed. *Principles of Surgery*. 8th ed. New York, NY: McGraw Hill; 2005. Chapter 29.
- Maurer CA, Renzulli P, Kull C, Käser SA, Mazzucchelli L, Ulrich A, et al. The impact of the introduction of total mesorectal excision on local recurrence rate and survival in rectal cancer: long-term results. *Ann Surg Oncol*. 2011;18(7):1899-1906.
- Heald RJ, Husband EM, Ryall RD. The mesorectum in rectal cancer surgery--the clue to pelvic recurrence? *Br J Surg*. 1982;69:613-616.
- The Ethicon Intraluminal Stapler: Optimal Device Performance Guide. 2016. Available from: URL:<http://www.ethicon.com/healthcare-professionals/products/staplers/circular/circular-intraluminal#!description-and-specs>.
- Giovannucci E, Wu K. Cancers of the colon and rectum. Schottenfeld D, Fraumeni J, eds. *Cancer. Epidemiology and Prevention*. 3rd ed. Oxford University Press; 2006.
- American Cancer Society. *Cancer Facts & Figures 2016*. American Cancer Society. Available from: <https://www.cancer.org/content/dam/cancer-org/research/cancer-facts-and-statistics/annual-cancer-facts-and-figures/2016/estimated-number-of-new-cancer-cases-and-deaths-by-sex-us-2016.pdf>
- Mastalier B. Cancerul de rect [Rectal cancer]. București: Editura Universitară Carol Davila; 2011, 53-60.
- Mastalier B, Botezatu C. The stapled anastomoses in rectal cancer surgery - modern alternative for bowel reconstruction. *Romanian statistical review - supliment trimestrul II*. 2012;66-71.
- Petz von A. Zur Technik der Magenresektion. Ein neuer Magen Darmnehhapparat. *Zentralbl Chir*. 1924,51:179.

24. Beuran M, Chiotoroiu Al. L, Chilie A, Morteau S, Vartic M, Avram M, et al. Anastomozele manuale versus anastomozele mecanice în cancerul colo-rectal complicat - studiu retrospectiv [Manual versus mechanical anastomoses in complicated colorectal cancer – a retrospective study]. *Chirurgia (Buc.)*. 2010;105(5):645-651.
25. Funariu Gh, Pop CE, Ionescu C, Scurtu R, Dindelegan G. Anastomoze mecanice în chirurgia rectocolică (Mechanical anastomoses in rectocolic surgery]. *Chirurgia (Buc.)*. 2001;96(2):213-219.
26. Fain SN, Patin CS, Morgenstern L. Use of a mechanical suturing apparatus in low colorectal anastomosis. *Arch Surg*. 1975;110(9):1079-1082.
27. Varma JS, Chan AC, Li MK, Li AK. Low anterior resection of the rectum using a double stapling technique. *Br J Surg*. 1990;77(8):888–890.