

Pseudoachalasia: a diagnostic challenge

Nader Roushan¹, Abolfazl Zolfaghari², Mehrnaz Asadi³, Reza Taslimi⁴

Received: 21 May 2013

Accepted: 12 March 2014

Published: 12 July 2014

Abstract

Here, we present a case of a 78-year-old man that underwent gastrointestinal endoscopy because of one-month history of dysphagia to liquids and solid foods with accompanying weight loss. On endoscopy, there was distal esophageal stenosis. Multiple biopsies were obtained. Histologic examination of the samples revealed normal tissue. The stenosis was treated by dilatation and abdomino pelvic computed tomography scanning was performed to search for an underlying malignant lesion that showed a mass adjacent to distal esophagus. We did endosonography-guided fine needle aspiration of the mass. It was a squamous cell carcinoma (SCC). Malignancy is a challenging diagnosis in patients with dysphagia and near normal endoscopy. To our knowledge, there are a few reports of SCC to cause it.

Keywords: Achalasia, Dysphagia.

Cite this article as: Roushan N, Zolfaghari A, Asadi M, Taslimi R. Pseudoachalasia: a diagnostic challenge. *Med J Islam Repub Iran* 2014 (12 July). Vol. 28:54.

Introduction

Achalasia is a primary esophageal motility disorder presenting with dysphagia to liquids and solid foods. It is usually diagnosed using barium swallow study and manometry. Barium study shows narrowing of esophagogastric junction (EGJ) while manometry shows decreased or absent distal esophageal peristalsis with increased lower esophageal sphincter (LES) pressure and impaired LES relaxation with deglutition. Esophagus appears to be normal on endoscopic examination (1).

Pseudoachalasia is characterised by achalasia-like symptoms caused by secondary etiologies. Clinical, radiologic and endoscopic findings resemble those of achalasia but treatment and prognosis are different in these conditions. Therefore, discriminating between these two disorders is important (1-5).

Case report

A 78-years-old man was admitted to our hospital due to 10-days history of intractable postprandial vomiting. He complained of progressive dysphagia presented initially to solid foods and then to liquids for a month. During this time, he had 15 kilogram weight loss.

He smoked for decades and noticed occasional productive cough with no relevant diagnostic work-up. He had history of hypothyroidism after being treated by radio-iodine for the primary hyperthyroidism when he was 60-years-old. However, at the time of presentation, he was in euthyroid state.

On clinical examination, he appeared ill and dehydrated. Except for bilateral temporal wasting, the whole clinical examination was normal. Tests of blood and elec-

1. (Corresponding author) Assistant Professor, Department of Internal Medicine, Division of Gastroenterology, Imam Khomeini Hospital, Tehran University of Medical Sciences, Tehran, Iran. nroshan@tums.ac.ir

2. Fellowship of Gastroenterology, Department of Internal Medicine, Division of Gastroenterology, Tehran University of Medical Sciences, Tehran, Iran. abaszoalfaghari1354@yahoo.com

3. Assistant Professor, Department of Internal Medicine, Imam Khomeini Hospital, Tehran University of Medical Sciences, Tehran, Iran. mehrnazasadi@yahoo.com

4. Assistant Professor, Department of Internal Medicine, Division of Gastroenterology, Tehran University of Medical Sciences, Tehran, Iran. rtaslimi@tums.ac.ir

trolytes showed white blood cell (WBC): 9,700 / μ l, Hb: 11.2 g/dl, MCV: 86/fl: Platelet count; 283,000 / μ l: ESR; 125 mm/ hour, Na: 137 and K: 3.6 meq/ l. Renal and liver function assays were normal as serum protein electrophoresis study.

There was no evidence of hepatobiliary or splenic abnormality on abdominal sonography.

On upper endoscopy, esophagus appeared to be diffusely erythematous with multiple white plaques compatible with candidiasis; due to tight LES stenosis, attempts to pass the endoscope into stomach was futile. After dilatation with the Savary dilators, all parts of stomach were visualized that seemed to have normal mucosa. Multiple biopsies were obtained from distal esophagus and proximal stomach (both side of LES); but histologic examination revealed normal mucosa.

Abdominal and chest CT scan showed an

abnormal soft tissue mass around distal esophagus with a solitary 2 cm pulmonary nodule (SPN) near right lung hilum. His medical records were unavailable to evaluate the growth rate of SPN.

On endosonography (EUS), a 42 mm hypoechoic mass was seen at LES extending beneath the mucosa, involving all layers of esophageal wall albeit without any regional lymph node abnormality. Fine needle aspiration (FNA) guided by EUS was done (Fig.1). Histological study of samples showed a well differentiated squamous cell carcinoma (Fig. 2). We did not evaluate the SPN as he refused to undergo further diagnostic work-up.

The tumor stage was T3N0M0. Therefore, he received chemo radiotherapy with platinum-based regimen. Thereafter, dysphagia improved significantly. Unfortunately, he died six months after treatment due to a heart attack.

Discussion

Motility type dysphagia defined by difficult passage of both liquids and solid foods to stomach is a diagnostic challenge to physicians. The differential diagnosis includes a wide spectrum of various disorders. At one end are benign motility disorders such as diffuse esophageal spasm, hypertensive LES and achalasia, and at the other extreme, are ominous malignant cancers mimicking achalasia. Dysphagia to both liquid and solid foods that is not due to primary neuronal disease and instead is due to secondary malignant or non-malignant causes is called pseudoachalasia; nonmalignant diseases include pancreatic pseudocyst, amyloidosis, sarcoidosis, neurofibromatosis, aortic aneurysm, juvenile Sjogren syndrome, chronic idiopathic intestinal pseudo obstruction, familial glucocorticoid deficiency syndrome, and a few surgeries (vagotomy, bariatric, Nissen fundoplication) (2, 5-12). Esophagogastric junction adenocarcinoma comprises the most common malignant cause of pseudoachalasia (2, 3, 13); the others include cancers of pancreas, esophagus, lung, kidney, hepatobiliary,

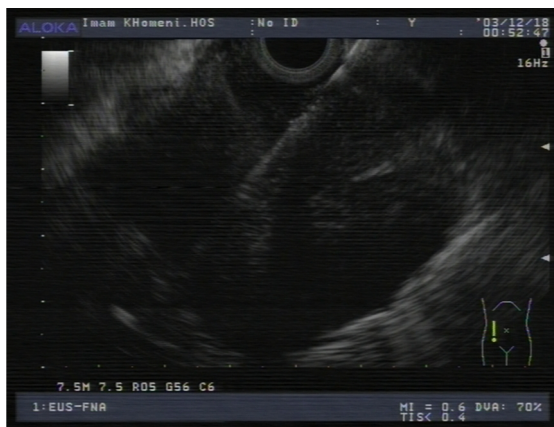


Fig. 1. Fine needle aspiration of the mass during endosonography.

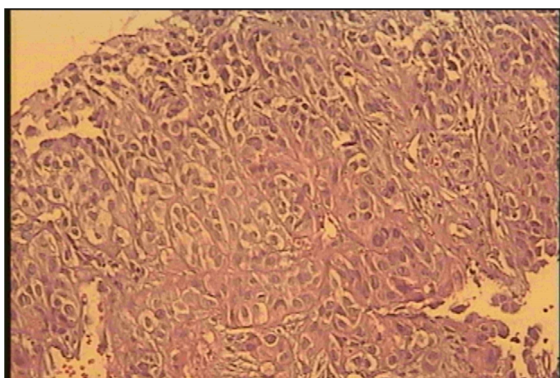


Fig.2. Squamous cell carcinoma pathologic preparation obtained during endosonography by Fine needle aspiration.

lymphoma and mesothelioma (2). Malignant neoplasms comprise 4% of achalasia-like syndromes (3, 13). Dysmotility in achalasia is caused by unrecognized causes that destroy distal esophageal and LES inhibitory neurons; these cause LES muscle contraction with no relaxation in deglutition. Suggested mechanisms for pseudoachalasia include encircling and compressing LES by tumor, infiltration of myenteric plexus branches or vagus nerves, and paraneoplastic neuropathy without direct infiltration of nerves by malignant cells (2, 5).

Standard treatment of achalasia, including balloon dilatation and surgical myotomy are ineffective and even dangerous for pseudoachalasia and delays timely diagnosis of malignant neoplasm (1-3, 5). So every attempts should be done to reach correct diagnosis.

Endoscopy is the first diagnostic modality in a patient with new onset dysphagia (14); it detects structural esophageal and gastric abnormalities; especially tumors. In achalasia-like syndrome, it may show mass, nodularity, irregular mucosa or ulcer, pointing to pseudoachalasia rather than achalasia (1, 15). Even in normal appearing mucosa, difficult passage of endoscope through LES suggests pseudoachalasia in contrast to achalasia that endoscope can be passed with subtle pressure through LES (1, 2).

In the case of normal appearing esophagus on endoscopy and new onset dysphagia, the physician must be vigilant to the presence of an underlying malignant lesion, especially when the patient is old, and there is significant weight loss (1, 13, 16). In such circumstances, CT scan and EUS are helpful diagnostic tools. CT scan may show asymmetric wall thickening of distal esophagus and even a well-defined mass (2, 5). EUS would reveal more information as it precisely defines esophageal wall layers and any abnormal tissue; EUS also can be used for tissue acquisition by FNA, when endoscopic biopsies are inconclusive (4, 17, 18).

In the literature, squamous cell carcinoma as a cause of pseudoachalasia has been

shown to be derived from esophagus, liver, lung and uterine cervix (1, 2, 5, 13). Our case was probably due to a primary lung squamous cell cancer with metastasis to distal esophagus because he was smoker and had a SPN in right lung.

Conclusion

Pseudoachalasia should be in mind when approaching to every patient with suspected achalasia and especially alarm signs should be questioned; on the other hand, it should be kept in mind that simple mucosal biopsy do not exclude pseudoachalasia and in suspected patients further work up such as CT scan and EUS may be warranted.

References

1. Kahrilas PJ, Kishk SM, Helm JF, Dodds WJ, Harig JM, Hogan WJ. Comparison of pseudoachalasia and achalasia. *Am J Med.* 1987 Mar; 82(3):439-46.
2. Paulsen JM, Aragon GC, Ali MA, Brody FJ, Borum ML. Pseudoachalasia secondary to metastatic breast carcinoma. *Dig Dis Sci.* 2010 Apr; 55(4):1179-81.
3. Lahbabi M, Ihssane M, Sidi Adil I, Dafr Allah B. Pseudoachalasia secondary to metastatic breast carcinoma mimicking radiation stenosis. *Clin Res Hepatol Gastroenterol.* 2012 Dec; 36(6):e117-21.
4. Bryant RV, Holloway RH, Nguyen NQ. Education and imaging. *Gastrointestinal: Role of endoscopic ultrasound in the evaluation of pseudoachalasia.* *J Gastroenterol Hepatol.* 2012 Jun; 27(6): 1128.
5. Saino G, Bona D, Nencioni M, Rubino B, Bonavina L. Laparoscopic diagnosis of pleural mesothelioma presenting with pseudoachalasia. *World J Gastroenterol.* 2009 Jul 28; 15(28):3569-72.
6. Benjelloun M, Peng CL, Héritier F, Roger M. [Pseudoachalasia due to amyloidosis treated by botulinum toxin]. *Rev Med Interne.* 2007 Mar; 28(3): 188-90.
7. López-Cepero Andrada JM, Jiménez Arjona J, Amaya Vidal A, Rubio Garrido J, Navas Relinque C, Soria de la Cruz MJ, Benítez Roldán A. [Pseudoachalasia and secondary amyloidosis in a patient with rheumatoid arthritis]. *Gastroenterol Hepatol.* 2002 Jun-Jul; 25(6):398-400.
8. Sica GS, Sujendran V, Warren B, Maynard ND. Neurofibromatosis of the esophagus. *Ann Thorac Surg.* 2006 Mar; 81(3):1138-40.
9. Awad ZT, Selima MA, Filipi CJ. Pseudoachalasia as a late complication of gastric wrap per-

formed for morbid obesity: report of a case. *Surg Today*. 2002; 32(10):906-9.

10. Roman S, Kahrilas PJ. Pseudoachalasia and laparoscopic gastric banding. *J Clin Gastroenterol*. 2011 Oct; 45(9):745-7.

11. Bonavina L, Bona D, Saino G, Clemente C. Pseudoachalasia occurring after laparoscopic Nissen fundoplication and crural mesh repair. *Langenbecks Arch Surg*. 2007 Sep; 392(5):653-6.

12. Chuah SK, Kuo CM, Wu KL, Changchien CS, Hu TH, Wang CC, Chiu YC, Chou YP, Hsu PI, Chiu KW, Kuo CH, Chiou SS, Lee CM. Pseudoachalasia in a patient after truncal vagotomy surgery successfully treated by subsequent pneumatic dilations. *World J Gastroenterol*. 2006 Aug 21; 12(31):5087-90.

13. Pesce A, Scilletta R, Branca A, Portale TR, Puleo S. A rare case of pancreatic cancer presenting as pseudoachalasia. *Ann Ital Chir*. 2012 Sep 10; 2012.

14. Kahrilas PJ, Pandolfino JE. Esophageal Neuromuscular Function and Motility Disorders. In: Feldman M, Friedman LS, Brandt LJ. *Sleisenger and Fordtran's Gastrointestinal and Liver Disease*. Philadelphia: SAUNDERS; 2010. p. 677-704.

15. Mohamed A. Education and Imaging. Gastrointestinal: pseudoachalasia caused by a lower esophageal stromal tumor. *J Gastroenterol Hepatol*. 2009 Jun; 24(6):1152.

16. Gockel I, Eckardt VF, Schmitt T, Junginger T. Pseudoachalasia: a case series and analysis of the literature. *Scand J Gastroenterol*. 2005 Apr; 40(4):378-85.

17. Devière J, Dunham F, Rickaert F, Bourgeois N, Cremer M. Endoscopic ultrasonography in achalasia. *Gastroenterology*. 1989 Apr; 96(4):1210-3.

18. Devière J. Primary achalasia: analysis of endoscopic ultrasonography features with different instruments. *Gastrointest Endosc Clin N Am*. 1995 Jul; 5(3):631-4.