



Therapeutic Effect of Autologous Activated Platelet-rich Plasma Therapy on Mid-dermal to Full-thickness Burns: A Case Series

Karina Karina, MD, PhD^{1,2,3,4} Krista Ekaputri, MD¹ Johannes Albert Biben, MD¹ Pritha Hadi, MD^{5,6}
Hubert Andrew^{2,7} Patricia Marcellina Sadikin, MD¹

¹Klinik Hayandra, Yayasan Hayandra Peduli, Jakarta Pusat, Indonesia

²HayandraLab, Yayasan Hayandra Peduli, Jakarta Pusat, Indonesia

³Faculty of Medicine, Universitas Pembangunan Nasional Veteran Jakarta, Indonesia

⁴Pusat Kajian Stem Cell, Universitas Pembangunan Nasional Veteran Jakarta, Indonesia

⁵Faculty of Medicine and Health Sciences, Universitas Jambi, Jambi, Indonesia

⁶Raden Mattaher Regional Hospital, Jambi, Indonesia

⁷Faculty of Medicine, Universitas Indonesia, Jakarta Pusat, Indonesia

Address for correspondence Karina Karina, MD, PhD, Klinik Hayandra, Yayasan Hayandra Peduli, Jl. Kramat VI No. 11, Jakarta Pusat, Indonesia (e-mail: karina@hayandra.com).

Arch Plast Surg 2022;49:405–412.

Abstract

Although modern medicine has made great strides in the management of burn injuries, associated complications such as pain, infection, dyspigmentation, and scarring have yet to be fully dealt with. Although skin grafting and meshing are routinely performed on burn patients, this method poses a risk for adverse effects. Activated autologous platelet-rich plasma (aaPRP), which is increasingly used in the field of plastic surgery, contains growth factors beneficial for wound regeneration. Seven cases of burns with varying severity and conditions that were treated with intralesional subcutaneous injection and intravenous aaPRP are presented and discussed herein. This case series indicates that subcutaneous and intravenous aaPRP is a safe procedure with the potential to be an alternative when skin grafting cannot be done or as an adjunct treatment to skin grafting.

Keywords

- ▶ platelet-rich plasma
- ▶ burns
- ▶ skin transplantation

Burn injuries are painful and could lead to morbidity through complications such as pain, infection, dyspigmentation, scarring, psychological conditions, and others.¹ Activated autologous platelet-rich plasma (aaPRP) is an interesting alternative to tackle these problems associated with burn injuries. aaPRP contains abundant growth factors, which are able to compensate for the depleted growth factors in wounds and provide an ideal microenvironment for wound repair.² We present seven cases of mid-dermal and full-thickness burns that were

treated with intralesional and intravenous (IV) aaPRP to demonstrate its therapeutic effects through wound re-epithelialization, anti-inflammation, and pain relief.

Case

This study reports a case series of seven patients with varying degrees of burns. The aaPRP was prepared with a method that our group developed. Exactly 24 mL of blood was

DOI <https://doi.org/10.1055/s-0042-1744423>.
ISSN 2234-6163.

© 2022. The Korean Society of Plastic and Reconstructive Surgeons. All rights reserved.

This is an open access article published by Thieme under the terms of the Creative Commons Attribution-NonDerivative-NonCommercial-License, permitting copying and reproduction so long as the original work is given appropriate credit. Contents may not be used for commercial purposes, or adapted, remixed, transformed or built upon. (<https://creativecommons.org/licenses/by-nc-nd/4.0/>)

Thieme Medical Publishers, Inc., 333 Seventh Avenue, 18th Floor, New York, NY 10001, USA

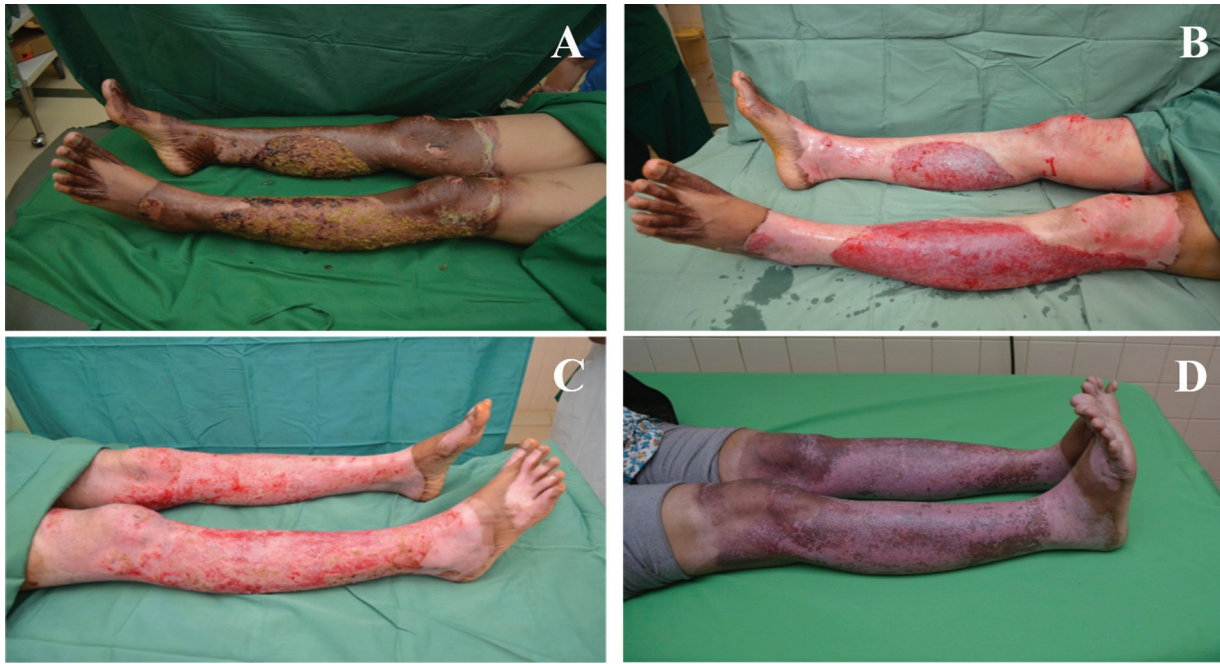

Fig. 1 Bilateral deep-dermal and full-thickness burns on the legs. (A,B) Initial presentation with (B) subsequent photograph after debridement and activated autologous platelet-rich plasma (aaPRP) therapy. (C) A photograph after the second dose of aaPRP on the 14th day. (D) A photograph showing full re-epithelialization of both legs on the 23rd day.

distributed into eight tubes containing sodium citrate and centrifuged at 1,000 rpm for 10 minutes. The plasma portion was drawn and recentrifuged at 3,000 rpm for 10 minutes. The platelet-poor portion was then discarded, leaving a concentrate of 2.5 mL in each tube (with ~8.85 times more platelets than whole blood). Precisely 0.15 mL of calcium activator (H-Remedy, HayandraLab, Indonesia) was added to each tube to activate the PRP, and the subsequent clots were removed. Finally, 10 mL of normal saline was added into each tube, and photoactivation (AdiLight-1, AdiStem Ltd., Hong Kong) was performed afterward. This processing method rendered the aaPRP devoid of leukocytes and platelets, and it was also suitable for subsequent IV administration.

For subcutaneous (SC) administration, we injected multiple doses of 0.1 mL of aaPRP. The injections were performed at the edge of the wound, with each injection 1 to 2 cm apart from the other. We also injected 0.1 mL of aaPRP at the center of the wound with a similar technique. The remaining aaPRP was then suspended in 100 mL of saline and delivered intravenously. In patients with a large wound area, the same dose of SC aaPRP was administered, but the distance between each injection was adjusted.

Case 1

A 43-year-old man presented with bilateral deep-dermal and full-thickness burns on his legs (18% of the total body surface area [TBSA]). Surgical debridement was performed 5 days after the flame burn injury. aaPRP therapy was then given via SC injection and IV infusion. The wound was dressed with paraffin gauze and dry gauze. The second dose of aaPRP was given on the 14th day postinjury. On the 18th day, the patient

was discharged, and 100% epithelialization was seen on the 23rd day (► Fig. 1).

Case 2

A 28-year-old man presented with deep-dermal burns on both forearms and hands (8% of the TBSA) due to flame. The wound was debrided on the third day postinjury and aaPRP was administered locally by SC injection and systemically by IV infusion. The second aaPRP dose was given on the ninth day postinjury. On the 21st day, the patient was discharged, and complete wound epithelialization was seen on the 26th day (► Fig. 2).

Case 3

A 38-year-old woman presented 2 days after experiencing deep-dermal and full-thickness burn on the lateral side of her left superior and inferior extremities. The burn comprised 13% of the patient's TBSA. On the fourth day postinjury, debridement was performed, followed by SC and IV aaPRP administration. A second dose was given on the 15th day postinjury. At 6 weeks postinjury, 100% epithelialization was observed. Long-term follow-up revealed a hypertrophic scar over the knee and elbow joint (► Fig. 3). The hypertrophic scar was subsequently treated with corticosteroid injection.

Case 4

A 42-year-old woman with a 3% TBSA mid-dermal burn presented 10 days after a flame injury to her left ventral arm and forearm along with signs of local infection (erythema, tenderness around the wound, and edema). The patient

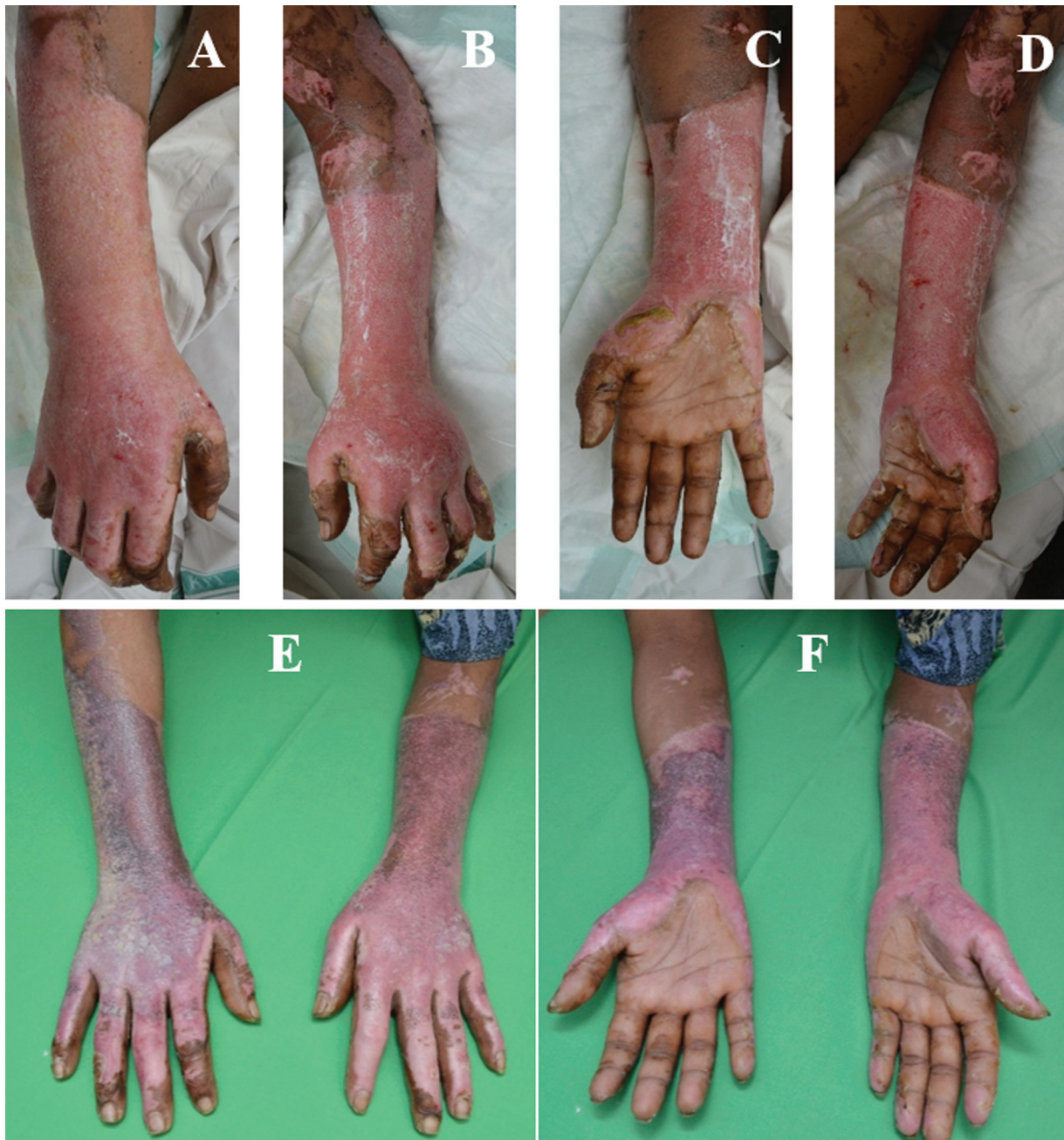

Fig. 2 Bilateral deep-dermal burns on the forearms and hands. The (A) right and (B) left posterior side along with the (C) right and (D) left anterior side of the forearm and hands after treatment on the third day. Full re-epithelialization on the (E) posterior and (F) anterior side of both forearm and hands on the 26th day postinjury.

experienced severe pain (numerical rating scale [NRS] 6) that discouraged her from extending her arm. On the same day, the wound was debrided and was treated with SC and IV aaPRP. On the 13th day postinjury, the patient reported relief from pain, and full epithelialization of the wound was observed (►Fig. 4). Mobility also returned, as the patient's arm could be extended comfortably.

Case 5

A 25-year-old woman experienced a 1% TBSA superficial-dermal burn on the dorsal aspect of the right hand. She was admitted to our clinic 7 days after a scalding injury and treated with SC and IV aaPRP. The patient's hand mobility

was limited due to severe pain (NRS 7) and inflammation. On the 10th day postinjury, no edema or inflammation was present on her hand. Hand mobility was regained as the patient was not in pain (NRS 0). Furthermore, 100% epithelialization of the affected area was observed (►Fig. 5).

Case 6

A 24-year-old man suffered an extensive deep-dermal and full-thickness burn injury 14 hours before presentation on both of his legs and the back of his left forearm and hand, comprising 44% of the TBSA. Surgical debridement was performed on the 1st day postinjury, administration of SC and IV aaPRP on the 1st and 14th days, escharotomy on the

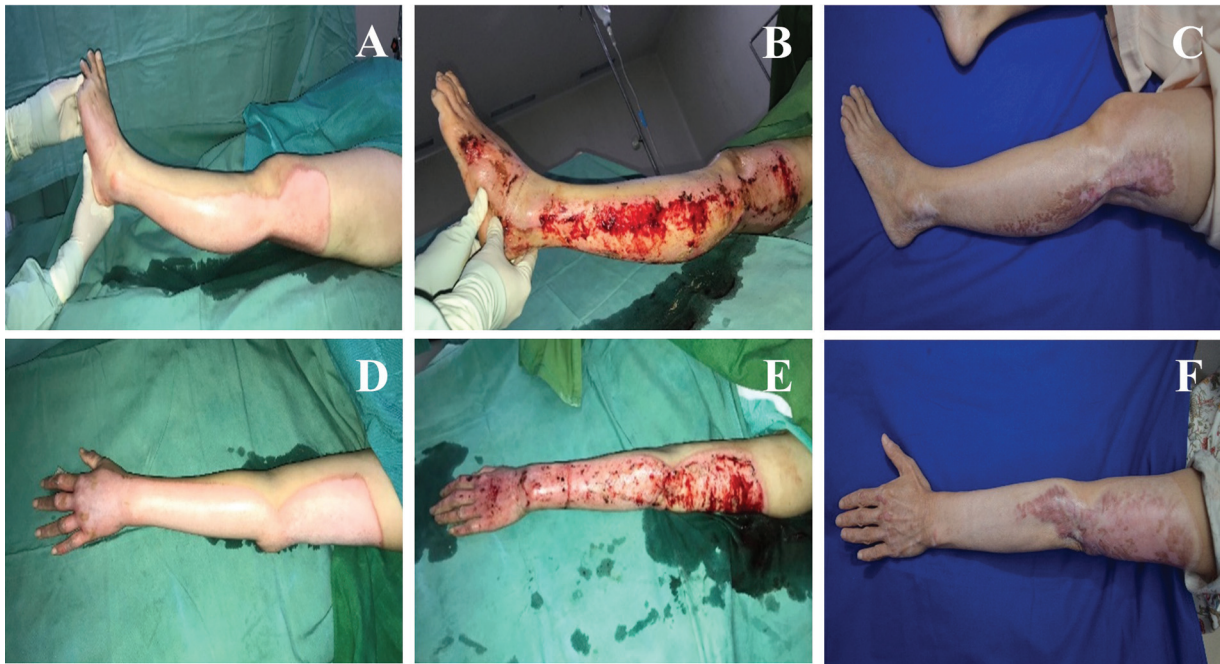

Fig. 3 Deep-dermal and full-thickness burns on the left extremities. Initial presentation at 2 days after injury of the (A) left inferior and (D) superior extremities. A photograph of the patient's (B) left inferior and (E) superior extremities after treatment on the fourth day. Subsequent follow-up of the (C) left inferior and (F) superior extremities at 9 months postinjury showing hypertrophic scarring.

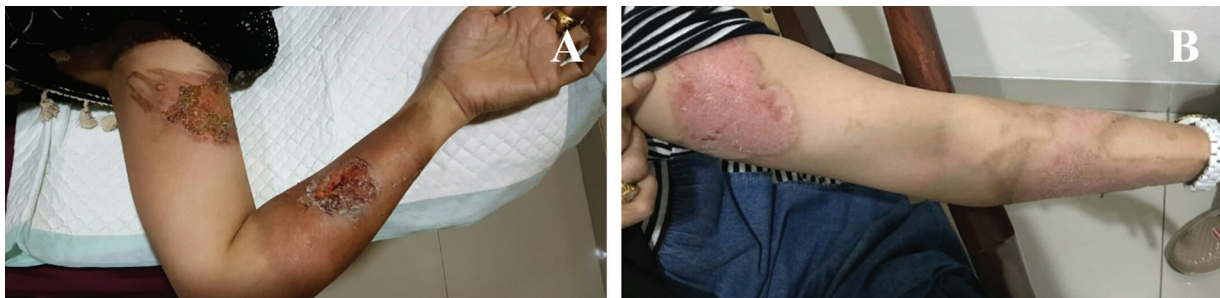

Fig. 4 Mid-dermal burn on the left arm and forearm. (A) Initial presentation with signs of local infection. (B) Return of mobility and complete epithelialization at 13 days postinjury.

6th and 16th days, and nonsurgical debridement on the 10th, 23rd, and 26th days postinjury. The patient was discharged on the same day as the last procedure with a 99% epithelialization rate (► Fig. 6).

Case 7

A 24-year-old man presented with deep-dermal and full-thickness burns inflicted 6 hours prior to hospitalization. The burns, which comprised 35% of the TBSA, were present on his bilateral anterior thighs, anterior left forearm, anterior right forearm, and posterior right forearm. Surgical debridement was performed upon hospitalization, escharotomy on the 3rd and 5th days postinjury, nonsurgical debridement on the 8th and 11th days, and aaPRP on the 2nd and 16th days. Additionally, a microbiology culture was also performed on the 15th day with samples taken from the patient showing infection by multidrug-resistant *Staphylococcus*. The patient was discharged on the 24th day with 100% epithelialization rate (► Fig. 7).

Informed consent was obtained from all the patients to include them in this case series and to publish their clinical photographs. No skin grafting procedures were done in any cases. Patients with deep-dermal and full-thickness burns were treated with aaPRP without skin grafting due to informed refusal. IV analgesics were given during hospitalization, whereas oral analgesics were given in the outpatient setting. Oral cephalosporin was given to patients if there were signs of infection. The last two cases required more intense antibiotic use to curb the infection. Patient 6 received ceftriaxone, ampicillin, and sulbactam, whereas patient 7 received ceftriaxone, ampicillin, sulbactam, vancomycin, and meropenem.

Discussion

Wound healing, pain, infection, and scarring remain as challenges in the management of burn injuries.¹ aaPRP is processed autologous plasma that is enriched in platelets. It contains

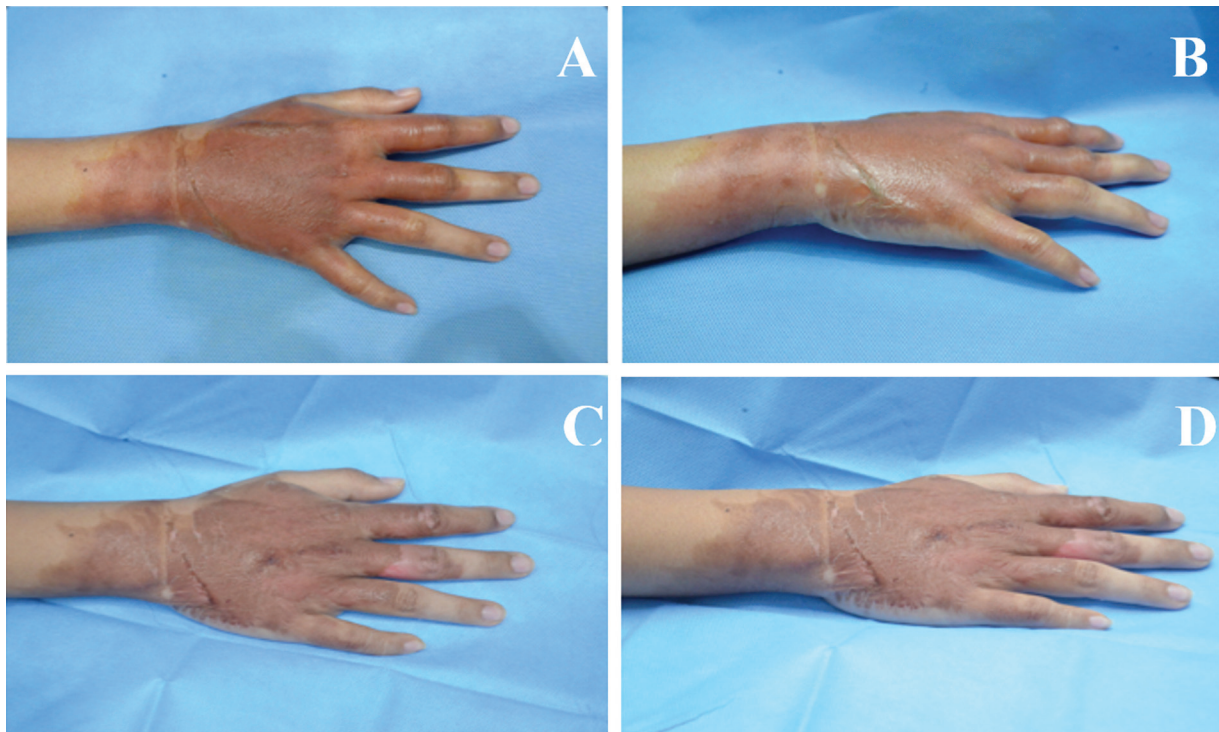


Fig. 5 Superficial-dermal burn of the dorsal right hand. (A) Anteroposterior and (B) oblique views of the hand at initial presentation. (C) Anteroposterior and (D) oblique views of the hand just 3 days after activated autologous platelet-rich plasma therapy.

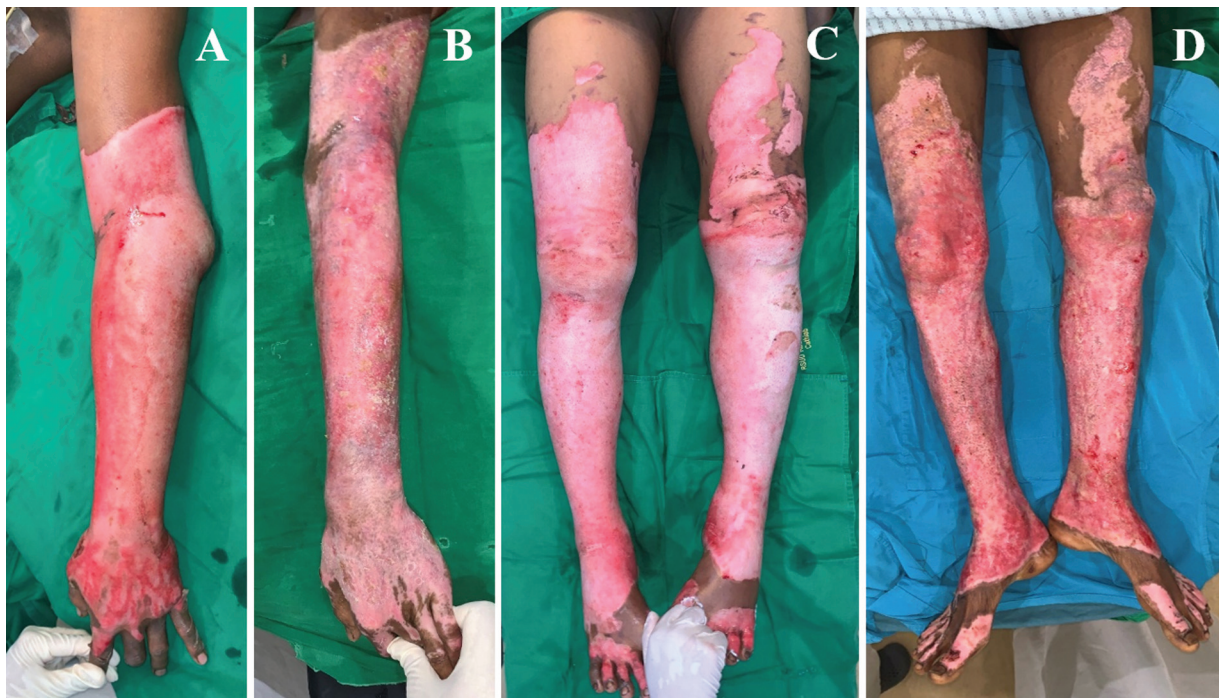


Fig. 6 Deep-dermal and full-thickness burns on the extremities. Initial presentation of a burn injury on the (A) left forearm and (C) both legs. Photograph presenting the condition of the (B) left forearm and (D) both legs 9 days after the second activated autologous platelet-rich plasma dose at 23 days postinjury.

growth factors and is frequently employed to accelerate wound healing, including burn wounds.³ Among the numerous growth factors present in aaPRP are platelet-derived growth factor, vascular endothelial growth factor, and epidermal growth factor.³ aaPRP also exerts anti-inflammatory

effects through the presence of cytokines, such as interleukin receptor antagonist and broad antibacterial effects through proteins such as connective tissue-activating peptide-III.^{4,5} It has been used in several clinical studies involving soft and hard tissue injuries, as well as burn wounds.^{2,6,7}

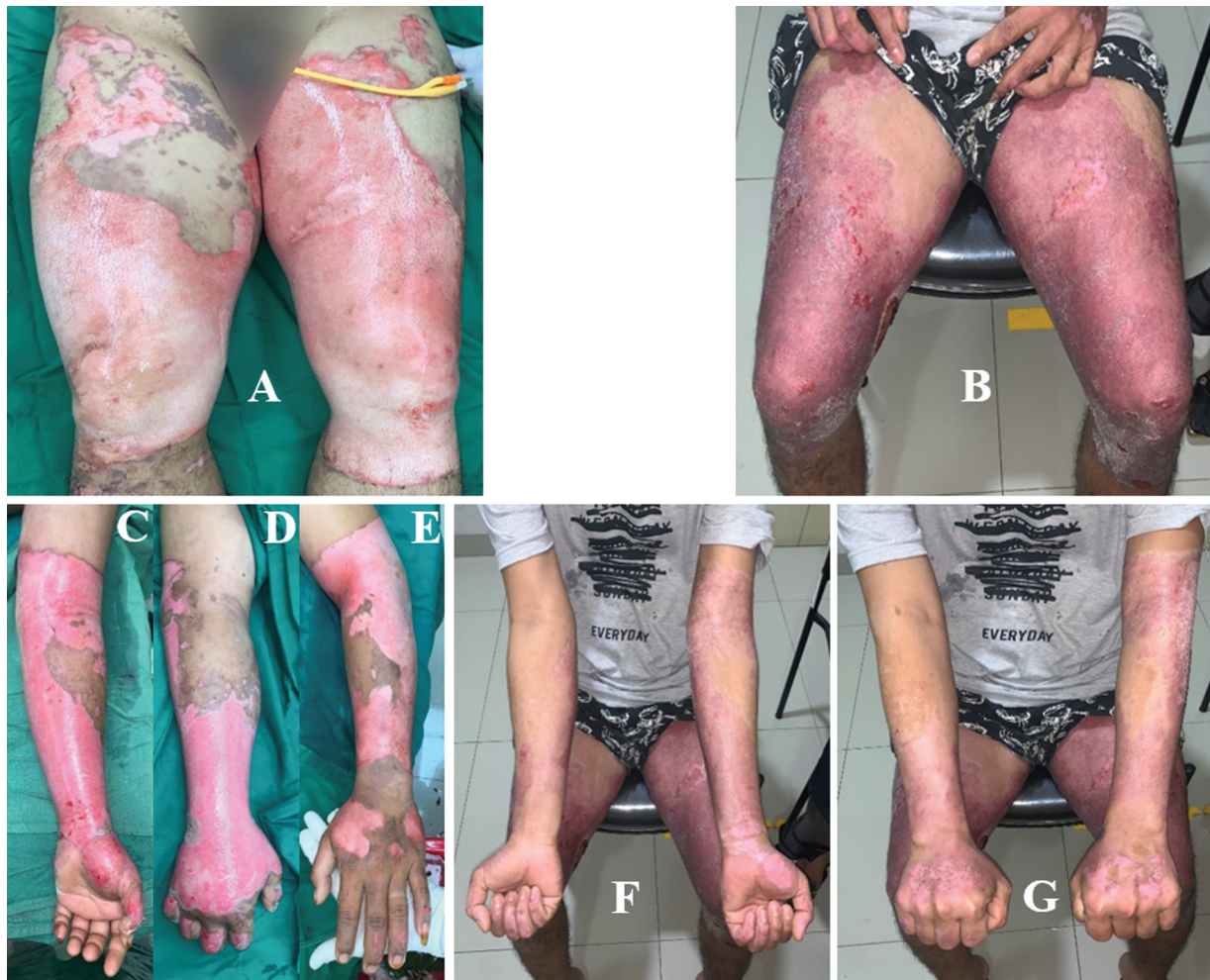

Fig. 7 Deep-dermal and full-thickness burns on the extremities. Initial presentation of a burn injury on the (A) anterior side of both thighs, (C) the anterior side of the left forearm, and (D) the anterior and (E) posterior side of the right forearm. Photographs of the anterior side of (B) both thighs and the (F) anterior side and (G) posterior side of both forearms at 5 days after discharge.

Wound closure is an important factor in burn injuries. Early wound closure reduces the risk of infection, fluid loss, mortality, and hypertrophic scarring.⁸ Our previous study in Sprague-Dawley rats with burn injuries showed that intradermal injection of PRP promoted tissue regeneration, although its performance was still inferior in comparison to a PRP–stromal vascular fraction combination.⁷ A porcine full-thickness wound model showed that the intrinsic contents of PRP promote extracellular matrix formation and organization, angiogenesis, and re-epithelialization.⁹ In cases 1, 2, 4, 5, and 7, intralesional and IV aaPRP therapy resulted in complete wound epithelialization before the fourth week.

Burn injuries cause pain by damaging peripheral sensory neurons and inducing inflammation by proinflammatory mediators.¹⁰ As we described earlier, aaPRP administration attenuated pain due to burn injuries. This amelioration in pain could be attributed to the anti-inflammatory properties of aaPRP. Beyond its applications for nociceptive burn pain due to inflammation, Huang et al¹¹ also demonstrated that PRP may be beneficial for burn-induced neuropathic pain, which develops in 6% of patients with burn injuries over 5 years.¹²

Infection is the second most common cause of mortality in burn injuries. The rise of multidrug organisms necessitates

innovations in increasing the effectiveness of current antimicrobials to improve burn injury morbidity and mortality rates.¹ Infection by *S. hominis*, which occurred in patient 7, accounts for around 50% of Gram-positive bacterial infections in Indonesian burn patients.¹³ The microbe responsible for infection was found to be resistant to all but one of the tested drugs (co-trimoxazole). In vitro and in vivo studies have previously confirmed the antibacterial properties of aaPRP. Although its exact mechanism has yet to be fully elucidated, aaPRP has the potential to be used as an adjunct to antibiotics for treatment of infections in burn injuries.⁵

In our patients, we did not perform split-thickness skin grafting (STSG). Usually, when burns are categorized as deep-dermal and full-thickness burns, skin grafting is done with prior debridement.¹ Pigmentation mismatch is a common complication with skin grafts, especially in STSG. In addition, grafting has risks such as donor and transplant site morbidity (scar, discoloration, hair loss at the donor site, and hair growth at the recipient area).^{1,14} It is important to note that the application of STSG is restricted in patients with severe burn injuries that comprise more than 50% of the TBSA as donor skin is very limited in such cases.¹ In our series, aaPRP treatment promoted wound healing and reduced

inflammation. This opens the possibility for aaPRP to serve as an alternative to skin grafting in deep burns where such a procedure is not an option, and it is also potentially beneficial in superficial burns.

When there is an insufficiency of donor skin, meshing is frequently done. Although meshing has several advantages such as covering a larger area for a smaller area of harvested skin, allowing fluid drainage, and increasing the edges for re-epithelialization, it has certain disadvantages. Meshing affects the original graft quality and can result in severe scarring. Furthermore, grafts that are subjected to meshing heal by secondary intention, which may result in contracture. Moreover, meshing is also aesthetically unfavorable as the recipient area heals with a checkered appearance.^{1,14} Based on our clinical experience, improving the mottled appearance of skin grafts is rather challenging in comparison to hypertrophic scar revision.

Although neither skin grafting nor meshing was not done in this case series, the utilization of PRP as a supplementary treatment to improve skin grafting outcomes is well documented.¹⁵ In the cases where epithelialization by aaPRP administration was predicted to be insufficient within 14 days, we opine that STSG should be considered. The rationale behind the utilization of aaPRP is to minimize the skin area in need of grafting, which in turn avoids the meshing or stamping of skin grafts and its aforementioned drawbacks. Thus, a complementary synergism—which could be taken advantage of—exists between aaPRP and STSG in the management of burn injuries.

Hypertrophic scars are the most common type of scar following burns. These scars pose a rehabilitative challenge and delay patients' reintegration into society, ultimately decreasing their quality of life.¹ Previous studies employing PRP for scar management showed promising results.¹⁶ In vitro, aaPRP lessens hypertrophic scar formation by downregulation of connective tissue growth factor through activation of the transforming growth factor- β 1 signaling negative feedback mechanism.¹⁷ Furthermore, a prolonged state of acute inflammation and delayed healing have been shown to induce pathological scarring or bacterial infection. Equine model research showed that wounds treated with PRP did not exhibit prolonged inflammation.^{18,19} This anti-inflammatory effect also counters systemic inflammation, which hinders the wound healing process through slower re-epithelialization and commonly occurs in severe burn patients.²⁰

In our series, we could not evaluate the scar outcomes because we did not perform long-term follow-up, except for patient 3, who developed hypertrophic scars at 9 months postinjury. A plausible explanation is that the location of the burn (which was at a major and highly-mobile joint) caused a slower healing process, hence contributing to scar formation. However, as previously stated, hypertrophic scars are more manageable than meshed or stamped skin. Furthermore, as skin grafting was not done, none of our patients experienced any donor scar morbidity.

Treatment with aaPRP ameliorates burn injury outcomes through various means, improving overall patient quality of

life. It is also a safe procedure that has the potential to be an alternative treatment in the cases where skin grafting cannot be done or as an adjunct when skin grafting is performed. Since this series is preliminary in nature, the optimal aaPRP dosing has yet to be determined. However, in the previous section, we have shared the empirical optimal dosing and frequency.

Although the results with our patients are encouraging, the limitations of this study are clear. The lack of long-term outcome data made long-term evaluations of the wounds impossible. In addition, as no recommendation currently exists, there was no standardization of aaPRP posology and administration frequency. Hence, further studies should be conducted in the form of well-designed randomized controlled trials to clarify the long-term results of aaPRP treatment in burn injury patients.

Author Contributions

Conceptualization: K.K. Investigation: K.E., J.A.B., and P.H. Resources: K.K. Writing—original draft: K.K., K. E., J.A.B., P.H., H.A., and P.M.S. Writing—review and editing: K.K., K.E., J.A.B., P.H., and H.A.

Ethical Approval

This study was approved by the Health Research Ethics Committee, University of Indonesia, and Cipto Mangunkusumo Hospital (No. 0249/UN2.F1/ETIK/2018) and performed in accordance with the principles of the Declaration of Helsinki.

Patient Consent

Informed consent was obtained from the patients.

Conflict of Interest

None declared.

References

- Wang Y, Beekman J, Hew J, et al. Burn injury: challenges and advances in burn wound healing, infection, pain and scarring. *Adv Drug Deliv Rev* 2018;123:3–17
- Liu J, Qu W, Li R, Zheng C, Zhang L. Efficacy of autologous platelet-rich gel in the treatment of deep grade II burn wounds. *Int J Clin Exp Med* 2018;11(03):2654–2659
- Pavlovic V, Ciric M, Jovanovic V, Stojanovic P. Platelet rich plasma: a short overview of certain bioactive components. *Open Med (Wars)* 2016;11(01):242–247
- Wakayama T, Saita Y, Kobayashi Y, et al. Quality comparison between two different types of platelet-rich plasma for knee osteoarthritis. *Regen Med Res* 2020;8:3
- Zhang W, Guo Y, Kuss M, et al. Platelet-rich plasma for the treatment of tissue infection: Preparation and clinical evaluation. *Tissue Eng Part B Rev* 2019;25(03):225–236
- Oryan A, Alidadi S, Moshiri A. Platelet-rich plasma for bone healing and regeneration. *Expert Opin Biol Ther* 2016;16(02): 213–232
- Karina K, Samudra MF, Rosadi I, et al. Combination of the stromal vascular fraction and platelet-rich plasma accelerates the wound healing process: pre-clinical study in a Sprague-Dawley rat model. *Stem Cell Investig* 2019;6(18):18

- 8 Singer AJ, Boyce ST. Burn wound healing and tissue engineering. *J Burn Care Res* 2017;38(03):e605–e613
- 9 Vermeulen P, Dickens S, Degezelle K, Van den Berge S, Hendrickx B, Vranckx JJ. A plasma-based biomatrix mixed with endothelial progenitor cells and keratinocytes promotes matrix formation, angiogenesis, and reepithelialization in full-thickness wounds. *Tissue Eng Part A* 2009;15(07):1533–1542
- 10 Morgan M, Deuis JR, Frøsig-Jørgensen M, et al. Burn pain: a systematic and critical review of epidemiology, pathophysiology, and treatment. *Pain Med* 2018;19(04):708–734
- 11 Huang SH, Wu SH, Lee SS, et al. Platelet-rich plasma injection in burn scar areas alleviates neuropathic scar pain. *Int J Med Sci* 2018;15(03):238–247
- 12 Klifto KM, Dellon AL, Hultman CS. Prevalence and associated predictors for patients developing chronic neuropathic pain following burns. *Burn Trauma* 2020;8:tkaa011
- 13 Soedjana H, Nadia J, Sundoro A, et al. The profile of severe burn injury patients with sepsis in hasan sadikin bandung general hospital. *Ann Burns Fire Disasters* 2020;33(04):312–316
- 14 Chen J, Jain SA. Principles of skin grafts. In: Weinzwieg J, ed. *Plastic Surgery Secrets Plus*. 2nd ed. Baltimore, MD: Mosby; 2010: 677–683
- 15 Aggarwal A, Chittoria RK, Dutta S, et al. Autologous platelet rich plasma: an adjunct to early tangential excision and grafting in burns. *Plast Aesthetic Res* 2018;5:47
- 16 Alser OH, Goutos I. The evidence behind the use of platelet-rich plasma (PRP) in scar management: a literature review. *Scars Burn Heal* 2018;4:2059513118808773
- 17 Nam SM, Kim YB. The effects of platelet-rich plasma on hypertrophic scars fibroblasts. *Int Wound J* 2018;15(04):547–554
- 18 Finnerty CC, Jeschke MG, Branski LK, Barret JP, Dziewulski P, Herndon DN. Hypertrophic scarring: the greatest unmet challenge after burn injury. *Lancet* 2016;388(10052):1427–1436
- 19 Carter CA, Jolly DG, Worden CE Sr, Hendren DG, Kane CJM. Platelet-rich plasma gel promotes differentiation and regeneration during equine wound healing. *Exp Mol Pathol* 2003;74(03):244–255
- 20 Rowan MP, Cancio LC, Elster EA, et al. Burn wound healing and treatment: review and advancements. *Crit Care* 2015;19:243