

CASE REPORT

Challenging, giant occipital encephalocele in a pediatric saipanese male

Joshua Loya | Nolan J. Brown  | David Gonda | Michael Levy

Department of Neurosurgery,
University of California San Diego,
Rady's Children's Hospital, San Diego,
California, USA

Correspondence

Nolan J. Brown, Department of
Neurosurgery, University of California
San Diego, 200 W Arbor Dr., #MC7893,
San Diego, CA 92103, USA.
Email: nolanb@uci.edu

Key Clinical Message: Giant occipital encephalocele is a rare form of congenital anomaly that involves protrusion of brain tissue (greater in size than the patient's cranial cavity) from a defect in the skull. This case reports illustrates repair of a giant encephalocele and emphasizes important methods to reduce risk for blood loss and other complications.

Abstract: A rare form of congenital anomaly, giant occipital encephalocele involves protrusion of brain tissue from a defect in the skull (in this case from the occiput). While encephalocele itself is a fairly rare entity, those qualifying as “giant”—defined by size of the deformity exceeding that of the skull itself—require very technically challenging surgery.

KEYWORDS

congenital malformation, dysraphism, encephalocele, neural tube defect, pediatric

1 | INTRODUCTION

An encephalocele is a type of cranial dysraphism characterized by herniation of intracranial contents including meninges, brain, blood vessels, and ventricular components through a midline calvarial defect.¹ As a rare form of neural tube defect, their etiology involves defective embryogenesis that can occur spontaneously or in association with early gestational exposures including hyperthermia, radiation, salicylates, and viral infection.² The giant variant, deemed as such when the encephalocele sac is larger than the newborn's head, represents a particularly rare and formidable treatment challenge in neurological surgery.^{3,4} These challenges arise from the relatively small circulating blood volume of the newborn patient coupled with resection of the often highly vascular encephalocele, which potentiates the risk of blood loss, hypovolemia, hypothermia, coagulopathy, and electrolyte imbalance from large fluid shifts in addition to unique anesthetic and airway concerns.^{2,5} Large encephaloceles

can be surgically treated with either truncation of the dysplastic neural tissue or reinternalization of the tissue into the cranial vault.⁶ Reinternalization in the giant variant poses a significant challenge due to the exceptionally high volume of tissue involved. Groups seeking to reinternalize the dysplastic tissue in these cases have reported performing concomitant cranial vault expansion to accommodate this volume and to avoid mass effect on the adjacent brain and intracranial hypertension.⁷ Because there is unclear benefit and possible detriment to reinternalization of the dysplastic neural tissue—and it can necessitate a more complex operation with higher risk—it is our practice to truncate the encephalocele tissue in large or giant lesions.

2 | CASE ILLUSTRATION

We present a newborn Saipanese male with limited prenatal care who presented to our institution with a giant occipital encephalocele with intact overlying dermis and

This is an open access article under the terms of the [Creative Commons Attribution-NonCommercial-NoDerivs](https://creativecommons.org/licenses/by-nc-nd/4.0/) License, which permits use and distribution in any medium, provided the original work is properly cited, the use is non-commercial and no modifications or adaptations are made.

© 2023 The Authors. *Clinical Case Reports* published by John Wiley & Sons Ltd.

pedunculated base (Figure 1). On examination, the patient elicited a strong cry with good facial symmetry and suckle, tolerated oral feeds, moved all extremities spontaneously with gross symmetry, and had a full but soft fontanel. An MRI was obtained showed a giant encephalocele sac containing a large amount of dysplastic brain tissue and ventricular components with a robust vascular supply as demonstrated on MR venogram (Figures 2 and 3). As noted by Zhahid and Khizar,⁸ the meningeal membrane that surrounds the giant encephalocele can be covered by a normal membrane, one that is unusually thin, or alternatively a dysplastic (abnormal) membrane, as was the case with our patient. The “large amount of dysplastic brain tissue” evident on MRI is therefore a reference to the large amount of abnormal tissue surrounding the brain that will eventually require dissection and removal.

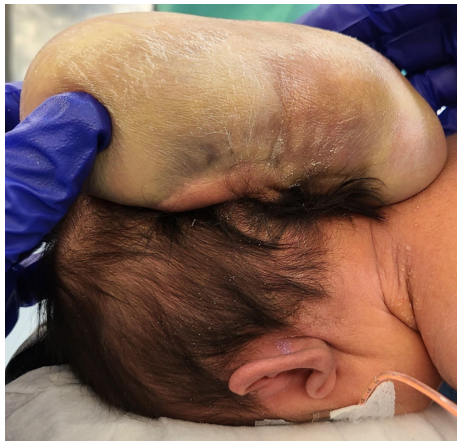

FIGURE 1 Newborn Saipanese male with limited prenatal care born at full term with an occipital mass.

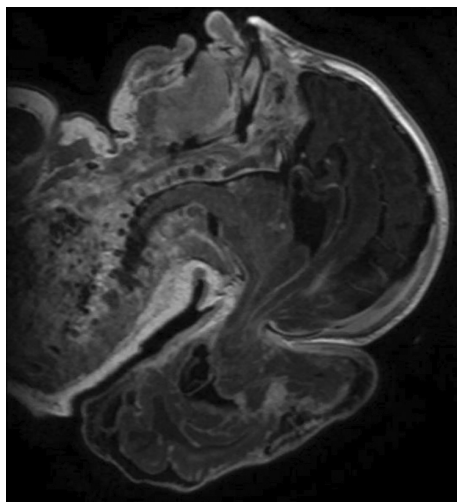


FIGURE 2 Magnetic resonance imaging revealed a 1.4 cm calvarial defect with a giant occipital encephalocele containing a large amount of dysplastic brain tissue.

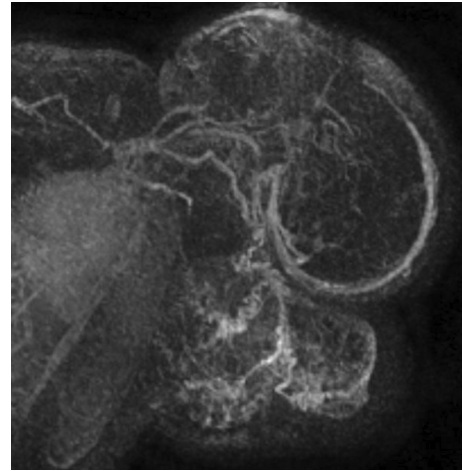

FIGURE 3 Magnetic resonance venogram shows robust vascular bundle supplying the dysplastic brain tissue within the encephalocele.

As this patient was certainly a candidate for surgical intervention, discussion was had with the parents regarding the profound neurocognitive disability often associated with these severe malformations and the decision was made to proceed with maximal surgical care after counseling. After fiberoptic intubation the patient was placed prone in a horseshoe headrest taking care to support the encephalocele manually during positioning, prepping, and draping to avoid tearing or rupture. A circumferential incision is made just below the equator of the lesion and dissection is carried anteriorly and circumferentially toward the calvarial defect being careful to remain in the dysplastic subcutaneous plane outside the neural tissue to minimize blood loss. Once the root of the encephalocele with its vascular supply is isolated around a perimeter, it is ligated with heavy silk suture at the base (Figure 4). Given the size of the encephalocele, it was determined that attempting to internalize the encephalocele material into the calvarium could place the native and ostensibly more normal neural structures at risk. Therefore, the encephalocele was truncated at its pedunculated base which appeared highly vascular and disorganized. The dysplastic tissue was then resected leaving a ligated end which is internalized and covered with native dura that was freed surrounding the defect (Figure 5). The patient remained hemodynamically stable during the perioperative and postoperative course and was extubated. Following the encephalocele repair, head circumference and transfontanelle ultrasound results were tracked on a daily basis. This demonstrated increasing head circumference through growth curves and increasing ventricular size consistent with hydrocephalus. As a result, the decision was made to place a cerebrospinal fluid shunt in delayed fashion for unresolved hydrocephalus. At the time the shunt was

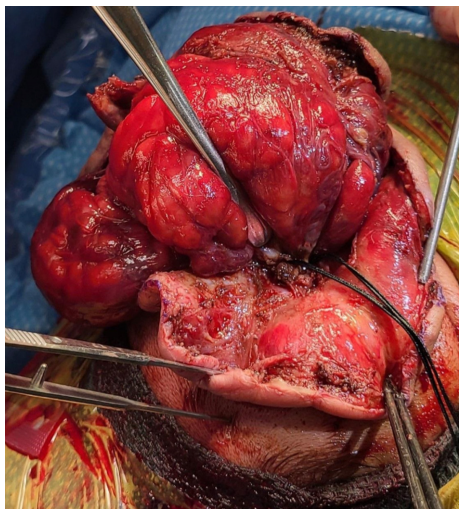


FIGURE 4 The pedicle of the dysplastic brain tissue is ligated with suture after circumferential dissection approaching the calvarial defect.

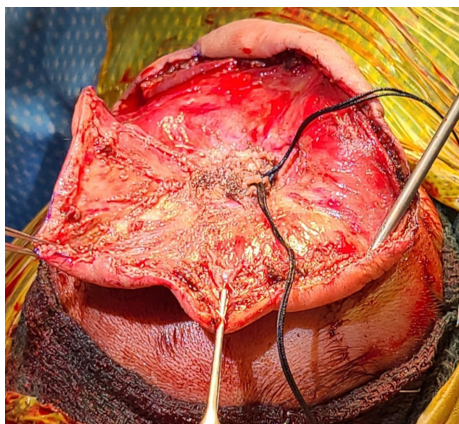


FIGURE 5 The remnant ligated pedicle and surrounding dysplastic dura and dermal tissue at the cranial defect after resection of the encephalocele contents.

placed (within 3 weeks postoperative) there were no signs of CSF leak, visual acuity deficits, or wound infection. Of note, hydrocephalus is commonly reported in conjunction with giant encephaloceles. As such, it was not thought to be a complication of the surgical intervention or the result of bleeding or other iatrogenic cause, but rather a feature related to the natural history and constellation of pathology associated with occipital encephaloceles.

3 | DISCUSSION

Numerous factors affect the outcome of surgical intervention in patients with encephaloceles, with the occiput being the most common location for this class of cranial dysraphisms. Among these factors include location, the size of the sac, the amount of brain matter herniated into

the contents of the sac, the presence versus absence of the brainstem, occipital lobe, and dural sinuses within the sac, and whether or not hydrocephalus is present.⁸ Even in cases where the surgeon is well aware of these factors and fully equipped to address them, complications such as intraoperative blood loss and perioperative hypothermia are in some cases inevitable and the potential for their occurrence lends an added layer of complexity to these cases.

Even more complex and challenging are giant occipital encephaloceles, an extremely rare, formidable form of encephalocele that can be very challenging for neurosurgeons to treat successfully. Also referred to as large or massive encephaloceles, giant encephaloceles are reported in only a few cases in reports in the literature and their exact incidence is unknown. Typically, patients with giant occipital encephaloceles will present as neonates and infants due to difficulties nursing and feeding, even when their defect should be recognized and addressed at birth.⁴ When the patients eventually present weeks or even months down the line, microcephaly, cleft lip, and CSF leak may be observed.⁴

Preoperatively, MRI should be evaluated to assess the condition of the transverse sinus and torcula in giant occipital encephaloceles, as these sinuses can herniate with other contents into the sac. MRI is also the first choice of imaging because CT should only be performed as a last resort due to risks of infant exposure to radiation (sometimes CT may be necessary to assess the structural integrity of the underlying bone). In a recent cases series of 14 children with giant encephaloceles (13 of which were located occipitally), hydrocephalus was present in 10 patients upon presentation.⁴ Seven of these patients ultimately required ventriculoperitoneal (VP) shunt, of which five were placed during the encephalocele repair surgery and the remaining two were inserted postoperatively in the setting of worsening hydrocephalus, the same scenario that required postoperative shunt insertion in our patient.⁴

Intraoperatively, perhaps the most challenging decision the surgeon will face is whether to perform partial excision of the brain or return its contents in full back into the intracranial cavity. In an ideal situation, all brain tissue would of course be kept, but the challenge of doing so in these anomalous cases is that the volume of herniated brain exceeds the size of cranial vault and cavity. In the series reported by Mahapatra and colleagues, 7/14 patients underwent partial excision of brain prior to closure.⁴ Other measures can be taken to avoid concerning elevations in ICP even when the full brain contents are returned—these include expansile cranioplasty and craniectomy—however, these measures involve a delicate balance of many considerations as even small fluctuations in ICP in infants can lead to complications such as sudden cardiorespiratory arrest.⁴ In sum, this surgery should be completed

in an efficient manner as possible due to risks for infant hypothermia, complications resulting from prolonged administration of anesthesia, blood loss, infection, respiratory distress, and aspiration pneumonia, among others.

4 | CONCLUSIONS

Herein, we present the rare case of a newborn Saiponese male with giant occipital encephalocele that was surgically reduced back into the patient's intracranial cavity during an exceedingly complex and risky procedure. Fortunately, the surgery was successful and the patient made good recovery in the immediate postoperative course. When encountered, all encephaloceles—including those meeting the criteria for “giant” and located occipitally—should be evaluated for the following, as these are the most important factors informing operative plan: encephalocele location, size, contents, and presence versus absence of hydrocephalus.

AUTHOR CONTRIBUTIONS

Joshua Loya: Conceptualization; investigation; methodology; project administration; supervision; validation; visualization; writing – original draft; writing – review and editing. **Nolan J. Brown:** Writing – original draft; writing – review and editing. **David Gonda:** Conceptualization; project administration; supervision; validation; visualization; writing – review and editing. **Michael Levy:** Conceptualization; supervision; validation; writing – review and editing.

FUNDING INFORMATION

Authors report no funding sources related to this work.

CONFLICT OF INTEREST STATEMENT

Authors report no conflicts of interest related to this work.

DATA AVAILABILITY STATEMENT

Data cannot be shared for confidentiality reasons. Queries about the data should be directed to the corresponding author.

ETHICS STATEMENT

Ethical approval was not required for this study in accordance with national guidelines.

CONSENT

Written informed consent was obtained from the patient to publish this report in accordance with the journal's patient consent policy.

ORCID

Nolan J. Brown  <https://orcid.org/0000-0002-6025-346X>

REFERENCES

1. Ghritlaharey RK. A brief review of Giant occipital encephalocele. *J Neurosci Rural Pract.* 2018;9(4):455-456.
2. Mahajan C, Rath GP, Bithal PK, Mahapatra AK. Perioperative management of children with giant encephalocele: a clinical report of 29 cases. *J Neurosurg Anesthesiol.* 2017;29(3):322-329.
3. Agrawal D, Mahapatra AK. Giant occipital encephalocele with microcephaly and micrognathia. *Pediatr Neurosurg.* 2004;40(4):205-206.
4. Mahapatra AK. Giant encephalocele: a study of 14 patients. *Pediatr Neurosurg.* 2011;47(6):406-411.
5. Singh HSD, Sharma D, Tandon M, Ganjoo P. Perioperative challenges in patients with giant occipital encephalocele with microcephaly and micrognathia. *J Neurosci Rural Pract.* 2012;3(1):68-70.
6. Bozinov O, Tirakotai W, Sure U, Bertalanffy H. Surgical closure and reconstruction of a large occipital encephalocele without parenchymal excision. *Childs Nerv Syst.* 2005;21(2):144-147.
7. Mohanty A, Biswas A, Reddy M, Kolluri S. Expansile cranioplasty for massive occipital encephalocele. *Childs Nerv Syst.* 2006;22(9):1170-1176.
8. Zahid S, Khizar A. Giant occipital encephalocele: a case report, surgical and anesthetic challenge and review of literature. *Egypt J Neurosurg.* 2021;36:38.

How to cite this article: Loya J, Brown NJ, Gonda D, Levy M. Challenging, giant occipital encephalocele in a pediatric saiponese male. *Clin Case Rep.* 2023;11:e7380. doi:[10.1002/ccr3.7380](https://doi.org/10.1002/ccr3.7380)