

Comparison of Special Stains for Keratin with Routine Hematoxylin and Eosin Stain

Roopa S Rao¹, Shankargouda Patil², Barnali Majumdar³, Rakesh G Oswal⁴

Contributors:

¹Professor and Head, Department of Oral Pathology & Microbiology, Faculty of Dental Sciences, MS Ramaiah University of Applied Sciences, Bengaluru, Karnataka, India; ²Associate Professor, Department of Oral Pathology & Microbiology, Faculty of Dental Sciences, MS Ramaiah University of Applied Sciences, Bengaluru, Karnataka, India; ³Postgraduate Student, Department of Oral Pathology & Microbiology, Faculty of Dental Sciences, MS Ramaiah University of Applied Sciences, Bengaluru, Karnataka, India; ⁴Reader, Department of Oral and Maxillofacial Surgery, MA Rangoonwala Dental College and Hospital, Pune, Maharashtra, India.

Correspondence:

Dr. Patil S. Department of Oral Pathology & Microbiology, Faculty of Dental Sciences, MS Ramaiah University of Applied Sciences, MS Ramaiah Institute of Technology Post, MS Ramaiah Nagar, Bengaluru - 560 054, Karnataka, India. Email: sbpatil1612@gmail.com

How to cite the article:

Rao RS, Patil S, Majumdar B, Oswal RG. Comparison of special stains for keratin with routine hematoxylin and eosin stain. J Int Oral Health 2015;7(3):1-5.

Abstract:

Background: Keratins are the most abundant proteins and are characteristic findings in many epithelial pathologies, making it a diagnostically important marker, both histopathologically and immunohistochemically. Since, immunohistochemistry is an expensive diagnostic tool, special stains to detect the degree of keratinization could serve as a faster and economic option. The aim of the present study was to compare the efficacy of special stains for keratin with standard hematoxylin and eosin stain (H and E). Objectives include: (i) To subject the diagnosed cases of keratin disorders to the selected special stains: Ayoub-shklar method, Dane-Herman method, Alcian blue –periodic acid Schiff's (PAS), rapid papanicolaou (PAP) and Gram's stain. (ii) To compare the staining specificity and staining intensity of special stains with respect to routine hematoxylin and eosin (H and E) stain. (iii) To compare the efficacy of special stains to routine H and E stain in identification of the type of keratin present in the selected cases.

Materials and Methods: A total of 80 cases of known pathology for keratin were retrieved from the department archive, which included 10 each of normal gingiva, hyperkeratosis, squamous papilloma, verrucous hyperplasia, verrucous carcinoma, well-differentiated squamous cell carcinoma, orthokeratinized odontogenic cyst and keratocystic odontogenic tumors. Six sections of 4 µ each from the paraffin blocks were made, stained with H and E and the special stains and these were evaluated by 2 pathologists based on the modified scoring criteria from Rahma Al-Maaini and Philip Bryant 2008.

Results: The results were tabulated using Chi square and kappa statistics. The statistical values for identification of the type of keratinization was insignificant showing that ortho and parakeratinized epithelia could be correctly identified by both H

and E as well as all the special stains. Furthermore, all the special stains showed a positive result and statistical significance ($P < 0.001$) with respect to the staining of keratin.

Conclusion: To conclude, though the special stains distinctly stained the keratin with a higher intensity, H and E proves to be overall better stain with respect to specificity

Key Words: Keratins, Ayoub-Shklar, Dane-Herman, alcian blue-periodic acid schiff, PAP, gram

Introduction

Keratins are one of the major and key structural proteins, found at their highest concentration and diversity in the keratinocytes of cutaneous as well as oral epithelium and accounts for almost 80% of the total protein content in differentiated cells of stratified epithelia. In the 1900s, keratins were believed to be the proteins, which could be extracted from the various epidermal modifications of animals such as wool, horns, claws, etc.^{1,2} Subsequently, with advancement in research and advent of 21st century technologies, keratins (cytokeratins) are now considered as intermediate filament proteins with specific physicochemical properties, found in any vertebrate epithelia.² They are part of the multi-gene family of proteins, occurring in basic and acidic protein pairs with varied expression pattern in different types of epithelia, as well as different layers of a single stratified epithelium. The main function of cytokeratins along with microtubules and microfilaments is to provide with structural integrity and mechanical resiliency to all the eukaryotic cells.³

The oral epithelium can be categorized into keratinized stratified epithelia (ortho and parakeratinized) and non-keratinized epithelia based on the presence or absence of keratinization. Keratinization or cornification involves the process of cytodifferentiation of the keratinocytes, starting from their post formative state, i.e., stratum basale to the final differentiated state of toughened cornified cells filled with keratin filaments found in the surface layer, i.e., stratum corneum.⁴

A wide range of hereditary and premalignant and malignant disorders arise due to defects in the keratinization process making keratin proteins an important diagnostic tool.⁴ Hence, one of the important fields of application of the keratins is in the diagnosis of epithelial pathologies. Though immunohistochemistry is known for its specificity in the diagnosis, it is not the preferred choice due to its cost and time consumption. Hematoxylin and eosin (H and E), the routine

dye, does not distinguish different eosinophilic components of connective tissue distinctly, on the other hand, special stains can prove to be a simple cost-effective solution to detect the presence and pattern of keratin histologically.

In the present study special stains ayoub-shklar (A-S) method, Dane-Herman (D-H) method, Alcian blue (AB) –periodic acid Schiff's (PAS), rapid papanicolaou (PAP) and Gram's stain were compared with routine H and E stain, with respect to their staining quality and ability to identify keratin.⁵

Aim and objectives

The aim of the present study was to compare the efficacy of special stains for keratin with standard H and E stain.

Objectives of the study include:

- (i) To subject the diagnosed cases of keratin disorders to the selected special stains: A-S method, D-H method, AB – PAS, rapid PAP and Gram's stain.
- (ii) To compare the staining specificity and staining intensity of special stains with respect to routine H and E stain.
- (iii) To compare the efficacy of special stains to routine H and E stain in identification of the type of keratin present in the selected cases.

Materials and Methods

The case selection and procedure for the present study are depicted in Flowchart 1 and Table 1 respectively.

The staining procedure for A-S stain was adopted from Ramulu *et al.*, the Dane- Herman stain from Dane and Herman and the other stains from Bancroft and Gamble.⁵⁻⁷ The AB -PAS procedure was modified from Scott and Clayton as follows:⁸

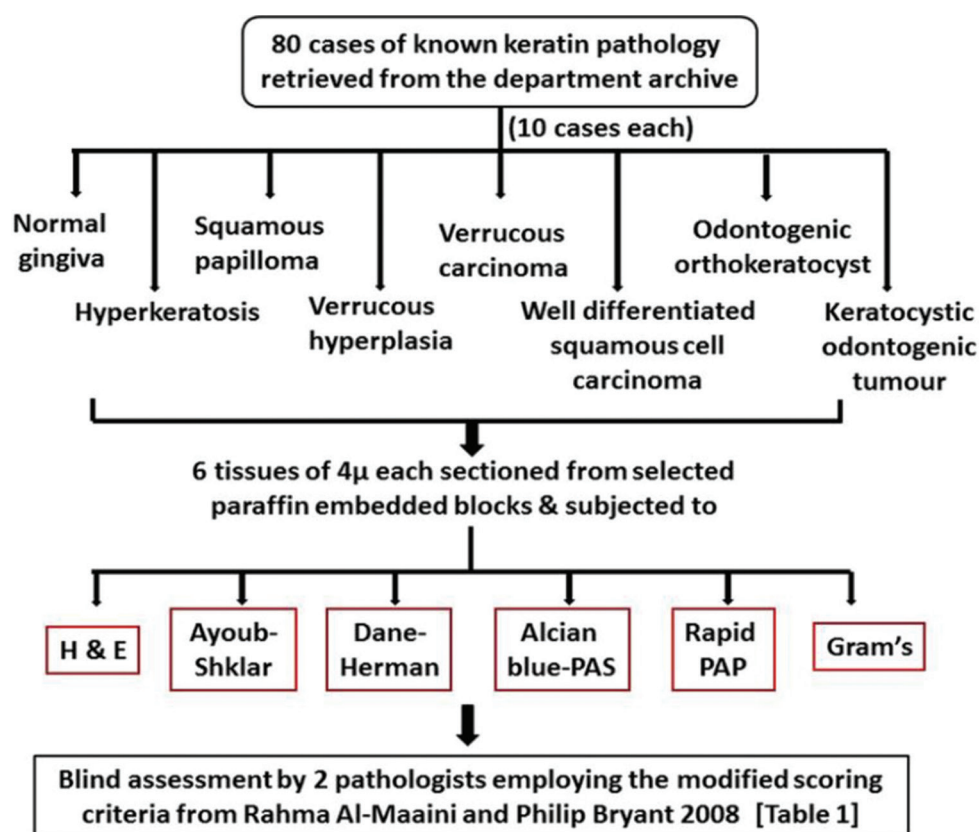
1. Deparaffinize and hydrate the tissue sections with distilled water.
2. Stain in AB for 30 min. Wash in water for 5 min.
3. Oxidize in acidified permanganate (equal parts of 0.5% potassium permanganate and 0.5% of sulfuric acid) for 5 min and rinse with 2% oxalic acid for 30 s and wash in water for 5 min.
4. Stain in Schiff's reagent for 15 min and wash in water for 10 min.
5. Stain in Mayer's hematoxylin for 3 min and wash in water for 5 min.
6. Dehydrate, clear in xylene and mount.

Statistical analysis

The results were tabulated using Chi-square test and kappa statistics for inter-observer variations.

Results

The pictomicrograph of keratin stained with H and E and the special stains is depicted in Figure 1. In the present study, all the special stains showed positive, and statistically significance of ($P < 0.001$) results with respect to the staining of keratin.



Flowchart 1: Case selection and procedure.

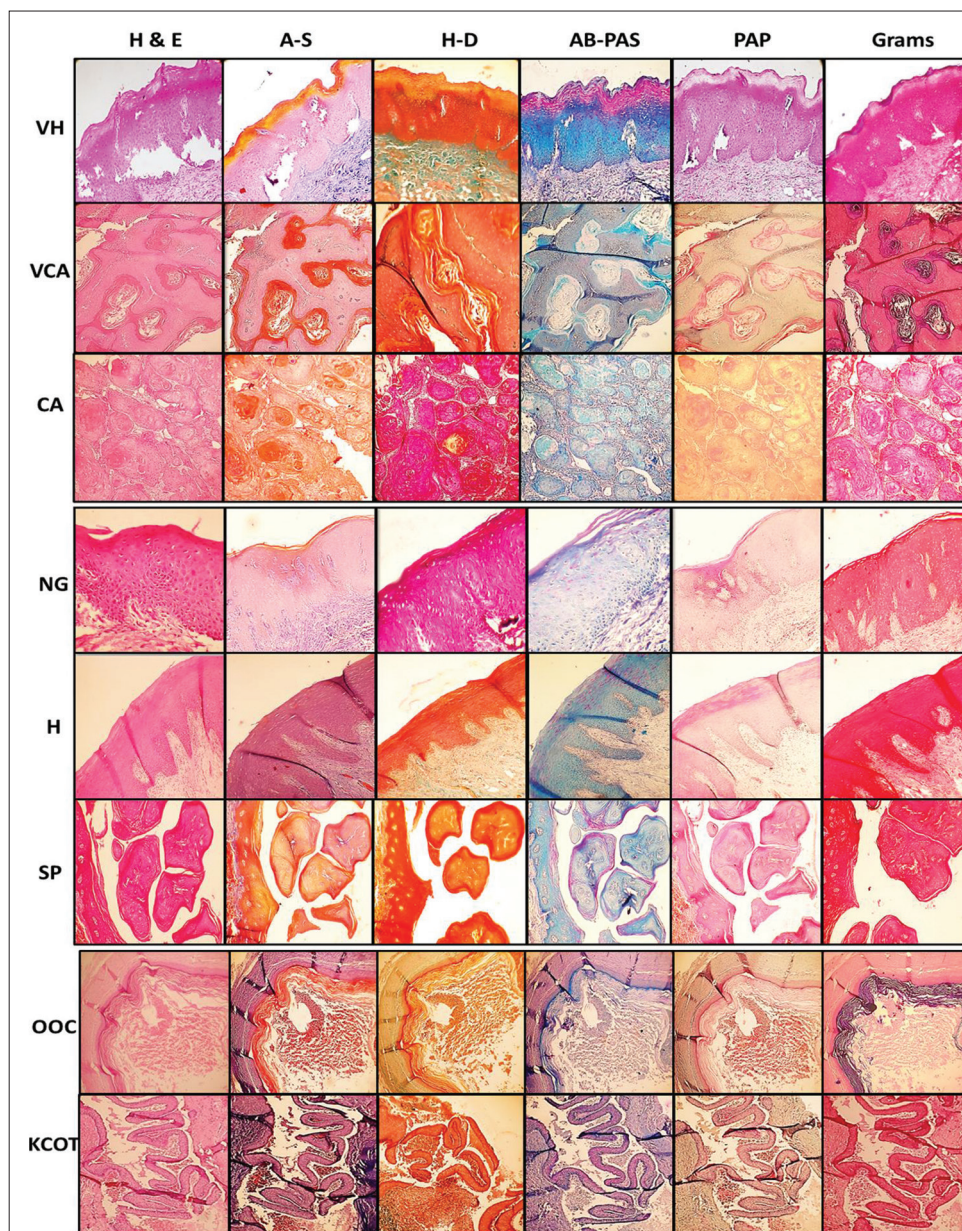


Figure 1: Pictomicrograph of keratin stained with H and E and different special stains (Magnification power: 10×) (NG: Normal gingiva, H: Hyperkeratosis, SP: Squamous papilloma, VH: Verrucous hyperplasia, VCA: Verrucous carcinoma, CA: Well differentiated squamous cell carcinoma, OOC: Orthokeratinized odontogenic cysts, KCOT: Keratocystic odontogenic tumour, H and E: Hematoxylin and eosin, A-S: Ayoub-shklar method, D-H: Dane-Herman method, AB-PAS: Alcian blue-periodic acid Schiff, PAP: Rapid papanicolaou and Gram’s stain).

Among the special stains, the staining specificity of D-H method was found to be higher, followed by A-S, AB-PAS, PAP and Gram’s (Table 2). Regarding the staining intensity, A-S method was found to be greater, followed by AB -PAS, D-H method, PAP and Gram’s (Table 3). Overall, the staining specificity and intensity of H and E was found to be highest when compared to all the special stains.

The statistical values for identification of the type of keratinization was insignificant showing that ortho and parakeratinized epithelia could be correctly identified by both H and E as well as all the special stains (Table 4).

Table 1: Criteria selected for evaluation of stains ^a	
Criteria	Score
Specificity of the stain	1 – Poor
Staining intensity	2 – Satisfactory
	3 – Good
	4 – Excellent

Kappa value of 0.57-0.60 suggested fair to moderate agreement between observers.

Discussion

Special stains are the non-routine stains which can differentiate specific cells, tissue components and microorganisms when

Table 2: Statistical values for staining specificity.

Stains (%)	Staining specificity				Total	χ^2 value	P value
	1	2	3	4			
H and E stain	0	0	18 (22.5)	62 (77.5)	80 (100)	545.524	<0.001
D-H stain	0	3 (3.8)	48 (60.0)	29 (36.3)	80 (100)		
A-S stain	0	9 (11.3)	62 (77.5)	9 (11.3)	80 (100)		
AB-PAS	0	18 (22.5)	61 (76.3)	1 (1.3)	80 (100)		
PAP	0	79 (98.8)	1 (1.3)	0	80 (100)		
Gram	9 (11.3)	65 (81.3)	6 (7.5)	0	80 (100)		

H and E: Hematoxylin and eosin, D-H: Dane-Herman, A-S: Ayoub-shklar, AB-PAS: Alcian blue-periodic acid Schiff's, PAP: Papanicolaou

Table 3: Statistical values for staining intensity.

Stains (%)	Staining intensity			Total	χ^2 value	P value
	2	3	4			
H and E stain	0	46 (57.5)	34 (42.5)	80 (100)	264.929	<0.001
D-H stain	0	75 (93.8)	5 (6.3)	80 (100)		
A-S stain	9 (11.3)	43 (53.8)	28 (35.0)	80 (100)		
AB-PAS	3 (3.8)	66 (82.5)	11 (13.8)	80 (100)		
PAP	43 (53.8)	37 (46.3)	0	80 (100)		
Gram	51 (63.7)	29 (36.3)	0	80 (100)		

H and E: Hematoxylin and eosin, D-H: Dane-Herman, A-S: Ayoub-shklar, AB-PAS: Alcian blue-periodic acid Schiff's, PAP: Papanicolaou

Table 4: Statistical value for type of keratin identification.

Stains (%)	Para		Total	Ortho		Total	χ^2 value	P value
	Absent	Present		Absent	Present			
H and E stain	15 (37.5)	25 (62.5)	40 (100)	25 (62.5)	15 (37.5)	40 (100)	0.000	1.000
D-H stain	15 (37.5)	25 (62.5)	40 (100)	25 (62.5)	15 (37.5)	40 (100)		
A-S stain	15 (37.5)	25 (62.5)	40 (100)	25 (62.5)	15 (37.5)	40 (100)		
AB-PAS	15 (37.5)	25 (62.5)	40 (100)	25 (62.5)	15 (37.5)	40 (100)		
PAP	15 (37.5)	25 (62.5)	40 (100)	25 (62.5)	15 (37.5)	40 (100)		
Gram	15 (37.5)	25 (62.5)	40 (100)	25 (62.5)	15 (37.5)	40 (100)		

H and E: Hematoxylin and eosin, D-H: Dane-Herman, A-S: Ayoub-shklar, AB-PAS: Alcian blue-periodic acid Schiff's, PAP: Papanicolaou

applied to histopathological or cytological preparations. Special stains for keratin are indicated to differentiate and emphasize small foci of abnormal keratinization.

Keratin is composed of insoluble proteins that in turn are made up of amino acids with high sulphhydryl and disulfide content, hence can be demonstrated by amino acid histochemical methods such as AB technique. Also, keratin can be demonstrated with Schiff's reagent, after oxidation with permanganate. The oxidation probably leads to the formation of a strong oxidant of small amounts of aldehyde groups from some of the keratin protein constituents. In the present study, instead of periodic acid, acidified permanganate solution was used for oxidation, which improved staining quality of the combined technique of AB and PAS.⁸ The combined technique of AB and PAS, stains the tissues containing both neutral and acidic mucins in varying shades of purple.^{5,10}

Keratins are also vividly stained red and orange to magenta shades respectively by phloxine, component of D-H method, and orange G dye, component of both A-S and PAP stain.^{5,11} Keratin, as well as keratohyline granules, are also moderately Gram-positive.⁵

In the present study, the sections of ortho and parakeratinized normal gingiva were equally distinguished by all the special stains when compared with H and E statistically. In relation to the individual cases, the keratin content of lumen as well as type of keratinized epithelia of orthokeratinized odontogenic cyst was better observed in D-H and A-S method (both the specificity and intensity was higher) than H and E. Similar observations were made with keratocystic odontogenic tumors.

The parakeratin plugging in verrucous carcinoma and the surface keratin patterns of squamous papilloma and verrucous hyperplasia was stained better with respect to intensity by D-H, A-S and AB -PAS, in turn, followed by PAP and Gram's stain but with respect to specificity the H and E stain was found to be a more suitable stain.

However not all the keratin pearls present in well-differentiated squamous cell carcinoma tissue sections could be stained positively by the special stains when compared with H and E, the possible explanation being that the keratin pearls stained positively with special stains would have undergone normal maturation process similar to physiologic keratin, whereas, the unstained keratin pearls might have certain unknown

biochemical differences in maturation process, rendering them less reactive to the special stains.⁶

Conclusion

In the present study, among all the special stains, D-H, A-S and AB-PAS demonstrated overall staining quality comparable to H and E, suggestive of their potential use as alternative stains for keratin. Also, all the special stains were able to successfully identify the type of keratinization and distinctly stain keratin distinguishing it from the other connective tissue components with a higher intensity, however, H and E showed a higher specificity on an overall basis.

References

1. Moll R, Divo M, Langbein L. The human keratins: Biology and pathology. *Histochem Cell Biol* 2008;129(6):705-33.
2. Bragulla HH, Homberger DG. Structure and functions of keratin proteins in simple, stratified, keratinized and cornified epithelia. *J Anat* 2009;214(4):516-59.
3. Nanci A. Ten Cate's Oral Histology: Development, Structure, and Function, 8th ed. Missouri, USA: Mosby Elsevier; 2012.
4. Shetty S, Gokul S. Keratinization and its disorders. *Oman Med J* 2012;27(5):348-57.
5. Bancroft JD, Gamble M. *Theory and Practice of Histological Techniques*, 6th ed. Philadelphia: Churchill Livingstone Elsevier; 2008.
6. Ramulu S, Kale AD, Hallikerimath S, Kotrashetti V. Comparing modified papanicolaou stain with ayoub-shklar and haematoxylin-eosin stain for demonstration of keratin in paraffin embedded tissue sections. *J Oral Maxillofac Pathol* 2013;17(1):23-30.
7. Dane ET, Herman DL. Haematoxylin-phloxine-Alcian blue-orange G differential staining of prekeratin, keratin and mucin. *Stain Technol* 1963;38:97-101.
8. Scott HR, Clayton BP. A comparison of the staining affinities of aldehyde fuchsin and the Schiff reagent. *J Histochem Cytochem* 1953;1(5):336-52.
9. Al-Maaini R, Bryant P. Honey as an alternative to formalin in the demonstration of connective tissue components. *J Histotechnol* 2008;31(2):67-72.
10. Prunieras M. PAB: A valuable stain for connective tissue, keratin and fungi. *J Invest Dermatol* 1960;35:309-14.
11. Carson FL, Christa H. *Histotechnology: A Self-Instructional Text*, 3rd ed. Hong Kong: American Society for Clinical Pathology; 2009.