

Review Article

Fat-removal orbital decompression for thyroid associated orbitopathy: The right procedure for the right patient



Eman Al-Sharif; Adel H. Alsuhaibani*

Abstract

Orbital decompression is an effective and invaluable procedure for addressing some of the chronic manifestations of Graves' Ophthalmopathy (GO) such as exophthalmos and orbital congestion. Fat-removal orbital decompression (FROD) started to gain popularity after its introduction in the late 20th century. Among the therapeutic armamentarium of techniques and approaches available for orbital decompression, FROD has proven its efficacy and safety in addition to its ability to reduce proptosis in a relatively predictable manner. In addition, postoperative complications occurring after FROD are generally considered to be less frequent and less serious compared to bone-removal orbital decompression (BROD). Nevertheless, despite of FROD's high benefit-to-risk ratio, proper selection of patients based on meticulous preoperative assessment, including imaging, is of paramount importance to achieve optimal functional and aesthetic results. Although up till now there is still no consensus regarding the procedure of choice in GO patients, FROD is an important option to consider in this subset of patients.

Keywords: Fat-removal orbital decompression (FROD), Bone-removal orbital decompression (BROD), Thyroid eye disease (TED), Graves' ophthalmopathy (GO), Proptosis

© 2017 The Authors. Production and hosting by Elsevier B.V. on behalf of Saudi Ophthalmological Society, King Saud University. This is an open access article under the CC BY-NC-ND license (<http://creativecommons.org/licenses/by-nc-nd/4.0/>). <http://dx.doi.org/10.1016/j.sjopt.2017.05.017>

Introduction

Thyroid Associated Orbitopathy (TAO) or Graves' Ophthalmopathy (GO) is a part of a chronic autoimmune inflammatory multisystemic disease which frequently affects the eye and surrounding orbital structures. Clinically significant GO develops in approximately 50% of patient with Graves' disease, with only 3–5% of patients developing the severe forms of the disease. Females are more commonly affected with TAO, yet, severe involvement is more common in elderly males.¹ Patients with GO may present a constellation of clinical ophthalmic manifestations including, but not limited to, proptosis/exophthalmos, lid retraction, periorbital edema, chemosis, strabismus and optic neuropathy.²

Pathogenesis

Throughout the past years, studies dedicated to understanding the etiology of GO revealed fundamental mechanisms behind this pathology. The disease starts with an acute inflammatory stage where there will be orbital infiltration by inflammatory cells, activation of fibroblasts with deposition of collagen and glycosaminoglycans (GAG) in orbital and periorbital tissues. Then, the fibrotic stage will follow resulting in scarring and fibrosis along with fat proliferation. These processes result in enlargement of the extraocular muscles, fat hypertrophy, and expansion of volume of orbital tissues. Subsequently, cosmetic and functional alterations develop such as forward protrusion of the eyeball

Received 17 April 2017; received in revised form 21 May 2017; accepted 29 May 2017; available online 14 June 2017.

Department of Ophthalmology, College of Medicine, King Saud University, Riyadh, Saudi Arabia

* Corresponding author at: Ophthalmology Department, College of Medicine, King Saud University, PO Box 245, Riyadh 11411, Saudi Arabia. Fax: +966 01 477 57 24.

e-mail address: adelsu@yahoo.com (A.H. Alsuhaibani).



Peer review under responsibility of Saudi Ophthalmological Society, King Saud University



Production and hosting by Elsevier

Access this article online: www.saudiophthaljournal.com www.sciencedirect.com

causing exophthalmos and eyelid retraction. In addition, there will be increase in the intraorbital pressure causing congestion and impedance of orbital venous outflow and restriction of extraocular motility leading to diplopia. Moreover, compressive optic neuropathy may develop in patients with severe forms of the disease.³⁻⁶

Treatment

Medical

Treatment of GO varies depending on the stage of the disease. Immunosuppressive corticosteroids, oral or intravenous pulses, are generally considered the first line therapy to control active disease. Orbital radiation may also be used solely or as an adjunct with steroids in patients with mild to moderate active disease.^{5,7,8}

Surgical

Surgical intervention, in the form of orbital decompression, is helpful in patients with severe acute disease with compressive optic neuropathy not responding to medical treatment. It is also effective in managing one of the chronic sequel of this disease, namely proptosis. In fact, previous studies have shown that facial disfigurement from proptosis in these patients may result in emotional distress and impairment of their psychosocial health and functioning.^{9,10} Nonetheless, improved quality of life scores and satisfaction with cosmetic results was reported in the majority of patients who underwent orbital decompression.¹¹

Following the introduction of orbital decompression by Dollinger in the early 20th century, numerous approaches and techniques were then described in the literature.⁵ Due to the lack of evidence supporting the use of one method over the other, surgeons are currently adopting the surgical method depending on their experience and the patient's individual condition.¹²

Surgical orbital decompression is usually required in minority of GO patients. The cumulative probability of undergoing surgery in GO patients is approximately 20% by 10 years.¹³ During the inactive stage of the disease, bone-removal orbital decompression (BROD) and/or fat-removal orbital decompression (FROD) is performed to cosmetically and functionally rehabilitate patients with exophthalmos, diplopia, orbital pain, orbital congestion and ocular hypertension.^{5,6,12}

FROD, as a sole procedure, gained popularity in the past few years among orbital surgeons. Hence, in this review, we will shed the light on the characteristics of this procedure together with a comparison between it and the well-known BROD.

Techniques of FROD versus BROD

The ultimate goal of orbital decompression in GO is to expand the orbital compartment to accommodate the pathologically enlarged muscles and fat. This can be achieved by the removal of orbital walls' bones or orbital fat (intraconal/extraconal) or a combination of both to enhance the desired outcome.

The techniques of BROD described in the scientific literature are abundant; yet, the extent of bony removal and approach (incision) varies depending on the patient's clinical presentation and the surgeon's experience.^{5,7} Decompressive techniques usually target the medial, lateral and inferior walls whereas the orbital roof should be avoided due to the potential serious complications.^{5,14}

In comparison, orbital fat decompression through intraorbital fat removal gained popularity among oculoplastic surgeons after Olivary re-introduced it in 1984.¹⁵ Thereafter, various studies concluded that transpalpebral or transconjunctival lipectomy reduced proptosis with little complications.^{12,16,17} Typically, the transconjunctival approach is employed and fat from the inferotemporal part of the orbit is excised using either a scissors or monopolar cautery.⁵ In our experience, we found that using the lower eyelid subciliary incision and then continuing the dissection in the preseptal plane all the way to the arcus marginalis followed by dissection between the orbital floor and the periosteum helps in reaching the inferotemporal fat behind the eyeball without the need to disturb the anterior orbital fat pads. Removal of inferotemporal fat behind the eyeball is very safe and effective in proptosis reduction. The degree of reduction is variable depending on the volume of the removed retrobulbar fat (Fig. 1). As a general rule, orbital fat removal from the inferotemporal part of the orbit will result in a 2 mm reduction in proptosis postoperatively compared to 2 mm for each wall in bone decompression.¹⁴ The superionasal fat pad can also be excised through a lid crease incision to further decrease proptosis by 0.5–1 mm.¹⁸

Advantages of fat-removal orbital decompression (FROD)

Studies evaluating the efficacy and safety of FROD showed that it is an effective and reliable procedure with good safety profile.^{6,16} Through their 20 years experience with a series of 3210 orbital fat decompressions, Richter and colleagues¹⁶ concluded that FROD doesn't only have a high-benefit/low-risk ratio, but it is also easy to perform in the hands of an experienced orbital surgeon. Serious life and vision threatening complications such as meningitis, CSF leak, vision loss, retrobulbar hemorrhage/hematoma, paresis and paresthesia of V1 and supraorbital nerve and sinusitis are rare or even non-existent in patients undergoing FROD.^{16,19}

The degree of exophthalmos can be reasonably decreased after undergoing FROD (Table 1).^{6,16,17,20-23} Since the intraorbital tissue is approximately 14 cc in volume, 40% volumetric lessening of retro-bulbar tissue can be achieved by resecting 6 cc of fat.²⁴ Several studies suggested that proptosis reduction usually correlates with the amount of resected fat.^{17,20,22} The Hertel exophthalmometry change after FROD can be predicted using an equation which considers the patient's age, gender and presence of preoperative diplopia.¹⁷ A recent study conducted by Liao and associates showed that the retro-bulbar volume change correlates considerably with the excised orbital fat volume and Hertel exophthalmometry change postoperatively.²² The authors proposed that orbital fat debulking causes volume reduction with subsequent proptosis reduction, though the reduction may vary where it is rationally expected to be greater in

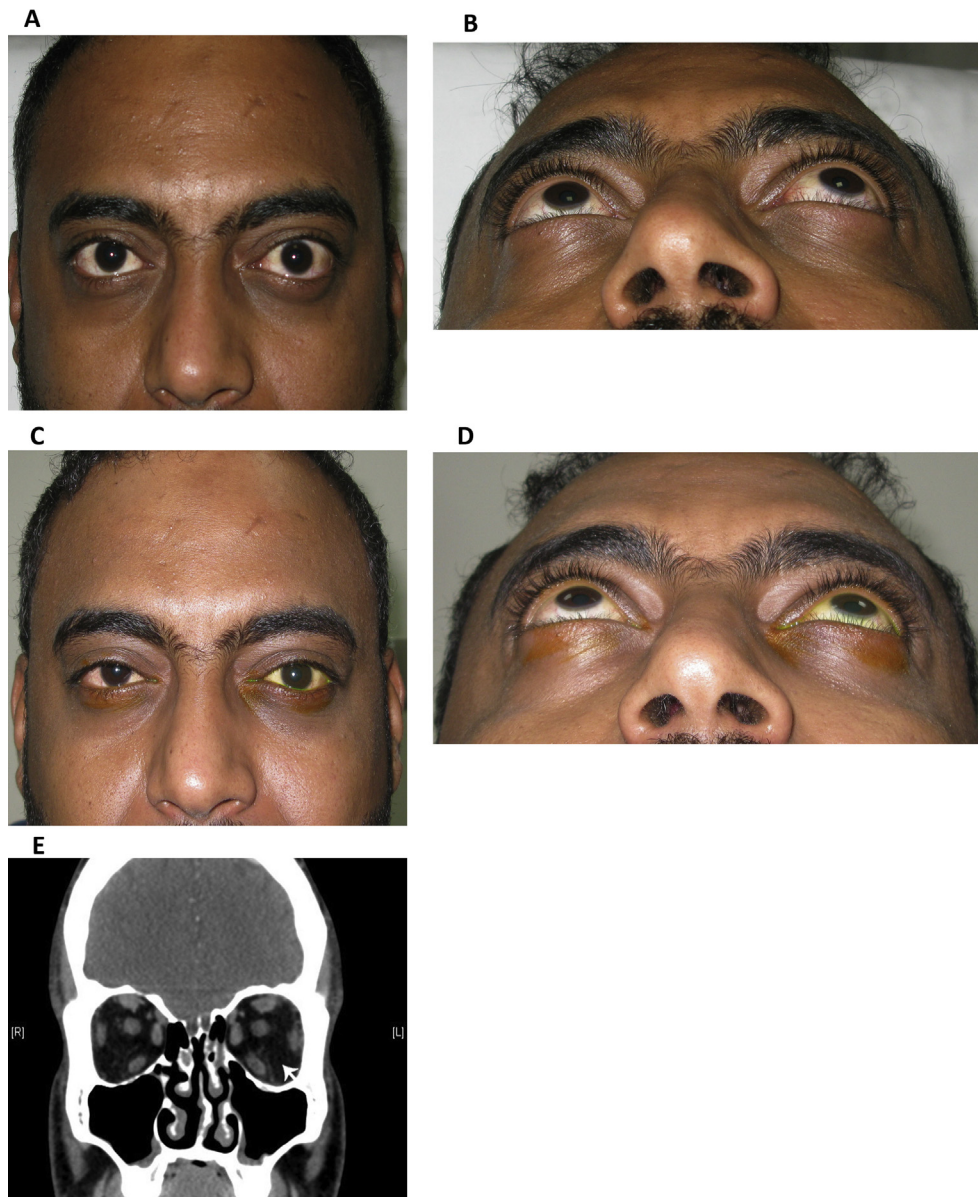


Figure 1. (A & B) A 33-year-old male with proptosis in the left eye more than the right eye due to Graves' Ophthalmopathy. (C & D) The same patient 6 months following fat-removal orbital decompression (FROD) for the left side showing improvement of proptosis of the left eye. (E) Coronal orbital computed tomography scan for the same patient (arrow indicating the area of orbital fat removed from the left orbit).

Table 1. Summary of some studies reporting results of FROD.

Authors	Year	Mean reduction of Hertel value (mm)	Mean volume of orbital fat removed (ml or cc)
Adenis et al. ²⁰	2003	4.7 ± 2.4	7.31 ± 1.9
Robert et al. ²¹	2006	4.4	6.4 ± 4.5
Richter et al. ¹⁶	2007	5.9	6.3
Wu et al. ¹⁷	2008	3.6 ± 1.0	3.6 ± 1.0
Liao and Huang ²²	2011	4.1 ± 0.9	4.4 ± 1.2
Chang et al. ²³	2012	4.4 ± 1.8	–
Li et al. ⁶	2015	4.2 ± 1.3	4.0 ± 1.1

GO patients with fat-predominant disease compared to those with muscle-predominant proptosis. It is noteworthy to mention that the proposed retro-bulbar volume change equation, derived from linear regression analysis, may have underestimated the true retro-bulbar volume change, as it didn't take into account the pre-equatorial fat volume.²²

To further highlight the benefits of FROD, a study evaluating the relationship between fat decompression and intraocular pressure showed a statistically significant decrease in IOP postoperatively.²¹ Furthermore, visual acuity improvement was noted after surgery in these patients.^{6,12} FROD conspicuously abolished the retro-bulbar pressure and head-

ache in more than two thirds of patients.¹⁶ This is explained by drop in intraorbital pressure with repositioning of the eye posteriorly, thus, decreasing traction on the optic nerve and venous engorgement.¹⁶ The rate of new-onset diplopia in GO patients postoperatively was found to be 20.2% ($n = 3210$ orbits) by Richter and colleagues.¹⁶ Recent studies showed more encouraging results with incidence rates as low as 2.8% ($n = 222$ orbits).¹⁷ Last but not least, almost all patients report momentous improvement in their cosmetic appearance, mental well-being and overall quality-of-life after surgery.¹⁶

Disadvantages and complications of fat-removal orbital decompression (FROD)

Looking at the shortcomings of FROD, regression of results and recurrence of proptosis was documented over a 3-years follow up period in 76.9% (10/13) of patients in a retrospective study. Authors attempted to explain this observation by proposing that this could be due to inadequate surgical removal of fat, postoperative fat regeneration and reactivation of the disease. The authors stated that proptosis reduction was maintained for a minimum of 1 year in these patients before regressing which suggests that adequate fat decompression was initially successfully met.²³ Fat regeneration or disease reactivation would provide a more reasonable explanation of this occurrence, although no conclusive results can be drawn out as postoperative imaging was not carried out in all these patients and the relatively short follow up period of 3 years might not have been adequate to clearly disclose a slow and mild subclinical recurrent inflammation. Interestingly, an earlier study demonstrated that fat volume intra-orbitally might continue to expand with aging.²⁵ This could be one of the reasons provoking or aggravating proptosis recurrence, although what opposes this theory is the fact that all patients will age but not all patients will regress. To the contrary, zero patients developed recurrent proptosis because of underlying fat hypertrophy in the 1374 patients described by Borumandi et al. hypothesized that the variability in proptosis reduction for a given surgical technique could be attributable to other factors as patient's orbital morphology, globe size, globe-orbital volume ratio and stiffness of orbital tissue.²⁶ Probably these individual related factors may also play a role in the recurrence of proptosis after FROD. Besides, FROD may not be adequate alone in patients with GO who may have significant extraocular muscle enlargement to achieve the desired reduction of proptosis, and thus, adjunctive BROD may be necessary in such cases.^{5,6,16} Further studies are still needed to identify the underlying causes and risk factors for regression.

Complications of FROD may occur in the early postoperative period and these usually require urgent medical intervention. In the large series of Richter and colleagues, 10 (0.7%) patients only developed retro-bulbar hematoma in which immediate revision was carried out. Infections developed in 12 (0.9%) cases that were also managed surgically in addition to systemic antibiotics. Supraorbital nerve paresis persisting more than 6 months developed in 19 (1.4%) patients because of iatrogenic contusion of the nerve.¹⁶ Additionally, one patient in a retrospective series of 11 patients developed early-onset presbyopia, which was thought to be a consequence of damage to the ciliary ganglion caused by traction during the surgery.⁶

Extraocular motility limitation may develop after FROD. New onset diplopia developed in 127 (28.9%) patients out of the 144 patients without preoperative diplopia and it lasted more than 6 months in 20.2% of patients after FROD in the series of Richter et al.¹⁶ Yet, further analysis revealed that the yearly incidence rate was lower ranging from 7.6% to 13.2% suggesting that the learning curve and growing surgical experience throughout the 20 years may have contributed to the this observation.¹⁶ Adenis et al. reported a new-onset diplopia rate of 32% after FROD whereas Wu et al. reported a rate of 2.8%.^{20,17} This discrepancy in diplopia rate may also be attributed to the different surgical approaches and amount of fat excised during surgery.¹⁷ It has been suggested that alteration of normal tissue planes during surgery stimulates the formation of adhesions between fat, extraocular muscles and periosteum. The resultant fat adherence syndrome may complicate future squint surgery whenever required.⁶

Fat-removal orbital decompression (FROD) VS bone-removal orbital decompression (BROD)

One of the major drawbacks to consider in BROD is its alteration of the normal anatomical build up and landmarks of the bony orbit. Perhaps not surprising, it is associated with a higher rate of complications compared to FROD, some of which may pose a threat on vision and life. Some of the reported complications are: partial or total vision loss, CSF leak, meningitis, hypoesthesia of V1 and/or V2, shifting in eye position and others.^{17,19,27,28} The incidence of surgically induced diplopia is generally less in patients undergoing FROD compared to BROD.^{17,23} Nonetheless, Garrity advocated that the type of diplopia occurring after FROD is more restrictive owing to the damage affecting intraorbital intermuscular septa, and hence, it is difficult to manage.²⁹

Proptosis reduction was comparable in patients undergoing FROD and BROD.^{16,17,21,23} Yet, the results were more predictable in FROD in comparison to the crude estimation

Table 2. Summary of comparison of FROD and BROD.

	FROD	BROD
Invasiveness of surgical procedure	Less invasive	More invasive
Occurrence of life-threatening and vision-threatening complications	Rare	More common
Reduction of proptosis	Comparable but depends on amount of resected fat	Comparable but depends on number of removed walls and whether combined with fat removal or not
New onset diplopia	Less common	More common
Regression	More common	Less common

FROD = fat removal orbital decompression; BROD = bone removal orbital decompression.

of proptosis reduction based on surgeon's experience in BROD.^{6,17,22} Regression was more likely to occur in patient who underwent fat excision alone as reported by Chang and colleagues.²³ A recent multivariate analysis looking at the risk factors and predictors of secondary decompression showed that fat removal along with bone removal was associated with decreased hazard for repeating decompression.³⁰ On the other hand, reports in the literature showed that both FROD and BROD restored vision quiet effectively in patients with DON.^{31-33,18,34} Table 2 provides a comparative summary of the pros and cons of both FROD and BROD.

Clauser and associates suggested the following algorithm for managing patients with GO: FROD is the surgery of choice when hertel values are up to 25–26 mm and imaging reveals fat-predominant expansion whilst those with muscle-predominant expansion (crowded apex syndrome) should undergo BROD. A combination of FROD and BROD

is conversely superior when exophthalmos exceeds 26 mm with hypertrophy of both fat and extraocular muscle components.³⁵

Other applications of FROD

FROD was reported to be beneficial in other conditions as well such as the treatment of orbital lymphangioma, globe retroplacement in patients planned for keratoprosthesis to decrease lagophthalmos, large eyeball and acquired epiblepharon.³⁶⁻³⁸ We found FROD to be a good procedure for people with facial asymmetry who are concerned because one eye is noticeably more prominent than the other eye (Fig. 2).

In conclusion, FROD, with its promising results, has proven to be an effective, reliable and safe procedure in patients with mild to moderate proptosis. Proper patient selection

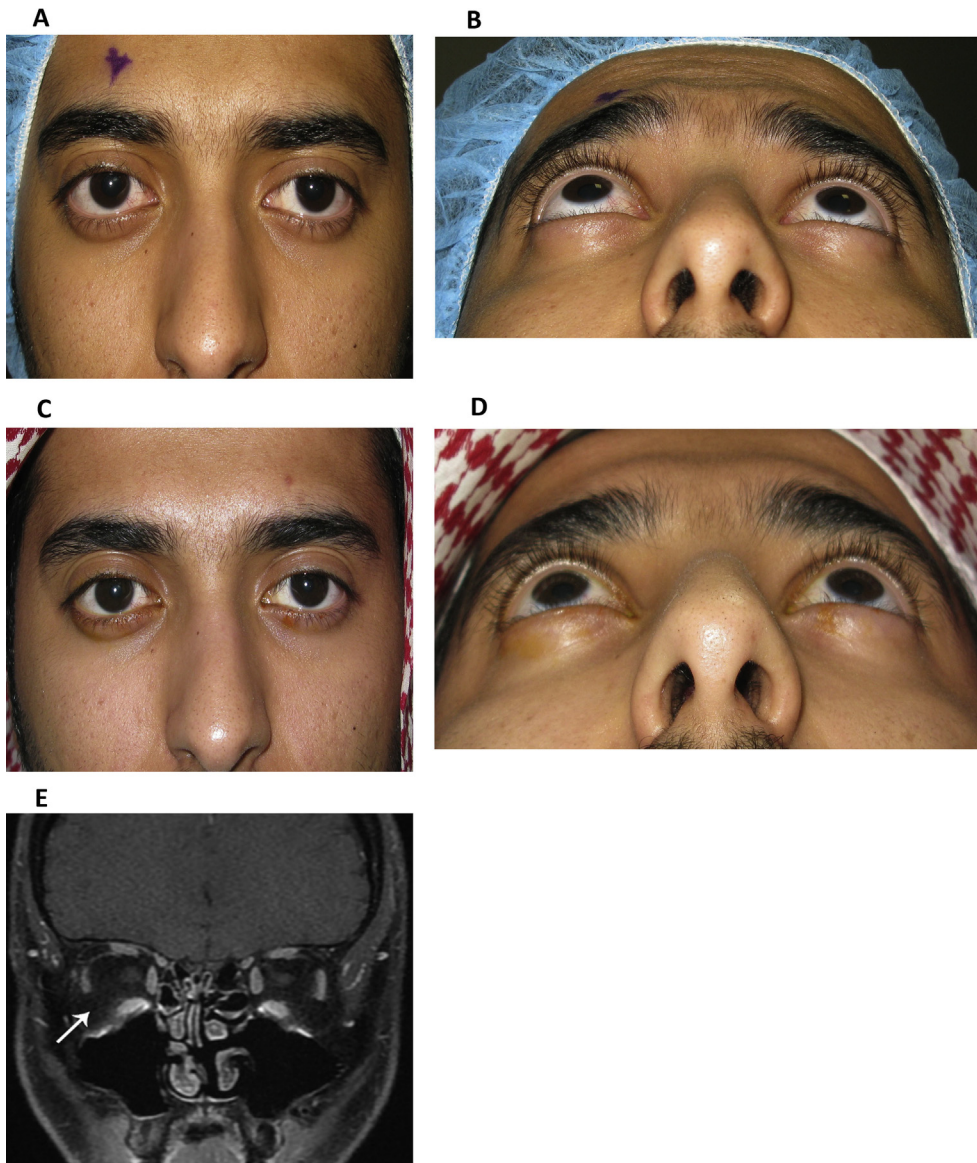


Figure 2. (A & B) A 22-year-old male with facial asymmetry concerned about the right eye being more prominent than the left eye for several years. There was no evidence of orbital pathology based on clinical and radiological evaluation. (C & D) The same patient 9 months following fat-removal orbital decompression (FROD) for the right side showing improvement in the prominence of the right eye. (E) Coronal orbital magnetic resonance imaging (T1) for the same patient (arrow indicating the area of orbital fat removed from the right orbit).

after meticulous preoperative assessment and imaging is a major factor in defining the success of surgery. However, how much fat can be removed and when to go for combined surgery remains a puzzling question that requires prospective randomized controlled trials for a definite answer.

Conflict of interest

The authors declared that there is no conflict of interest.

References

- Wiersinga WM, Bartalena L. Epidemiology and prevention of Graves' ophthalmopathy. *Thyroid* 2004;**12**(10):855–60.
- Bartley G, Fatourehchi V, Kadmas E, Jacobsen SJ, Ilstrup DM, Garrity JA, et al. Clinical features of Graves' ophthalmopathy in an incidence cohort. *Am J Ophthalmol* 1996;**121**:284–90.
- Bahn RS. Graves' ophthalmopathy. *N Engl J Med* 2010;**362**:726–38.
- Burch HB, Wartofsky L. Graves' ophthalmopathy: current concepts regarding pathogenesis and management. *Endocr Rev* 1993;**14**(4):747–93.
- Braun TL, Bhadkamkar MA, Jubbal KT, Weber AC, Marx DP. Orbital decompression for thyroid eye disease. *Semin Plast Surg* 2017;**31**(4):40–5.
- Li EY, Kwok TY, Cheng AC, et al. Fat-removal orbital decompression for disfiguring proptosis associated with Graves' ophthalmopathy: safety, efficacy and predictability of outcomes. *Int Ophthalmol* 2015;**35**(3):325–9.
- Kang S, Sa H. Current trends in the management of thyroid ophthalmopathy. *Hanyang Med Rev* 2016;**36**(3):186–91.
- Zang S, Ponto KA, Kahaly GJ. Clinical review: intravenous glucocorticoids for Graves' orbitopathy: efficacy and morbidity. *J Clin Endocrinol Metab* 2011;**96**(2):320–32.
- Yeatts RP. Quality of life in patients with graves ophthalmopathy. *Trans Am Ophthalmol Soc* 2005;**103**:368–411.
- Estcourt S, Quinn AG, Vaidya B. Quality of life in thyroid eye disease: impact of quality of care. *Eur J Endocrinol* 2011;**164**:649–55.
- Tehrani M, Krummenauer F, Mann WJ, Pitz S, Dick HB, Kahaly GJ. Disease-specific assessment of quality of life after decompression surgery for Graves' ophthalmopathy. *Eur J Ophthalmol* 2004;**14**(1):193–9.
- Boboridis KG, Uddin J, Mikropoulos DG, Bunce C, Mangouritsas G, Voudouragkaki IC, et al. Critical appraisal on orbital decompression for thyroid eye disease: a systematic review and literature search. *Adv Ther* 2015;**32**(7):595–611.
- Bartley GB, Fatourehchi V, Kadmas EF, Jacobsen SJ, Ilstrup DM, Garrity JA, et al. The treatment of graves' ophthalmopathy in an incidence cohort. *Am J Ophthalmol* 1996;**121**(2):200–6.
- Naik MN, Nair AG, Gupta A, Kamal S. Minimally invasive surgery for thyroid eye disease. *Indian J Ophthalmol* 2015;**63**(11):847–53.
- Olivari N. Transpalpebral decompression of endocrine ophthalmopathy (Graves' disease) by removal of intraorbital fat: experience with 147 operations over 5 years. *Plast Reconstr Surg* 1991;**87**(4):627–41.
- Richter DF, Stoff A, Olivari N. Transpalpebral decompression of endocrine ophthalmopathy by intraorbital fat removal (Olivari technique): experience and progression after more than 3000 operations over 20 years. *Plast Reconstr Surg* 2007;**120**(1):109–23.
- Wu CH, Chang TC, Liao SL. Results and predictability of fat-removal orbital decompression for disfiguring graves exophthalmos in an Asian patient population. *Am J Ophthalmol* 2008;**145**(4):755–9.
- Prat MC, Braunstein AL, Dagi Glass LR, Kazim M. Orbital fat decompression for thyroid eye disease: retrospective case review and criteria for optimal case selection. *Ophthalm Plast Reconstr Surg* 2015;**31**(3):215–8.
- Sellari-Franceschini S, Dallan I, Bajraktari A, Fiacchini G, Nardi M, Rocchi R, et al. Surgical complications in orbital decompression for Graves' orbitopathy. *Acta Otorhinolaryngol Ital* 2016;**36**(4):265–74.
- Adenis JP, Camezind P, Robert PY. Is incidence of diplopia after Fat Removal Orbital Decompression a predictive factor of choice of surgical technique for Graves' ophthalmopathy? *Bull Acad Natl Med* 2003;**187**(9):1649–58, 1649–58;1659–60.
- Robert PY, Rivas M, Camezind P, Rulfi JY, Adenis JP. Decrease of intraocular pressure after fat-removal orbital decompression in Graves disease. *Ophthalm Plast Reconstr Surg* 2006;**22**(2):92–5.
- Liao SL, Huang SW. Correlation of retrobulbar volume change with resected orbital fat volume and proptosis reduction after fatty decompression for Graves ophthalmopathy. *Am J Ophthalmol* 2011;**151**(3):465–9.
- Chang M, Baek S, Lee TS. Long-term outcomes of unilateral orbital fat decompression for thyroid eye disease. *Graefes Arch Clin Exp Ophthalmol* 2013;**251**(3):935–9.
- Olivari N. Endocrine ophthalmopathy: surgical treatment. *HNO* 2010;**58**(1):8–10. <http://dx.doi.org/10.1007/s00106-009-2025-x>.
- Lee JM, Lee H, Park M, Lee TE, Lee YH, Baek S. The volumetric change of orbital fat with age in Asians. *Ann Plast Surg* 2011;**66**:192–5.
- Borumandi F, Hammer B, Kamer L, von Arx G. How predictable is exophthalmos reduction in Graves' orbitopathy? A review of the literature. *Br J Ophthalmol* 2011;**95**(12):1625–30. <http://dx.doi.org/10.1136/bjo.2010.181313>.
- McCormick CD, Bearden WH, hunts JH, Anderson RL. Cerebral vasospasm and ischemia after orbital decompression for graves ophthalmopathy. *Ophthalm Plast Reconstr Surg* 2004;**20**:347–51.
- Alsuhaibani AH, Carter KD, Policeni B, Nerad JA. Orbital volume and eye position changes after balanced orbital decompression. *Ophthalm Plast Reconstr Surg* 2011;**27**(3):158–63.
- Garrity JA. Orbital lipectomy (fat decompression) for thyroid eye disease: an operation for everyone? *Am J Ophthalmol* 2011;**151**(4):399–400.
- Wu CY, Niziol LM, Musch DC, Kahana A. Thyroid-related orbital decompression surgery: a multivariate analysis of risk factors and outcomes. *Ophthalm Plast Reconstr Surg* 2017;**33**(3):189–95.
- Korkmaz S, Konuk O. Surgical treatment of dysthyroid optic neuropathy: long-term visual outcomes with comparison of 2-wall versus 3-wall orbital decompression. *Curr Eye Res* 2016;**41**(1):159–64.
- Miśkiewicz P, Rutkowska B, Jabłońska A, Krzeski A, Trautsołt-Jeziorska K, Kęćik D, et al. Complete recovery of visual acuity as the main goal of treatment in patients with dysthyroid optic neuropathy. *Endokrynol Pol* 2016;**67**(2):166–73.
- Kazim M, Trokel SL, Acaroglu G, Elliott A. Reversal of dysthyroid optic neuropathy following orbital fat decompression. *Br J Ophthalmol* 2000;**84**(6):600–5.
- Clauser LC, Tieghi R, Galiè M, Franco F, Carinci F. Surgical decompression in endocrine orbitopathy. Visual evoked potential evaluation and effect on the optic nerve. *J Craniomaxillofac Surg* 2012;**40**(7):621–5.
- Clauser LC, Galiè M, Tieghi R, Carinci F. Endocrine orbitopathy: 11 years retrospective study and review of 102 patients & 196 orbits. *J Craniomaxillofac Surg* 2012;**40**(2):134–41.
- Lee JK, Lee TS. Orbital lymphangioma treated by lateral wall decompression and fat removal. *Jpn J Ophthalmol* 2010;**54**(2):174–5.
- Norris JH, Carpenter D, Al Raqqad N, Brittain P, Daya S, Liu C, et al. Indications for orbital decompression for patients undergoing keratoprosthesis surgery. *Ophthalm Plast Reconstr Surg* 2012;**28**(4):346–9.
- Almoussa R, Sundar G. Acquired epiblepharon treated by lateral orbital and fat decompression. *Middle East Afr J Ophthalmol* 2011;**18**(1):80–1.