




# Microvascular Decompression versus Radiofrequency Ablation in Trigeminal Neuralgia of the Maxillary and Mandibular Divisions

Hosam-Eldin Abdel-Azim Habib<sup>1</sup>  Mohamed Hamdy Ellakany<sup>2</sup> Hossam Elnoamany<sup>1</sup>  
Ahmed Gabry Elnaggar<sup>1</sup>

<sup>1</sup>Neurosurgery Department, Faculty of Medicine, Menoufia University, Menoufia, Egypt

<sup>2</sup>Anesthesia and Pain Management Department, Medical Research Institute, Alexandria University, Alexandria, Egypt

Address for correspondence Hosam Abdel Azim Habib, MD, Neurosurgical Department, Faculty of Medicine, Menoufia University, Dr Yassin Abdel Gafar St., Shebin Elkom, Menoufia, Egypt 32511 (e-mail: hosamhabib@gmail.com; hosam.habib@med.menoufia.edu.eg).

Asian J Neurosurg 2024;19:221–227.

## Abstract

**Background** Although medical treatment is the mainstay of therapy, in trigeminal neuralgia (TN), patients failing to respond to it make them candidates to ablative or nonablative procedures.

**Objective** The aim of this study was to compare the outcome of Microvascular decompression (MVD) and radiofrequency (RF) thermocoagulation in the management of TN affecting the mandibular and maxillary divisions.

**Materials and Methods** Retrospective analysis of the data of 40 patients suffering from intractable classical TN affecting the maxillary or mandibular divisions or both was carried out. Twenty patients were operated upon by MVD of the trigeminal nerve; and 20 had RF ablation of the maxillary or mandibular divisions of the trigeminal nerve or both.

**Results** In MVD the overall successful outcome was achieved in 16 patients (80%), while the failure was in 4 patients (20%) of which 3 had a fair outcome and 1 patient had a poor outcome. Whereas in RF the overall successful outcome was achieved in 17 patients (85%), while the failure was in 3 patients (15%) of which 2 had a fair outcome and 1 patient had a poor outcome. Outcome was insignificantly different between both groups ( $p$ -value 0.806).

**Conclusion** MVD and RF ablation represent safe and efficacious surgical choices for addressing TN that encompasses both the mandibular and maxillary divisions. Long-term follow-up studies demonstrate that MVD consistently yields favorable outcomes, establishing it as the preferred primary surgical technique, unless contraindicated by the patient's general health and specific needs.

## Keywords

- ▶ trigeminal
- ▶ neuralgia
- ▶ microvascular
- ▶ decompression
- ▶ radiofrequency

## Introduction

Trigeminal neuralgia (TN) that was once called the “suicide disease” is a form of neuropathic pain affecting the face and

has a remarkably consistent clinical picture including severe (usually unilateral), lancinating, paroxysmal electric shock-like pain, occurring in the territories of one or more of the divisions of the trigeminal nerve (TGN). It is usually

article published online  
May 27, 2024

DOI <https://doi.org/10.1055/s-0044-1779516>.  
ISSN 2248-9614.

© 2024. Asian Congress of Neurological Surgeons. All rights reserved.

This is an open access article published by Thieme under the terms of the Creative Commons Attribution-NonDerivative-NonCommercial-License, permitting copying and reproduction so long as the original work is given appropriate credit. Contents may not be used for commercial purposes, or adapted, remixed, transformed or built upon. (<https://creativecommons.org/licenses/by-nc-nd/4.0/>)

Thieme Medical and Scientific Publishers Pvt. Ltd., A-12, 2nd Floor, Sector 2, Noida-201301 UP, India

associated with fear, anxiety, depression, and in severe cases suicidal tendencies. Pain severely alters the patient's physical and mental status and impairs his daily functions.<sup>1,2</sup>

The pathogenesis of TN has remained elusive. Demyelination of the nerve by vascular compression at the root entry zone of the brainstem has been proposed as the principal factor involved in the genesis of TN. Compressive damage to the nerve fibers is hypothesized to cause hyperexcitability, allowing for impulses traveling in A $\beta$  touch fibers to be abnormally transmitted by nociceptive C fibers (ephaptic transmission).<sup>3-5</sup>

Recently, hyperactivity of the trigeminal nuclei has been implicated in addition to the vascular compression, based on the absence of compressive arteries in some patients during exploratory posterior fossa surgeries, as well as the absence of the history of TN prior to death in cadaveric studies which revealed an intimate relationship between arteries and the cranial nerves.<sup>3-5</sup> All the patients suffering from TN seek treatment aiming to achieve a sustained pain relief and improvement of their life quality. Pharmacological treatment should be the first-line treatment of TN, and only when it fails to control the pain, or when side effects set in, are the patients offered surgical options. Medical treatment includes the use of antiepileptic drugs mainly carbamazepine or oxcarbazepine to modulate the pain and ameliorate symptoms, but their side effects may be debilitating by themselves to the extent of affecting the patient's quality of life. In addition, in a considerable number of patients the pain control provided by these medication wanes with time, rendering them ineffective.<sup>6</sup>

Surgical treatments can be ablative (destructive) or non-ablative. The surgeries are performed at different levels of the TGN trigger points, Gasserian ganglion, or root entry zone in the posterior fossa. The procedures done at the trigger points or Gasserian ganglion are destructive procedures, as the TGN sensory function is intentionally destroyed, whereas procedures directed to the root entry zone as microvascular decompressive (MVD) procedures preserve the nerve's normal function. The destructive procedures include percutaneous radiofrequency (RF) thermocoagulation, Gasserian ganglion balloon compression, and glycerol or absolute alcohol rhizolysis.<sup>1,6</sup>

Gamma Knife radiosurgery (GKR) is another viable option for TN, whether as a primary or a secondary treatment. The mechanism of pain relief after GKR remains unclear. However, it seems that GKR diffusely damages all axons of the TGN, raising the pain thresholds, which means that pain sensation is not conveyed.<sup>7</sup>

Gasserian ganglion therapies are considered minor procedures but are associated with a high rate of recurrence and possible ophthalmological complications if the fibers of the ophthalmic division are injured. MVD, on the other hand, is a major neurosurgical procedure that carries risks of complications, either in the immediate perioperative period or in the long term and has been associated with a small risk of mortality.<sup>1,6</sup>

Although TN is not a life-threatening condition, the intensity of pain associated with it may be so distressing to the patient to the extent of warranting the application of the previously mentioned procedures despite their associated

risks, especially if the patient is not tolerating the cost and side effects of medical treatment.<sup>6</sup>

Throughout the literature MVD is the best surgical intervention for the treatment of TN as it optimizes outcome while minimizing recurrence rates.<sup>6,8,9</sup> Challenges, such as lack of tools, patient refusal, or medical unfitness for intracranial procedures, may necessitate alternative approaches to this ideal technique. Thus, was the decision to explore the alternative technique of RF which became available to the authors in the past 3 years, when met by such challenges.

## Objectives

To compare the outcome of MVD and percutaneous RF in the management of TN of the maxillary and mandibular divisions

## Patients and Methods

Retrospective analysis of the data of 40 patients that were admitted to the Neurosurgical Department of Menoufia University and Anesthesia and Pain Management Department of the Medical Research Institute of Alexandria University, suffering from intractable classical TN affecting the maxillary or mandibular divisions or both was carried out. Twenty patients were operated upon by MVD of the TGN, and 20 had RF ablation of the maxillary or mandibular divisions of the TGN or both. For each group the data incorporated in the study was that of 20 consecutive patients meeting the inclusion criteria, starting from the earliest available records, from the year 2013 to 2022.

Criteria for RF:

(1) Inclusion criteria:

- Classical TN patients showing minimal or no pain relief after adequate dose and duration of medication or those unable to tolerate the medications or their side effects; as well as patients medically unfit for MVD surgery or refusing it.

(2) Exclusion criteria:

- Recurrent cases of TN and patients suffering from other demyelinating disease were excluded from the study; additionally patients with neuralgia affecting the ophthalmic division were excluded for fear of occurrence of corneal anesthesia.

Criteria for MVD:

(1) Inclusion criteria:

- Classical TN patients showing minimal or no pain relief after adequate dose and duration of medication or those unable to tolerate the medications or their side effects.

(2) Exclusion criteria:

- Exclusion criteria are similar to those for RF, but patients with affection of the ophthalmic division

were not included in this study for the sake of comparison with RF as these patients are not candidates for RF.

Magnetic resonance imaging (MRI) was ordered for all patients to detect any vascular loops compressing the TGN and to exclude other possible pathologies. But the absence of MRI evidence of vascular loops or compression did not exclude the patient from posterior fossa exploratory surgery.

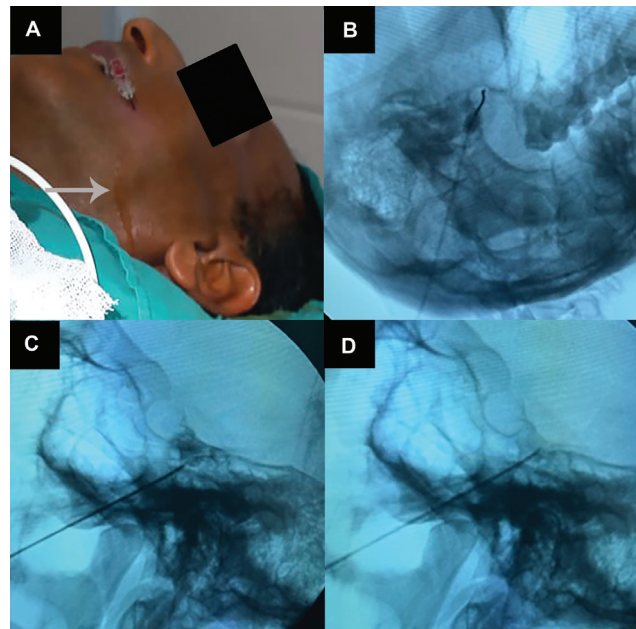
MVD surgery was performed through a posterior fossa retrosigmoid approach in a three-quarter prone position. After the craniotomy was performed the dura was opened and the cerebellopontine angle was explored exposing the whole length of the TGN from its exit from the Meckel's cave to its entry zone in the brainstem; this step sometimes necessitated division of the superior petrosal vein for adequate exposure.

Meticulous atraumatic dissection of the nerve to free it from any arachnoid filaments was performed; to detect any vascular compression of the nerve, whether arterial or venous. When a compressing vessel was found, it was adequately dissected away from the nerve followed by insertion of interposing material between the two structures; in case of venous compression, the vein was coagulated and divided without the use of Teflon.

RF cases were all operated upon in the supine position under general intravenous anesthesia, sterilization of the face was performed, and drabs were applied, then local infiltration with Xylocaine 2% was done at the site of needle insertion which is generally located 3 cm lateral to oral fissure. Under fluoroscopic control the foremen ovale is localized in a mento-occipital view (rotating C-arm with 15–25 degrees in the coronal plane and 20–30 degrees in the sagittal plane also called oblique submental view) after which an active 5-mm curved tip, 22-gauge, 15 cm RF needle (Cosman; Cosman Medical, Burlington, Massachusetts, United States) is inserted guided to the lateral wall of the foramen, and once engaged the stilette is removed to detect cerebrospinal fluid egress, at this point the C-arm is repositioned to achieve lateral views to assess the needle depth for proper positioning which is the petroclival junction and 5 mm anterior to plane of the clivus for the mandibular and at the clivus for the maxillary division (► Fig. 1). At this point the patients are awakened to perform sensory stimulation, which is first applied at 50 Hz starting at 0.3 to 0.5 volts to detect sensory stimulation of the affected area and motor stimulation at 2 Hz, 0.1 ms, 0.1 to 0.3 volts. Once the patient reports of paresthesia and/or twitching in response to the stimulation in the affected dermatome, the parameters of radiofrequency (RFT) were set to 70°C.

The outcome was regarded as:

- Excellent: if the patient became pain-free and off medication.
- Good: if the patient became pain-free but at times needing medications, but without the medication side effects (all were medically intractable preoperatively).
- Fair: if the patient requires medications but has breakthrough pain or side effects from the medication.



**Fig. 1** Male patient, 53 years old, presented with trigeminal neuralgia of the mandibular and maxillary divisions. (A) After needle insertion through the foramen oval, stilette is removed to detect cerebrospinal fluid (CSF) egress. (B) Oblique submental view showing the radiofrequency (RF) needle in the foremen ovale. (C) Lateral fluoroscopic view showing the needle placed 5 mm anterior to the clivus for mandibular RF. (D) Lateral fluoroscopic view showing the needle placed at the clivus for maxillary RF.

- Poor: if still with pain.

Excellent and good results are considered as successes, while fair and poor results are considered as failures.

## Statistical Analysis

Statistical analysis was done by SPSS v27 (IBM, Armonk, New York, United States). Shapiro–Wilk test and histograms were used to evaluate the normality of the distribution of data. Quantitative parametric data were presented as mean and standard deviation and were analyzed by unpaired Student's *t*-test. Qualitative variables were presented as frequency and percentage (%) and analyzed using the chi-square test. Correlation between various variables was done using Spearman rank correlation equation for nonnormal variables/nonlinear monotonic relation. A two-tailed *p*-value of < 0.05 was considered statistically significant.

## Results

Age, sex, radiological evidence, side of affection, and division of TGN affected were insignificantly different between both groups. Preoperative medical treatment duration was significantly higher in the microvascular group than the pulsed group (*p*-value 0.010) (► Table 1). Follow-up duration was significantly higher in the microvascular group than the pulsed group (*p*-value < 0.001) (► Table 1).

As regards the MVD patients, the superior cerebellar artery (SCA) was the sole offending vessel in 13 patients

**Table 1** Demographic and topographic distribution of the studied groups

		MVD group (n = 20)	RF group (n = 20)	p-Value
Age (y)		48.85 ± 10.8 (range 29–67)	50.15 ± 14.83 (range 22–76)	0.753
Sex	Male	5 (25%)	7 (35%)	0.490
	Female	15 (75%)	13 (65%)	
Radiological evidence	Positive	13 (65%)	11 (55%)	0.519
	Negative	7 (35%)	9 (45%)	
Medical treatment duration (mo)		29.15 ± 12.43	19.7 ± 9.54	0.010
Side of affection	Right	6 (30%)	10 (50%)	0.197
	Left	14 (70%)	10 (50%)	
Division of trigeminal nerve affected	V2	4 (20%)	5 (25%)	0.817
	V3	12 (60%)	10 (50%)	
	V2 + V3	4 (20%)	5 (25%)	
Follow-up (mo)		38.45 ± 6.04 (range 30–48)	15.75 ± 7.0 (range 6–30)	< 0.001

Abbreviations: MVD, microvascular decompression; RF, radiofrequency.

Note: Data are presented as mean ± standard deviation (SD) or frequency (%).

**Table 2** Offending vessel of microvascular group

	MVD group (n = 20)
SCA	13 (65%)
AICA	3 (15%)
Petrosal vein	1 (5%)
SCA and vein	1 (5%)
No definite compressive	2 (10%)

Abbreviations: AICA, anterior inferior cerebellar artery; MVD, microvascular decompression; SCA, superior cerebellar artery.

(65%) while the anterior inferior cerebellar artery (AICA) compression was detected in 3 patients (15%) (► **Table 2**). Nine of the patients with arterial compression had an excellent outcome of which six were recognized in the preoperative imaging.

In two patients (10%) no definite compressing vessel was detected, so only complete removal of the arachnoid filaments was done, with one patient reporting a fair outcome and the second reported a poor outcome and developed tinnitus and mild sensory neural hearing loss (SNHL) (► **Table 2**).

Pure venous compression was detected in one patient (5%) by a tributary of the superior petrosal vein in the cisternal portion of the TGN that was coagulated and divided with no postoperative sequelae and a good outcome (► **Table 2**).

Another patient had multiple vascular compressions by both the SCA and superior petrosal vein, both compression sites were decompressed with the patient achieving an excellent outcome.

In MVD the overall successful outcome was achieved in 16 patients (80%), while the failure was reported in 4

**Table 3** Follow-up and outcome of the studied groups

	MVD group (n = 20)	RF group (n = 20)	p-Value
<b>Outcome</b>			
Excellent	7 (35%)	10 (50%)	0.806
Good	9 (45%)	7 (35%)	
Fair	3 (15%)	2 (10%)	
Poor	1 (5%)	1 (5%)	

Abbreviations: MVD, microvascular decompression; RF, radiofrequency.  
Note: Data are presented as frequency (%).

patients (20%) of which 3 had a fair outcome and 1 patient had a poor outcome (► **Table 3**). Whereas in RF the overall successful outcome was achieved in 17 patients (85%), while the failure was reported 3 patients (15%) of which 2 had a fair outcome and 1 patient had a poor outcome. Outcome was insignificantly different between both groups (*p*-value 0.806).

Complication rate was insignificantly different (*p*-value 0.131) between both groups. In MVD complications were observed in 2 patients (10%), in the form of a patient that developed a pseudomeningocele that was managed conservatively. The second was the previously mentioned patient that had persistent tinnitus and mild SNHL.

In RF the most common complication was paresthesia, which was observed in six patients (30%), followed by masseter weakness that was observed in four patients (20%). The paresthesia was transient and improved in five patients. In those who developed weakness, three had RF of the mandibular division, while the fourth patient developed weakness despite targeting the maxillary division alone. The weakness was transient in three patients, while the fourth case had persistent

weakness as well as severe persistent paresthesia and reported a final poor outcome; worth mentioning is that this patient was the second patient in our experience with RF for TN. There was no correlation between division of TGN affected and complications (correlation coefficient  $-0.245$ ,  $p$ -value  $0.127$ ).

## Discussion

Initially, TN was managed through targeting the preganglionic fibers of the TGN in the middle cranial fossa, it was then that Dandy first described his observation of vascular loops compression of the TGN at the root entry zone. It was not till the advent of the operative microscope that Peter Jannetta in 1967 was able to confirm this theory of vascular compression and introduced MVD.<sup>1</sup>

Alcohol injection of the Gasserian ganglion was introduced early in the twentieth century, following that in 1981, Håkason introduced glycerol as an alternative chemoneurolytic technique capable of producing pain relief. In 1932, Kirschner used crude monopolar electrocoagulation for TGN lesioning; four decades later in 1974, Sweet and Wepsic, utilized the more precise RF current to produce controlled thermocoagulation of the nerve, which continues to be employed successfully to this day.<sup>7-13</sup>

The key to a successful MVD is adequate exposure of the TGN throughout its course. At times it is difficult to visualize the medial side of the root entry zone, missing the offending vessel which is the main reason for MVD failure. Other identified causes of failure were the use of unshredded Teflon patch (which may be easily dislodged), free muscle grafts (that may get resorbed), and nerve compression by the excessive use of Teflon.<sup>4</sup>

If the compression originated from the SCA, Sindou et al opted to elevate the SCA using a Teflon sling instead of simply placing Teflon in between, as they were concerned about the nerve being compressed by the Teflon. On the other hand, if the offending vessel was the AICA, they performed a straightforward transposition of the loop away from the nerve to prevent damage to the short perforators to the brainstem and the labyrinthine artery originating from the AICA. Veins that were indenting the nerve were sacrificed in their series.<sup>14</sup> In our study, we inserted interposing material for arterial compression. One patient in our study had sole venous compression and in a second patient a vein in addition to SCA, and these veins were divided without any resulting complications.

Despite the lack of preoperative MRI evidence of neurovascular compression (NVC) in seven patients in the current study, NVC was detected during surgical exploration in all cases except two. This finding aligns with the study conducted by Jo et al, which revealed the presence of NVC in 53.2% of patients intraoperatively, even though their presurgical MRI results were negative. The study concluded that the absence of positive MRI findings does not indicate long-term failure of MVD for TN. However, the presence of positive MRI findings predicts long-term success. Additionally, Jo et al discovered that compression caused by a vein alone or a

combination of venous compression was a poor prognostic factor for achieving success in MVD.<sup>13</sup>

Recently, numerous studies have provided confirmation that the utilization of high-resolution MRI with diverse data acquisition techniques has proven to be reliable for detecting NVC, detecting the atrophic changes in TN, and predicting the extent of compression on the nerve root. Furthermore, these studies have established a correlation between the degree of root compression and the resulting outcome.<sup>12,15-18</sup>

Although the success rate of this study was similar to that conducted by Sindou et al, where they achieved an 80% success rate in treating patients, but actually they adhered to more strict parameters, where they considered an outcome successful only if complete pain relief and complete discontinuation of medication were achieved. Additionally, 4.9% of their patients had some residual background pain but did not require medication, while 15.1% of the patients experienced treatment failure.<sup>14</sup>

When treating TN with involvement of the first division, MVD, glycerol rhizotomy, and Gasserian balloon compression are considered the procedures of choice. This choice is due to their lower likelihood of causing corneal anesthesia, which has been observed when RF is applied in such cases, potentially leading to neurotrophic keratitis. However, it should be noted that both glycerol rhizotomy and balloon compression have higher recurrence rates compared to MVD.<sup>19,20</sup>

Hong et al recommended using temperatures between 65°C and 70°C when targeting the maxillary and/or mandibular divisions, to achieve effective pain control and minimizing permanent complication including masseter weakness and facial.<sup>21</sup>

In a retrospective study conducted by Tronnier et al, involving 225 patients who underwent MVD and 206 patients who underwent percutaneous RF rhizotomy, it was found that there was a 50% risk of pain recurrence within 2 years after RF rhizotomy. In contrast, among MVD patients, 64% remained completely free of pain for up to 20 years following the surgery.<sup>22</sup>

Several reviews have thoroughly examined various percutaneous modalities used in the treatment of TN. These reviews consistently emphasize that percutaneous procedures offer excellent alternatives to MVD. RF treatment has shown a commendably low complication rate, comparable to other percutaneous techniques.<sup>6,17,20-24</sup> Despite this, since its introduction in 1974 by Sweet and Wepsic, with its extensive application in TN, and improvement of RF generators and parameters used, an immediate pain relief was reported to be as high as 85 to 97% by more recent studies.<sup>11,25-27</sup>

MVD is not a minor procedure and its application in elderly patients has been always a concern, but recently published series in older age groups indicate that the decision to recommend MVD should be based upon the patient's fitness rather than his age.<sup>28,29</sup>

But in this study elderly patients more readily choose RF rather than MVD, although they were informed that MVD had the lowest recurrence rates at long-term follow-up and

was considered to be the best option for young healthy patients.<sup>22,30</sup>

All the MVD patients of this study were operated at time period prior to those of RF, a shift due to the lack of availability of Teflon, and this explains the significantly lengthier follow-up duration. But the lengthier preoperative medication duration for MVD was attributed to the patients' fear from being subjected to an open cranial procedure, which delayed the intervention until the pain was unbearable, which was not the case with RF.

In their systematic review of the efficacy and safety of percutaneous approaches in the management of TN, Tekalikidis et al emphasized that when solely targeting the maxillary division,<sup>31</sup> it was difficult to contain the thermo-coagulatory damage from reaching the ophthalmic or mandibular divisions and its real-time detection.<sup>31-33</sup>

Tang et al in their study, which enrolled older patients above 70 years of age, reported an excellent pain relief in all their patients at discharge, with 49% maintaining pain relief even after 10 years.<sup>34</sup>

Zhao et al in their RF series of 1,070 patients reported a pain-free rate in 70.2% of the patients at 10 years and reported that patients prone to long-term pain recurrence are those having initial poor response to medications, patients with atypical facial pain, and patients with previous facial numbness. The most common complication in their study was ipsilateral facial numbness reported in approximately 77% of the patients with 5.4% suffering troublesome dysesthesia. They also documented the higher incidence of severe complications including troublesome dysesthesia, keratitis, and masseter weakness was higher when temperature of 80°C was used.<sup>27</sup> In this study, the temperature used for RF was 70°C but we did have patients having masseter weakness and dysesthesia, but most of them had a complete recovery. Yao et al recommended RF at 68°C is for treating V2/V3 and that RF may be performed at 62 to 65°C if the patients wish to minimize possible complications such as facial numbness.<sup>32</sup>

It is generally agreed that MVD provides the longest duration of pain relief while preserving facial sensation. Although major complications may follow MVD (including severe gait disturbances due to cerebellar brainstem ischemia related to vascular spasm from manipulation, trochlear nerve palsy, facial nerve palsy, loss of hearing, permanent TGN sensory disturbances, and even death), however, in an experienced hand, MVD has a low morbidity and mortality rates.<sup>17,20,35-37</sup>

No major morbidity or mortality occurred in the present study with MVD, except for a patient who developed pseudomeningocele that was managed conservatively by application of a lumbar drain and a patient who developed tinnitus and mild hearing loss.

Previous studies comparing both MVD and RF confirmed the superiority of MVD over RF and even advocated the use of RF only in patients unfit for surgery or those refusing invasive open procedures.<sup>8,9</sup>

Choosing a neurosurgical approach for treating TN involves weighing potential pain relief against possible com-

lications. Patients should be informed about pros and cons of each procedure with full understanding prior to making their decisions.

The limitations of this study were the limited number of patients in both groups and the relatively short follow-up for RF in comparison to the MVD group as they were operated at earlier period to the RF group.

## Conclusion

MVD and RF ablation represent safe and efficacious surgical choices for addressing TN that encompasses both the mandibular and maxillary divisions. Long-term follow-up studies demonstrate that MVD consistently yields favorable outcomes, establishing it as the preferred primary surgical technique, unless contraindicated by the patient's general health and specific needs.

### Ethical Approval

The study was approved by the Local Ethical Scientific Committee of the Menoufia Faculty of Medicine, Menoufia, Egypt. The Institutional Review Board (IRB) approval number and date ID: 4/2023NEUS14-2.

### Authors' Contributions

All authors contributed equally.

### Funding

None.

### Conflict of Interest

None declared.

## References

- 1 Apfelbaum RI. Comparison of the long-term results of microvascular decompression and percutaneous trigeminal neurolysis for the treatment of trigeminal neuralgia. *Int Congr Ser* 2002; 1247:629-643
- 2 Salama H, Ben-Khayal H, Mohamed MA, et al. Outcome of medical and surgical management in intractable idiopathic trigeminal neuralgia. *Ann Indian Acad Neurol* 2009;12(03):173-178
- 3 Cohen-Gadol AA. Microvascular decompression surgery for trigeminal neuralgia and hemifacial spasm: nuances of the technique based on experiences with 100 patients and review of the literature. *Clin Neurol Neurosurg* 2011;113(10):844-853
- 4 Møller AR. Vascular compression of cranial nerves: II: pathophysiology. *Neurol Res* 1999;21(05):439-443
- 5 Thomas KL, Vilensky JA. The anatomy of vascular compression in trigeminal neuralgia. *Clin Anat* 2014;27(01):89-93
- 6 Spatz AL, Zakrzewska JM, Kay EJ. Decision analysis of medical and surgical treatments for trigeminal neuralgia: how patient evaluations of benefits and risks affect the utility of treatment decisions. *Pain* 2007;131(03):302-310
- 7 Park YS, Kim JP, Chang WS, Kim HY, Park YG, Chang JW. Gamma knife radiosurgery for idiopathic trigeminal neuralgia as primary vs. secondary treatment option. *Clin Neurol Neurosurg* 2011;113(06):447-452
- 8 Keric N, Kalasauskas D, Kreth SL, et al. An age-dependent outcome analysis of microvascular decompression and percutaneous thermocoagulation in trigeminal neuralgia. *BMC Neurol* 2021;21(01):182

- 9 Li Y, Yang L, Ni J, Dou Z. Microvascular decompression and radiofrequency for the treatment of trigeminal neuralgia: a meta-analysis. *J Pain Res* 2019;12:1937–1945
- 10 Håkanson S. Trigeminal neuralgia treated by the injection of glycerol into the trigeminal cistern. *Neurosurgery* 1981;9(06):638–646
- 11 Sweet WH, Wepsic JG. Controlled thermocoagulation of trigeminal ganglion and rootlets for differential destruction of pain fibers. 1. Trigeminal neuralgia. *J Neurosurg* 1974;40(02):143–156
- 12 Fujiwara S, Sasaki M, Wada T, et al. High-resolution diffusion tensor imaging for the detection of diffusion abnormalities in the trigeminal nerves of patients with trigeminal neuralgia caused by neurovascular compression. *J Neuroimaging* 2011;21(02):e102–e108
- 13 Jo KW, Kong DS, Hong KS, Lee JA, Park K. Long-term prognostic factors for microvascular decompression for trigeminal neuralgia. *J Clin Neurosci* 2013;20(03):440–445
- 14 Sindou M, Leston J, Howeydy T, Decullier E, Chapuis F. Microvascular decompression for primary Trigeminal Neuralgia (typical or atypical). Long-term effectiveness on pain; prospective study with survival analysis in a consecutive series of 362 patients. *Acta Neurochir (Wien)* 2006;148(12):1235–1245
- 15 Leal PR, Hermier M, Souza MA, Cristino-Filho G, Froment JC, Sindou M. Visualization of vascular compression of the trigeminal nerve with high-resolution 3T MRI: a prospective study comparing preoperative imaging analysis to surgical findings in 40 consecutive patients who underwent microvascular decompression for trigeminal neuralgia. *Neurosurgery* 2011;69(01):15–25
- 16 Blitz AM, Northcutt B, Shin J, et al. Contrast-enhanced CISS imaging for evaluation of neurovascular compression in trigeminal neuralgia: improved correlation with symptoms and prediction of surgical outcomes. *AJNR Am J Neuroradiol* 2018;39(09):1724–1732
- 17 Zhang H, Lei D, You C, Mao BY, Wu B, Fang Y. The long-term outcome predictors of pure microvascular decompression for primary trigeminal neuralgia. *World Neurosurg* 2013;79(5-6):756–762
- 18 Leal PR, Barbier C, Hermier M, Souza MA, Cristino-Filho G, Sindou M. Atrophic changes in the trigeminal nerves of patients with trigeminal neuralgia due to neurovascular compression and their association with the severity of compression and clinical outcomes. *J Neurosurg* 2014;120(06):1484–1495
- 19 Laghmari M, El Ouahabi A, Arkha Y, Derraz S, El Khamlichi A. Are the destructive neurosurgical techniques as effective as microvascular decompression in the management of trigeminal neuralgia? *Surg Neurol* 2007;68(05):505–512
- 20 Zakrzewska JM. Surgery for trigeminal neuralgia? *Pain* 2011;152(03):469–470
- 21 Hong T, Ding Y, Yao P. Long-term efficacy and complications of radiofrequency thermocoagulation at different temperatures for the treatment of trigeminal neuralgia. *Biochem Res Int* 2020;2020:3854284
- 22 Tronnier VM, Rasche D, Hamer J, Kienle AL, Kunze S. Treatment of idiopathic trigeminal neuralgia: comparison of long-term outcome after radiofrequency rhizotomy and microvascular decompression. *Neurosurgery* 2001;48(06):1261–1267
- 23 Tatli M, Satici O, Kanpolat Y, Sindou M. Various surgical modalities for trigeminal neuralgia: literature study of respective long-term outcomes. *Acta Neurochir (Wien)* 2008;150(03):243–255
- 24 Herta J, Loidl TB, Schmied T, et al. Retrospective comparison of percutaneous balloon compression and radiofrequency-thermo-coagulation in the management of trigeminal neuralgia. *Acta Neurochir (Wien)* 2023;165(07):1943–1954
- 25 Liu G, Du Y, Wang X, Ren Y. Efficacy and safety of repeated percutaneous radiofrequency thermocoagulation for recurrent trigeminal neuralgia. *Front Neurol* 2019;9:1189
- 26 Bharti N, Sujith J, Singla N, Panda NB, Bala I. Radiofrequency thermoablation of the Gasserian ganglion versus the peripheral branches of the trigeminal nerve for treatment of trigeminal neuralgia: a randomized. *Pain Physician* 2019;22(02):147–154
- 27 Zhao W, Yang L, Deng A, Chen Z, He L. Long-term outcomes and predictors of percutaneous radiofrequency thermocoagulation of Gasserian ganglion for maxillary trigeminal neuralgia: a retrospective analysis of 1070 patients with minimum 2-year follow-up. *Ann Med* 2022;54(01):2420–2430
- 28 Sekula RF Jr, Frederickson AM, Jannetta PJ, Quigley MR, Aziz KM, Arnone GD. Microvascular decompression for elderly patients with trigeminal neuralgia: a prospective study and systematic review with meta-analysis. *J Neurosurg* 2011;114(01):172–179
- 29 Toda K. Operative treatment of trigeminal neuralgia: review of current techniques. *Oral Surg Oral Med Oral Pathol Oral Radiol Endod* 2008;106(06):788–805, 805.e1–805.e6
- 30 Broggi G, Ferroli P, Franzini A. Treatment strategy for trigeminal neuralgia: a thirty years experience. *Neurol Sci* 2008;29(suppl 1):S79–S82
- 31 Texakalidis P, Xenos D, Tora MS, Wetzel JS, Boullis NM. Comparative safety and efficacy of percutaneous approaches for the treatment of trigeminal neuralgia: a systematic review and meta-analysis. *Clin Neurol Neurosurg* 2019;182:112–122
- 32 Yao P, Deng YY, Hong T, et al. Radiofrequency thermocoagulation for V2/V3 idiopathic trigeminal neuralgia: effect of treatment temperatures on long-term clinical outcomes: a cohort study. *Medicine (Baltimore)* 2016;95(26):e4019
- 33 Huang Q, Liu X, Chen J, et al. The effectiveness and safety of thermocoagulation radiofrequency treatment of the ophthalmic division (V1) and/or maxillary (V2) and mandibular (V3) division in idiopathic trigeminal neuralgia: an observational study. *Pain Physician* 2016;19(07):E1041–E1047
- 34 Tang YZ, Jin D, Bian JJ, Li XY, Lai GH, Ni JX. Long-term outcome of computed tomography-guided percutaneous radiofrequency thermocoagulation for classic trigeminal neuralgia patients older than 70 years. *J Craniofac Surg* 2014;25(04):1292–1295
- 35 Sarnvivad P, Bumpenboon A, Chumnanvej S. Retrospective long term outcome following microvascular decompression surgery in Thai patients with trigeminal neuralgia. *J Med Assoc Thai* 2013;96(07):801–806
- 36 Lambrou G, Zakrzewska J, Matharu M. Trigeminal neuralgia: a practical guide. *Pract Neurol* 2021;21(05):392–402
- 37 Abduhamid AS, Alomari MS, Ghaddaf AA, et al. Radiofrequency thermoablation of the peripheral branches of trigeminal nerve versus the Gasserian ganglion for treating idiopathic trigeminal neuralgia: a systematic review and meta-analysis. *J Clin Neurosci* 2022;104:42–47