

## Case Report

# Pneumomediastinum and subcutaneous emphysema complicating staphylococcal pneumonia

I A Finnie, C I A Jack, J S McKay

Accepted 11 November 1994

---

Pneumonia is one of the leading causes of death in the UK, accounting for 60,000 fatalities annually.<sup>1</sup> *Staphylococcus aureus* causes less than 5% of all pneumonias<sup>2,3</sup> but is associated with a high mortality and morbidity<sup>2,3</sup>, even in previously healthy individuals. We report a case of a young adult who developed a pneumomediastinum and marked subcutaneous emphysema as a complication of staphylococcal pneumonia. Pneumomediastinum is a relatively rare complication of staphylococcal pneumonia, especially in adults. If cardiac filling is significantly reduced urgent aspiration or surgical treatment is required.

## CASE REPORT

A previously healthy 15 year old girl was admitted to Leighton Hospital with a seven day history of productive cough with purulent sputum. She also complained of increasing breathlessness and bilateral pleuritic chest pain. Sixteen hours prior to admission she developed swelling of the neck and lower face. She was cyanosed and pyrexial (39.4°C orally). Respiratory rate was 40/min, heart rate 120/minute and blood pressure 90/50 mm Hg. There was no pulsus paradoxus. Two heart sounds were present, together with systolic and diastolic crackling. There was subcutaneous crepitus from the sternal angle to the mandible. Chest expansion was generally poor, with dullness to percussion at the right base, and bronchial breathing at both bases.

White cell count was  $53 \times 10^9$ /litre (98% neutrophils) and arterial blood gases indicated profound hypoxia in keeping with type 1 respiratory failure (pH 7.40,  $pO_2$  5.8 kPa,  $pCO_2$  3.8 kPa). Serum urea and electrolytes were normal. Chest radiograph showed bilateral patchy consolidation at the lung bases with a small pneumomediastinum and subcutaneous emphysema (Figure).

---

Royal Liverpool Hospital, Liverpool.

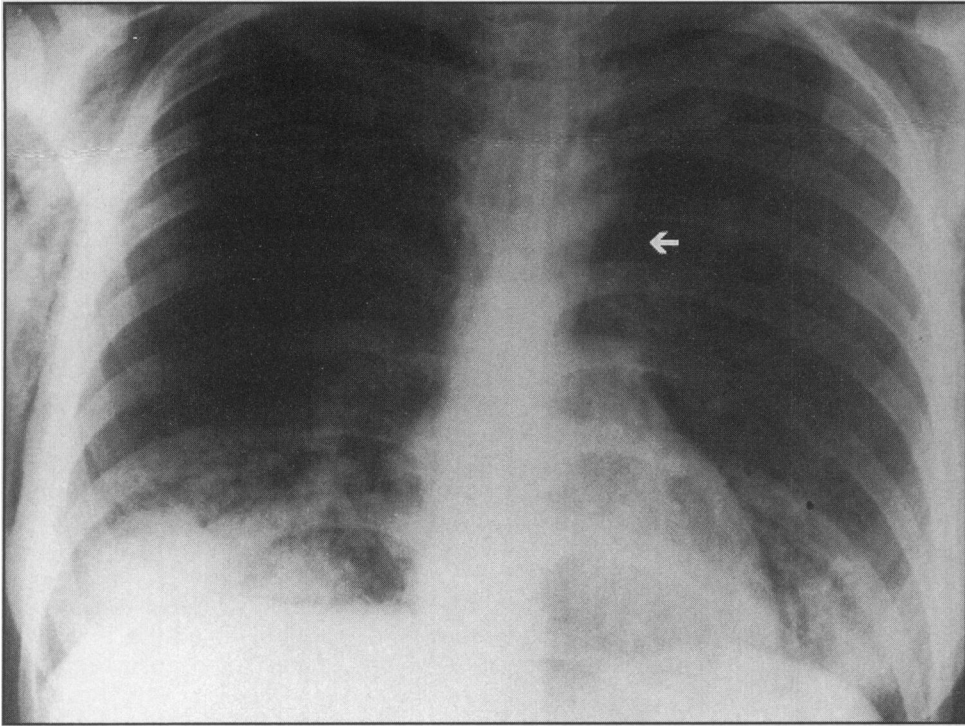
I A Finnie, MB, BCh, MRCP, Senior Registrar.

C I A Jack, MD, MRCP, Lecturer (Honorary Senior Registrar).

Leighton Hospital, Crewe, Cheshire, CW1 4QJ.

J S McKay, MD, MRCP, Consultant Physician.

Correspondence to Dr Finnie, Consultant Physician and Gastroenterologist, Glan Clwyd Hospital, Bodelwyddan, nr Rhyl, Clwyd, LL18 5UJ.



Chest radiograph on admission showing patchy shadowing at both lung bases, extensive subcutaneous emphysema, and the presence of air in the mediastinum (arrow).

After blood and sputum cultures were obtained, intravenous ampicillin and erythromycin were commenced; chest physiotherapy was combined with high concentration oxygen given by venturi mask. Within 48 hours of starting this management there was marked clinical improvement, heart rate settling to 100/min and resolution of the subcutaneous emphysema. Although the patient had not previously been treated with antibiotics the blood cultures were sterile. Microscopy of a mucopurulent sputum specimen revealed gram-positive cocci however; subsequent culture (reported 48 hours after admission by Dr H Mamattah, Consultant Microbiologist) was positive for *Staphylococcus aureus* so oral flucloxacillin was substituted for ampicillin, and erythromycin was continued. The patient subsequently made a full recovery and was discharged home ten days following admission.

## DISCUSSION

*Staphylococcus aureus* is an unusual cause of pneumonia in adults; this agent was responsible for only four cases of pneumonia out of 303 in which an infectious agent was isolated in the British Thoracic Society (BTS) survey.<sup>2</sup> Factors which are associated with a poor prognosis in patients with pneumonia include a respiratory rate  $\geq 30$ /min, a diastolic blood pressure  $\leq 60$  mmHg, blood urea  $> 7$  mmol/l, and a staphylococcal aetiology. Since three of these factors were present in our patient she may have been fortunate to survive.

Pneumonia caused by *Staphylococcus aureus* is commonly thought to occur as a sequela to previously impaired respiratory defences, usually caused by influenza or a similar virus, and several authors have stressed that the prognosis with associated influenza A virus infection may be especially grave.<sup>3, 4</sup> In staphylococcal pneumonia there is marked tissue destruction and healing by fibrosis; subsequently antibiotics may penetrate poorly and the results of treatment may be slow (2-4 weeks of treatment may be necessary). Recognised complications of staphylococcal pneumonia include abscess formation, pneumothorax and empyema.<sup>5</sup> Although escape of air into the mediastinum and subcutaneous tissues or pleura by alveolar rupture is recognised in staphylococcal pneumonia, these complications tend to occur in neonates.<sup>5</sup>

Our patient had typical features of pneumomediastinum and subcutaneous emphysema including chest and neck pain and swelling, together with signs of the underlying pneumonia. Hamman's sign (crackling, bubbling or churning sounds occurring in time with the heartbeat<sup>6</sup>) is characteristic but not pathognomonic for pneumomediastinum (it may also occur in patients with a left sided pneumothorax, in which instance it may be abolished by lying the patient on the left). The diagnosis is usually confirmed by a chest radiograph showing radiolucent lines along the cardiac borders.

Pneumomediastinum in adults has been associated with other forms of suppurative lung disease including *Pneumocystis carinii* pneumonia in AIDS, substance abuse, trauma, parturition, asthma, and the neuroleptic malignant syndrome. Spontaneous cases also occur.<sup>6</sup> Contrary to popular belief pneumomediastinum is often benign and self-limiting,<sup>6</sup> and treatment is aimed at that of the underlying disorder. However, if cardiac filling is significantly restricted, the air should be aspirated or removed surgically without delay.<sup>7</sup> Our patient did not have any features of cardiac tamponade and thus was treated conservatively.

## REFERENCES

1. Macfarlane J. Community-acquired pneumonia. *Br J Dis Chest* 1987; **81**: 116-27.
2. British Thoracic Society Research Committee and the Public Health Laboratory Service. Community-acquired pneumonia in adults in British Hospitals in 1982-1983: a survey of aetiology, mortality, prognostic factors and outcome. *Quart J Med* 1987; **62**: 195-220.
3. Woodhead M A, Radvan J, Macfarlane J T. Adult community-acquired staphylococcal pneumonia in the antibiotic era: a review of 61 cases. *Quart J Med* 1987; **64**: 783-90.
4. Grant A P, Barber J M. Staphylococcal pneumonia. *Ulster Med J* 1954; **23**: 27-33.
5. Macfarlane J T. Acute respiratory infections in adults. In Brewis R A L, Gison G J, Geddes D M eds. *Respiratory medicine*. Ballière Tindal. London 1990: 880-923.
6. Hamman L. Mediastinal emphysema. *JAMA* 1945; **128**: 1-6.
7. Beg M H, Reyazuddin, Ansari M M. Traumatic tension pneumo mediastinum mimicking cardiac tamponade. *Thorax* 1988; **43**: 576-7.