




## Case Report

# Primary myxoid temporal bone tumor: A rare neurosurgical manifestation of Carney complex?

Tobechi Nwankwo Mbadugha<sup>1</sup>, Kohei Kanaya<sup>2</sup>, Tetsuyoshi Horiuchi<sup>2</sup>, Mai Iwaya<sup>3</sup>, Samuel Chukwunonyerem Ohaegbulam<sup>1</sup>, Kazuhiro Hongo<sup>2</sup>

<sup>1</sup>Department of Neurosurgery, Memfys Hospital for Neurosurgery, Onitsha Expressway, Enugu, Nigeria, Department of <sup>2</sup>Neurosurgery and <sup>3</sup>Laboratory Medicine, Shinshu University School of Medicine, Asahi, Matsumoto, Nagano, Japan.

E-mail: Tobechi Nwankwo Mbadugha - tobechimbadugha@gmail.com; \*Kohei Kanaya - kanaya@shinshu-u.ac.jp; Tetsuyoshi Horiuchi - tetuyosi@shinshu-u.ac.jp; Mai Iwaya - mkatou@shinshu-u.ac.jp; Samuel Chukwunonyerem Ohaegbulam - samcohaegbulam@hotmail.com; Kazuhiro Hongo - khongo@shinshu-u.ac.jp



### \*Corresponding author:

Kohei Kanaya,  
Department of Neurosurgery,  
Shinshu University School  
of Medicine, Asahi 3-1-1,  
Matsumoto-390-8621, Nagano,  
Japan.

kanaya@shinshu-u.ac.jp

Received : 09 April 2020

Accepted : 09 June 2020

Published : 27 June 2020

### DOI

10.25259/SNI\_170\_2020

### Quick Response Code:



## ABSTRACT

**Background:** Carney complex (CNC) is a rare autosomal dominant syndrome, manifesting mainly with cardiac, cutaneous, and mucosal myxomas. Osteochondromyxoma is known as an extremely rare bone lesion of CNC which usually appears early in life; however, there were no reports of primary bone myxoma of the skull in the patients with CNC. We present the first case of primary myxoid skull tumor in the patient with CNC.

**Case Description:** We report the left temporal bone tumor with significant intracranial mass effect in a 58-year-old woman already diagnosed with CNC. Complete resection of the tumor with skull bone reconstruction was carried out. Pathological diagnosis was labeled the lesion as an atypical myxoid spindle cell neoplasm. The features were different from atrial myxoma and osteochondromyxoma which has been described in CNC. There have been no signs of recurrence in 9 years follow-up.

**Conclusion:** To the best of our knowledge, there have been no reports of the primary myxoid tumors in the skull in the patients with CNC. This paper highlighted a possible important association between CNC and primary intracranial myxoid tumors.

**Keywords:** Carney complex, Myxoid tumor, Skull

## INTRODUCTION

Carney complex (CNC) is a rare autosomal dominant syndrome characterized by pigmented, myxomatous lesions of the skin, mucosae, cardiac, and other tissues as well as multiple endocrine and nonendocrine neoplasms.<sup>[5,14]</sup> It is a disease that is relatively unknown to the neurosurgeon. Cushing's syndrome from primary pigmented nodular adrenocortical disease, growth hormone-secreting pituitary adenomas, and psammomatous melanotic schwannomas are some of the well-recognized, albeit rare, neurosurgical manifestations of CNC.<sup>[15]</sup>

Primary myxoid tumors rarely occur intracranially. To the best of our knowledge, there have been no previous reports in the literature of primary myxoid tumors of the head-and-neck region identified in CNC patients.

We present a 58-year-old woman with a primary myxoid tumor in the left temporal bone in the setting of CNC diagnosis. This case illustrates the challenges in making a histological

This is an open-access article distributed under the terms of the Creative Commons Attribution-Non Commercial-Share Alike 4.0 License, which allows others to remix, tweak, and build upon the work non-commercially, as long as the author is credited and the new creations are licensed under the identical terms.

©2020 Published by Scientific Scholar on behalf of Surgical Neurology International

diagnosis in this group of tumors and the features that make them difficult to treat radically, as previously reported.<sup>[4]</sup>

## CASE REPORT

### History and examination

A 58-year-old woman presented with a 4-month history of anomic aphasia, memory disturbance, and a recent onset of dizziness. At age 32 years, she was managed for stroke resulting from atrial myxoma, which was removed surgically. The patient's daughter and granddaughter were both diagnosed with CNC, in addition to the daughter having Cushing's syndrome.

On examination, she was fully conscious and cooperative. She had fluent aphasia as well as naming disorder and agraphia. Pupils were 2.5 mm in size bilaterally and promptly reactive, and there were no obvious cranial neuropathies. Motor and sensory examinations were unremarkable, and cerebellar signs were negative. The other system examinations were essentially normal.

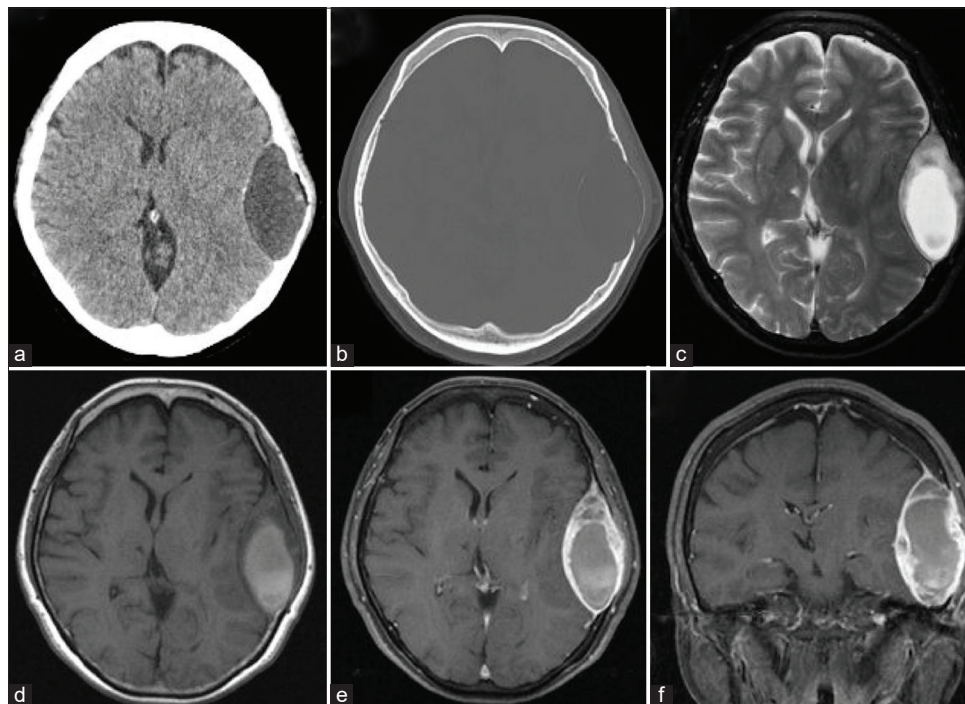
### Radiological findings

Computed tomography (CT) scan showed a well-circumscribed, hypodense, extra-axial mass in the left

temporal region with significant bony erosion and partially calcified rims. Brain magnetic resonance imaging (MRI) revealed a heterogeneously contrast-enhanced mass with significant displacement of the adjacent temporoparietal lobes [Figure 1].

### Treatment and postoperative course

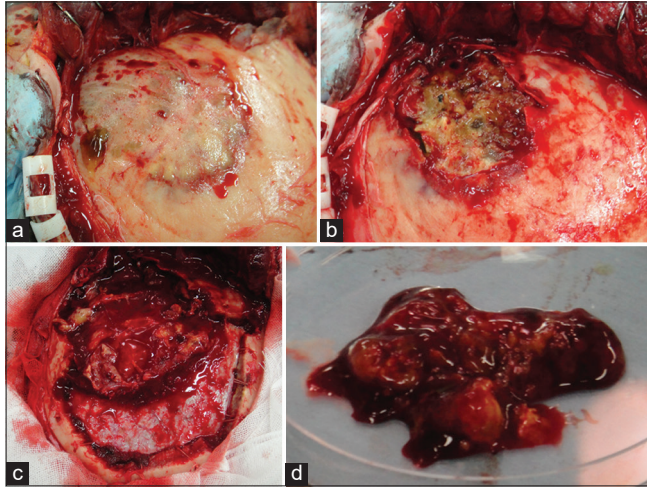
The patient underwent tumor excision through a left frontotemporal approach. There was tumor invasion of the cranium and partial destruction of the outer table of the skull; however, the temporalis muscle and periosteum were intact. The tumor consisted of a yellowish soft lesion with a jelly-like component. The inner table of the skull was destroyed, and the tumor was adherent to the dura. The tumor was meticulously dissected from the dura and gross total resection of the tumor was achieved [Figure 2]. The dura was coagulated, and cranioplasty was done with titanium mesh plate. Intraoperative frozen section was unable to make a histopathological diagnosis. Postoperative course was uneventful, and the anomic aphasia had a complete resolution. Postoperative imaging confirmed gross total tumor resection [Figure 3]. She has been followed for over 9 years without any neurological deficit including seizures (Karnofsky performance scale 100%) or radiological signs of recurrence.



**Figure 1:** Axial brain CT scans showing the hypodense mass with partially calcified rim and bone erosion of the adjacent left temporal bone. (a,b) Axial T2-weighted MR image showing hyperintense lesion at the left temporal bone. (c) Axial T1-weighted MR image showing hypointense circumferential mass and hyperintense fluid component in the mass. (d) Axial and coronal enhanced T1-weighted MR images showing heterogeneous contrast enhancement of the tumor. (e,f)

### Histopathological diagnosis

Grossly, the pathological specimen consisted of a yellowish, soft, and gelatinous tissue. Histologically, the resected lesion showed a proliferation of bland spindle cells which had ovoid to elongated nuclei with myxoid stroma. Occasionally, spindle cells with atypical hyperchromic nuclei were seen.



**Figure 2:** Intraoperative photos after the left frontotemporal skin flap was raised, illustrating the yellowish gelatinous tumor and the involved temporal bone. (a) After removal of the outer table. (b) Removal of the tumor and the inner table. (c) The gross pathological specimen. (d)

There were prominent macrophages and no cartilage, osteoid, or bone were identified [Figure 4]. Immunohistochemistry, the spindle cells were focally immunoreactive for EMA and alpha-SMA, negative for desmin, and CD34. S-100 showed equivocal expression [Table 1]. The features were different from atrial myxoma and appeared rather more cellular than tumors known as osteochondromyxoma which has been described in CNC. Pathological diagnosis was descriptive and labeled the lesion as an atypical myxoid spindle cell neoplasm.

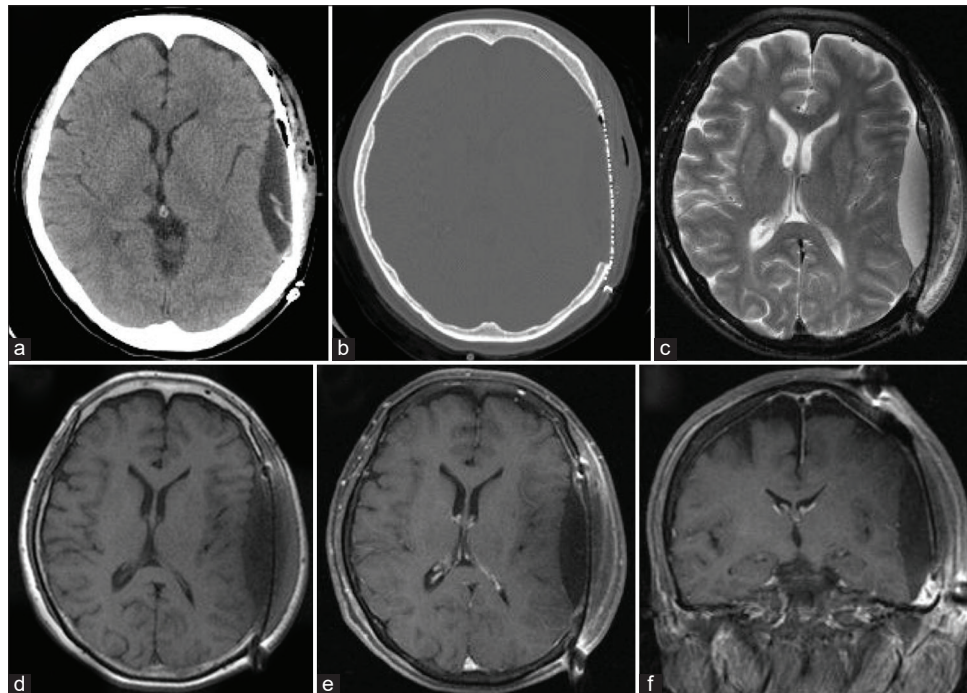
### DISCUSSION

Primary myxoma, a benign lesion of mesenchymal origin, is a rare intracranial lesion. Metastatic/embolic atrial myxoma, although uncommon, is a more frequent occurrence than

**Table 1:** Immunohistochemical features of the present case and myxoma.

	Present case	Myxoma
EMA	Focally positive	Less positive
α-SMA	Focally positive	Positive
Desmin	Negative	Negative
CD34	Negative	Positive
S-100	Equivocal expression	Negative
Vimentin	Not examined	Positive

EMA: Epithelial membrane antigen, SMA: Smooth muscle actin

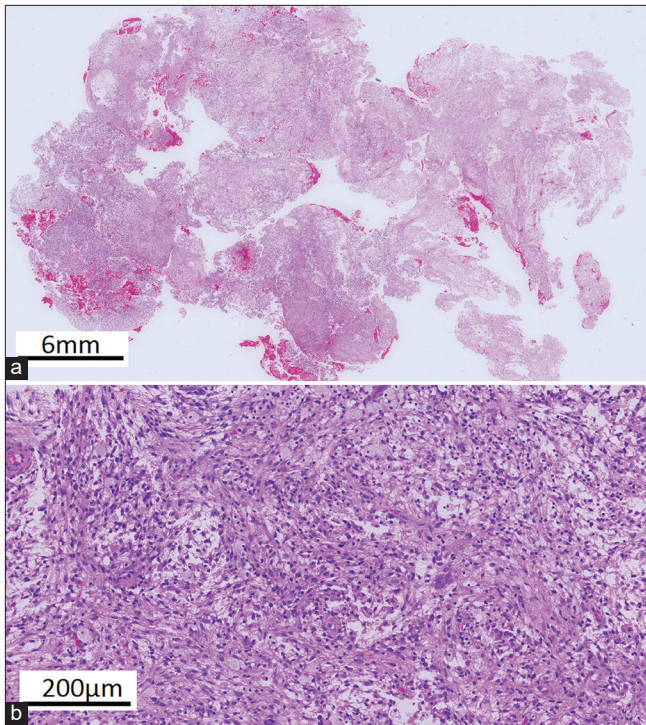


**Figure 3:** Postoperative brain CT scans showing removal of the tumor and reconstruction with titanium mesh plate. (a,b) Axial T2-weighted MR image showing decompression of the left temporal lobe. (c) T1 (d) and enhanced T1-weighted (e,f) MR images showing total removal of the tumor.

primary myxoid intracranial tumors.<sup>[9,10]</sup> Occasionally, the metastatic lesion may manifest first and may be the pointer to a primary cardiac myxoma.<sup>[11,12]</sup>

Of the cases of primary myxomas reported in the head-and-neck region, the most common locations were the maxilla and mandible.<sup>[1]</sup> Other less frequently involved locations were the pituitary and posterior fossae, with one case reported in each of the locations.<sup>[7,8]</sup> To the best of our knowledge, fewer than 10 cases have been identified in the temporal bone, mostly involving the petrous skull base, usually manifesting with hearing disturbances and varying degrees of facial palsies.<sup>[4,6,10]</sup> None of these cases were identified in CNC patients. The difficulty in differentiating a true bone myxoma from other myxoid bone tumors is well established<sup>[4,9,10]</sup> and is demonstrable in this case. Clinically, true myxomas are slow-growing, benign lesions, developing in the marrow, and expanding the cortex to destroy the bone by aseptic pressure necrosis.<sup>[8]</sup> Radiologically, they appear as expansive lesions within the skull tables, hypo- to iso-dense with variable enhancement, and vascularity patterns on CT and MRI and extensive bony erosion, as was observed in the present case. On microscopy, they are composed of stellate cells in the dispersed myxoid stroma with the absence of nuclear atypia and mitotic figures.

Unlike the true myxomas, the other myxoid bone tumors are more malignant lesions with myxomatous degeneration.



**Figure 4:** Macroscopic view showing a proliferation of bland spindle cells with myxoid stroma. (a) Microscopic view showing spindle cells having ovoid to elongated and atypical hyperchromic nuclei with prominent macrophages and no cartilage, osteoid, or bone. (b)

They lack differentiated mesenchymal elements with hypercellularity, nuclear pleomorphism, and mitotic figures. The differentials include myxoid chondrosarcoma, myxoliposarcoma, myxorhabdomyosarcoma, chordoma, myxoid malignant fibrous histiocytoma, and metastatic tumors of the skull.<sup>[4,10]</sup> Other more benign lesions such as hemangiopericytoma, meningioma, and other neoplasms of the dura and skull base in this location should also be excluded in the differential diagnosis.<sup>[8,9]</sup> The differential diagnoses of bone myxoma are shown in [Table 2].

Immunohistochemistry may be helpful in distinguishing these myxoid lesions, although the findings were inconsistent with the index case. Findings supporting a myxoma is positive staining for vimentin and negative for S-100, desmin, neuron-specific enolase, keratin, and glial fibrillary acid protein. It also shows positivity for  $\alpha$ -smooth muscle actin (SMA), calretinin and CD34 of cardiac myxomas, and less for epithelial membrane antigen (EMA) [Table 1].<sup>[3,9,13]</sup>

To the best of our knowledge, these primary bone myxomas of the head-and-neck region have never been reported in association with CNC. Osteochondromyxoma is the bone myxoma that has been identified in the CNC patients, although its occurrence is still rare.<sup>[5,14]</sup> The diagnosis of osteochondromyxoma is very unlikely in our patient because it has only been reported in early life before the age of 2 years and usually involves nasal sinuses and long bones of the extremities, never been reported in the intracranial cavity.<sup>[5,14]</sup> In addition, there was no evidence of cartilage, osteoid, nor bone in the core of the tumor in the index patient except for the surrounding bone cells. The diagnostic criteria for CNC<sup>[5,14]</sup> and the clinical manifestations in the present case are shown in [Table 3]. Even though it is obvious that this patient has a rare primary myxoid tumor in the temporal bone with a diagnosis of CNC, what is unclear this primary myxoid bone tumor might be a rare intracranial manifestation of CNC. More extensive immunohistochemistry and immunotyping of the tumor may help resolve some of these suspicions.

On the whole, the recognition of a possible association between CNC and a primary intracranial bone myxoma has implications in patient management, bearing in mind the known risks in the perioperative management of patients with CNC. They are at risk for ACTH-independent Cushing's syndrome and cardiac myxoma with its subsequent risk of

**Table 2:** Differential diagnoses of bone myxoma.

Myxoid chondrosarcoma	Myxoliposarcoma	Myxorhabdo myosarcoma
Chordoma	Myxoid malignant fibrous histiocytoma	Metastatic tumors of the skull
Hemangiopericytoma	Meningioma	Others

**Table 3:** Diagnostic criteria for CNC and the clinical manifestations in the present case.

Major criteria	Present case
Spotty skin pigmentation with typical distribution (lips, conjunctiva and inner or outer canthi, vaginal, and penile mucosal)	
Myxoma* (cutaneous and mucosal) or cardiac myxoma*	Cardiac myxoma
Breast myxomatosis* or fat-suppressed magnetic resonance imaging findings suggestive of this diagnosis	
Primary pigmented nodular adrenocortical disease (PPNAD)* or paradoxical positive response of urinary glucocorticosteroid excretion to dexamethasone administration during Liddle's test	
Acromegaly as a result of growth hormone (GH)-producing adenoma*	
Large cell calcifying Sertoli cell tumors (LCCSCT)* or characteristic calcification on testicular ultrasound	
Thyroid carcinoma* (at any age) or multiple hypoechoic nodules on thyroid ultrasound in prepubertal child	
Psammomatous melanotic schwannomas (PMS)*	
Blue nevus, epithelioid blue nevus (multiple)*	
Breast ductal adenoma (multiple)*	
Osteochondromyxoma*	
Supplemental criteria	
Affected first-degree relative	Patient's daughter
Activating pathogenic variants of <i>PRKACA</i> and <i>PRKACB</i>	
Inactivating mutation of <i>PRKAR1A</i> gene	
Findings suggestive of or possibly associated with CNC, but not diagnostic for the disease (minor criteria)	
Intense freckling (without darkly pigmented spots or typical distribution)	
Blue nevus, common type (if multiple)	
Café-au-lait spots or other "birthmarks"	
Elevated IGF-I levels, abnormal glucose tolerance test (GTT), or paradoxical GH response to TRH (thyrotropin-releasing hormone) testing in the absence of clinical acromegaly	
Cardiomyopathy	
History of Cushing's syndrome, acromegaly, or sudden death in extended family	Cushing's syndrome in patient's daughter
Pilonidal sinus	
Colonic polyps (usually in association with acromegaly)	
Multiple skin tags or other skin lesions; lipomas	
Hyperprolactinemia (usually mild and almost always combined with clinical or subclinical acromegaly)	
Single, benign thyroid nodule in a child younger than age 18 years; multiple thyroid nodules in an individual older than age 18 years (detected on ultrasound examination)	
Family history of carcinoma, in particular of the thyroid, colon, pancreas, and ovary; other multiple benign or malignant tumors	
To make the diagnosis of CNC, a patient must either: (1) exhibit two of the major criteria confirmed by histology, imaging or biochemical testing, or meet (2) one major criterion and one supplemental one. *With histologic confirmation	

hemodynamic or embolic complications, including stroke and heart failure.<sup>[5,14,15]</sup> This could have devastating consequences if not suspected and properly investigated before surgery.

More so, making an accurate diagnosis will help in genetic screening and counseling of both the patient and relatives as they are predisposed to certain tumors such as growth hormone-secreting adenomas and nerve sheath tumors, including schwannomas which are more common neurosurgical manifestations of CNC.<sup>[15]</sup>

The treatment of primary intracranial myxoid tumors is surgical removal as the tumor is generally insensitive to radiation.<sup>[4]</sup> Radical *en bloc* removal of the tumor is required to reduce recurrence risk. However, several factors limit radical resection, namely, the aggressive nature of the tumor

with bone erosions and dural invasion, the gelatinous nature of the tumor, and its extensive vascularity.<sup>[4,10]</sup> Reoperation and close follow-up must be the treatment of choice in cases with recurrence. Radiotherapy should only be considered in inoperable cases due to its limited efficacy.<sup>[9]</sup> There is also no definitive chemotherapy for recurrent myxoma, although there is a case report of the cerebral metastases of cardiac myxoma treated with irradiation and chemotherapy (doxorubicin and ifosfamide) with a 10-year remission.<sup>[2]</sup>

Fortunately, the temporal convexity was involved in the index case, and the dura was not bridged even though the tumor was adherent. Thus, the tumor was meticulously detached from the dura and completely resected with the removal of the involved convexity bone. Cranioplasty was subsequently

performed to repair the deformity. This would have been more challenging in the skull base with an increased risk of serious complications such as cerebrospinal fluid leak and cranial nerve injuries.

Recurrence of primary myxoid bone tumors is common, with 25% of tumors recurring if they were not radically resected.<sup>[16]</sup> Despite radical resections, local recurrences have also been reported as early as 3 months and as late as 10 years after initial surgical resection.<sup>[10]</sup> We believe that gross total removal of the lesion can be related to no recurrence in 9 years. Furthermore, the regular follow-up has been continued for this patient. Long-term follow-up for the patients with CNC is recommended with lifelong surveillance.<sup>[5,14]</sup>

## CONCLUSION

We reported a case of primary myxoid skull tumor in the patient with CNC treated with radical resection without recurrence in 9 years follow-up. As previously reported<sup>[4,10]</sup>, radical removal of the myxoid bone tumor can contribute to long-term control. Primary intracranial myxoid tumors may be a rare neurosurgical manifestation of CNC. More clinical reports, as well as immunohistochemical analysis in future, may be needed to confirm a strong association between these two clinicopathologic entities.

## Declaration of patient consent

The authors certify that they have obtained all appropriate patient consent.

## Financial support and sponsorship

Nil.

## Conflicts of interest

There are no conflicts of interest.

## REFERENCES

1. Andrews T, Kountakis SE, Maillard AA. Myxomas of the head and neck. *Am J Otolaryngol* 2000;21:184-9.

2. Bernet F, Stulz PM, Carrel TP. Long-term remission after resection, chemotherapy, and irradiation of a metastatic myxoma. *Ann Thorac Surg* 1998;66:1791-2.
3. Burke A, Tavora F. The 2015 WHO classification of tumors of the heart and pericardium. *J Thorac Oncol* 2015;11:441-52.
4. Charabi S, Engel P, Bonding P. Myxoid tumours in the temporal bone. *J Laryngol Otol* 1989;103:1206-9.
5. Correa R, Salpea P, Stratakis C. Carney Complex : An update. *Eur J Endocrinol* 2015;173:M85-97.
6. Hsieh DL, Tseng HM, Young YH. Audiovestibular evolution in a patient undergoing surgical resection of a temporal bone myxoma. *Eur Arch Otorhinolaryngol* 2006;263:614-7.
7. Klein MV, Schwaighofer BW, Sobel DF, Hesselink JR. Primary myxoma of the posterior fossa. *Neuroradiology* 1990;32:250-1.
8. Nagatani M, Mori S, Takimoto N, Arita N, Ushio Y, Hayakawa T, *et al.* Primary myxoma in the pituitary fossa: Case report. *Neurosurgery* 1987;20:329-31.
9. Oruckaptan HH, Sarac S, Gedikoglu G. Primary intracranial myxoma of the lateral skull base: A rare entity in clinical practice. *Turk Neurosurg* 2010;20:86-9.
10. Osterdock RJ, Greene S, Mascott CR, Amedee R, Crawford BE. Primary myxoma of the temporal bone primary myxoma of the temporal bone in a 17-year-old boy: Case report. *Neurosurgery* 2001;48:945-8.
11. Rupp GM, Heyman RA, Martinez AJ, Sekhar LN, Jungreis CA. The pathology of metastatic cardiac myxoma. *Am J Clin Pathol* 1989;91:221-7.
12. Sekhar LN, Pomeranz S, Janecka IP, Hirsch B, Ramasastry S. Temporal bone neoplasms: A report on 20 surgically treated cases. *J Neurosurg* 1992;76:578-87.
13. Singhal P, Luk A, Rao V, Butany J. Molecular basis of cardiac myxomas. *Int J Mol Sci* 2014;151:1315-37.
14. Vezzosi D, Vignaux O, Dupin N, Bertherat J. Carney complex: Clinical and genetic 2010 update. *Ann Endocrinol (Paris)* 2010;71:486-93.
15. Watson JC, Stratakis CA, Bryant-Greenwood PK, Koch CA, Kirschner LS, Nguyen T, *et al.* Neurosurgical implications of carney complex. *J Neurosurg* 2000;92:413-8.
16. Whitman RA, Stewart S, Stoopack JG, Jerrold TL. Myxoma of the mandible: Report of case. *J Oral Surg* 1971;29:63-70.

**How to cite this article:** Mbadugha TN, Kanaya K, Horiuchi T, Iwaya M, Ohaegbulam SC, Hongo K. Primary myxoid temporal bone tumor: A rare neurosurgical manifestation of Carney complex?. *Surg Neurol Int* 2020;11:166.