

# GABA-A Receptor Encephalitis After Autologous Hematopoietic Stem Cell Transplant for Multiple Myeloma

## Three Cases and Literature Review

Yoji Hoshina, MD, Jonathan Galli, MD, Ka-Ho Wong, MBA, Tibor Kovacsovics, MD, Mary Steinbach, DNP, APRN, Karen L. Salzman, MD, Joseph Scott McNally, MD, PhD, Eric Lancaster, MD, PhD, M. Mateo Paz Soldán, MD, PhD, and Stacey L. Clardy, MD, PhD

**Correspondence**  
Dr. Clardy  
stacey.clardy@hsc.utah.edu

*Neurol Neuroimmunol Neuroinflamm* 2022;9:e200024. doi:10.1212/NXI.0000000000200024

## Abstract

### Background and Objectives

The relationship between autologous hematopoietic stem cell transplant (aHSCT) for multiple myeloma (MM) and anti-GABA<sub>A</sub> receptor (GABA<sub>A</sub>R) encephalitis is unknown. We aimed to describe the clinical features, diagnostic process, and outcome of 3 cases of anti-GABA<sub>A</sub>R encephalitis in patients with a history of prior aHSCT for MM.

### Methods

A case series of 3 patients. Anti-GABA<sub>A</sub>R antibody was tested at the University of Pennsylvania Laboratory.

### Results

The patients were all male, aged 52 (case 1), 61 (case 2), and 62 (case 3) years at encephalitis symptom onset. The duration between completion of aHSCT and the onset of encephalitis was 43, 18, and 9 months, respectively. All 3 patients presented with new seizures and altered cognitive function. Other symptoms included headache and visual obscurations in cases 1 and 2 and intractable vertigo and mania in case 3. Brain MRI demonstrated nonenhancing multifocal T2-weighted/fluid-attenuated inversion recovery cortical and subcortical hyperintensities in all 3 patients. Cases 2 and 3 underwent brain biopsy before initiating immunomodulatory therapy, which demonstrated nonspecific encephalitis with astrogliosis in the white matter; these 2 patients were started on immunotherapy for the treatment of anti-GABA<sub>A</sub>R encephalitis after 22 days and 3 months, respectively, from the first presentation. Case 1 was started on empiric immunotherapy within 8 days of presentation without requiring brain biopsy, given characteristic MRI imaging. CSF analysis demonstrated the presence of anti-GABA<sub>A</sub>R antibodies in all 3 cases. Cases 1 and 3 also tested positive for anti-GABA<sub>A</sub>R antibodies in the serum (serum test was not performed in case 2). Cases 1 and 2 recovered to work full-time within 1 year. Case 3 reported occasional myoclonic-like movement.

### Discussion

We highlight the importance of considering anti-GABA<sub>A</sub>R encephalitis in patients with seizures, multifocal nonenhancing brain lesions, and a history of aHSCT for MM. Awareness in recovered post-aHSCT patients with MM may be crucial because prompt recognition can avoid brain biopsy and delays in treatment. The rapid initiation of immunotherapy while awaiting autoantibody results will likely improve functional outcomes.

From the Department of Neurology (Y.H., J.G., K.-H.W., M.M.P.S., S.L.C.), University of Utah Health; Department of Neurology (J.G., M.M.P.S., S.L.C.), Veterans Affairs Medical Center, UT; Division of Hematology and Hematologic Malignancies (T.K., M.S.), Huntsman Cancer Institute, University of Utah Health; Department of Radiology and Imaging Sciences (K.L.S., J.S.M.), University of Utah Health; and Department of Neurology (E.L.), University of Pennsylvania, Philadelphia.

Go to [Neurology.org/NN](https://www.neurology.org/NN) for full disclosures. Funding information is provided at the end of the article.

The Article Processing Charge was funded by the authors.

This is an open access article distributed under the terms of the Creative Commons Attribution-NonCommercial-NoDerivatives License 4.0 (CC BY-NC-ND), which permits downloading and sharing the work provided it is properly cited. The work cannot be changed in any way or used commercially without permission from the journal.

## Glossary

**aHSCT** = autologous hematopoietic stem cell transplantation; **ANA** = antinuclear antibodies; **ANCA** = antineutrophil cytoplasmic antibodies; **CRP** = C-reactive protein; **ED** = emergency department; **ESR** = erythrocyte sedimentation rate; **FLAIR** = fluid-attenuated inversion recovery; **GABA<sub>A</sub>R** =  $\gamma$ -aminobutyric acid type A receptor; **IgG** = immunoglobulin G; **JC** = John Cunningham; **ME** = meningitis/encephalitis; **MM** = multiple myeloma; **OCB** = oligoclonal bands; **WBC** = white blood cell.

The  $\gamma$ -aminobutyric acid type A receptor (GABA<sub>A</sub>R) is a ligand-gated, chloride ion channel that mediates most of the fast inhibitory synaptic transmission in the brain.<sup>1</sup> It regulates brain excitability and is the pharmacologic target of several antiepileptic drugs, sedatives, and anxiolytic drugs.<sup>2</sup> Variation of this receptor are associated with epilepsy and other neurologic dysfunctions.<sup>2</sup> Anti-GABA<sub>A</sub>R encephalitis, in which immunoglobulin G (IgG) targets the receptor, is an immunotherapy-responsive autoimmune disorder first described in 2014.<sup>3</sup> Common symptoms of anti-GABA<sub>A</sub>R encephalitis include status epilepticus and medication-refractory epilepsy. On MRI, the characteristic finding consists of multifocal, nonenhancing brain lesions involving gray and white matter.<sup>4</sup> The largest reported case series of anti-GABA<sub>A</sub>R encephalitis comprised 26 patients (15 adults and 11 children); of 15 adults, 7 had an underlying tumor, with thymoma reported most commonly.<sup>4</sup> In that report, we specifically described a case of anti-GABA<sub>A</sub>R encephalitis after autologous hematopoietic stem cell transplantation (aHSCT) for multiple myeloma (MM), noting that the relationship between aHSCT for MM and anti-GABA<sub>A</sub>R encephalitis is unclear. In this study, we describe the clinical features, diagnostic processes, and outcomes of 3 cases of anti-GABA<sub>A</sub>R encephalitis in patients with a history of aHSCT for MM.

## Methods

Three cases of anti-GABA<sub>A</sub>R encephalitis in patients with a history of aHSCT for MM were diagnosed at the University of Utah and University of Pennsylvania from November 2017 to March 2019. The presence of anti-GABA<sub>A</sub>R antibodies was confirmed at the University of Pennsylvania Laboratory in all cases. Reactivity in a specific GABA<sub>A</sub>R cell-based assay using live human embryonic kidney cells expressing  $\alpha 1\beta 3$  subunits was examined in serum and/or CSF. The patients were informed that deidentified data concerning the case would be submitted for publication, and consent was provided.

### Standard Protocol Approvals, Registrations, and Patient Consents

The patients were informed that deidentified data concerning the case would be submitted for publication, and consent was provided.

### Data Availability

Any anonymized data not published within this article will be made available by request from any qualified investigator.

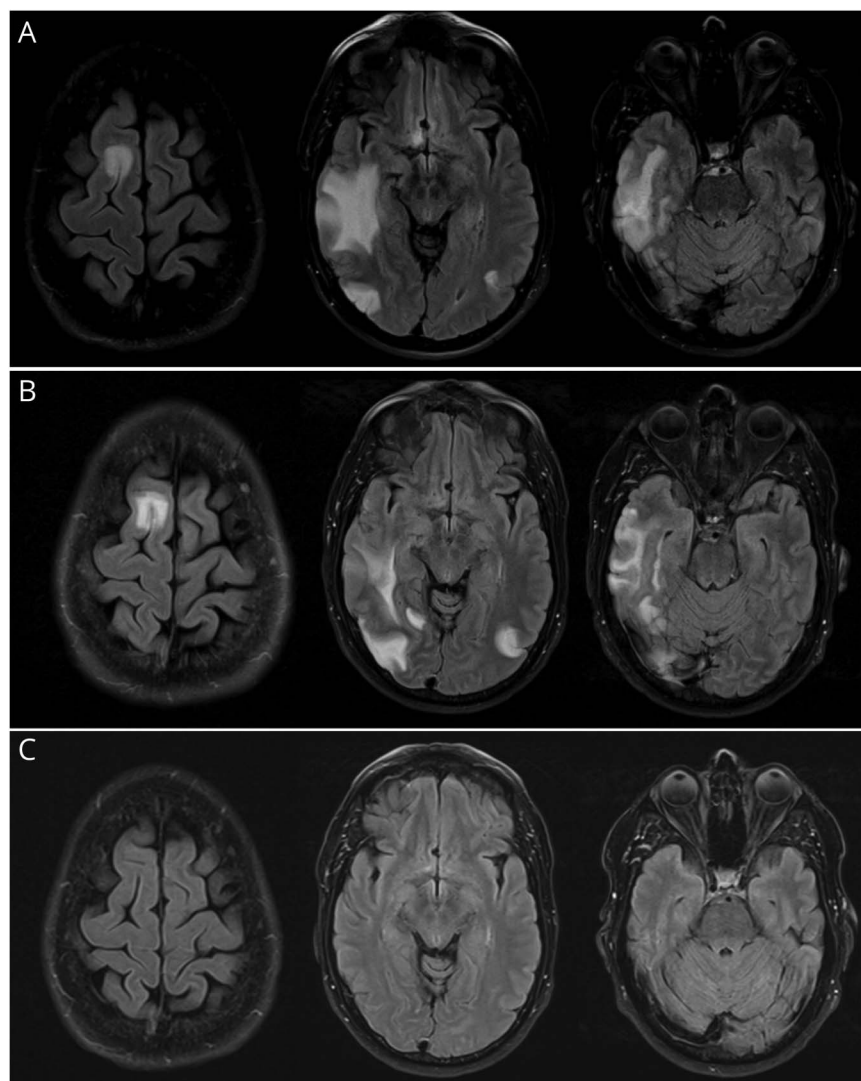
## Results

Two cases were diagnosed at the University of Utah (cases 1 and 2), and one was diagnosed at the University of Pennsylvania (case 3).

### Case 1

A 52-year-old man with a 4-year history of MM presented to the emergency department (ED) with intermittent headaches for 3 weeks, sometimes preceded by visual obscuration, described as “a colorful bee.” He had received induction treatment with cyclophosphamide, bortezomib, and dexamethasone and then proceeded to a melphalan-based aHSCT 43 months prior. He had completed maintenance with lenalidomide, bortezomib, and dexamethasone 6 months before neurologic presentation. Physical and neurologic examinations at presentation were unremarkable. Brain MRI with and without contrast demonstrated multifocal patchy areas of cortical and subcortical nonenhancing T2-weighted (T2w)/fluid-attenuated inversion recovery (FLAIR) hyperintense areas, involving both cerebral hemispheres, which were greatest in the lateral right temporal lobe (Figure 1A). Serum lab tests were negative for C-reactive protein (CRP), erythrocyte sedimentation rate (ESR), antinuclear antibodies (ANA), antineutrophil cytoplasmic antibodies (ANCA), extractable nuclear antigen antibodies (anti-SS-A, anti-SS-B, anti-Smith, anti-RNP, anti-Jo-1, anti-Scl 70, anticentromere), and neural antibodies, including aquaporin-4 receptor, glutamic acid decarboxylase, anti-N-methyl-D-aspartate receptor, and voltage-gated potassium channel complex screening. He underwent CSF analysis, demonstrating a normal white blood cell (WBC) count (2/ $\mu$ L), slightly elevated protein level (59 mg/dL), normal glucose level, and matched oligoclonal bands (OCB) in the serum and CSF. The CSF IgG index was normal at 0.48. Additional CSF tests were all negative, including cytology, flow cytometry, John Cunningham (JC) virus PCR, and meningitis/encephalitis (ME) panel. The patient was discharged without treatment, with a close neurology follow-up.

Four days after discharge, the patient returned to the ED with new-onset generalized tonic-clonic seizures. He had been experiencing mild cognitive symptoms, episodes of feeling “pulled to the left” and lip smacking. He also reported ongoing headaches with visual obscuration. Neurologic examination at this time demonstrated subtle left lower quadrantanopia without any other deficits. Repeat MRI with and without contrast confirmed multifocal areas of parenchymal signal within the bilateral cerebral hemispheres on T2w/FLAIR imaging. Repeat CSF analysis demonstrated a normal WBC count (2/ $\mu$ L), elevated protein level (69 mg/dL), normal glucose level, and matched OCB. The CSF IgG index was 0.49. Flow



(A) Brain MRI findings at the time of presentation. Multifocal patchy areas of cortical and subcortical T2w/FLAIR hyperintensity, involving both cerebral hemispheres, are shown. Involvement is greatest in the lateral right temporal lobe, with additional prominent foci of involvement along the right superior frontal gyrus, posterior left temporal lobe, and right occipital lobe. (B) Repeat brain MRI 2 weeks after initiation of treatment. Unchanged distribution of multifocal cortical and subcortical abnormality. Findings are mildly decreased in the right temporal lobe but mildly increased in the bilateral inferolateral occipital lobes. (C) Repeat brain MRI 3 months after hospitalization. Post-treatment resolution of the previously described cortical and subcortical T2w/FLAIR hyperintensities, previously demonstrated in the bilateral frontal and temporal lobes, is shown. FLAIR = fluid-attenuated inversion recovery.

cytometry, herpes simplex virus-1/2, Mayo Clinic Laboratories serum, and CSF neurologic autoantibody panel test (ENS1, ENC1) results were all negative. Continuous EEG detected intermittent rhythmic delta activity in the right frontotemporal region, consistent with nonspecific focal cerebral dysfunction. Antiepileptic therapy was initiated with levetiracetam (1,000 mg twice daily). At this point, GABA<sub>A</sub>R encephalitis was suspected based on its characteristic clinical–radiologic presentation as in cases 2 and 3. Empiric treatment was started with a 5-day course of IV methylprednisolone (1,000 mg daily) with concomitant initiation of plasmapheresis for a total of 5 days of treatment. Immediately following this, treatment with rituximab (1,000 mg) was initiated (the first 2 treatments were 2 weeks apart and then every 6 months thereafter) along with oral prednisone (60 mg daily). Repeat brain MRI 2 weeks after initiation of treatment demonstrated an unchanged distribution of multifocal lesions with findings mildly decreased in the right

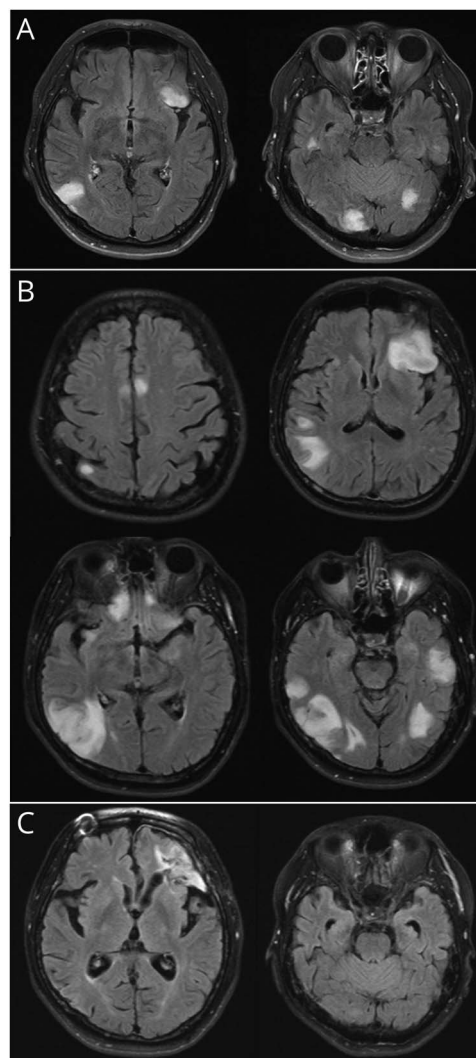
temporal lobe but mildly increased in the bilateral inferolateral occipital lobes (Figure 1B). At the time of discharge, the patient was asymptomatic, without additional seizure activity. Serum and CSF analysis revealed the presence of anti-GABA<sub>A</sub>R antibodies after discharge. At 1-month follow-up after hospitalization, the patient remained asymptomatic without seizure activity. At this time, oral prednisone was tapered off over 2 months. Three months after discharge, routine EEG was normal, and repeat brain MRI demonstrated nearly complete resolution of his cortical and subcortical abnormalities (Figure 1C). He returned to full-time work within the year. A PET scan evaluation for MM performed 9 months after hospitalization showed unchanged lytic lesions and a diffuse heterogeneous marrow signal without new lesions. Chest CT showed no evidence of thymoma or lung cancer. He is currently receiving rituximab every 6 months with a tentative plan to continue treatment for at least 2–3 years.

## Case 2

A 61-year-old man with a 2-year history of MM presented to the ED with a 3-day history of headaches, imbalance, and visual obscurations that he described as “a butterfly moving” in his left visual field. Eighteen months prior, he had received induction treatment with cyclophosphamide, bortezomib, and dexamethasone and then proceeded to a melphalan-based aHSCT. The patient was maintained on lenalidomide. His aHSCT course was unremarkable. He also had a medical history of prostate cancer that was treated with brachytherapy 6 years prior. On presentation, physical and neurologic examinations were notable only for a length-dependent neuropathy that began when he was taking bortezomib. Brain MRI with and without contrast demonstrated multifocal T2w/FLAIR hyperintensities in the left frontal operculum, right temporal lobe, and bilateral occipital lobes, involving gray and white matter without contrast enhancement (Figure 2A). Serum tests were negative for CRP, ANA, anti-double-stranded DNA, anti-SS-A antibody, anti-SS-B antibody, ANCA, antiphospholipid panel, rheumatoid factor, beta-2 microglobulin, protein C, protein S, HIV, and rapid plasma reagin. The prostate-specific antigen level was normal at 0.2 ng/mL. The ESR was mildly elevated at 25 mm/h. CSF analysis showed a normal WBC count (2/ $\mu$ L), mildly elevated total protein level (45 mg/dL), normal glucose level (61 mg/dL), and matched OCB in the CSF and serum, which is consistent with a systemic immune reaction. The CSF IgG index was normal at 0.55. CSF Gram stain, aerobic culture, cytology, flow cytometry, and ME panel tests were all negative. Continuous EEG captured multiple electrographic seizures without an obvious clinical correlation. The patient was started on levetiracetam (500 mg twice a day) and was discharged initially with a plan to continue lenalidomide with close follow-up.

Two weeks after the discharge, he presented to the ED feeling increasingly fatigued, with decreased cognitive function (Montreal Cognitive Assessment score of 11) and ongoing visual obscurations. His daughter reported that the patient had been speaking slower, became slower in his thought process, and walked slower. Neurologic examination at this presentation revealed significant encephalopathy and new left hemianopsia. His brain MRI with and without contrast demonstrated an interval increase in the size of the existing bilateral areas with new T2w/FLAIR-hyperintense lesions without contrast enhancement (Figure 2B). Continuous EEG showed multifocal slowing, sharp waves, and multiple seizures in the right occipital and left frontocentral regions. Repeat CSF analysis demonstrated an elevated WBC count at 9/ $\mu$ L (97% lymphocytes), elevated protein level (61 mg/dL), normal glucose level (61 mg/dL), and matched OCB in the CSF and serum. The CSF IgG index was 0.49. Additional CSF tests were negative for the meningitis encephalitis panel, West Nile virus antibody, JC virus PCR, cytology, and flow cytometry. The Mayo Clinical Laboratories serum and CSF neurologic autoantibodies panels (ENS1, ENC1) returned negative results. At this point, CSF samples were sent to the University of Pennsylvania for GABA<sub>A</sub>R antibody testing. During admission, seizures were treated with

**Figure 2** Serial Brain Magnetic Resonance Imaging (Case 2)



(A) Brain MRI findings at the time of presentation. T2w/FLAIR signal abnormalities in the left frontal operculum, right temporal lobe, and bilateral occipital lobes are shown. (B) Repeat brain MRI 2 weeks after the first presentation. Worsening appearance of existing bilateral supratentorial T2w/FLAIR-hyperintense lesions shown over time. New lesions have developed involving the paramedian frontal lobes bilaterally and the high right parietal lobe. (C) Repeat brain MRI 5 months after hospitalization. Posttreatment resolution of most of the scattered patchy hyperintense regions of parenchymal signal abnormality is observed. Left frontal encephalomalacia is secondary to intraparenchymal hemorrhage. FLAIR = fluid-attenuated inversion recovery.

levetiracetam (1,000 mg twice daily), and the patient later transitioned to lacosamide (100 mg twice daily). A brain biopsy was performed, which was notable only for nonspecific astrogliosis, increased microglia, and rarefied white matter. He was treated empirically with IV methylprednisolone (1,000 mg daily) for 6 days, followed by IV immunoglobulin (IVIg) (2 g/kg) over 3 days. One month after admission, he was treated with rituximab (1,000 mg) IV, with a second dose 2 weeks later. His recovery was delayed because of hemorrhagic transformation at the initial biopsy site, and a second biopsy was performed (showing nonspecific gliosis again). After a total of 5 weeks of hospitalization, he was discharged to inpatient rehabilitation.

Serologic testing for GABA<sub>A</sub>R antibodies was positive after discharge. Three months posthospitalization, he demonstrated significant clinical improvement of the encephalopathy and visual symptoms. He continued with IV rituximab (1,000 mg every 6 months) along with antiepileptic therapy to address his risk of epilepsy due to postbiopsy changes. Follow-up brain MRI with and without contrast approximately 5 months after hospitalization demonstrated a significant response to treatment with resolution of most of the T2w/FLAIR cortical and subcortical lesions (Figure 2C). A PET scan was performed to evaluate his MM, revealing a stable size and number of lytic lesions with no hypermetabolism to suggest active disease. Chest CT showed no evidence of thymoma or lung cancer.

During the remaining follow-up visits, he continued to demonstrate excellent clinical improvement and returned to previous activities and employment. His rituximab was discontinued after 2 years and 8 months (7 infusions in total), followed by a recurrence of clinical and radiographic disease activity 15 months after the last dose of rituximab. Immunotherapy was promptly reinitiated with subsequent return to full clinical function.

### Case 3

A 62-year-old man with a history of aHSCT for MM developed vertigo with falls on standing and mild confusion. He had received induction treatment with lenalidomide, bortezomib, and dexamethasone and then proceeded to a melphalan-based aHSCT 9 months prior. His aHSCT course was unremarkable, and he was receiving lenalidomide maintenance therapy.

He first presented at an outside hospital, where physical and neurologic examinations and brain MRI with and without contrast were unremarkable. He had no apparent seizures at that time. His symptoms progressed over the next 2–3 weeks, and he became very nauseated and had difficulty moving due to intractable vertigo. He presented to the University of Pennsylvania for further evaluation and management. Initial serum lab tests and CSF analysis showed nondiagnostic results. Brain MRI at that time revealed multifocal, nonenhancing cortical and subcortical T2w/FLAIR hyperintensities with temporal lobe involvement. A brain biopsy was performed and showed nonspecific inflammatory changes. He was initiated on a 5-day course of IV methylprednisolone. Although the diagnosis was unclear, his symptoms and the MRI abnormalities subsequently improved, and he was discharged home.

One month later, the patient returned to the hospital with confusion and mania. His family reported that he had become irrational and experienced multiple falls. Repeat brain MRI showed worsening multifocal, nonenhancing, cortical and subcortical T2w/FLAIR hyperintensities. Continuous EEG during this admission detected intermittent electrographic seizure activities. Anti-GABA<sub>A</sub>R encephalitis was suspected based on its characteristic radiologic findings and seizures. He was started with a 5-day course of IV methylprednisolone at 1,000 mg daily, followed by 3 courses of plasmapheresis. However, his condition continued to evolve, and he became

unresponsive for 3 weeks, during which time CSF and serum testing results returned, and revealed the presence of anti-GABA<sub>A</sub>R antibodies. He was started on rituximab (with the first 2 treatments 2 weeks apart and every 6 months thereafter) along with an additional 5-day course of IV methylprednisolone followed by a 5-day course of IVIg. He also received cyclophosphamide thereafter.

During the postdischarge follow-up, his condition continued to improve, and he was able to return to full function; he had a normal physical examination 2 months after discharge. Brain MRI also demonstrated nearly complete resolution of his cortical and subcortical abnormalities. A PET scan was performed to evaluate his MM, revealing stable multiple lytic bone lesions, but no other evidence of cancer, including thymoma. Chest CT did not demonstrate any evidence of thymoma or lung cancer. He continued to report occasional myoclonic-like movements in his hands and legs; however, routine EEG was unremarkable, and no convulsive episodes were reported.

## Discussion

We describe 3 cases of anti-GABA<sub>A</sub>R encephalitis in patients with a history of aHSCT for MM (Table). In this series, all patients were male, with ages at onset of encephalitis between 52 and 62 years. The time from the completion of aHSCT to the onset of encephalitis symptoms ranged from 9 to 43 months. These data are consistent with a previous report, which described a 62-year-old man who developed anti-GABA<sub>A</sub>R encephalitis 10 months after an aHSCT.<sup>4</sup> MM is a condition that affects mainly older adults with a median age at diagnosis of 65–74 years. Thirty-seven percent of patients are younger than 65 years, and 10% are younger than 50 years.<sup>5</sup> The younger age of our patient population at the diagnosis of MM can be explained by the data supporting the administration of a 3-drug induction therapy plus aHSCT for patients younger than 65 years with no major underlying medical issues.<sup>5</sup> Our current findings showed that new-onset seizures and cognitive impairment were the most common clinical manifestations seen in all 3 cases. In a previous study, seizures were reported to be the most common symptom (88%), followed by altered cognitive function (67%).<sup>4</sup> Also consistent with the previous study, in which brain MRI abnormalities were reported in 88% of cases, usually involving the temporal lobes (95%),<sup>4</sup> all cases in our report showed temporal lobe involvement, as well as both gray and white matter involvement. All 3 cases tested positive for anti-GABA<sub>A</sub>R antibodies in the CSF. Cases 1 and 3 also tested positive for anti-GABA<sub>A</sub>R antibodies in the serum (serum test was not performed in case 2). Available data do not indicate whether serum or CSF should be tested preferentially because of the rarity of the condition. In a previous study analyzing 16 patients with paired serum and CSF samples, 14 had antibodies in both and 2 only in serum,<sup>4</sup> suggesting that when possible, patients with suspected

**Table** Main Clinical Features and Treatment

Case	Age, y/sex	Clinical features on presentation	Malignancies	Period after aHSCT	Time from presentation to diagnosis	Anti-GABA <sub>A</sub> R Ab	First-line treatment	Second-line treatment	Other diagnostic procedure	Outcome
1	52/M	Headaches, visual obscuration, cognitive impairment, generalized seizures.	MM (diagnosed 49 mo prior)	43 mo	8 d	CSF, serum	IVMP, PLEX, Prednisone	RTX	None	Returned to previous activities and employment within a year.
2	61/M	Headaches, visual obscurations, cognitive impairment, imbalance.	MM (diagnosed 28 mo prior) Prostate cancer (brachytherapy 6 y prior, CR)	18 mo	22 d	CSF	IVMP, IVIg	RTX	Brain biopsy	Returned to previous activities and employment within a year.
3	62/M	Intractable vertigo, falls, nausea, confusion, mania.	MM (diagnosed 15 mo prior)	9 mo	3 mo (had a 5-d course of IVMP 3 wk after presentation)	CSF, serum	IVMP, PLEX, IVIg	RTX, CTX	Brain biopsy	Residual myoclonic-like movements in his legs and hands.

Abbreviations: aHSCT = autologous hematopoietic stem cell transplant; anti-GABA<sub>A</sub>R Ab = anti-γ-aminobutyric acid type A receptor antibody; CR = complete resolution; CTX = cyclophosphamide; IVIg = IV immunoglobulin; IVMP = IV methylprednisolone; M = man; MM = multiple myeloma; PLEX = plasmapheresis; RTX = rituximab.

anti-GABA<sub>A</sub>R encephalitis should have testing on both serum and CSF.

In cases 1 and 2, the patients were started on treatment for anti-GABA<sub>A</sub>R encephalitis within 8 and 22 days, respectively. In case 3, although the patient had a 5-day course of steroid treatment, the treatment for anti-GABA<sub>A</sub>R encephalitis was delayed for 3 months. The patient did not have histories of convulsion or electrographic seizures for 2 months after the first presentation, making the diagnosis of anti-GABA<sub>A</sub>R encephalitis challenging. Interestingly, both cases 1 and 2 first presented with headache and visual obscuration before seizures.

Two patients (cases 2 and 3) underwent brain biopsy before initiating therapy, which is characteristically bland in this condition; they presented only nonspecific astrogliosis and increased microglia in the white matter but no lymphocyte infiltration or activated macrophages. This highlights the importance of not excluding the possibility of autoimmune encephalitis if brain biopsy lacks inflammation when clinical and radiologic features are suggestive. In case 1, we were able to initiate empiric immunotherapy early and without a brain biopsy because of the high suspicion of anti-GABA<sub>A</sub>R encephalitis based on its characteristic clinical–radiologic presentation. Using these patients' cases, we hope to raise awareness and potentially prevent brain biopsy in similar characteristic cases in the future. As noted in the consensus guidelines, the current diagnostic criteria for autoimmune encephalitis is too reliant on antibody testing and the response to immunotherapy.<sup>6</sup> Timely recognition and treatment of autoimmune encephalitis is crucial to mitigating the consequent burden of cognitive impairment and neurologic disability that can result from this condition,<sup>7</sup> but at present, commercial testing for GABA<sub>A</sub>R antibodies is often not readily available. In addition, the detection of neuronal surface antibodies using the commercial assay has been reported to show false negative

results in a substantial number of patients, especially in CSF samples, underscoring the importance of the recognition of the clinical characteristics of anti-GABA<sub>A</sub>R encephalitis to prevent delays in the initiation of appropriate immunotherapy.<sup>8</sup>

Autoimmune complications in a patient with a history of aHSCT have been reported, with immune thrombocytopenia, thyroid dysfunction, and myasthenia gravis being the most common autoimmune diagnoses. The mechanism of autoimmune complications is not clearly understood, but it is postulated to be multifactorial and involve post-aHSCT immune dysregulation, genetic predisposition, and environmental factors, such as infections.<sup>9</sup> MM itself occurs in the context of a variety of autoimmune conditions.<sup>10</sup> Although autoimmunity affecting the CNS in the posttransplant setting has been reported in some studies, it is rare. A retrospective study over 13 years of the Mayo Clinic Neuroimmunology Laboratory database (Rochester, MN) demonstrated that only 3 patients met the criteria of autoimmune encephalitis by 2016 criteria<sup>6</sup> after solid-organ or hematopoietic stem cell transplantation.<sup>11</sup> In the series, 1 patient developed a new neurologic condition 38 months after aHSCT for MM and was diagnosed as acute disseminated encephalopathy with positive myelin oligodendrocyte glycoprotein antibodies.<sup>11</sup> A separate publication reported 1 case of anti-N-methyl-D-aspartate receptor encephalitis 16 months after kidney transplantation for radiation nephropathy preceded by stem cell transplant; however, the case was an allogeneic stem cell transplant for non-Hodgkin lymphoma.<sup>12</sup> The mechanism of developing autoimmune encephalitis posttransplant remains unclear.

We were unable to identify any reports of anti-GABA<sub>A</sub>R encephalitis in a patient who had a history of MM without subsequent aHSCT; however, we identified a report of another type of autoimmune encephalitis: anti-γ-aminobutyric acid, type B, receptor encephalitis in a nontransplanted patient

with MM.<sup>13</sup> Confounding factors secondary to other tumors, particularly thymoma, should be considered. In all our cases, chest CT and PET scan were performed during the follow-up and demonstrated no evidence of cancer except MM. Further studies are required to determine the relationship and mechanism between having aHSCT after MM and anti-GABA<sub>A</sub>R encephalitis.

This case series highlights the importance of recognizing the possibility of anti-GABA<sub>A</sub>R encephalitis in patients who develop seizures or characteristic MRI abnormalities after undergoing aHSCT for MM. Early awareness and collaboration between hematologists, neurologists, and neuroradiologists can prevent unnecessary brain biopsy and delayed diagnosis. In addition, early diagnosis and initiation of empirical immunotherapy while awaiting autoantibody results may help control refractory seizures and other neurologic dysfunctions and improve long-term functional outcomes.

## Acknowledgment

The authors are grateful for the generous support of the Barbara Gural Steinmetz Foundation in support of Autoimmune Neurology Research at the University of Utah.

## Study Funding

The authors report no targeted funding.

## Disclosure

Stacey L. Clardy reports the following disclosures: Section Editor, Neurology Podcast and Neurology Minute. Editorial Board, Neurology: Neuroimmunology and Neuroinflammation. Research support from NIH/NINDS (U01, The ExTINGUISH Trial), the Western Institute for Veteran Research, the Siegel Rare Neuro-immune Association, the Immune Deficiency Foundation, Viela Bio/Horizon, Alexion/AstraZeneca, the Barbara Gural Steinmetz Foundation, Sumaira Foundation for NMO. Consulting/Ad Board: Alexion, VielaBio/Horizon, Genentech/Roche, Guidepoint, ExpertConnect, Clarion Healthcare (\*Fees to U.Utah Development account). Medical Advisory Board of the Sumaira Foundation for NMO (unpaid). Employed full-time by: University of Utah Health and the Salt Lake City VA. The remaining authors report no disclosures relevant to this manuscript. Go to Neurology.org/NN for full disclosures.

## Publication History

Received by *Neurology: Neuroimmunology & Neuroinflammation* October 4, 2022. Accepted in final form November 7, 2022. Submitted and externally peer reviewed. The handling editor was Josep O. Dalmau, MD, PhD, FAAN.

## Appendix Authors

Name	Location	Contribution
<b>Yoji Hoshina, MD</b>	Department of Neurology, University of Utah Health, UT	Analysis and interpretation of the data and drafting the manuscript for intellectual content

## Appendix (continued)

Name	Location	Contribution
<b>Jonathan Galli, MD</b>	Department of Neurology, University of Utah Health, UT; Department of Neurology, Veterans Affairs Medical Center, UT	Revising the manuscript for intellectual content
<b>Ka-Ho Wong, MBA</b>	Department of Neurology, University of Utah Health, UT	Revising the manuscript for intellectual content
<b>Tibor Kovacovics, MD</b>	Division of Hematology and Hematologic Malignancies, Huntsman Cancer Institute, University of Utah Health, UT	Revising the manuscript for intellectual content
<b>Mary Steinbach, DNP, APRN</b>	Division of Hematology and Hematologic Malignancies, Huntsman Cancer Institute, University of Utah Health, UT	Revising the manuscript for intellectual content
<b>Karen L Salzman, MD</b>	Department of Radiology and Imaging Sciences, University of Utah Health, UT	Revising the manuscript for intellectual content
<b>Joseph Scott McNally, MD, PhD</b>	Department of Radiology and Imaging Sciences, University of Utah Health, UT	Revising the manuscript for intellectual content
<b>Eric Lancaster, MD PhD</b>	Department of Neurology, University of Pennsylvania, Philadelphia, PA	Analysis and interpretation of the data and drafting the manuscript for intellectual content
<b>M. Mateo Paz Soldán, MD, PhD</b>	Department of Neurology, University of Utah Health, UT; Department of Neurology, Veterans Affairs Medical Center, UT	Design and conceptualization of the study and revising the manuscript for intellectual content
<b>Stacey L. Clardy, MD PhD</b>	Department of Neurology, University of Utah Health, UT; Department of Neurology, Veterans Affairs Medical Center, UT	Design and conceptualization of the study and revising the manuscript for intellectual content

## References

- Macdonald RL, Olsen RW. GABAA receptor channels. *Annu Rev Neurosci*. 1994;17:569-602. doi: 10.1146/annurev.ne.17.030194.003033.
- Ohkawa T, Satake S, Yokoi N, et al. Identification and characterization of GABA(A) receptor autoantibodies in autoimmune encephalitis. *J Neurosci*. 2014;34(24):8151-8163. doi: 10.1523/JNEUROSCI.4415-13.2014.
- Petit-Pedrol M, Armangue T, Peng X, et al. Encephalitis with refractory seizures, status epilepticus, and antibodies to the GABAA receptor: a case series, characterisation of the antigen, and analysis of the effects of antibodies. *Lancet Neurol*. 2014;13(3):276-286. doi: 10.1016/S1474-4422(13)70299-0.
- Spatola M, Petit-Pedrol M, Simabukuro MM, et al. Investigations in GABA<sub>A</sub> receptor antibody-associated encephalitis. *Neurology*. 2017;88(11):1012-1020. doi: 10.1212/WNL.0000000000003713.
- Palumbo A, Anderson K. Multiple myeloma. *N Engl J Med*. 2011;364(11):1046-1060. doi: 10.1056/NEJMra1011442.
- Graus F, Titulaer MJ, Balu R, et al. A clinical approach to diagnosis of autoimmune encephalitis. *Lancet Neurol*. 2016;15(4):391-404. doi: 10.1016/S1474-4422(15)00401-9.
- Hébert J, Day GS, Steriade C, Wennberg RA, Tang-Wai DF. Long-term cognitive outcomes in patients with autoimmune encephalitis. *Can J Neurol Sci*. 2018;45(5):540-544. doi: 10.1017/cjn.2018.33.
- Ruiz-García R, Muñoz-Sánchez G, Naranjo L, et al. Limitations of a commercial assay as diagnostic test of autoimmune encephalitis. *Front Immunol*. 2021;12:691536. doi: 10.3389/fimmu.2021.691536.
- Sherer Y, Shoenfeld Y. Autoimmune diseases and autoimmunity post-bone marrow transplantation. *Bone Marrow Transpl*. 1998;22(9):873-881. doi: 10.1038/sj.bmt.1701437.

10. Shimanovsky A, Alvarez Argote J, Murali S, Dasanu CA. Autoimmune manifestations in patients with multiple myeloma and monoclonal gammopathy of undetermined significance. *BBA Clin*. 2016;6:12-18. doi: 10.1016/j.bbacli.2016.05.004
11. Cohen DA, Lopez-Chiriboga AS, Pittock SJ, et al. Posttransplant autoimmune encephalitis. *Neurol Neuroimmunol Neuroinflamm*. 2018;5(6):e497. doi: 10.1212/NXI.0000000000000497.
12. Zhao CZ, Erickson J, Dalmau J. Clinical reasoning: agitation and psychosis in a patient after renal transplantation. *Neurology*. 2012;79(5):e41-4. doi: 10.1212/WNL.0b013e3182616fad.
13. Jeffery OJ, Lennon VA, Pittock SJ, Gregory JK, Britton JW, McKeon A. GABAB receptor autoantibody frequency in service serologic evaluation. *Neurology*. 2013;81(10):882-887. doi: 10.1212/WNL.0b013e3182a35271.