

Wilson's Disease Update: An Indian Perspective

Niraj Kumar, Prashant LK¹, Vinay Goyal²

Department of Neurology, All India Institute of Medical Sciences, Rishikesh, Uttarakhand, ¹Center for Parkinson's Disease and Movement Disorders, Vikram Hospital, Bengaluru, Karnataka, ²Department of Neurology, Medanta Hospital, Gurugram, Haryana, India

Abstract

Wilson's disease (WD) is an autosomal recessive disorder due to ATP7B gene mutation, resulting in defective copper metabolism, with the liver and brain being primarily affected. WD being a treatable disorder, early diagnosis and proper management may result in near complete recovery. It has received significant attention over the past 50 years, with several Indian contributions. This study collates published Indian studies on WD in Pubmed and Embase databases and puts them in perspective. Several Indian case series suggest WD may be more prevalent than thought. Commonly detected ATP7B mutation in India is p.C271X. Although initial Indian series reported significant osseomuscular presentation, neuropsychiatric and hepatic manifestations dominated the later reports. A significant male predominance is observed in the Indian series. Pure hepatic presentation starts earlier than neurological or osseomuscular WD. A positive family history may be seen in nearly 50% of Indian WD cases, with a high rate of consanguinity. Up to two-third of the Indian cases may be initially misdiagnosed, with a mean diagnostic delay of up to 2 years. Abnormalities in serum ceruloplasmin and 24-hour urinary copper has been reported in more than four-fifth cases. Brain MRI is abnormal in nearly all neurological WD cases. Copper chelation remains the mainstay of therapy, with D-penicillamine being the most widely used chelator in India. Global Assessment Scale for WD is a comprehensive tool for clinical monitoring. Hepatic presentation carries a five-time higher mortality risk than neurological, with up to 90% Indian neurological WD cases recovering back to pre-morbid functionality with adequate therapy.

Keywords: D-penicillamine, Kayser-Fleischer ring, serum ceruloplasmin, urinary copper, Wilson's disease.

INTRODUCTION

Wilson's disease (WD) is an autosomal recessive neurometabolic disorder due to mutation in ATP7B gene on Chromosome 13q.^[1] This leads to defective copper metabolism resulting in excessive copper deposition in several organs, primarily involving liver and brain.^[1] Although Frerichs, in 1861, first described a child having movement disorders, with his autopsy findings showing liver cirrhosis, it was SAK Wilson who published a comprehensive description of the clinical and pathological features of "progressive lenticular degeneration" in 1912.^[2] Nearly four decades later, Dimercaprol was introduced in its treatment.^[3]

In 1956, Walshe reported the success of Penicillamine, an oral chelating agent, in the treatment of WD.^[4] The utility of zinc compounds in the treatment of WD was initially described by Schouwink in 1961.^[5] Walshe introduced Trientine in 1969 when he successfully used it to treat a WD patient who developed Penicillamine-induced nephropathy.^[6] Tetrathiomolybdate was initially tested in 1984.^[7] While Penicillamine, zinc and Trientine are widely used in WD, Tetrathiomolybdate is undergoing clinical trials.

India has been one of the geographical hot spots for WD.^[8] The World Health Organization (WHO) puts the global prevalence of WD at 30-100/million.^[9] WD affected 7.6% cases in a study of hepatobiliary spectrum disorders in North India.^[10] Although epidemiological data on neurological WD from India is lacking, a WD clinic from South India reported 15-20 new WD cases every year.^[11]

Recently, the Movement Disorders Society of India (MDSI), Indian National Association for Study of the Liver (NASL), The Indian Society of Paediatric Gastroenterology, Hepatology, and Nutrition (ISPGHN) have come with unified guidelines for the management of WD in India.^[1] This review addresses various works on WD done in India.

METHOD

We searched the literature for studies describing "Wilson's disease in India" till December 31, 2020. We searched Pubmed and Embase databases. Pubmed search was done using (((('Wilson's disease'[Title/Abstract]) or ('Wilson disease'[Title/Abstract])) or ('Wilson's disease'[Title/Abstract])) or ('Hepatolenticular degeneration'[MeSH Terms])) and (((India) or (India[MeSH Terms])) or (India[Title/

Address for correspondence: Dr. Niraj Kumar, Additional Professor, Department of Neurology, All India Institute of Medical Sciences, Rishikesh, Uttarakhand, India. E-mail: drnirajkumarsingh@gmail.com

Submitted: 12-May-2021 **Accepted:** 15-May-2021 **Published:** 14-Oct-2021

This is an open access journal, and articles are distributed under the terms of the Creative Commons Attribution-NonCommercial-ShareAlike 4.0 License, which allows others to remix, tweak, and build upon the work non-commercially, as long as appropriate credit is given and the new creations are licensed under the identical terms.

For reprints contact: WKHLRPMedknow_reprints@wolterskluwer.com

DOI: 10.4103/aian.AIAN_171_21

Abstract])). Search terms used for Embase database were: 'Wilson disease' or 'Wilson's disease' or 'Hepatolenticular degeneration' and 'India.'

Abstracts were read and studies meeting inclusion criteria were evaluated while those not meeting the review criteria and duplicate studies were excluded. Similarly, conference presentations were excluded. Search with the keywords mentioned above led to 1247 articles from Pubmed and Embase together (Supplementary document 1). Abstracts were read and 374 articles, primarily involving description of clinical works on Wilson's disease, fulfilled our search criteria. The decade-wise distribution of the number of these articles is depicted in Figure 1. Seventy-two of these articles describing clinical work on Indian WD cases were used to synthesize this review.

HISTORY OF WD DESCRIPTION FROM INDIA

More than half-a-century after Wilson's seminal work, WD was first reported from India by Wadia and Dastur in 1963.^[12] Since then several works have been published from India from various exclusive WD clinics from across India. A significant proportion of clinical work on Indian WD cases came from Mumbai by Prof. NH Wadia and Prof. DK Dastur early on and more recently by Dr. Mohit Bhatt, Dr. Anu Aggarwal and Dr. Aabha Nagral. Other major Indian centres include National Institute of Mental Health and Neurological Sciences (NIMHANS) Bangalore (Prof. H. Sathyanarayana Swamy, Prof. AB Taly, and Prof. Sanjib Sinha); All India Institute of Medical Sciences New Delhi (Prof. Madhuri Behari and Prof. Vinay Goyal); Sanjay Gandhi Post Graduate Institute Lucknow (Prof. UK Misra, Prof. J Kalita, and Prof. SK Yachha), St. John's Medical College Hospital, Bangalore (Prof. Harshad Devarbhavi), and Bangur Institute of Neurology Kolkata (Prof. SK Das and Prof. Kalyan Bhattacharya), S.N. Pradhan Centre of Neurosciences Kolkata (Prof. Jharna Ray) and Christian Medical College Vellore (Prof. Chundamannil E Eapen).

PATHOGENESIS

Since copper is toxic in free form, it is transported in a bound form (ceruloplasmin) from hepatic cells to several tissues

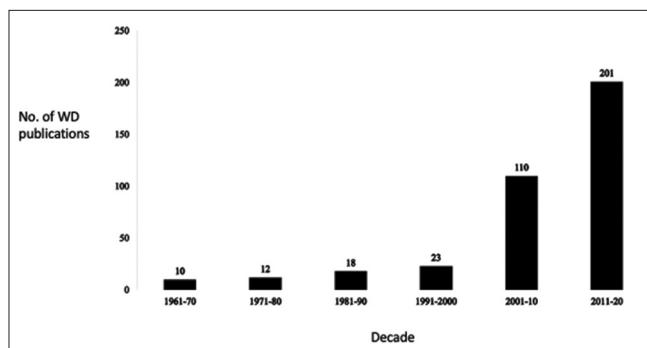


Figure 1: Histogram showing distribution of number of publications on Indian WD cases till December 31, 2020

and excess copper is excreted in bile.^[11] The ATP7B protein is involved in transport of copper for synthesis of copper-bound ceruloplasmin from apo-ceruloplasmin and biliary excretion of excess copper from hepatocytes. Mutation in the ATP7B gene on chromosome 13q results in failure of copper transport and abnormal accumulation of copper in hepatocytes and spillage of excess non-ceruloplasmin copper from liver cells to systemic circulation leading to its accumulation in several organs including the brain.^[1,11] A clinico-pathological report involving autopsy of eight WD patients reported a widespread neuropathology and lack of universal lenticular involvement.^[13]

Excess free copper in the liver, brain and other organs may either cause a direct toxic damage or result in failure of the antioxidant defence system leading to increased oxidative stress and free radical damage to local tissue.^[1,11] Sinha *et al.*,^[14] reported raised serum malondialdehyde (MDA), a marker of oxidative stress, in 10% WD cases, but failed to notice any significant difference in clinical status of patients with or without MDA elevation. Since patients were already receiving treatment for WD, a change in their oxidative state was likely. In a separate study, the same group reported elevated serum pro, as well as anti-inflammatory cytokines including TNF- α , IFN- γ , IL-2, IL-4, IL-6 in WD, but failed to correlate it with disease severity and therapeutic response.^[15] Reduction in serum tocopherol, a natural antioxidant, was reported in nearly 60% cases in a separate series, although it lacked clinical or biochemical correlation.^[16] Kalita *et al.*,^[17] recently reported a significant reduction in antioxidant capacity along with elevated MDA, cytokines and glutamate in WD, more pronounced in neurologic WD and untreated cases as compared to asymptomatic WD and treated cases respectively. The same group reported reduced antioxidant capacity and elevated MDA levels in neurological worsening following chelation therapy.^[18] Interestingly, the reported changes in oxidative state were associated with elevated serum free copper and 24-hour urinary copper in neurologically worsened cases.^[18]

GENETICS OF WD

More than 750 mutations in ATP7B gene have been reported to date.^[19] After the first report from North India,^[20] several genetic studies have been published from India. (Supplementary document 2) A recent study from South India reported 36 different ATP7B mutations, with 13 of them being novel ones.^[19] While p.His1069Glu mutation at exon 14 is most frequently reported in European population, p.Arg778Leu missense mutation at exon 8 is most common in Asians.^[19,21] A genetic study involving 43 WD patients from North-West India reported exons 8,12,13,15,16 and 18 as hot spots for mutations.^[22] Compared to the western world, a higher degree of homozygosity (up to 60%) have been reported in India,^[21] possibly related to intra-ethnic group or intra-caste marriages and consanguinity.^[21,23] While pC271X mutation is most commonly detected in India cases,^[21,24] a variety of other mutations are also reported.^[19,21,24]

While European WD cases with p.H1069Q mutations usually present in second or third decade of life with primarily neurological features, commonly detected p.C271X mutation in Indian cases result in severe clinical manifestations in the first or second decade of life.^[21] Mukherjee *et al.*,^[24] reported p.C271X and p.G1101R as the most common mutations in eastern and western India respectively in their cohort of 199 patients, but significantly lower number of patients from western as compared to eastern India (25 vs 174) was a major limitation in this study. Collating the major Indian genetic studies, mutation in p.C271X appears the most common mutation in western, southern as well as eastern India, with an allelic frequency of 20.2%, 10% and 16% respectively.^[21–23,25] Although the mutational pattern in India show a regional variation, few other overlapping mutations have also been reported in addition to p.C271X.^[21] While mutation in p.G1061E has been reported in western, southern and eastern India,^[21,23,26] that involving p.I1102T is observed in western, eastern and north-western India.^[21,22,26]

A recent study reports hepatosplenomegaly and extrapyramidal features including bradykinesia, rigidity and dystonia to be more likely associated with truncating mutations and tremor with missense mutations.^[19] Despite the ongoing genetic research, a correlation between specific ATP7B mutations and WD phenotype is lacking.^[1] In fact, affected siblings sharing common genetic mutations may differ phenotypically.^[25] Additional genetic, epigenetic and environmental factors may influence clinical phenotypes in WD and contribute to the varied clinical presentation.^[19,21]

CLINICAL FEATURES

WD has a heterogenous clinical presentation ranging from asymptomatic to acute/chronic liver involvement and neuropsychiatric illness.^[1] The largest Indian series of 282 patients by Taly *et al.*,^[27] reported initial neurologic manifestations in 70% cases, with 15% cases having initial hepatic and 4% cases having both hepatic and neurologic presentation. While one-third cases in the initial Indian report by Manghani and Dastur had osseomuscular presentation,^[28] neuropsychiatric and hepatic manifestations predominated in the later series.^[27]

Aggarwal *et al.*,^[21] reported that the age of onset in Indian patients is usually earlier as compared to those from Europe, Korea and South America. While pure hepatic Indian WD cases may present in the first decade of life, neurological manifestations commonly appear in the second decade.^[27] Pure psychiatric and osseomuscular manifestations are common in the third decade.^[27] Most Indian series report a significant male predominance (M: F = 2.7:1),^[27,29–33] with the androcentric nature of Indian society being a likely contributor. Males outnumbered females in a large European series involving 627 WD cases, but showed only minimal male predominance (M: F = 1.16:1).^[34] As observed in other extrapyramidal disorders including Parkinson's disease,

protective role of estrogen in females and iron metabolic differences may contribute to male predominance.^[34] Nearly half the Indian cases may have a positive family history and/or consanguineous parentage, higher than the west.^[27] Children of consanguineous parentage manifest earlier.^[27] The mean diagnostic delay of 16–28 months in Indian cases may result from delay in seeking medical care due to illiteracy and poverty or want of adequate medical facility.^[27,31,32,35] Table 1 includes the demographic, clinical and investigational profile along with outcomes reported in various Indian series. The clinical features of WD are depicted in Figure 2 and salient points are described below:

Hepatic manifestations

Clinical or biochemical liver derangement involves nearly all WD cases. It commonly manifests in first decade of life and vary from asymptomatic stage to liver cirrhosis.^[1] Pandit *et al.*,^[39] from West India reported acute hepatitis and fulminant hepatic involvement each in 10% of WD cases, with one-third cases showing chronic hepatic involvement. Liver cirrhosis may be detected during the work-up for an acute hepatic involvement in WD.^[21] An episode of viral hepatitis may unmask or trigger hepatic WD.^[1] WD may contribute to more than two-fifth cases of chronic liver disorder in children. (Supplementary document 2) Hepatocellular carcinoma and cholangiocarcinoma have rarely been reported in long-standing WD cases. (Supplementary document 2).

Neurological WD

Extrapyramidal features are most common neurological manifestations in Indian cases,^[27] similar to reports from world literature. Taly *et al.*,^[27] reported parkinsonism in nearly two-third cases, dystonia and ataxia in one-third cases, pyramidal features in 16% and chorea, athetosis and myoclonus in less than 10% cases. Craniofacial dystonia may cause typical “Wilsonian facies,” characterized by dull looking face with “Vacuous smile” and drooling of saliva [Figure 3].^[1] Seizures may be seen in 8–38% cases, probably resulting from direct copper toxicity, liver related metabolic derangements or pyridoxine deficiency related to Penicillamine use.^[27,31,32,35,44,45] Patients with extensive lesions on brain MRI, especially cortical ones, are likely to manifest seizures.^[44] Cognitive deficits have been reported in 23–78% Indian WD cases.^[27,31–33,35] Abnormalities in motor speed, verbal working memory along with attention is common in Indian cases.^[46]

Psychiatric features

In his monograph, Wilson reported psychiatric features in two-third cases.^[2] Psychiatric manifestations may dominate the clinical presentation in WD.^[47] Psychiatric features including mania, depression, suicidal tendencies and schizophrenia like illnesses have been reported in 16–43% Indian WD cases.^[27,31,32] Using structured clinical interview, Shanmugiah *et al.*,^[48] reported syndromic psychiatric disorders in 24% cases, with bipolar affective disorder (18%) being most common. Unusual features including catatonia and obsessive-compulsive disorder have also been reported. (Supplementary document 2).

Table 1: Demographic, Clinical, Investigational Profile and Outcome Pattern Reported in Indian Studies Describing at least 20 or more cases with Wilson's Disease

Authors & year (Place in India)	No. of cases (M: F)	Mean age of onset (Range)	Clinical features & biochemical investigations								Outcome with treatment		
			H.S (%)	N.S (%)	H+N.S (%)	A.S (%)	O.S (%)	KFR (%)	Low CP (%)	High UC (%)	Imp (%)	No imp (%)	Death (%)
Dastur <i>et al.</i> ^[29] (1968, Mumbai)	23 (15:8)	13.4 (4-25)	4.3	43.5	8.7	8.7	34.8	-	-	-	-	-	-
Raiamani <i>et al.</i> ^[36] (1987 Vellore)	30 (22:8)	-	36.7	43.3	0	0	20	-	-	-	-	-	-
Jha <i>et al.</i> ^[31] (1998, New Delhi)	22 (20:2)	18.5 (10-33)	-	-	-	-	-	95.4	86.4	100	-	-	-
Kalra <i>et al.</i> ^[37] (2000, New Delhi)	25	6.8 (H.S.) 8 (N.S.)	20	20	36	16	8	-	-	-	-	-	-
Richard <i>et al.</i> ^[38] (2000, Vellore)	60	12* (5-52)	60	40	-	-	-	-	-	-	-	-	-
Sinha <i>et al.</i> ^[32] (2001, Ranchi)	49 (38:11)	11.3 (8-23)	0	71.4	30.6	0	0	97.9	93.8	-	95.8	4.2	-
Pandit <i>et al.</i> ^[39] (2002, Pune)	124	8.4 (4-60)	54.03	22.6	0	15.3	0	-	-	-	-	-	-
Taly <i>et al.</i> ^[27] (2007, Bangalore)	282 (196:86)	15.9 (3-50)	14.9	69.1	3.5	5.3	7.1	95.4	93.1	70.1	87.1	12.3	8.1
Panagariya <i>et al.</i> ^[35] (2007, Jaipur)	21 (14:7)	13.2	0	100	0	0	0	100	85.7	100	85.7	14.3	-
Tryambak <i>et al.</i> ^[40] (2009, Kolkata)	34	7.7	50	20.6	-	23.5	5.9	32.3	82.3	100	78.2	-	-
Soni <i>et al.</i> ^[41] (2009, New Delhi)	30 (17:13)	14 (7-35)	0	96.7	0	0	3.3	-	-	-	-	-	-
Aggarwal <i>et al.</i> ^[21] (2013, Mumbai)	52 (30:22)	11.6	28.8	65.4	0	1.9	0	-	-	-	-	-	-
Pulai <i>et al.</i> ^[42] (2014, Kolkata)	78 (52:26)	14.71	100	-	-	-	-	-	-	-	-	-	-
Ranjan <i>et al.</i> ^[33] (2015, Lucknow)	34 (28:6)	11* (7-39)	0	100	0	0	0	-	-	-	-	-	-
Gupta <i>et al.</i> ^[43] (2018, Vellore)	31 (21:10)	-	67.7	0	32.3	0	0	87	94	97	90	-	-

* Median age. Abbreviations: A.S: asymptomatic; CP: ceruloplasmin; H.S: hepatic symptoms; H+N.S: hepatic and neurologic symptoms; Imp: clinical improvement; KFR: Kayser-Fleischer rings; N.S: neurologic symptoms; O.S: Other symptoms; UC: 24-hour urinary copper

Ocular features

Kayser-Fleischer (KF) rings has been detected in 97-100% neurologic Indian WD cases,^[27,32,35] 14-87% hepatic WD^[27,43] and up to 60% pre-symptomatic cases.^[27] Greenish-brown in colour, KF rings result from copper deposition in Descemet's membrane [Figure 3]. Starting at upper corneal margin, KF ring spreads to the lower followed by medial and then lateral margins of cornea.^[1] Copper deposition in anterior capsule of lens forms sunflower cataract, which is uncommon, reported in 2-17% cases.^[1,49]

Osseomuscular features

Although only 2% cases may report osseomuscular features at presentation, up to 14% cases may have such manifestations. Nearly 40% cases showed radiological osteoporosis.^[27] Commonly reported musculoskeletal features in WD include large-joint polyarthritis involving especially knees, low back pain, osteomalacia, refractory rickets, spontaneous fractures

and limb deformities.^[1,50] These features may result from metabolic derangements including inadequate dietary intake of essential minerals and vitamins, renal involvement impairing calcium and phosphorus absorption, and hypoparathyroidism either due to copper accumulation in parathyroid gland or secondary to renal disease.^[27,28] Several Indian authors have reported WD cases developing metabolic bone disease due to renal tubular acidosis. (Supplementary document 2) Interestingly, significant osseomuscular involvement in children with WD may rarely result in initial misdiagnosis of "muscular dystrophy", with further work-up revealing the correct diagnosis.^[51]

Renal features

Copper deposition in epithelium of proximal and distal convoluted tubules result in hypercalciuria and hyperphosphaturia leading to nephrocalcinosis, nephrolithiasis and Vitamin D-resistant rickets.^[1] Kapoor *et al.*,^[52] reported

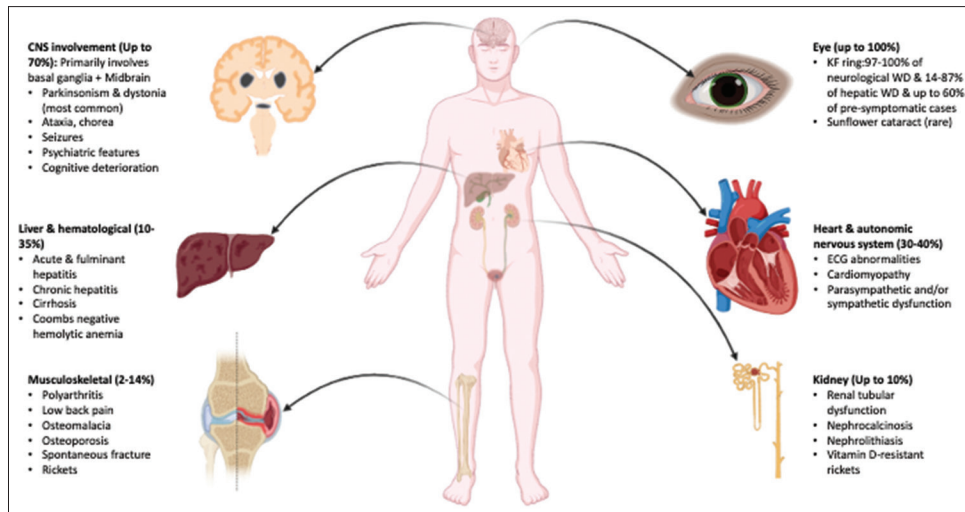


Figure 2: Major organs involved along with resulting clinical manifestations in Wilson's disease

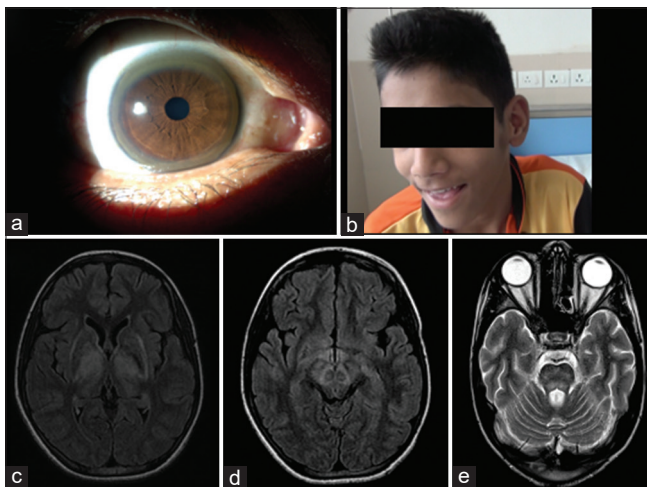


Figure 3: Clinical and brain MRI findings in Wilson's disease. (a) KF ring on slit-lamp examination; (b) Wilsonian dystonic smile. Axial FLAIR MRI brain sequence showing (c) involvement of bilateral thalamic and lateral putamen (bright claustrum sign) and (d) the typical "Face of giant panda sign." (e) Axial T2 MRI brain sequence shows pontine hyperintensity.

renal tubular acidosis in more than half the patients with WD, more common in hepatic WD of longer disease duration. These patients often manifest with metabolic bone disorders. Additionally, chelation with D-penicillamine may cause glomerular dysfunction with resulting proteinuria. Nephrotic-range proteinuria due to D-penicillamine warrants its discontinuation.^[1]

Other features

Cardiomyopathy, cardiac arrhythmias and autonomic dysfunction have been reported in WD.^[1,53] Meenakshi-Sundaram *et al.*,^[54] reported electrocardiogram abnormalities in up to 30% of cases, possibly related to cardiac copper deposition. The same group earlier reported autonomic dysfunction in up to 40% WD cases, more prominent in neurologic WD, possibly related to copper deposition in diencephalon, hypothalamus

and brainstem nuclei.^[55] WD may commonly affect sleep. Netto *et al.*,^[56] reported a significant reduction in total sleep, sleep-efficiency and rapid eye movement sleep along with prolonged sleep-onset latency in WD patients.

Other manifestation of WD including generalized hyperpigmentation, coombs-negative hemolytic anemia, endocrinal abnormalities such as short-stature, diabetes, hypoparathyroidism and menstrual irregularities and non-hepatic malignancies such as retinoblastoma, basal cell carcinoma, leukemia and glioblastoma multiforme have also been reported. (Supplementary document 2).

Diagnosis

Early diagnosis of WD is of utmost importance for prompt initiation of treatment and a favourable outcome. Prashanth *et al.*,^[8] reported misdiagnosis in up to 63% of WD cases, causing a mean diagnostic delay of 2 years (0.8-30 years). Keeping a very low threshold for clinical suspicion is helpful. Evaluation by an experienced ophthalmologist on a slit-lamp must be done before declaring absence of KF ring in a clinically suspected patient.

Biochemical investigations

Assessment of copper and ceruloplasmin in serum and 24-hour urinary copper aid in diagnosing WD.

Serum ceruloplasmin

Although normal or slightly reduced serum ceruloplasmin levels may be reported, a value below 10 mg/dl (Normal = 20-40 mg/dl) in a clinically suspected cases is highly suggestive of WD.^[1] Low serum ceruloplasmin has been reported in 85-95% Indian cases.^[27,31,32,35] Reduced serum ceruloplasmin may also be detected in other chronic liver disorders, protein losing enteropathy, nephritic syndromes, Menke's disease and aceruloplasminemia.^[1] Being an acute phase reactant, ceruloplasmin levels may falsely rise to normal range if the patient has a coincidental acute inflammatory condition.^[1]

Twenty-four-hour urinary copper

Although 24-hour urinary copper may be elevated in heterozygous WD carriers and obstructive liver disorders, levels >100 mcg/dl are highly suggestive of WD,^[1] and has been reported in 70-100% Indian WD cases.^[27,31,35] Use of copper-free container to store urine is essential. The levels may be falsely low in asymptomatic WD cases.^[1] Taly *et al.*,^[27] reported levels >160 mcg/dl in 70% cases.

Serum copper

It measures both ceruloplasmin-bound and free serum copper. Low serum copper have been reported in 57-77% Indian cases.^[32,35] Testing potentially dangerous unbound copper is less reliable as its value depends on that of serum ceruloplasmin and total serum copper.^[1]

Hepatic copper

Estimating liver copper level by liver biopsy is highly sensitive and accurate for diagnosing WD, though difficult logistically. It can be elevated even in asymptomatic cases. A level >250 mcg/g of dry weight (Normal ≤50) is suggestive of WD.^[1]

Neuroimaging

CT brain

Cortical atrophy and ventricular dilatation are the most common finding in CT brain, each involving up to 45% Indian WD cases. Brainstem and caudate atrophy and hypodensities involving cerebral hemisphere, basal-ganglia and thalamus may be seen.^[27] Extensive white-matter involvement has been rarely reported.^[57]

MRI brain

Abnormalities in MRI brain is detected in almost all neurological WD cases.^[58] A study from north India reported a higher sensitivity for FLAIR and T2 sequence (97%) in detecting abnormalities in WD, with the former faring even better.^[33] Nearly all brain structures may be involved on brain MRI in neurological WD.^[58] Commonly reported findings include T2 hyperintensities involving bilateral basal-ganglia (72%), thalamus (58%) and midbrain (49%) along with atrophy involving cerebrum (70%), brainstem (66%) and cerebellum (52%) [Figure 3].^[58] Characteristic findings including the “face of giant panda” in midbrain and the “face of miniature panda” in pons have been described in <20% cases.^[58,59] Presence of T2 hyperintensities involving tectal plate and central pons resembling central pontine myelinolysis along with concurrent T2 hyperintensities in basal ganglia, thalamus and brainstem is highly suggestive of WD.^[59,60]

Magnetic resonance spectroscopy suggests reduced breakdown and/or elevated production of membrane phospholipids along with increased neuronal destruction in basal ganglia.^[61] While dysarthria, tremor, parkinsonism, dystonia and gait abnormalities correlates with lesions involving globus pallidus,^[58] choreoathetosis correlates with thalamic, pallidal and putaminal lesions and cognition with subcortical white matter changes.^[33] Interestingly, brain MRI in severe

neurological WD and postural instability may show midbrain atrophy.^[62] The extent and load of brain MRI lesions correlates with clinical severity,^[33,58] and diffusion restriction inversely correlates with duration of disease.^[42] Brain MRI lesions may resolve with clinical improvement in WD.^[63,64]

Neurophysiological studies

Abnormalities in visual evoked potentials (VEP), electro-retinography and brainstem auditory evoked potentials (BAEP) along with regaining of retinal function with improvement in clinical status have been reported.^[65,66] Taly *et al.*,^[27] described abnormalities in electroencephalogram (41.1%), brainstem auditory evoked potentials (42.1%) and visual evoked potentials (35%). A study from North India reported evoked potential abnormalities in 61% of neurological WD cases. Abnormalities were reported in motor evoked potential (35.7%), BAEP (61.5%), VEP (57%) and somatosensory evoked potential (30.7%), with the abnormalities in the latter three being subclinical.^[67] Abnormality in motor evoked potentials correlate with the clinical and neuroimaging findings involving motor pathway. Frequency of abnormalities in evoked potentials increases with clinical severity.^[67]

Modified Leipzig score

Indian experts from Hepatology, Pediatric Hepatology and Neurology modified the “Leipzig scoring system,” commonly used for diagnosing WD.^[1] They validated the “modified Leipzig score” in 70 WD cases. In the “modified Leipzig score,” additional points are allotted to positive family history of WD as well as to serum ceruloplasmin level <5 mg/dl, while use of D-penicillamine challenge test for assessing 24-hour urinary copper was removed.^[1] [Table 2]

Family screening

While siblings of a proband carries 25% risk, offspring and parents have 0.5% risk of developing WD.^[1] In absence of genetic testing, first-degree relatives including siblings, parents and offspring of a WD patient should undergo assessment for KF ring along with serum ceruloplasmin and 24-hour urinary copper.^[1] Monitoring for WD symptoms every 6-12 months is advocated even if diagnosis has been ruled out during first screening.^[1,68]

Treatment

Advances in WD management may help restore the pre-morbid functionality in symptomatic and avoid manifestations in asymptomatic cases. Treatment modalities in WD can be categorized in three groups:

- Anti-copper therapy: Copper chelators and zinc
- Symptomatic therapy: Medical (including injection botulinum toxin) and surgical therapies for alleviating severe neurological features (parkinsonism, dystonia and tremor).
- Definitive therapy: Liver transplantation

In addition to disease-specific therapy, patients should keep away from high copper containing foods including shellfish,

Table 2: Modified Leipzig Score for Diagnosing Wilson's Disease (Modified from Nagral *et al.*, 2019)^[1]

Features	Score
1 Kayser-Fleischer corneal rings	Present=2; Absent=0
2 Serum ceruloplasmin	Normal (>20 mg/dl) = 0; 0-5 mg/dl=3; 6-11 mg/dl=2; 12-20 mg/dl=1
3 24-hour urinary copper (in absence of acute hepatitis)	>100 mcg/day=2; 40-100 mcg/day=1; <40 mcg/day=0
4 Coomb's negative hemolytic anemia with liver disorder	Present=1; Absent=0
5 Genetic mutation	Detected on both chromosome=4/One chromosome=1/Not detected/test not done=0
6 Liver biopsy	Orcein or Rhodamine-positive granules=1
7 Neurobehavioral symptoms	Present=2; Absent=0
8 MRI brain	Typical features suggestive of WD present=1; absent=0
9 Family history of WD	Sibling death from liver or neurological features suggestive of WD=1
Total score	4 or more=Definitive diagnosis of WD 3=Possible WD and further evaluation needed 2 or less=WD unlikely

nuts, chocolate, mushrooms, and liver, especially in the early phase of treatment, at least for the first year.^[1] Use of copper utensils for cooking food should be discouraged.^[69] Caregivers must be counselled at the outset regarding the need for life-long de-coppering and maintenance of good compliance. Kalita *et al.*,^[70] reported a reduction in oxidative stress and improve clinical status in neurological WD cases receiving vitamin C and E along with anti-copper therapy.

Anti-copper therapy

Although dimercaprol (British anti-Lewisite, BAL) was the first copper chelator to be used,^[3] introduction of D-penicillamine in 1956 revolutionized the treatment of WD.^[4] Other drugs including zinc, Trientine, DMPS and tetrathiomolybdate were subsequently added to the therapeutic armamentarium. [Table 3]

Dimercaprol

Two-decades after its description in WD by Cumings, use of dimercaprol or British anti-Lewisite (BAL) was first reported in India by Dastur *et al.*,^[29] Although BAL failed to provide noticeable benefit in their patients,^[29] a series from South India reported significant clinical improvement.^[72] Due to need of daily deep intramuscular injection and waning of efficacy with time [Table 3], BAL fell out of favour once D-penicillamine became available.

D-penicillamine

Considered as the drug of choice in WD, it is the most commonly used copper-chelator in India.^[1] Possessing a sulfhydryl group along with an amino group, D-penicillamine chelates copper by making a stable ring complex with it. Having 4-8 times higher cupriuretic potential than BAL,^[68] a single gram of D-penicillamine chelates 200 mg of copper.^[1] Simultaneously, it induces hepatic cytosolic metallothionein which binds and neutralizes the toxic copper.^[1] Clinical stabilization and normalization of body copper balance may take months to years.^[1,68]

Although safe in pregnancy, excretion in breast milk makes it unsafe during breast-feeding.^[68] It is used in a dose of 20 mg/kg/day for children and up to a maximum dose of 2 gm/day in

adults. Since food interferes with its absorption, it should be administered at least an hour before or 2 hours after meals.^[1,68] Inhibition of pyridoxine kinase by D-penicillamine necessitates simultaneous supplementation of 20-40 mg/day of Pyridoxine, especially in pregnancy, childhood, malnourished state and patients suffering acute intercurrent illnesses.^[1]

Paradoxical neurological worsening (PNW) has been reported in 30-33% of Indian cases.^[35,73] A "start low and go slow" de-coppering policy is advocated.^[68] Initiating D-penicillamine at a lower dose of 250 mg/day with gradual escalation over weeks may reduce the risk.^[63] D-penicillamine may cause early and delayed hypersensitivity reaction. Early hypersensitivity warrants permanent discontinuation of DPM, especially in cases developing bone-marrow suppression (agranulocytosis and aplastic anemia) and glomerulonephritis or significant proteinuria.^[1] Long-term use of D-penicillamine interferes with lysyl-oxidase, thereby interrupting collagen and elastin linking, resulting in degenerative dermopathy and elastosis perforans serpiginoza.^[68,74] D-penicillamine may affect functionality of neuromuscular junction and generalized myasthenia gravis following its use has been reported,^[75] but Komal Kumar *et al.*,^[76] failed to detect any significant effect of the drug on neuromuscular junction.

Zinc

Zinc induced intestinal metallothionein traps absorbed copper in the mucosal cells and gets excreted when mucosa sloughs out naturally. It may also induce hepatocyte metallothionein, providing protection from copper toxicity.^[1] Zinc induces metallothionein slowly and normalization of copper balance takes a longer time as compared to copper chelators.^[68] Of the available zinc salts, acetate has the least incidence of gastritis.^[1] Zinc is used in a dose of 75 mg/day for children and adults weighing <50 Kg and 150 mg/day for the rest in three divided doses on empty stomach or away from meals.^[1] Since copper chelators including D-penicillamine and Trientine can chelate zinc, their doses should be kept separate to maintain the efficacy.^[68]

Low cost and easy availability of zinc along with manageable adverse effects makes it an attractive option for Indian

Table 3: Anti-Copper Drugs Used in Treatment of Wilson's Disease

Drugs	Route of administration & Dose	Adverse effects	Special remarks
A Copper chelators			
a. Dimercaprol (British anti-Lewisite) ^[68]	Deep intramuscular 5 mg/kg bolus f/b 2.5 mg/kg 1.5 ml (10% suspension in peanut oil) twice a day	Painful Hematoma & sterile abscess at injection site HT & tachycardia (dose dependent) Nausea, vomiting, abdominal pain Headache, paresthesia	BAL is lipid-soluble with best blood-brain barrier permeability amongst all copper-chelators Tachyphylaxis-efficacy reduces with continuous use Not preferred now – May be tried as a 1-month course in combination of DPM in refractory cases
b. Penicillamine ^[1,68]	Oral (in 2-3 divided doses) - Start low-go slow policy Adults: Up to 2 g/day Children: 20 mg/kg/day	Paradoxical neurological worsening (10-50% cases) Early drug HSE (< 3 weeks): fever, skin rash, thrombocytopenia, leucopenia, lymphadenopathy Late-onset HSE (months to years): lupus, Goodpasture syndrome, myasthenia, skin lesions/Penicillamine dermatopathy, ageusia, bone-marrow suppression, optic neuritis	Safe in pregnancy but avoid breast-feeding Anti-pyridoxine effect: Vit. B6 supplementation especially in pregnancy, acute illness or nutritional deficiencies Take away from meals Psychiatric features less responsive than neurological features
c. Trientine ^[68,71]	Oral (in 3 divided doses) - Start low-go slow policy Adults: 750 mg – 2 g/day Children: 20 mg/kg/day	Paradoxical neurological worsening (up to 26% cases) Late-onset HSE: lupus, nephritis Sideroblastic anemia Skin rash; ageusia Pancolitis; hemorrhagic gastritis	Safe in pregnancy but avoid breast-feeding Take away from meals Monitor for iron deficiency
d. Unithiol (Dimercapto Propane sulfonate) ^[68]	Oral 200 mg twice daily	Early HSE: fever, leucopenia Nausea, dysgeusia	A sulfonic acid derivative of dimercaprol Only few reports in literature; no reports from India to date
B Drug reducing gastrointestinal absorption of copper			
Zinc ^[1,68]	Oral 150 mg (adults) and 75 mg (children) of elemental zinc/day in 2-3 divided doses	Gastric irritation (especially with zinc sulphate salt) Elevation of serum amylase and lipase (asymptomatic) Paradoxical neurological worsening (rare)	Food interferes with absorption: give away from meals Safe in pregnancy Relatively slow to act – primarily used as maintenance therapy after initial therapy with copper chelators
C Drug which can chelate copper and reduce gastrointestinal absorption of copper			
Tetrathiomolybdate (Undergoing clinical trials – not commercially available) ^[71]	Oral 20 mg 3 times per day with meals and 3 times without meals	Bone-marrow suppression (reversible) Acute hepatitis Elevated aminotransferases, triglycerides and cholesterol Seizures Paradoxical neurological worsening (less common)	Damage epiphyseal bone-growth in animal studies – dangerous to use in children and adolescents

patients.^[11] On the contrary, a very slow anti-copper action and failure as a prophylaxis monotherapy in asymptomatic WD^[77] highlights its limitation, with many authorities limiting its use as a maintenance therapy after desirable negative copper balance is achieved using chelators.^[68] A couple of Indian studies highlight the efficacy of zinc monotherapy in maintenance phase.^[43,78] While Sinha *et al.*,^[78] reported nearly 90% success rate of Penicillamine withdrawal in neurological WD patients taking a combination of Penicillamine and zinc therapy, Gupta *et al.*,^[43] reported that switching from Penicillamine to zinc therapy may be a safe and effective

therapy in symptomatic hepatic WD across all grades of baseline disease severity.

Trientine

Unlike BAL and D-penicillamine, Trientine lacks sulfhydryl group, but its four amino groups forms a stable ring compound with copper to chelate it out.^[68] Although it can be used as a first line drug, huge cost and poor availability in India limits its use.^[27,73] Although safe in pregnancy, breast-feeding should be avoided as it is excreted in breast milk.^[68] It is used in a dose of 20 mg/kg/day in children and 750-2000 mg/day in adults in

three divided doses.^[1] It is heat-sensitive and requires storage in tightly closed containers between 2-8° C.^[1] Trientine induced PNW is less common as compared to D-penicillamine, with a series reporting 26% worsening.^[71] Early-onset hypersensitivity reaction to Trientine is less common than D-penicillamine.^[68] Late reactions including lupus and nephritis have also been reported.^[68]

Tetrathiomolybdate (TMB)

TMB acts by reducing copper absorption from gastrointestinal tract and also chelates out systemic copper. It needs a complex dosing schedule of 20 mg six times a day, three times with meals to serve the first purpose and thrice away from meals to fulfil the latter.^[71] Results of long-term therapy with TMB is lacking. The drug is currently undergoing multinational clinical trial and reports regarding its use in India is lacking.^[68]

Symptomatic therapy

Till the time anti-copper therapy stabilizes the clinical status, patient needs to be managed symptomatically. Levodopa-carbidopa and dopamine agonists may benefit parkinsonism. Anticholinergics and Benzodiazepines improve dystonic features and tremor. Botulinum toxin injection may help focal dystonia, and related tremor. Management of seizures require antiepileptics, preferably avoiding drugs with primary hepatic metabolism. Psychiatric manifestations may respond to behavioural therapy or antipsychotics, preferably the atypical ones to minimize the extrapyramidal side-effects.^[1] Lesioning surgery and deep brain stimulation targeting ventral intermediate nucleus of thalamus and globus pallidus internus for treating tremor and dystonia respectively may help drug-refractory extrapyramidal features in WD.^[8,79]

Liver transplant

Hepatic failure is the primary indication for liver transplantation (LT) in WD. Although its use in treating neurological WD is still unproven, a recent Indian study involving living-donor LT in predominantly hepatic WD cases

revealed neurological improvement in three cases having additional neurological features.^[80]

SPECIAL CIRCUMSTANCES

Sinha *et al.*,^[81] reported 50% success rate in 59 pregnancies involving 16 WD female patients, with 10 of them being diagnosed with WD during pregnancy. While spontaneous abortion occurred in 24 pregnancies, medical termination was done in two and still birth involved three pregnancies. Past pregnancies in these patients included 12 successful pregnancies and 9 spontaneous abortions. None of the patients reported any significant change in clinical status during pregnancy. Majority of these patients were on low dose D-penicillamine and zinc sulphate and no teratogenic effect was reported in babies born. Thus, pregnancy does not significantly alter the course of WD, but recurrent abortions are common in untreated WD.^[81] Microcephaly and short limbs have been reported in the foetus born to an untreated WD mother. (Supplementary document 2).

DISEASE MONITORING

Although several scales have been proposed for monitoring the disease activity in WD, Global Assessment Scale for Wilson's Disease (GAS for WD) involves a complete assessment including neuropsychiatric, hepatic and osseomuscular features along with their effect on quality of life,^[82] and has been validated by the same group.^[21] It consists of two tiers of assessment. [Table 4] Tier 1 of GAS assesses WD disability involving the liver, cognition and behaviour, motor and osseomuscular features with each domain being scored on a 6-point scale from 0 to 5. Tier 2 assesses neurological deficits including 14 items with each graded on a 5-point scale from 0 to 4. The total maximum score including tier 1 and 2 is 56.^[82]

PROGNOSIS

Early diagnosis and prompt initiation of treatment results

Table 4: Global Assessment Scale for Wilson's Disease (Modified From Aggarwal *et al.*, 2009)^[82]

Tier 1: Each domain scored from 0 to 5 based on its effect on activities of daily living such as personal hygiene, dressing, eating, walking etc.:

0=normal to 5=Life threatening liver disorder for item 1; completely dependent on caregivers for items 2, 3 and 4)

1. Liver: Includes clinical, biochemical and abdominal ultrasound assessment of liver
2. Cognition and behavior: Involves assessment of cognitive decline, depression and psychosis
3. Motor: Involves assessment of neurological motor deficits
4. Osseomuscular: Involves clinical or radiological assessment of bone, joint or muscle involvement

Tier 2: Neurological assessment (Items 1-13 scored from 0 to 4 based on clinical severity)

- | | |
|---------------------------|---|
| 1. Wilson's facies | 10. Swallowing |
| 2. Scholastic performance | 11. Salivation |
| 3. Depression | 12. Posture and gait |
| 4. Psychosis | 13. Kayser-Fleischer ring |
| 5. Dystonia | 14. Uncommon features: |
| 6. Tremor | (scored by presence or absence of uncommon features with maximum score for the item being 4): |
| 7. Chorea | Emotional lability; Seizures over preceding 1 month; Myoclonus; Stereotypy; Tics; Pyramidal signs; Eye movement abnormalities |
| 8. Parkinsonism | |
| 9. Speech | |

in favourable outcome with improved quality of life in majority of WD cases.^[1,83] Up to 90% Indian neurological WD cases recover back to pre-morbid functionality with adequate therapy and regular follow-up.^[27,32,35,43] Despite the best measures, nearly 5-15% cases may fail to improve and 6-8% cases may deteriorate and succumb to their illness.^[27,32,35] Patients with hepatic presentation carry a five-time higher risk of mortality than neurological WD.^[38] WD patients with acute hepatic involvement fare worse, with more than 50% mortality especially in those having hepatic encephalopathy.^[84]

CONCLUSION

WD seems more prevalent in India than the literature suggests. Epidemiological studies may enhance our understanding in this regard. Early recognition and adequate anti-copper therapy may improve the long-term outcome. A pan India registry of WD cases is the need of the hour. It will increase awareness about WD in the medical fraternity and help standardize the management protocol.

Authorship:

Dr. Niraj Kumar: Conception, design and writing the first draft.

Dr. Prashanth LK: Conception, design, review and critique.

Dr. Vinay Goyal: Conception, design, review and critique

Disclosures (related to this manuscript):

Dr. Niraj Kumar, Dr. Prashanth LK and Dr. Vinay Goyal report no disclosures relevant to the manuscript.

Funding:

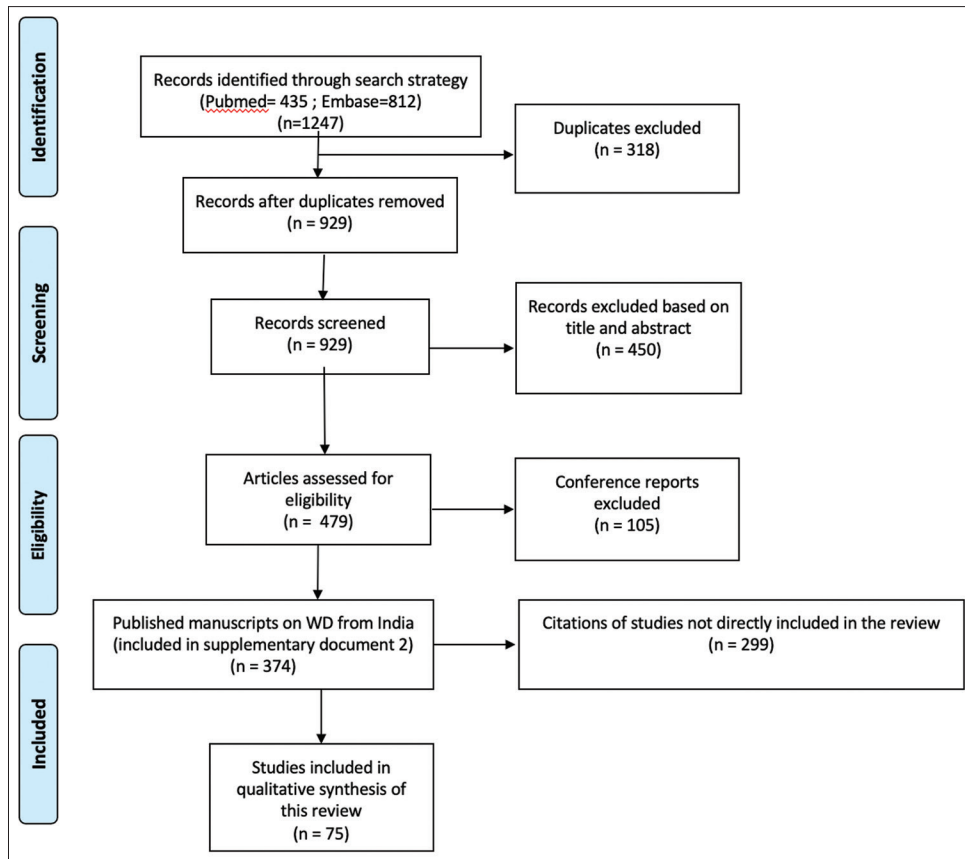
We report no funding for this study.

REFERENCES

- Nagral A, Sarma MS, Matthai J, Kukkle PL, Devarbhavi H, Sinha S, *et al.* Wilson's Disease: Clinical Practice Guidelines of the Indian National Association for Study of the Liver, the Indian Society of Pediatric Gastroenterology, Hepatology and Nutrition, and the Movement Disorders Society of India. *J Clin Exp Hepatol* 2019;9:74-98.
- Wilson SA. Progressive lenticular degeneration: A familial nervous disease associated with cirrhosis of the liver. *Brain* 1912;34:295-507.
- Cumings JN. The copper and iron content of brain and liver in the normal and in the hepatolenticular degeneration. *Brain* 1948;71:410-5.
- Walshe JM. Wilson's disease; new oral therapy. *Lancet* 1956;270:25-6.
- Schouwink G. De hepatocerebrale degeneratie, met een onderzoek naar zinkstofwisseling. In: University of Amsterdam, Thesis, MD, 1961.
- Walshe JM. Management of penicillamine nephropathy in Wilson's disease: A new chelating agent. *Lancet* 1969;294:1401-2.
- Walshe JM. Penicillamine: The treatment of first choice for patients with Wilson's disease. *Mov Disord* 1999;14:545-50.
- Prashanth LK, Taly AB, Sinha S, Arunodaya GR, Swamy HS. Wilson's disease: Diagnostic errors and clinical implications. *J Neurol Neurosurg Psychiatry* 2004;75:907-9.
- Liu J, Luan J, Zhou X, Cui Y, Han J. Epidemiology, diagnosis, and treatment of Wilson's disease. *Intractable Rare Dis Res* 2017;6:249-55.
- Yachha SK, Sharma BC, Khanduri A, Srivastava A. Current spectrum of hepatobiliary disorders in northern India. *Indian Pediatr* 1997;34:885-90.
- Taly AB, Prashanth LK, Sinha S. Wilson's disease: An Indian perspective. *Neurol India* 2009;57:528-40.
- Wadia NH, Dastur DK. Wilson's disease in four Indian families. *Neurol* 1963;11:1.
- Meenakshi-Sundaram S, Mahadevan A, Taly AB, Arunodaya GR, Swamy HS, Shankar SK. Wilson's disease: A clinico-neuropathological autopsy study. *J Clin Neurosci* 2008;15:409-17.
- Sinha S, Christopher R, Prashanth LK, Vidya N, Arunodaya GR, Rao S, *et al.* Malondialdehyde levels in Wilson's disease. *Ann Indian Acad Neurol* 2004;7:507-10.
- Goyal MK, Sinha S, Patil SA, Jayalekshmy V, Taly AB. Do cytokines have any role in Wilson's disease? *Clin Exp Immunol* 2008;154:74-9.
- Sinha S, Christopher R, Arunodaya GR, Prashanth LK, Gopinath G, Swamy HS, *et al.* Is low serum tocopherol in Wilson's disease a significant symptom? *J Neurol Sci* 2005;228:121-3.
- Kalita J, Kumar V, Misra UK, Ranjan A, Khan H, Konwar R. A study of oxidative stress, cytokines and glutamate in Wilson disease and their asymptomatic sibs. *J Neuroimmunol* 2014;274:141-8.
- Kalita J, Kumar V, Ranjan A, Misra UK. Role of oxidative stress in the worsening of neurologic Wilson disease following chelating therapy. *Neuromolecular Med* 2015;17:364-72.
- Singh N, Kallollimath P, Shah MH, Kapoor S, Bhat VK, Viswanathan LG, *et al.* Genetic analysis of ATP7B in 102 south Indian families with Wilson disease. *PLoS One* 2019;14:e0215779.
- Gupta A, Neogi R, Mukherjee M, Mukhopadhyay A, Roychoudhury S, Senapati A, *et al.* DNA linkage based diagnosis of Wilson disease in asymptomatic sibs. *Indian J Med Res* 2003;118:208-14.
- Aggarwal A, Chandhok G, Todorov T, Parekh S, Tilve S, Zibert A, *et al.* Wilson disease mutation pattern with genotype-phenotype correlations from Western India: Confirmation of p.C271* as a common Indian mutation and identification of 14 novel mutations. *Ann Hum Genet* 2013;77:299-307.
- Kumar S, Thapa BR, Kaur G, Prasad R. Identification and molecular characterization of 18 novel mutations in the ATP7B gene from Indian Wilson disease patients: Genotype [4]. *Clin Genet* 2005;67:443-5.
- Santhosh S, Shaji RV, Eapen CE, Jayanthi V, Malathi S, Chandy M, *et al.* ATP7B mutations in families in a predominantly southern Indian cohort of Wilson's disease patients. *Indian J Gastroenterol* 2006;25:277-82.
- Mukherjee S, Dutta S, Majumdar S, Biswas T, Jaiswal P, Sengupta M, *et al.* Genetic defects in Indian Wilson disease patients and genotype-phenotype correlation. *Park Relat Disord* 2014;20:75-81.
- Gupta A, Aikath D, Neogi R, Datta S, Basu K, Maity B, *et al.* Molecular pathogenesis of Wilson disease: Haplotype analysis, detection of prevalent mutations and genotype-phenotype correlation in Indian patients. *Hum Genet* 2005;118:49-57.
- Gupta A, Chattopadhyay I, Dey S, Nasipuri P, Das SK, Gangopadhyay PK, *et al.* Molecular pathogenesis of Wilson disease among Indians: A perspective on mutation spectrum in ATP7B gene, prevalent defects, clinical heterogeneity and implication towards diagnosis. *Cell Mol Neurobiol* 2007;27:1023-33.
- Taly AB, Meenakshi-Sundaram S, Sinha S, Swamy HS, Arunodaya GR. Wilson disease: Description of 282 patients evaluated over 3 decades. *Medicine (Baltimore)* 2007;86:112-21.
- Manghani DK, Dastur DK. Wilson's disease in India. II. Biochemical and pathogenetic considerations in patients, parents, and sibs. *Neurology* 1968;18:117-26.
- Dastur DK, Manghani DK, Wadia NH. Wilson's disease in India. I. Geographic, genetic, and clinical aspects in 16 families. *Neurology* 1968;18:21-31.
- Murthy BS, Murthy JM, Krishnaveni A, Reddy MV, Das SM. Wilson's disease in south India and experience with zinc therapy. *J Assoc Physicians India* 1988;36:417-9.
- Jha SK, Behari M, Ahuja GK. Wilson's disease: Clinical and radiological features. *J Assoc Physicians India* 1998;46:602-5.
- Sinha S, Jha DK, Sinha KK. Wilson's disease in Eastern India. *J Assoc Physicians India* 2001;49:881-4.
- Ranjan A, Kalita J, Kumar S, Bhoi SK, Misra UK. A study of MRI changes in Wilson disease and its correlation with clinical features and outcome. *Clin Neurol Neurosurg* 2015;138:31-6.
- Litwin T, Gromadzka G, Czlonkowska A. Gender differences in Wilson's disease. *J Neurol Sci* 2012;312:31-5.
- Panagariya A, Sureka RK, Sharma AK, Dev A, Agarwal N. Wilson's disease: A study of 21 cases from north-west India. *Ann Indian Acad*

- Neurol 2007;10:255-8.
36. Raiamani K, Sharma RN, John G, Raju JM, Ganesh A, John L. Wilson's disease in India: Clinical and laboratory manifestations in thirty patients. *J Assoc Physicians India* 1987;35:438-41.
 37. Kalra V, Khurana D, Mittal R. Wilson's disease--early onset and lessons from a pediatric cohort in India. *Indian Pediatr* 2000;37:595-601.
 38. Richard VS, Harris VK, Shankar V, Loganathan G, Chandy GM. Clinical manifestations and survival pattern of Wilson's disease. *Natl Med J India* 2000;13:301-3.
 39. Pandit A, Bavdekar A, Bhave S. Wilson's disease. *Indian J Pediatr* 2002;69:785-91.
 40. Tryambak S, Sumanta L, Radheshyam P, Sutapa G. Clinical profile, prognostic indicators and outcome of Wilson's disease in children: A hospital based study. *Trop Gastroenterol* 2009;30:163-6.
 41. Soni D, Shukla G, Singh S, Goyal V, Behari M. Cardiovascular and sudomotor autonomic dysfunction in Wilson's disease-Limited correlation with clinical severity. *Auton Neurosci Basic Clin* 2009;151:154-8.
 42. Pulai S, Biswas A, Roy A, Guin DS, Pandit A, Gangopadhyay G, *et al.* Clinical features, MRI brain, and MRS abnormalities of drug-naïve neurologic Wilson's disease. *Neurol India* 2014;62:153-8.
 43. Gupta P, Choksi M, Goel A, Zachariah U, Sajith KG, Ramachandran J, *et al.* Maintenance zinc therapy after initial penicillamine chelation to treat symptomatic hepatic Wilson's disease in resource constrained setting. *Indian J Gastroenterol* 2018;37:31-8.
 44. Kalita J, Misra UK, Kumar V, Parashar V. Predictors of seizure in Wilson disease: A clinico-radiological and biomarkers study. *Neurotoxicology* 2019;71:87-92.
 45. Prashanth LK, Sinha S, Taly AB, Mahadevan A, Vasudev MK, Shankar SK. Spectrum of epilepsy in Wilson's disease with electroencephalographic, MR imaging and pathological correlates. *J Neurol Sci* 2010;291:44-51.
 46. Hegde S, Sinha S, Rao SL, Taly AB, Vasudev MK. Cognitive profile and structural findings in Wilson's disease: A neuropsychological and MRI-based study. *Neurol India* 2010;58:708-13.
 47. Srinivas K, Sinha S, Taly AB, Prashanth LK, Arunodaya GR, Janardhana Reddy YC, *et al.* Dominant psychiatric manifestations in Wilson's disease: A diagnostic and therapeutic challenge! *J Neurol Sci* 2008;266:104-8.
 48. Shanmugiah A, Sinha S, Taly AB, Prashanth LK, Tomar M, Arunodaya GR, *et al.* Psychiatric manifestations in Wilson's disease: A cross-sectional analysis. *J Neuropsychiatry Clin Neurosci* 2008;20:81-5.
 49. Goyal V, Tripathi M. Sunflower cataract in Wilson's disease. *J Neurol Neurosurg Psychiatry* 2000;69:133.
 50. Misra AK, Biswas A, Ganguly G, Ghosh A, Das SK, Roy T. Arthropathic presentation of Wilson's disease. *J Assoc Physicians India* 2004;52:246-8.
 51. Bhattacharyya KB, Basu S, Chakravarty A. Three cases of Wilson's disease masquerading as childhood muscular dystrophy. *Basal Ganglia* 2012;2:115-7.
 52. Kapoor N, Cherian KE, Sajith KG, Thomas M, Eapen CE, Thomas N, *et al.* Renal tubular function, bone health and body composition in Wilson's disease: A cross-sectional study from India. *Calcif Tissue Int* 2019;105:459-65.
 53. Bajaj B, Wadhwa A, Singh R, Gupta S. Cardiac arrhythmia in Wilson's disease: An oversight and overlooked entity! *J Neurosci Rural Pract* 2016;7:587-9.
 54. Meenakshi-Sundaram S, Sinha S, Rao M, Prashanth LK, Arunodaya GR, Rao S, *et al.* Cardiac involvement in Wilson's disease—An electrocardiographic observation. *J Assoc Physicians India* 2004;52:294-6.
 55. Meenakshi-Sundaram S, Taly AB, Kamath V, Arunodaya GR, Rao S, Swamy HS. Autonomic dysfunction in Wilson's disease—A clinical and electrophysiological study. *Clin Auton Res* 2002;12:185-9.
 56. Netto AB, Sinha S, Taly AB, Panda S, Rao S. Sleep in Wilson's disease: A polysomnography-based study. *Neurol India* 2010;58:933-8.
 57. Saha P, Jain S, Mishra NK, Khosla A, Maheshwari MC. Extensive CT scan abnormality in Wilson's disease. *J Assoc Physicians India* 1991;39:568-9.
 58. Sinha S, Taly AB, Ravishankar S, Prashanth LK, Venugopal KS, Arunodaya GR, *et al.* Wilson's disease: Cranial MRI observations and clinical correlation. *Neuroradiology* 2006;48:613-21.
 59. Prashanth LK, Sinha S, Taly AB, Vasudev MK. Do MRI features distinguish Wilson's disease from other early onset extrapyramidal disorders? An analysis of 100 cases. *Mov Disord* 2010;25:672-8.
 60. Sinha S, Taly AB, Ravishankar S, Prashanth LK, Vasudev MK. Central pontine signal changes in Wilson's disease: Distinct MRI morphology and sequential changes with de-coppering therapy. *J Neuroimaging* 2007;17:286-91.
 61. Sinha S, Taly AB, Ravishankar S, Prashanth LK, Vasudev MK. Wilson's disease: 31P and 1H MR spectroscopy and clinical correlation. *Neuroradiology* 2010;52:977-85.
 62. Kalita J, Naik S, Bhoi SK, Misra UK, Ranjan A, Kumar S. Pontomesencephalic atrophy and postural instability in Wilson disease. *Am J Neuroradiol* 2017;38:1343-7.
 63. Prashanth LK, Taly AB, Sinha S, Ravishankar S, Arunodaya GR, Vasudev MK, *et al.* Prognostic factors in patients presenting with severe neurological forms of Wilson's disease. *QJM* 2005;98:557-63.
 64. Sinha S, Taly AB, Prashanth LK, Ravishankar S, Arunodaya GR, Vasudev MK. Sequential MRI changes in Wilson's disease with de-coppering therapy: A study of 50 patients. *Br J Radiol* 2007;80:744-9.
 65. Sathishchandra P, Swamy HS. Visual and brain stem auditory evoked responses in Wilson's disease. *Acta Neurol Scand* 1989;79:108-13.
 66. Sathishchandra P, Ravishankar Naik K. Visual pathway abnormalities Wilson's disease: An electrophysiological study using electroretinography and visual evoked potentials. *J Neurol Sci* 2000;176:13-20.
 67. Das M, Misra UK, Kalita J. A study of clinical, MRI and multimodality evoked potentials in neurologic Wilson disease. *Eur J Neurol* 2007;14:498-504.
 68. Aggarwal A, Bhatt M. Advances in treatment of Wilson disease. *Tremor Other Hyperkinet Mov* 2018;8:525.
 69. Singh S, Behari M. Wilson's disease. *J Assoc Physicians India* 2003;51:183-90.
 70. Kalita J, Kumar V, Misra UK, Parashar V, Ranjan A. Adjunctive antioxidant therapy in neurologic Wilson's disease improves the outcomes. *J Mol Neurosci* 2020;70:378-85.
 71. Brewer GJ, Askari F, Lorincz MT, Carlson M, Schilsky M, Kluin KJ, *et al.* Treatment of Wilson disease with ammonium tetrathiomolybdate. *Arch Neurol* 2006;63:521-7.
 72. Singh DS, Bisht DB, Sharma RN, Ranganathan P, Ramakrishnan S. Wilson's disease in South India. *J Assoc Physicians India* 1978;26:217-22.
 73. Kalita J, Kumar V, Chandra S, Kumar B. Worsening of Wilson Disease following penicillamine therapy. *Eur Neurol* 2014;71:126-31.
 74. Khandpur S, Jain N, Singla S, Chatterjee P, Behari M. D-penicillamine induced degenerative dermopathy. *Indian J Dermatol* 2015;60:406-9.
 75. Narayanan CS, Behari M. Generalized myasthenia gravis following use of D-penicillamine in Wilson's disease. *J Assoc Physicians India* 1999;47:648.
 76. Kumar RK, Patil SA, Taly AB, Nirmala M, Sinha S, Arunodaya GR. Effect of D-penicillamine on neuromuscular junction in patients with Wilson disease. *Neurology* 2004;63:935-6.
 77. Mishra D, Kalra V, Seth R. Failure of prophylactic zinc in Wilson disease. *Indian Pediatr* 2008;45:151-3.
 78. Sinha S, Taly AB. Withdrawal of penicillamine from zinc sulphate – penicillamine maintenance therapy in Wilson's disease : Promising, safe and cheap. *J Neurol Sci* 2008;264:129-32.
 79. Pal PK, Sinha S, Pillai S, Taly AB, Abraham RG. Successful treatment of tremor in Wilson's disease by thalamotomy: A case report. *Mov Disord* 2007;22:2287-90.
 80. Choudhary NS, Saigal S, Saraf N, Rastogi A, Goja S, Bhangui P, *et al.* Outcome of living donor liver transplantation for Wilson's disease in adults: A single center experience. *J Clin Exp Hepatol* 2018;8:132-5.
 81. Sinha S, Taly AB, Prashanth LK, Arunodaya GR, Swamy HS. Successful pregnancies and abortions in symptomatic and asymptomatic Wilson's disease. *J Neurol Sci* 2004;217:37-40.
 82. Aggarwal A, Aggarwal N, Nagral A, Jankharia G, Bhatt M. A novel global assessment scale for Wilson's disease (GAS for WD). *Mov*

- Disord 2009;24:509-18.
83. Kumar RK, Taly A, Nair KP, Sinha S, Prashanth LK, Vidya N, *et al.* Quality of life in Wilson's disease. Ann Indian Acad Neurol 2008;11:37-43.
84. Devarbhavi H, Singh R, Adarsh CK, Sheth K, Kiran R, Patil M. Factors that predict mortality in children with Wilson disease associated acute liver failure and comparison of Wilson disease specific prognostic indices. J Gastroenterol Hepatol 2014;29:380-6.



Supplementary document 1: PRISMA flow chart for articles selection